

Case Report

# Successful Treatment of Primary Cutaneous Peripheral T-Cell Lymphoma Presenting Acquired Ichthyosis with Oral Bexarotene Monotherapy

Kayo Tanita Taku Fujimura Yota Sato Takanori Hidaka  
Sadanori Furudate Yumi Kambayashi Akira Tsukada Akira Hashimoto  
Setsuya Aiba

Department of Dermatology, Tohoku University Graduate School of Medicine,  
Sendai, Japan

## Keywords

Peripheral T-cell lymphoma not otherwise specified · Bexarotene · Acquired ichthyosis

## Abstract

Acquired ichthyosis (AI) is a reactive cutaneous manifestation that can be associated with malignant hematological disease, including cutaneous T-cell lymphoma (CTCL). Since it is difficult to distinguish AI from ichthyosiform mycosis fungoides, to select the treatment for CTCL with ichthyosis-like appearance and to evaluate its efficacy is sometimes challenging. In this report, we describe a case of primary cutaneous peripheral T-cell lymphoma not otherwise specified presenting AI successfully treated with oral bexarotene. In the present case, the administration of oral bexarotene was not only effective for lymphoma cells infiltrating ulcers and nodules, but it also eliminated AI.

© 2017 The Author(s)  
Published by S. Karger AG, Basel

## Introduction

Acquired ichthyosis (AI) is a reactive cutaneous manifestation that can be associated with malignant hematological disease, including cutaneous T-cell lymphoma (CTCL) [1]. Among the various lymphomas, CD30+ lymphomas, such as Hodgkin lymphomas and CD30+ lymphoproliferative disorders (anaplastic large-cell lymphoma, lymphomatoid papulosis), occasionally present an ichthyosiform appearance and merely cause other variants of CTCL, including peripheral T-cell lymphoma not otherwise specified (PTCL-NOS). On the other hand, ichthyosiform mycosis fungoides (MF) is a rare variant of MF, histologically showing epidermotropic infiltration of atypical lymphocytes [2–4]. In this report, we describe a case of primary cutaneous PTCL-NOS presenting AI successfully treated with oral bexarotene.

## Case Report

A 45-year-old Japanese man visited our outpatient clinic with a 5-year history of systemic ichthyosis-like scaly erythema with subcutaneous nodules on the wrist and lower leg. On his initial visit, physical examination revealed prominent, large scales on the extensor surface of the extremities (Fig. 1a). Moreover, elastic, subcutaneous nodules were detected on the bilateral wrists (Fig. 1b). A biopsy specimen from the left wrist revealed atypical lymphoid cells densely infiltrated from the upper dermis to the subcutaneous tissue (Fig. 1c). In contrast, few atypical, large cells were detected in the lesional skin of an ichthyosis-like eruption (Fig. 1d). Immunohistochemical staining revealed that these atypical lymphocytes, which were distributed throughout the dermis, were positive for CD3, CD4, CD5, and CD45, and negative for CD7, CD8, and CD30. Assessment of T-cell receptor (TCR) gene rearrangement by Southern blot analysis confirmed the monoclonality of the TCR $\beta$  chain. A full blood count and biochemical profile revealed slightly increased levels of serum IL-2R (634 U/mL) and normal levels of serum LDH (195 U/L). We screened for possible metastatic lesions with positron emission tomography and found no evidence of lymph node swelling or visceral lesions. From the above findings, we diagnosed the patient as having primary cutaneous PTCL-NOS (T3N0M0 stage IIB) presenting AI. We first treated the patient with oral prednisolone 30 mg/day without any effects. During oral intake of prednisolone, he developed an ulcer with prominent necrotic tissue on the right shin (Fig. 2a), and we administered etoposide 50 mg/day for 1 year. The necrotic ulcer gradually improved with scarring, but a deep, vermicular ulcer remained (Fig. 2b). Moreover, around the ulcer, a prominent adherence of large scales still remained. We then administered oral bexarotene 300 mg/m<sup>2</sup>/day. The ulcer was cured with scarring, and the ichthyosis-like scales diminished within 8 weeks after the administration of bexarotene (Fig. 2c). The elastic subcutaneous nodules on the bilateral wrists also regressed during the 8 weeks.

## Discussion

AI is a reactive cutaneous manifestation that may be associated with malignant hematological disease, including CTCL [5]. On the other hand, ichthyosiform MF is a rare variant of MF, histologically showing epidermotropic infiltration of atypical lymphocytes [2–4]. Since an ichthyosiform eruption contains sparsely infiltrating lymphocytes, it is difficult to distinguish AI and ichthyosiform MF by clinical appearance, immunohistochemical staining, or

analysis of the TCR rearrangement. Therefore, to select a treatment for CTCL with an ichthyosis-like appearance and to evaluate its efficacy is sometimes challenging. In this report, we describe a case of primary cutaneous PTCL-NOS presenting AI successfully treated with oral bexarotene. In the present case, the administration of oral bexarotene was effective not only for the lymphoma-infiltrating ulcers and nodules, but it also eliminated the AI.

Bexarotene is a third-generation retinoid X receptor-selective retinoid, which is administered for the treatment for CTCLs. The mechanisms of its antitumor effects are diverse [6]. For example, bexarotene produces dose-dependent apoptosis of CTCL cells by reducing the serum IL-4 in patients with Sézary syndrome [7]. In another report, bexarotene reduced the expression of CCR4 and E-selectin, leading to suppressed migration of CTCL cells in the lesional skin [8]. Notably, the production of CCL17 and CCL22 from tumor-associated macrophages (TAMs) is augmented by the stimulation of IL-4 [5, 9], which is abundant in the cancer stroma of advanced MF [10]. Since TAMs are necessary for the formation of CTCLs in the lesional skin [11], the decreased levels of IL-4 by the administration of bexarotene could reduce both chemokines from TAMs and the expression of chemokine receptors on CTCL cells, leading to the suppression of cancer formation in the lesional skin of CTCL.

In addition to the immunomodulation, bexarotene effects the proliferation and differentiation of epidermal keratinocytes [12, 13]. Indeed, these previous reports suggested that retinoid X receptor activation by bexarotene induces normalization of keratinocyte differentiation, leading to its therapeutic effects on psoriasis [12, 13]. Although the suppression of CTCL itself might effect the AI as a dermatome of lymphomas, the effects of bexarotene on keratinocytes might have improved the AI appearance in our present case. This report presents only a single case, but further cases may provide fundamental insights into the mechanisms of the effects of bexarotene on lymphomas and AI.

### Statement of Ethics

The patient gave written informed consent.

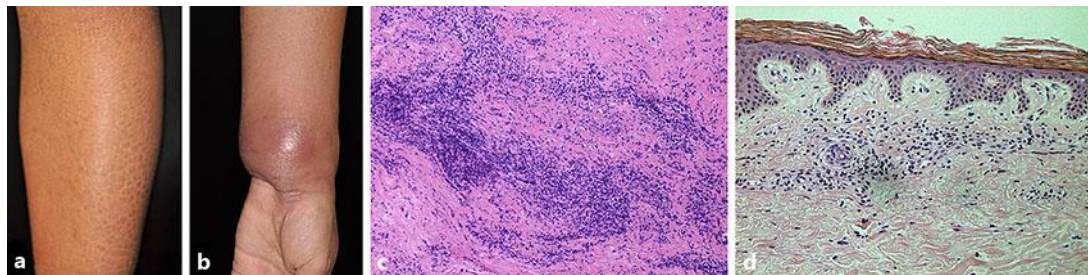
### Disclosure Statement

The authors declare no conflicts of interest.

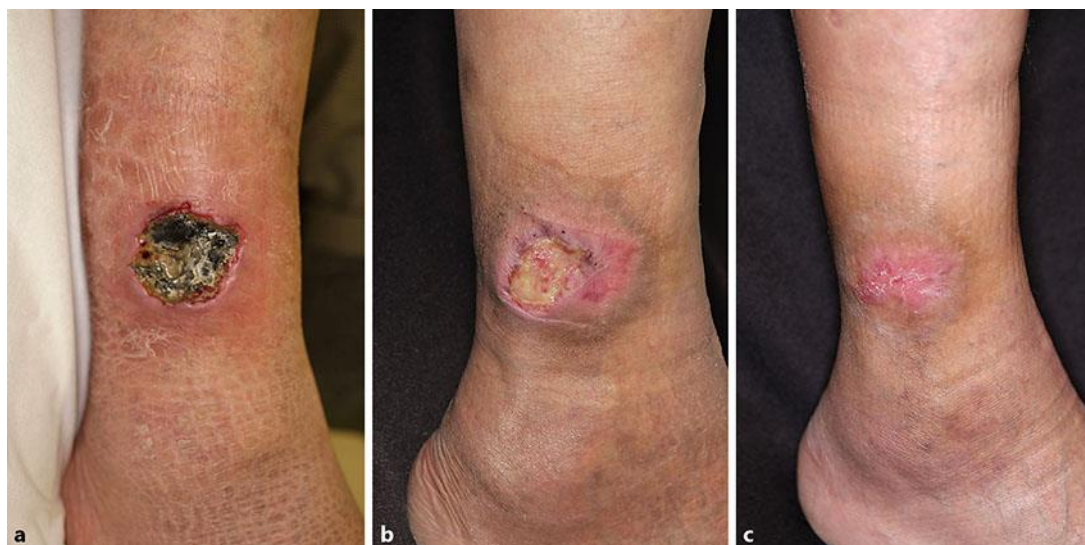### References

- 1 Morizane S, Setsu N, Yamamoto T, Hamada T, Nakanishi G, Asagoe K, Iwatsuki K: Ichthyosiform eruptions in association with primary cutaneous T-cell lymphomas. *Br J Dermatol* 2009;161:115–120.
- 2 Kütting B, Metze D, Luger TA, Bonsmann G: Mycosis fungoides presenting as an acquired ichthyosis. *J Am Acad Dermatol* 1996;34(5 Pt 2):887–889.
- 3 Marzano AV, Borghi A, Facchetti M, Alessi E: Ichthyosiform mycosis fungoides. *Dermatology* 2002;204:124–129.
- 4 Hodak E, Amitay I, Feinmesser M, Aviram A, David M: Ichthyosiform mycosis fungoides: an atypical variant of cutaneous T-cell lymphoma. *J Am Acad Dermatol* 2004;50:368–374.
- 5 Furudate S, Fujimura T, Kakizaki A, Hidaka T, Asano M, Aiba S: Tumor-associated M2 macrophages in mycosis fungoides acquire immunomodulatory function by interferon alpha and interferon gamma. *J Dermatol Sci* 2016;83:182–189.
- 6 Panchal MR, Scarisbrick JJ: The utility of bexarotene in mycosis fungoides and Sézary syndrome. *Onco Targets Ther* 2015;8:367–373.

- 7 Budgin JB, Richardson SK, Newton SB, Wysocka M, Zaki MH, Benoit B, Rook AH: Biological effects of bexarotene in cutaneous T-cell lymphoma. *Arch Dermatol* 2005;141:315–321.
- 8 Richardson SK, Newton SB, Bach TL, Budgin JB, Benoit BM, Lin JH, Yoon JS, Wysocka M, Abrams CS, Rook AH: Bexarotene blunts malignant T-cell chemotaxis in Sezary syndrome: reduction of chemokine receptor 4-positive lymphocytes and decreased chemotaxis to thymus and activation-regulated chemokine. *Am J Hematol* 2007;82:792–797.
- 9 Fujimura T, Kakizaki A, Furudate S, Kambayashi Y, Aiba S: Tumor-associated macrophages in skin: how to treat their heterogeneity and plasticity. *J Dermatol Sci* 2016;83:167–173.
- 10 Furudate S, Fujimura T, Kakizaki A, Kambayashi Y, Asano M, Watabe A, Aiba S: The possible interaction between periostin expressed by cancer stroma and tumor-associated macrophages in developing mycosis fungoides. *Exp Dermatol* 2016;25:107–112.
- 11 Wu X, Schulte BC, Zhou Y, Haribhai D, Mackinnon AC, Plaza JA, Williams CB, Hwang ST: Depletion of M2-like tumor-associated macrophages delays cutaneous T-cell lymphoma development in vivo. *J Invest Dermatol* 2014;134:2814–2822.
- 12 Smit JV, de Jong EM, van Hooijdonk CA, Otero ME, Boezeman JB, van de Kerkhof PC: Systemic treatment of psoriatic patients with bexarotene decreases epidermal proliferation and parameters for inflammation, and improves differentiation in lesional skin. *J Am Acad Dermatol* 2004;51:257–264.
- 13 Franssen ME, Smit JV, van Erp PE, van de Kerkhof PC: A multiparameter flow cytometric analysis of the effect of bexarotene on the epidermis of the psoriatic lesion. *Br J Dermatol* 2003;149:506–512.



**Fig. 1.** **a** Prominent, large scales adhered to the extensor surface of the extremities. **b** Elastic, subcutaneous nodules were detected on the bilateral wrists. **c** Atypical lymphoid cells densely infiltrated from the upper dermis to the subcutaneous tissue, with involvement of the overlying epidermis. **d** Few atypical, large cells were detected in the lesional skin of the ichthyosis-like eruption. **c, d** Original magnification,  $\times 100$ .



**Fig. 2.** **a** Ulcer with prominent necrotic tissue on the right shin. **b** Just before the administration of bexarotene. **c** Eight weeks after the administration of bexarotene.