








Transvaginal Direct Puncture and Ethanol Sclerotherapy for Cervicovaginal Venous Malformations: A Case Report and Literature Review

자궁경부 및 질에 발생한 정맥기형에 대한 질 경유 직접 천자 및 에탄올 경화요법: 증례 보고 및 문헌 고찰

Gu Seong Jeong, MD¹ , Suk Hyun Bae, MD^{1*} , Young Soo Do, MD² ,
Hyoung Nam Lee, MD³ , Sang Joon Lee, MD⁴ 

¹Department of Radiology, Inje University College of Medicine, Ilsan Paik Hospital, Goyang, Korea

²Department of Radiology, Samsung Medical Center, Sungkyunkwan University School of Medicine, Seoul, Korea

³Department of Radiology, Soonchunhyang University Cheonan Hospital, Cheonan, Korea

⁴Department of Radiology, Kangwon National University Hospital, College of Medicine, Kangwon National University, Chuncheon, Korea

Cervicovaginal venous malformations are extremely rare. Sclerotherapy is proven to be effective for superficial venous malformations but not for venous malformations in the lower genital tract of female. A 52-year-old female presented with intermittent vaginal bleeding. The amount of vaginal bleeding gradually increased over 3 months. Contrast-enhanced pelvis CT showed several phleboliths and dilated vessels, but pelvic angiography showed no early draining veins, nidus, or feeding artery. We performed transvaginal direct puncture and ethanol sclerotherapy rather than surgical treatment because she wanted to preserve the uterus. After four sessions of sclerotherapy, she had significantly decreased vaginal bleeding without complications. Here, we report the first case of cervicovaginal venous malformations successfully treated with transvaginal direct puncture and ethanol sclerotherapy.

Index terms Cervix Uteri; Vagina; Vascular Malformation; Ethanol; Sclerotherapy

INTRODUCTION

Vascular anomalies are divided into two broad biologic categories: vascular or vasoproliferative neoplasms and vascular malformations, according to the 1996 Interna-

Received June 4, 2020

Revised July 5, 2020

Accepted July 12, 2020

*Corresponding author

Suk Hyun Bae, MD
Department of Radiology,
Inje University College of Medicine,
Ilsan Paik Hospital,
170 Juhwa-ro, Ilsanseo-gu,
Goyang 10380, Korea.

Tel 82-31-910-7607

Fax 82-31-910-7369


E-mail baesuckhyun@naver.com

This is an Open Access article distributed under the terms of the Creative Commons Attribution Non-Commercial License (<https://creativecommons.org/licenses/by-nc/4.0/>) which permits unrestricted non-commercial use, distribution, and reproduction in any medium, provided the original work is properly cited.


ORCID iDs

Gu Seong Jeong 


<https://orcid.org/0000-0003-4024-4563>

Suk Hyun Bae 


<https://orcid.org/0000-0002-1888-2510>

Young Soo Do 

<https://orcid.org/0000-0002-6603-6474>

Hyoung Nam Lee 

<https://orcid.org/0000-0002-2135-9384>

Sang Joon Lee 

<https://orcid.org/0000-0001-6492-514X>

tional Society for the Study of Vascular Anomalies classification proposed by Mulliken and Glowacki's (1). Vascular malformations are also subdivided into high-flow versus low-flow lesions according to their rheology. According to the classification, venous malformations (VMs) are included in slow-flow malformations (1, 2).

About 40% of VMs are found in the head and neck region (3). Especially, VMs in the female lower genital tract were very rarely reported (4). Management of VM have various treatment options such as observation, sclerotherapy, surgical excision or a combination of these treatments (2). Among them surgical treatment is preferred in VM of the female lower genital tract (4). We report here the first case of successful direct puncture and ethanol sclerotherapy for cervicovaginal VM of a 52-year-old female via transvaginal route.

CASE REPORT

A 52-year-old female, para 2-0-0-2, presented with history of intermittent vaginal bleeding for the last two years. She looked a little pallor, but physical examination findings and laboratory studies were unremarkable. Also, she has no previous history of abortion, trauma and abdominal surgery. She has been on conservative treatment for the last two years, but the amount of vaginal bleeding began to increase over the late three months.

Transvaginal ultrasonography and contrast enhanced pelvis CT revealed several phleboliths and dilated vessels around the cervicovaginal wall without early draining veins (Fig. 1A). Pelvic angiography showed no feeding artery, nidus and early draining veins (Fig. 1B, C). On these findings, the lesion was considered most likely to be the VM rather than the arteriovenous malformation.

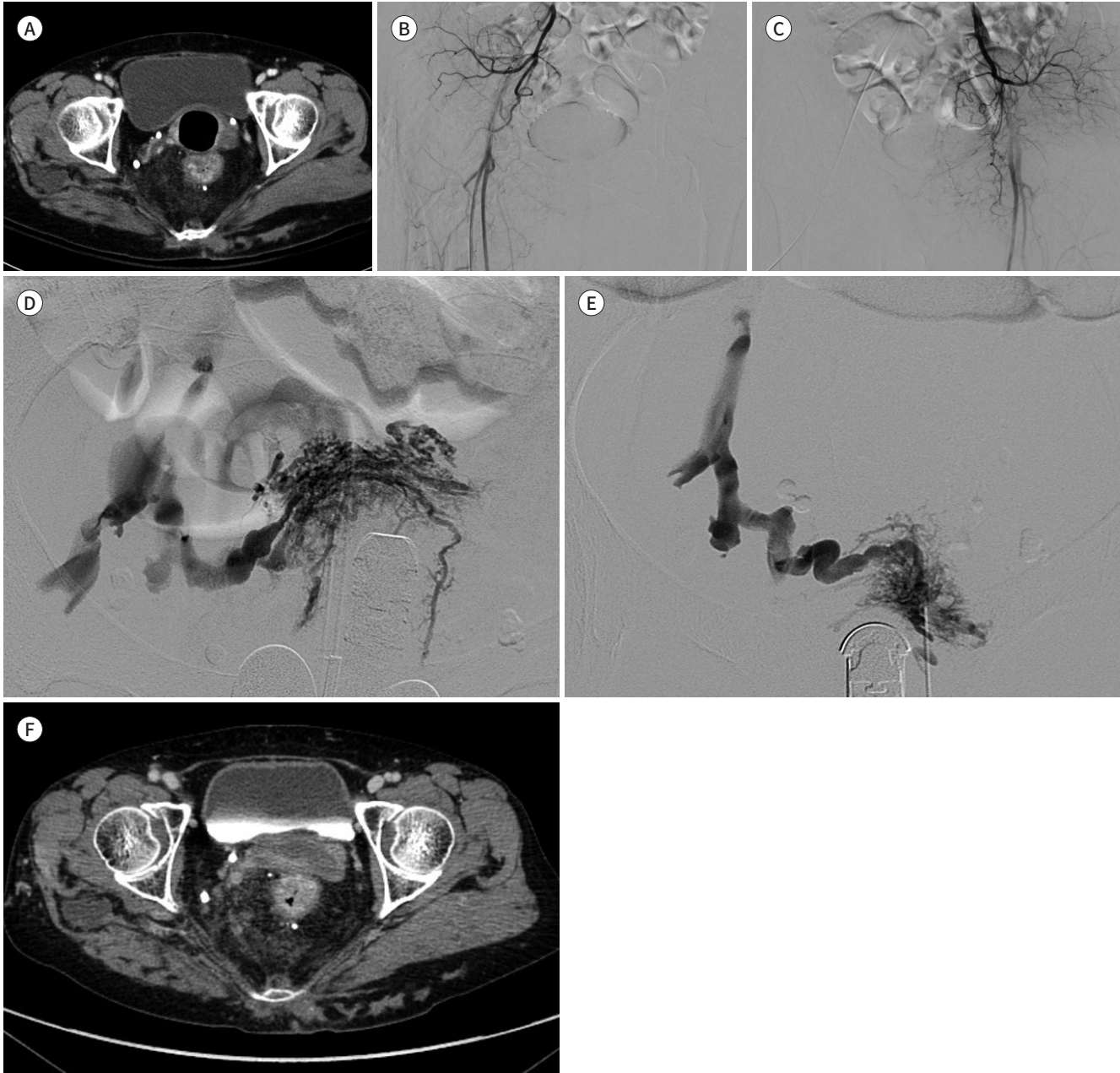We considered percutaneous ethanol sclerotherapy rather than surgical treatment because she wanted to preserve the uterus. A procedure was performed under general anesthesia with lithotomy position. A 21-gauge Chiba needle (Cook Inc., Bloomington, IN, USA) attached to transvaginal probe was inserted through the vagina. Under ultrasonography guidance, the dilated vessels around the cervicovaginal wall was punctured with a 21-gauge Chiba needle. To identify abnormal dilated veins, a test injection of contrast medium was performed under fluoroscopy. And ethanol sclerotherapy were performed using 80% ethanol as an embolic agent (Fig. 1D, E). She received 4 sessions of ethanol sclerotherapy treatment at three month intervals. After one year, a follow-up enhanced CT scans showed that previous dilated vessels decreased around the right cervicovaginal wall (Fig. 1F). The patient had significantly decreased vaginal bleeding without complication after 4 sessions of sclerotherapy. If the amount of vaginal bleeding increases, additional sclerotherapy may be considered, but additional treatment is not currently planned due to a significant reduction in vaginal bleeding and increased patient satisfaction.

DISCUSSION

VMs are the most common vascular malformation in the body with a prevalence of 1% of the population (5). More than 40% of cases are found in the head and neck (3, 5). VMs are congenital lesions and become symptomatic with the child's growth. However, they may not be

Fig. 1. Transvaginal ethanol sclerotherapy in a 52-year-old female with cervicovaginal venous malformations.

A. Contrast-enhanced pelvis CT shows several phleboliths and dilated vessels without early draining veins around the cervicovaginal wall.
B, C. Pretreatment pelvic angiography shows no feeding artery, nidus, or early draining veins.
D, E. First (**D**) and third (**E**) sessions of transvaginal direct puncture and ethanol sclerotherapy was done for cervicovaginal venous malformations.
F. One-year follow-up contrast-enhanced CT shows a decrease in dilated vessels around the right cervicovaginal wall.



noticed for life without rapid enlargement of VMs (2, 4).

Cervical or vaginal VMs are extremely rarely reported. Wang et al. (4) reported that only three patients involved the cervicovaginal lesions among 646 female patients with unclassified vascular anomalies. Karpathiou et al. (6) reported 8 cases of VM lesions in vagina or cervix of 50000 gynecological tract specimens during a 20 years period. In most cases, cervico-

vaginal VMs are asymptomatic and require no treatment. However, if the patient has symptoms such as abnormal vaginal bleeding or protruding mass, treatment is needed (4, 7).

In the localized lesion of cervicovaginal VMs, it is preferred to selective embolization, local excision or a combined procedure rather than hysterectomy. However, hysterectomy is preferred in the case of diffuse lesion or older patients (4). In diffuse lesion of our case, we performed direct puncture and ethanol sclerotherapy rather than hysterectomy. We report the first case of successful treatment of the cervicovaginal VM as transvaginal direct puncture and ethanol sclerotherapy.

In conclusion, our case provide evidence that transvaginal direct puncture and ethanol sclerotherapy is relatively noninvasive, safely, and effective alternative treatment option in the cervicovaginal VM.

Author Contributions

Writing—original draft, all authors; and writing—review & editing, all authors.

Conflicts of Interest

The authors have no potential conflicts of interest to disclose.

Funding

None

REFERENCES

1. Kollipara R, Dinneen L, Rentas KE, Saettele MR, Patel SA, Rivard DC, et al. Current classification and terminology of pediatric vascular anomalies. *AJR Am J Roentgenol* 2013;201:1124-1135
2. Steiner F, FitzJohn T, Tan ST. Ethanol sclerotherapy for venous malformation. *ANZ J Surg* 2016;86:790-795
3. Baek HJ, Hong JP, Choi JW, Suh DC. Direct percutaneous alcohol sclerotherapy for venous malformations of head and neck region without fluoroscopic guidance: technical consideration and outcome. *Neurointervention* 2011;6:84-88
4. Wang S, Lang JH, Zhou HM. Venous malformations of the female lower genital tract. *Eur J Obstet Gynecol Reprod Biol* 2009;145:205-208
5. Fowell C, Vereá Linares C, Jones R, Nishikawa H, Monaghan A. Venous malformations of the head and neck: current concepts in management. *Br J Oral Maxillofac Surg* 2017;55:3-9
6. Karpathiou G, Chauleur C, Da Cruz V, Forest F, Peoc'h M. Vascular lesions of the female genital tract: clinicopathologic findings and application of the ISSVA classification. *Pathophysiology* 2017;24:161-167
7. Casey PM, Long ME, Marnach ML. Abnormal cervical appearance: what to do, when to worry? *Mayo Clin Proc* 2011;86:147-150; quiz 151

자궁경부 및 질에 발생한 정맥기형에 대한 질 경유 직접 천자 및 에탄올 경화요법: 증례 보고 및 문헌 고찰

정구성¹ · 배석현^{1*} · 도영수² · 이형남³ · 이상준⁴

자궁경부 및 질에 발생하는 정맥기형은 매우 드문 질환이다. 표피적 정맥기형에 대한 경화요법은 매우 효과적인 것으로 알려져 있으나, 여성 하부 생식기에서의 정맥기형에 대한 효과는 아직 증명되지 않았다. 52세 여자 환자가 간헐적인 질 출혈을 보였다. 3달 동안 질 출혈의 양은 점차 증가했다. 조영 후 골반 컴퓨터단층촬영에서 자궁경부 및 질 주변으로 다수의 정맥돌 및 확장된 정맥들이 보였으나, 골반 혈관조영술에서 조기 유출 정맥, 핵과 영양동맥은 보이지 않았다. 환자는 자궁 보존 치료를 위하여 수술보다는 질 경유 직접 천자 및 에탄올 경화요법을 시행했다. 총 4회 경화요법 후, 환자는 합병증 없이 질 출혈이 상당 부분 감소했다. 저자들은 질 경유 직접 천자 및 에탄올 경화요법을 이용한 자궁경부 및 질의 정맥기형의 성공적 치료를 경험하였기에 문헌 고찰과 함께 보고하는 바이다.

¹인제대학교 의과대학 일산백병원 영상의학과,

²성균관대학교 의과대학 삼성서울병원 영상의학과,

³순천향대학교 천안병원 영상의학과,

⁴강원대학교 의과대학 강원대학교병원 영상의학과