

Received: 2016.06.09
Accepted: 2016.08.03
Published: 2016.09.09

ISSN 1941-5923
© Am J Case Rep, 2016; 17: 655-659
DOI: 10.12659/AJCR.899997

Gingival Fibromatosis with Significant *De Novo* Formation of Fibrotic Tissue and a High Rate of Recurrence

Authors' Contribution:
Study Design A
Data Collection B
Statistical Analysis C
Data Interpretation D
Manuscript Preparation E
Literature Search F
Funds Collection G

ABCDEF 1 **Katarzyna Gawron**
BCD 2 **Katarzyna Łazarz-Bartyzel**
BCD 3 **Andrzej Fertala**
BCD 4 **Paweł Plakwicz**
AEF 1,5 **Jan Potempa**
ACDE 2 **Maria Chomyszyn-Gajewska**

1 Department of Microbiology, Faculty of Biochemistry, Biophysics and Biotechnology, Jagiellonian University, Krakow, Poland
2 Department of Periodontology and Oral Medicine, Jagiellonian University, Medical College, Institute of Dentistry, Krakow, Poland
3 Department of Orthopaedic Surgery, Sidney Kimmel Medical College, Thomas Jefferson University, Philadelphia, PA, U.S.A.
4 Department of Periodontology, Medical University of Warsaw, Warsaw, Poland
5 Oral Health and Systemic Disease Research Group, School of Dentistry, University of Louisville, Louisville, KY, U.S.A.

Corresponding Authors: Katarzyna Gawron, e-mail: katarzyna.gawron@uj.edu.pl; Maria Chomyszyn-Gajewska, e-mail: mdgajews@cyf-kr.edu.pl
Conflict of interest: None declared
Source of support: This work was supported by grant from the National Science Centre, Poland (2012/07/B/NZ6/03524 to K.G.)

Patient: Female, 11
Final Diagnosis: Hereditary gingival fibromatosis
Symptoms: Gingival overgrowth
Medication: —
Clinical Procedure: Surgery
Specialty: Dentistry


Objective: Rare disease
Background: Hereditary gingival fibromatosis is characterized by slowly progressive enlargement of the gingiva that can present as an isolated condition or a part of various syndromes.

Case Report: An 11-year-old female reported with a gingival lesion that caused masticatory problems and poor oral hygiene. Periodontal examination revealed a dense tissue covering 30% of her teeth crowns within both jaws. Panoramic x-ray showed a normal bone height and teeth positioning. The patient did not use any medications, but a similar condition was also present in other family members. The patient was diagnosed with hereditary gingival fibromatosis. Surgery was carried out to remove excess of gingival tissue. Post-surgical healing was uneventful, but four weeks after the first surgery, the condition recurred amounting to 45% of the initial tissue volume presenting in the mandible, and 25% in the maxilla. Two months later, no significant growth was noted in the mandible, while in the maxilla, growth increased to 40% of the pre-operative state. Analysis by polarized microscope showed a significant increase of thin fibrotic fibrils that contributed 80% of the total pool of collagen fibrils in the patient's gingiva, but only 25% in healthy gingiva. The patient was receiving outpatient care for follow-up every three months and surgical intervention had not been planned as long as her periodontal health would not be compromised.

Conclusions: It is currently not clear whether the extent of the fibrosis had a mechanistic association with the ratio of gingival tissue re-growth in our case study. Further studies are needed to explain this association and improve the management of this condition.

MeSH Keywords: Collagen Type I • Fibromatosis, Gingival • Recurrence • Treatment Outcome

Full-text PDF: <http://www.amjcaserep.com/abstract/index/idArt/899997>




1384



—



5



15



Background

Hereditary gingival fibromatosis (HGF) is a rare condition characterized by slowly progressive overgrowth of the gingiva in the maxilla and mandible. It can present as an isolated condition or a part of various syndromes. The excess gingival tissue can cover part or the entire crown of the tooth, and can result in diastemas, teeth displacement or retention of primary or permanent teeth. It may also cause masticatory, phonetic, psychological, and esthetic issues [1,2]. The condition can also result in pseudo-pocketing and periodontal problems due to difficulties with maintaining an appropriate oral hygiene [3]. Routine treatment of minimal and local gingival overgrowth relies on maintaining proper oral hygiene and/or root scaling, while cases of advanced, diffuse gingival enlargement require extensive surgical intervention. Recurrence can appear several months to several years after surgery [2–8].

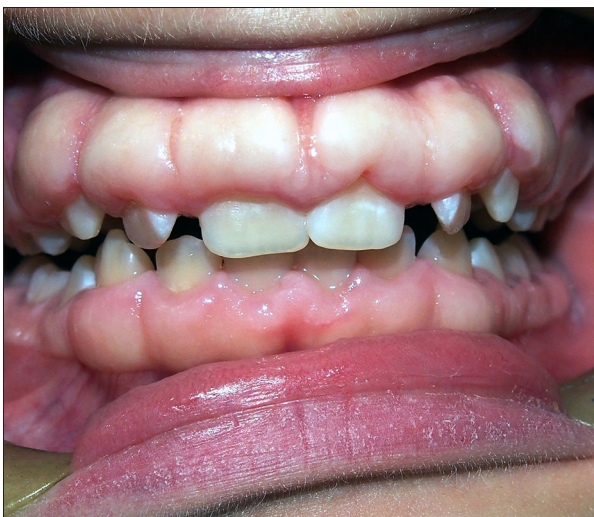

Figure 1. Clinical appearance of diffuse, hereditary gingival fibromatosis in an 11-year-old female (before surgery).

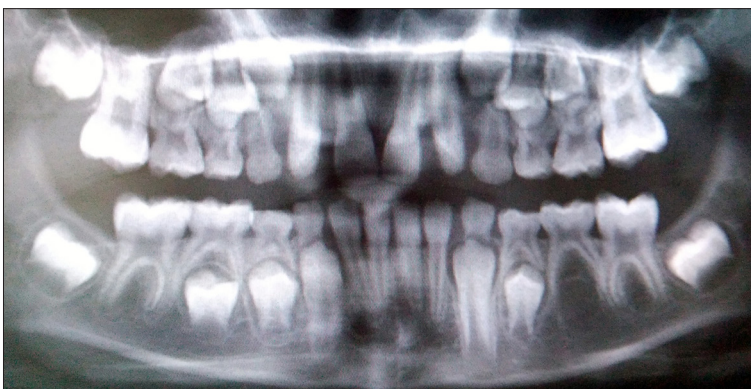

Figure 2. Panoramic radiograph in an 11-year-old female diagnosed with diffuse, hereditary gingival fibromatosis: twelve permanent teeth (i.e., 16, 12, 11, 21, 22, 26, 36, 32, 31, 41, 42, 46), and twelve deciduous teeth (i.e., 53, 54, 55, 63, 64, 65, 75, 74, 73, 83, 84, 85) in normal position, fifteen unerupted (permanent) teeth (i.e., 17, 15, 14, 13, 23, 24, 25, 27, 37, 34, 33, 43, 44, 45, 47) and normal alveolar bone height are visible. Tooth 12 and 22 are present in regular position, but slightly rotated, tooth 35 is invisible.

We report the management of an 11-year-old female case with diffuse HGF and present the histological analysis of gingival lesion with an emphasis on the content of fibrotic fibrils.

Case Report

This study was carried out in accordance with the Helsinki Declaration and the written consent was obtained prior to the study from patient's mother, as approved by the Bioethical Committee of the Jagiellonian University, Medical College in Krakow.

An 11-year-old Caucasian female presented for evaluation of a gingival lesion that impeded oral hygiene, caused masticatory problems and bleeding while brushing her teeth. Intraoral clinical examination revealed a painless, firm, and pale pink tissue covering 30% of her teeth crowns in the maxilla and mandible (Figure 1). Panoramic radiograph showed normal positioning of her twelve permanent teeth (i.e., 16, 12, 11, 21, 22, 26, 36, 32, 31, 41, 42, 46) and twelve deciduous teeth (i.e., 53, 54, 55, 63, 64, 65, 75, 74, 73, 83, 84, 85) that were also visible during intraoral examination. X-ray also showed fifteen unerupted (permanent) teeth (i.e., 17, 15, 14, 13, 23, 24, 25, 27, 37, 34, 33, 43, 44, 45, 47) and normal alveolar bone height. Tooth 12 and 22 were present in regular position, however, slightly rotated, while tooth 35 was imperceptible (Figure 2). The patient did not use any medications. A similar condition was present in three other family members; for example the patient's mother reported gingival overgrowth first at the time of deciduous dentition and then during eruption of permanent teeth. The results of patient's physical examination, medical history, laboratory tests, and histopathological evaluation of tissue sections excluded any genetic disease/syndrome or neoplastic growth. The patient was diagnosed with HGF.

Surgery was performed at the age of 11 years because of functional, hygienic, and psychological reasons. The patient also required orthodontic treatment. After proper oral hygiene was

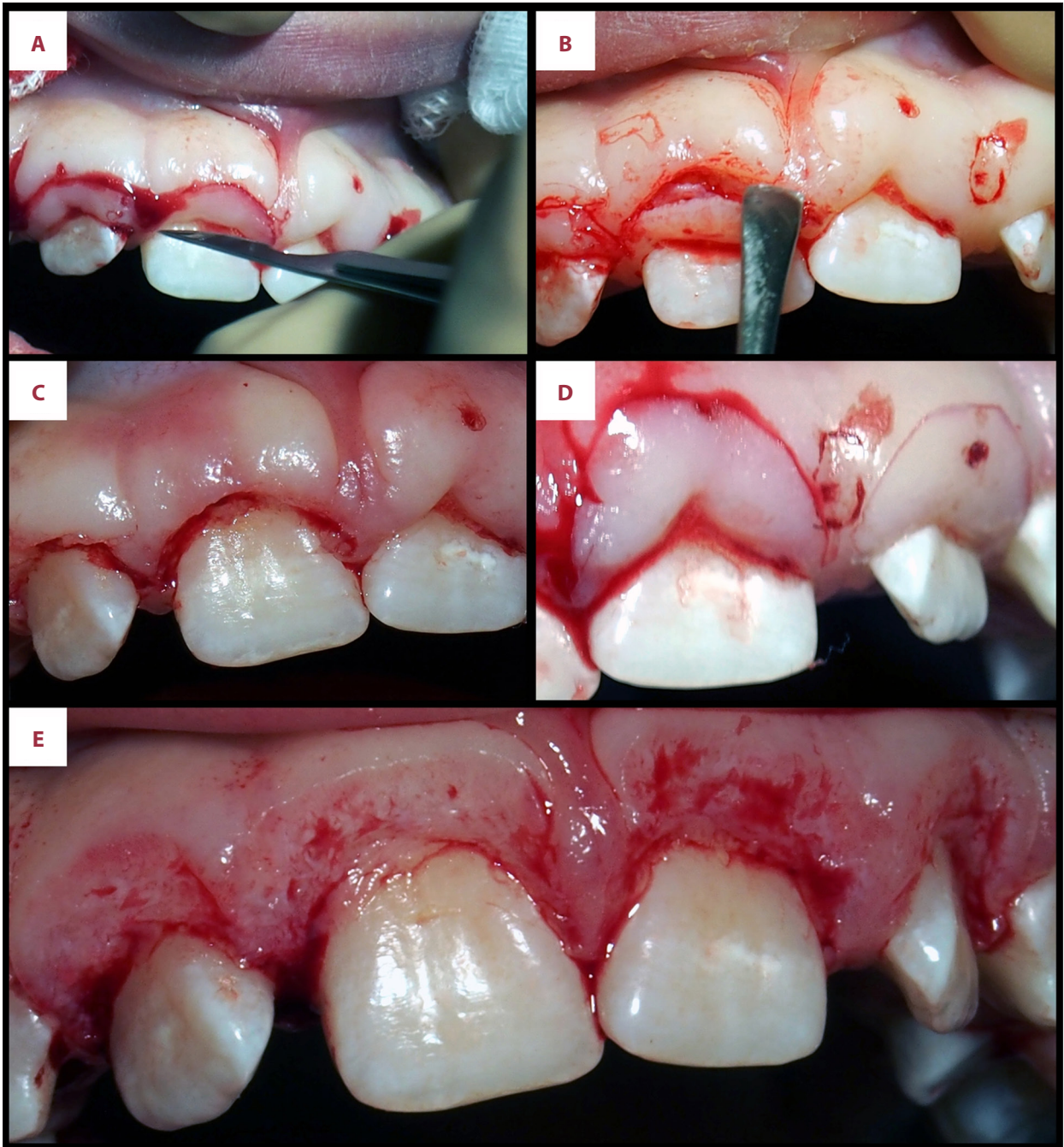


Figure 3. Gingivectomy and gingivoplasty procedure of the maxilla in an 11-year-old female with diffuse, hereditary gingival fibromatosis: continuous bevel incision carried out with the use of scalpel at the 45° angle to the long axis of the teeth 11 and 12, (A); the resected tissue around teeth 11 and 12 removed with the raspator, (B); exposed crowns of the teeth 11 and 12 visible after gingivectomy, (C); continuous bevel incision visible in the area of the teeth 21 and 22, (D); exposed crowns of the teeth 11, 12, 21, and 22 with restored contour of the gingival tissue after gingivoplasty carried out by scalpel type 15C and diamond bur, (E).

established, the patient underwent standard surgical procedures to remove excess gingival tissue. Under local anesthesia with articaine plus adrenalin (1:200,000, Septanest, Septodont, Poland) the excess of gingival tissue was removed by external

bevel gingivectomy, first in the mandible and then after two weeks in the maxilla. Along with gingivectomy, gingivoplasty was conducted to restore the labial contour of the gingiva (Figure 3 depicts the intra-operative procedure of the maxillary

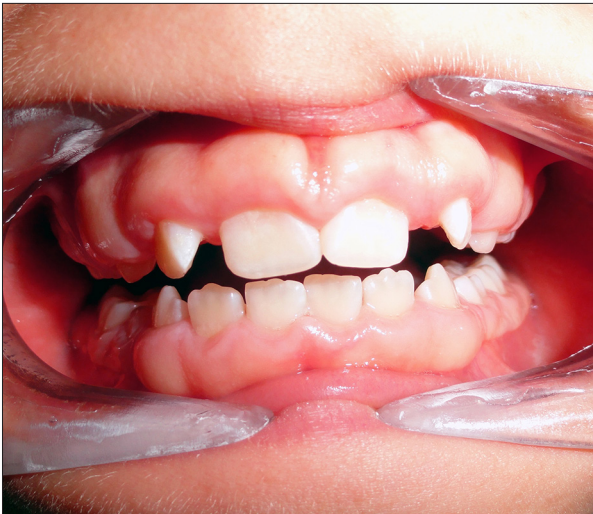

Figure 4. Diffuse, hereditary gingival fibromatosis in an 11-year-old female four weeks post-surgery in the mandible and two weeks after operation carried out in the maxilla: the recurrence within the mandible comprised approximately 45% of the pre-operative tissue volume, and in the maxilla – 25% of initial volume.

part surrounding teeth 11, 12, 21, and 22). A periodontal dressing (Septo-pack, Septodont, Poland) was applied, post-operative instructions were given, and chlorhexidine rinses were prescribed. Two weeks, one month, and three months after first surgery, the patient was re-called for control visits, when post-operative oral hygiene instructions were reinforced. The healing was uneventful, however, four weeks after surgery in the mandible, and two weeks after excision in the maxilla, the recurrence of overgrowth was seen in both dental arches. The recurrence within the mandible comprised approximately 45% of the pre-operative tissue volume, whereas in the maxilla, the tissue overgrowth attained 25% of the initial volume (Figure 4). At three months follow-up, any significant,

additional growth in the mandible was noted, while in the maxilla, the recurrence comprised 40% of the initial, pre-operative volume. On palpation, the regrown gingiva was more dense, firmer, and less elastic with a rougher surface compared to that at pre-operative status. Despite the unusually rapid rate of recurrence within the first four weeks after surgery, a gradual decrease of the recurrence ratio was observed in the following two months. The patient did not complain about bleeding and problems with hygiene or chewing and was satisfied with the improvement of aesthetics. She was under outpatient care with control visits once every three months. Further surgical intervention was not planned as long as her periodontal health and function would not be affected by the excessive mass of gingival tissue.

Histopathological evaluation of gingival biopsies revealed thickened epithelium with elongated rete ridges extending locally into connective tissue. Abundant fibroblasts were accompanied by numerous bundles of collagen fibrils and moderate blood vessels throughout subepithelial and dense connective tissue (Figure 5A). The examination of gingival biopsies by polarized light microscopy showed a significant increase of thin, green-birefringence fibrils i.e., corresponding to fibrotic fibrils that contributed 80% of the total pool of collagen fibrils (Figure 5B). In contrast, in healthy gingiva thin fibrils constituted only about 25% of the total pool (Figure 5C).

Discussion

HGF is a condition characterized by etiological heterogeneity [3,5]. The diagnosis is dependent on a thorough history, clinical examination, panoramic radiographs, histopathology, and laboratory tests. Differential diagnosis is needed to exclude co-existence of genetic diseases and syndromes, infections, thrombotic thrombocytopenic purpura, amyloidosis, systemic

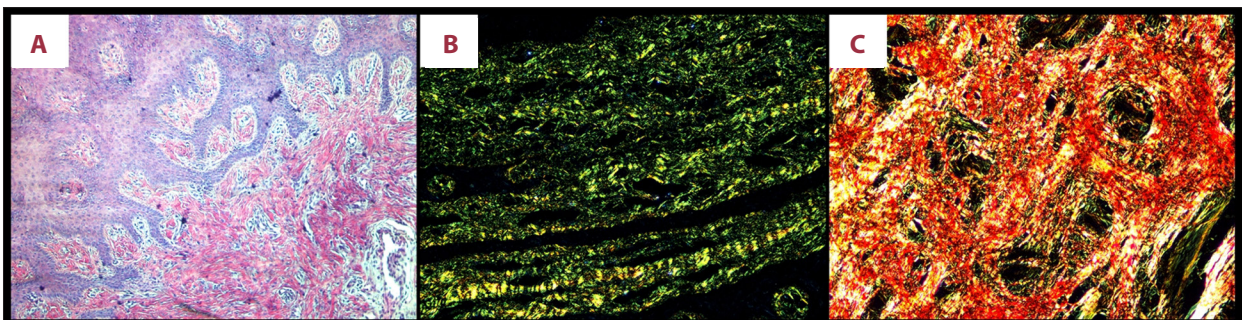


Figure 5. Histopathological evaluation of the gingival biopsy obtained from 11-year-old female with diffuse, hereditary gingival fibromatosis: hematoxylin and eosin staining shows thickened epithelium with locally elongated rete ridges, abundant fibroblasts and moderate blood vessels in subepithelial and dense connective tissue, original magnification 100×, (A); the analyzes of percentages of differently colored collagen fibrils evaluated in picosirius red stained sections of patient lesion (B), and control gingiva (C) by a polarized microscopy (Eclipse, LV100POL, Nikon Inc.) and the NIS Elements software (Nikon Inc.), original magnification 200×.

hormonal stimulation, blood dyscrasias, and tumors [2,3]. Standard treatment consists of surgical excision of the lesion by means of scalpel, cautery, or laser after the establishment of a proper oral hygiene.

Clinical features of this condition, including the rate of recurrence, may differ among families as well as between the members of the same family, however, the reasons for such variations are currently unknown. The family of our patient presents an example, where a recurrence was noted a year after surgery in the patient's mother [5], whereas no recurrence was present in patient's sister. In other reported cases, recurrence was not observed, while in some cases, disease relapse occurred from several months to several years after treatment. Kavvadia et al. (2005) reported a case of an 11-year-old male with diffuse idiopathic gingival fibromatosis and the absence of eruption of permanent teeth. Thirty months after surgery, permanent dentition had still not erupted, but recurrence of the overgrowth was not seen [9]. Kelekis-Cholakis et al. (2002) presented a case of management of a 13-year-old female with progressive HGF. Initial treatment consisted of four-quadrant gingivectomy with reverse bevel incisions, followed by orthodontic treatment. Three years later, complete recurrence was noted. Another full-mouth gingivectomy did not reveal any signs of recurrence a year later [10].

Linkage analysis of HGF patients revealed several chromosomal regions that may contain mutations responsible for isolated, non-syndromic autosomal dominant forms of HGF. The candidate loci, i.e., *GINGF*, *GINGF2*, and *GINGF4*, have been localized to chromosome 2p21-p22 [11], 5q13-q22 [12] and 11p15 [13], respectively. Moreover, after sequencing about 16 genes in the candidate interval (2p21-p22), a single base insertion in the Son-of-Sevenless-1 (*SOS-1*) gene (MIM 182530)

underlying *GINGF* locus was detected in a Brazilian family [14]. This mutation has been suggested as one possible etiological factor for isolated, non-syndromic HGF. Considering the genetic background and heterogeneity of HGF, we postulate that the variable rate of recurrence of this condition may be associated with the presence of some mutations, but this hypothesis needs further investigation.

Histological analyses of gingival tissue from reported case with HGF, stained by picosirius red, showed a significant increase of thin, green-birefringent fibrils that correspond to the fibrotic fibrils. This indicates a persistent fibrotic process that has been reported to underline pathological changes seen in numerous fibrotic diseases and conditions, including phenytoin-induced gingival overgrowth (PIGO) [15], but has not been reported yet in cases of HGF. Considering two other members of family diagnosed with HGF, much less fibrotic appearance and lower proliferation rates of gingival fibroblasts have been noted, as compared to the patient case presented (unpublished data).

Conclusions

It is currently not clear whether the extent of the fibrotic process had a mechanistic association with the ratio of gingival tissue re-growth in our case study. Further studies of larger groups of patients with fibrotic HGF with a high rate of recurrence are needed to explain this association and possibly improve the management of this condition.

Competing interests

The authors declare that they have no competing interests.

References:

1. Millet C, Rodier P, Farges JC et al: Surgical and prosthetic treatment in an elderly patient affected by unilateral idiopathic gingival fibromatosis: A case report. *Gerodontology*, 2012; 29: e1185-89
2. Gawron K, Łazarz-Bartyzel K, Potempa J, Chomyszyn-Gajewska M: Gingival fibromatosis: clinical, molecular and therapeutic issues. *Orphanet J Rare Dis*, 2016; 11: 9
3. Häkkinen L, Csiszar A: Hereditary gingival fibromatosis: Characteristics and novel putative pathogenic mechanisms. *Dent Res*, 2007; 86: 25-34
4. Baptista IP: Hereditary gingival fibromatosis: A case report. *J Clin Periodontol*, 2002; 29: 871-74
5. Gawron K, Łazarz-Bartyzel K, Łazarz M et al: *In vitro* testing the potential of a novel chimeric IgG variant for inhibiting collagen fibrils formation in recurrent hereditary gingival fibromatosis: chimeric antibody in a gingival model. *J Physiol Pharmacol*, 2014; 65: 585-91
6. Zhou M, Xu L, Meng HX: Diagnosis and treatment of a hereditary gingival fibromatosis case. *Chin J Dent Res*, 2011; 14: 155-58
7. Jadhav AS, Marathe SP: Recurrent idiopathic gingival fibromatosis with generalized aggressive periodontitis: A rare case report. *J Indian Soc Periodontol*, 2015; 19: 93-95
8. Tripathi AK, Dete G, Saimbi CS, Kumar V: Management of hereditary gingival fibromatosis: A 2 years follow-up case report. *J Indian Soc Periodontol*, 2015; 19: 342-44
9. Kavvadia K, Pepelassi E, Alexandridis C et al: Gingival fibromatosis and significant tooth eruption delay in an 11-year-old male: A 30-month follow-up. *Int J Paediatr Dent*, 2005; 15: 294-302
10. Kelekis-Cholakis A, Wiltshire WA, Birek C: Treatment and long-term follow-up of a patient with hereditary gingival fibromatosis: A case report. *J Can Dent Assoc*, 2002; 68: 290-94
11. Hart TC, Pallos D, Bowden DW et al: Genetic linkage of hereditary gingival fibromatosis to chromosome 2p21. *Am J Hum Genet*, 1998; 62: 876-83
12. Xiao S, Bu L, Zhu L et al: A new locus for hereditary gingival fibromatosis (*GINGF2*) maps to 5q13-q22. *Genomics*, 2001; 74: 180-85
13. Zhu Y, Zhang W, Huo Z et al: A novel locus for maternally inherited human gingival fibromatosis at chromosome 11p15. *Hum Genet*, 2007; 121: 113-23
14. Hart TC, Zhang Y, Gorry MC et al: A mutation in the *SOS1* gene causes hereditary gingival fibromatosis type 1. *Am J Hum Genet*, 2002; 70: 943-54
15. Kantarci A, Black SA, Xydias CE et al: Epithelial and connective tissue cell CTGF/CCN2 expression in gingival fibrosis. *J Pathol*, 2006; 210: 59-66