

# Inoperable Sacral Giant Cell Tumor: Therapeutic Options and Pain Control\*

## *Tumor de células gigantes do sacro inoperável: opções terapêuticas e controle da dor*

Eneida de Mattos Brito Oliveira Viana<sup>1</sup> Katia Torres Batista<sup>1</sup>  José Leite Carneiro Junior<sup>1</sup>

<sup>1</sup> Rede Sarah de Hospitais de Reabilitação, Brasília, DF, Brazil

Rev Bras Ortop 2019;54:347–352.

Address for correspondence Katia Torres Batista, Rede Sarah de Hospitais de Reabilitação, SMHS Qd 301 Bloco A, Brasília, DF, CEP: 70335-901, Brasil (e-mail: katiatb@terra.com.br; 203911@sarah.br).

### Abstract

#### Keywords

- ▶ giant cell tumors
- ▶ orthopedics
- ▶ chronic pain

### Resumo

#### Palavras-chave

- ▶ tumores de células gigantes
- ▶ ortopedia
- ▶ dor crônica


Sacral giant cell tumor (GCT) is a rare condition. Its treatment is complex, since surgical removal is difficult and the response to other therapeutic options is low. The control of its growth and pain is an additional challenge. The present paper reports a case of inoperable sacral GCT, with embolization and radiotherapy for pain control as therapeutic options. The patient, a 39-year-old male, presented pain in the sacral region with lower limb irradiation due to an inoperable sacral giant cell tumor. The patient was submitted to embolization, radiotherapy, pain management with opioids and other drugs, and a rehabilitation program. Despite the difficulty in tumor growth and pain control during the follow-up, the outcome is stable after 9 years.

O tumor de células gigantes do sacro é raro e seu tratamento complexo, devido à dificuldade para exeresse cirúrgica e à baixa resposta às outras opções terapêuticas. Entre os desafios relacionados a este tumor está o controle do seu crescimento e da dor. No presente artigo, relatamos um caso de tumor de células gigantes do sacro inoperável, apresentando as opções terapêuticas de embolização e de radioterapia para o controle da dor. Trata-se de um paciente do sexo masculino, admitido aos 39 anos, apresentando dor na região sacral com irradiação para os membros inferiores, com diagnóstico de tumor de células gigantes sacral inoperável. Realizou-se embolização, uso de interferon, radioterapia, tratamento da dor com opioides e medicamentos adjuvantes, associado a programa de reabilitação. Descreveu-se o difícil controle do crescimento tumoral e da dor ao longo do seguimento, com desfecho estável após 9 anos.

### Introduction

Giant cell tumors (GCTs) are rare, accounting for between 8 and 10% of the benign primary bone tumors. Their prevalence is higher after skeletal maturity (3<sup>rd</sup> and 4<sup>th</sup> decades of life), with a low predilection for women. These tumors affect mainly the long bones and, less frequently, the vertebrae, the pelvis, and the sacrum. They may be associated with

\* Work performed at Rede Sarah de Hospitais de Reabilitação, Brasília, DF, Brazil, and presented at the Instituto de Ensino e Pesquisa from the Hospital Sírio Libanês to obtain the certification as a specialist in the care of patients with pain.

 Katia Torres Batista's ORCID is <https://orcid.org/0000-0003-1300-4281>.

pseudotumoral conditions, malignancy, metastases (10%), mainly to the lung, and local recurrence. The main symptom is pain (54.4%).<sup>1-3</sup>

The treatment of GCTs is surgical, by complete tumor excision and defect filling with bone graft, polymethylmethacrylate, or endoprosthesis. Amputations are rarely indicated, since this is a benign tumor.<sup>1</sup> The greatest challenge lies in cases located at the dorsal and sacral spine, with extensive destruction and restricted surgical options. For sacral GCTs, curettage with cementation is the best option. Sacrectomy worsens the quality of life due to sphincter incontinence and anesthesia of the perineal region.<sup>1</sup>

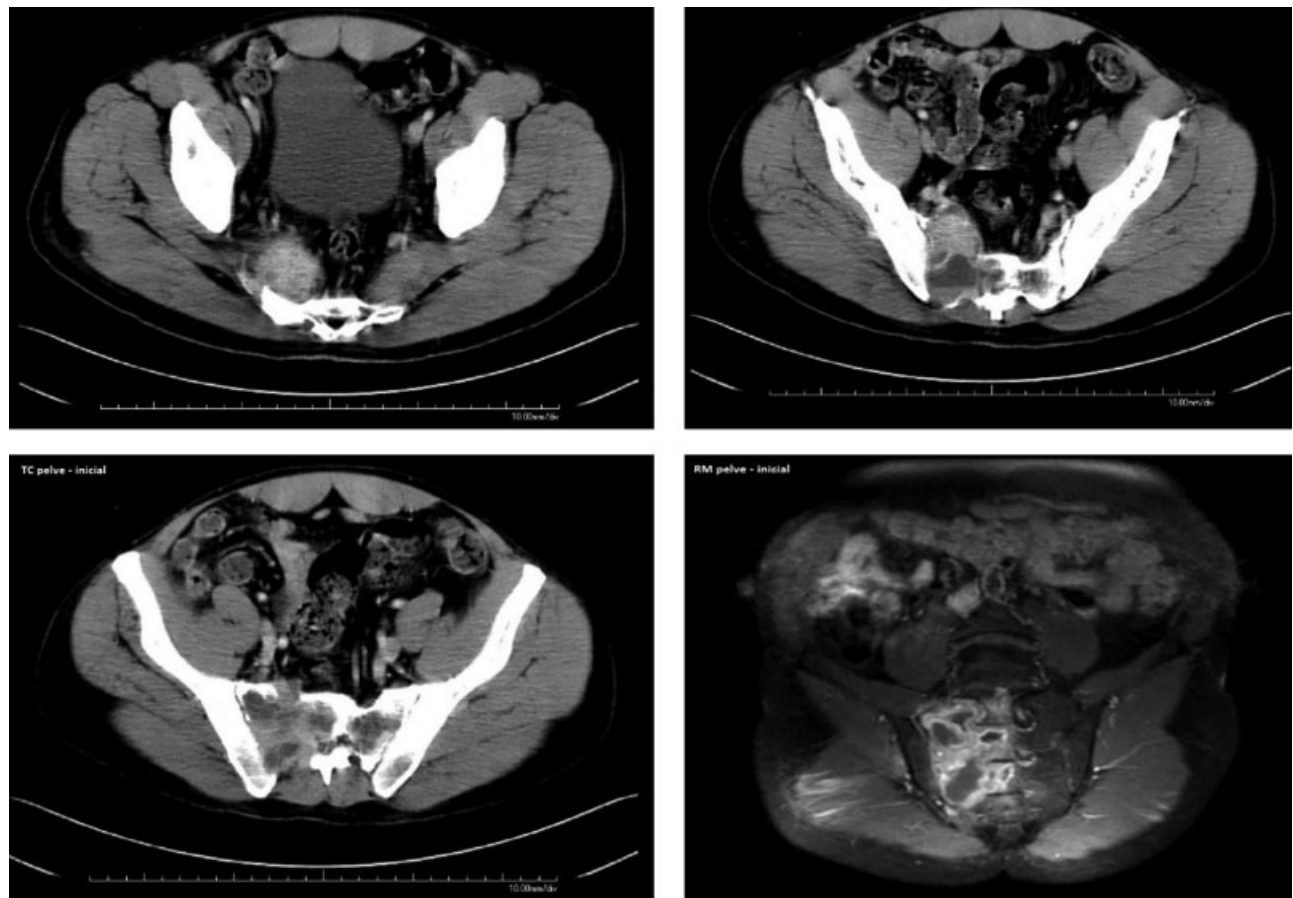
Radiographic studies show a lytic, solitary, inflated, eccentric lesion with cortical thinning or erosion.<sup>2</sup> Pain and local swelling are the most frequent complaints, being caused by local and distant bone infiltration. Opioids are the most effective drugs for moderate and severe pain control, but their use in complex cases requires dose and administration route management, in addition to combination with other treatments.<sup>4</sup>

The present paper describes the therapeutic options and pain control in a complex case of inoperable sacral GCT.

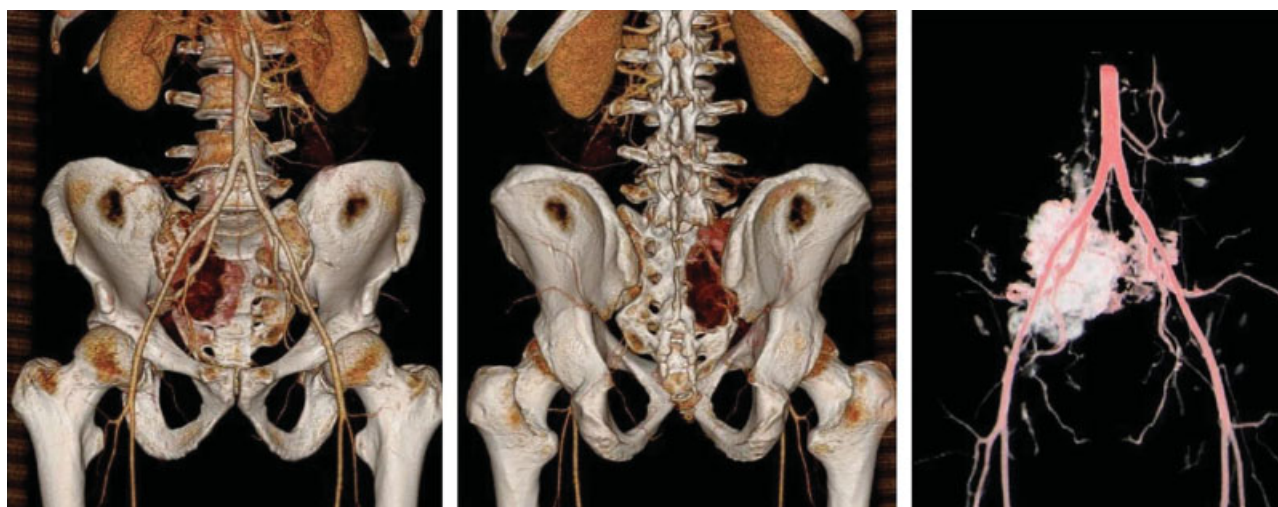
## Case Report

Male, 39-year-old patient hospitalized with intense pain in the sacral region, irradiating to the right lower limb for 3 months. He had sought care in emergency departments, without diagnosis or improvement of the symptoms. A nuclear magnetic resonance imaging (NMRI) and a computed tomography (CT) scan of the lumbar spine revealed an expansive, inflated, osteolytic sacral lesion, measuring  $8.3 \times 5.8 \times 4.8$  cm, with areas of cortical rupture and an extraosseous component, affecting the central and right lateral portions of the sacrum, from S1 to S4, including the sacral foramina, extending to the sacral vertebral canal, and with a small cortical involvement of the right iliac bone (**►Fig. 1**). Moreover, the center of the lesion had a cystic appearance with liquid levels.

The involvement of the sacral roots and the apparent infiltration of the piriformis muscle was also noted, with edema of the medial and maximal gluteal muscles. Despite the close contact between the lesion and the sciatic nerve, the iliac vessels, and the upper and lower gluteal vessels, there were no signs of circumferential involvement of these



**Fig. 1** Nuclear magnetic resonance imaging showing an osteolytic lesion, measuring  $8.3 \times 5.8 \times 4.8$  cm, with areas of cortical rupture and an extraosseous component, affecting the central and right lateral portions of the sacrum (from S1 to S4), the sacral foramina, the sacral vertebral canal, and the sacroiliac joint; in addition, there is a small cortical involvement of the right iliac bone. The center of the lesion has a cystic appearance with liquid levels. The involvement of the sacral roots and the apparent infiltration of the piriformis muscle was also noted, with edema of the medial and maximal gluteal muscles. The lesion abuts the sciatic nerve, the iliac vessels, and the upper and lower gluteal vessels; there is also a bilateral L4 spondylolysis associated with a grade 2 anterolisthesis of L4 on L5, resulting in neural foramina stenosis at this level.



**Fig. 2** Tumor embolization with gel foam and spheres through selective catheterization of the middle sacral, L5 radicular, superior gluteal, and internal iliac right arteries, and irrigation through the left lateral sacral artery.

structures. The scan also revealed a bilateral L4 spondylolysis associated with a grade 2 anterolisthesis of L4 on L5, with neural foramina stenosis at this level. The lesion was classified as grade III. On the physical examination, the patient had a gait, a mild bulging at the right lumbosacral region, altered dermatome sensitivity (from L2 to S2), and preserved muscle strength.

The sacral lesion was biopsied, revealing a giant cell tumor histologically characterized by multinucleated giant cells dispersed at the tumor tissue and an aneurysmal bone cyst, evidenced by a hypervascularized, expansive, osteolytic lesion consisting of blood, connective tissue bars, and giant cell trabeculae. The location and extension of the tumor rendered it inoperable. Two intra-arterial embolization procedures (►Fig. 2) were performed, but the pain intensified. Pain control was initially attempted with opioids (morphine) in doses ranging from 5 mg to 200 mg every 4 hours, fentanyl, methadone, gabapentin for neuropathic pain management, and tricyclic antidepressants (amitriptyline), anti-inflammatory agents, and analgesics. Interferon alpha 2A (1.1 MU/m<sup>2</sup>, up to 4.4 MU/m<sup>2</sup>) was used as antiangiogenic therapy for 7 months. Due to pain worsening at deambulation, an intrathecal catheter was placed at L3/L4 with a fentanyl infusion pump. Despite pain improvement, there were frequent flares due to L4–L5 spondylolysis with grade I listhesis and neural foramen stenosis evidenced by hypoaesthesia in L5–S1, patellar and deep tendinous reflexes abolishment, positive Lasègue sign, and total loss of right ankle movements. An electroneuromyography evidenced the presence of a lesion at the right sciatic nerve. A pelvic and lumbosacral spine tomography showed tumor growth and involvement of adjacent nerve structures.

Two radicular blocks in L4/L5 (►Fig. 3) were performed using bupivacaine and methylprednisolone. Due to interferon treatment failure and pain persistence, at the 11<sup>th</sup> month, the patient was referred to radiotherapy with a 4,500 cGy dose, which resulted in partial pain and tumor control. From the 11<sup>th</sup> month to the 28<sup>th</sup> month, the patient needed

assistance in daily life activities (DLAs); he had proper sphincter control, but erectile dysfunction. In addition, the patient presented dysautonomia, which was controlled with phosphodiesterase inhibitors. The patient was referred to hydrotherapy and physical therapy, resulting in pain and mood improvement. A control CT scan showed minimal reduction of the sacral lesion.

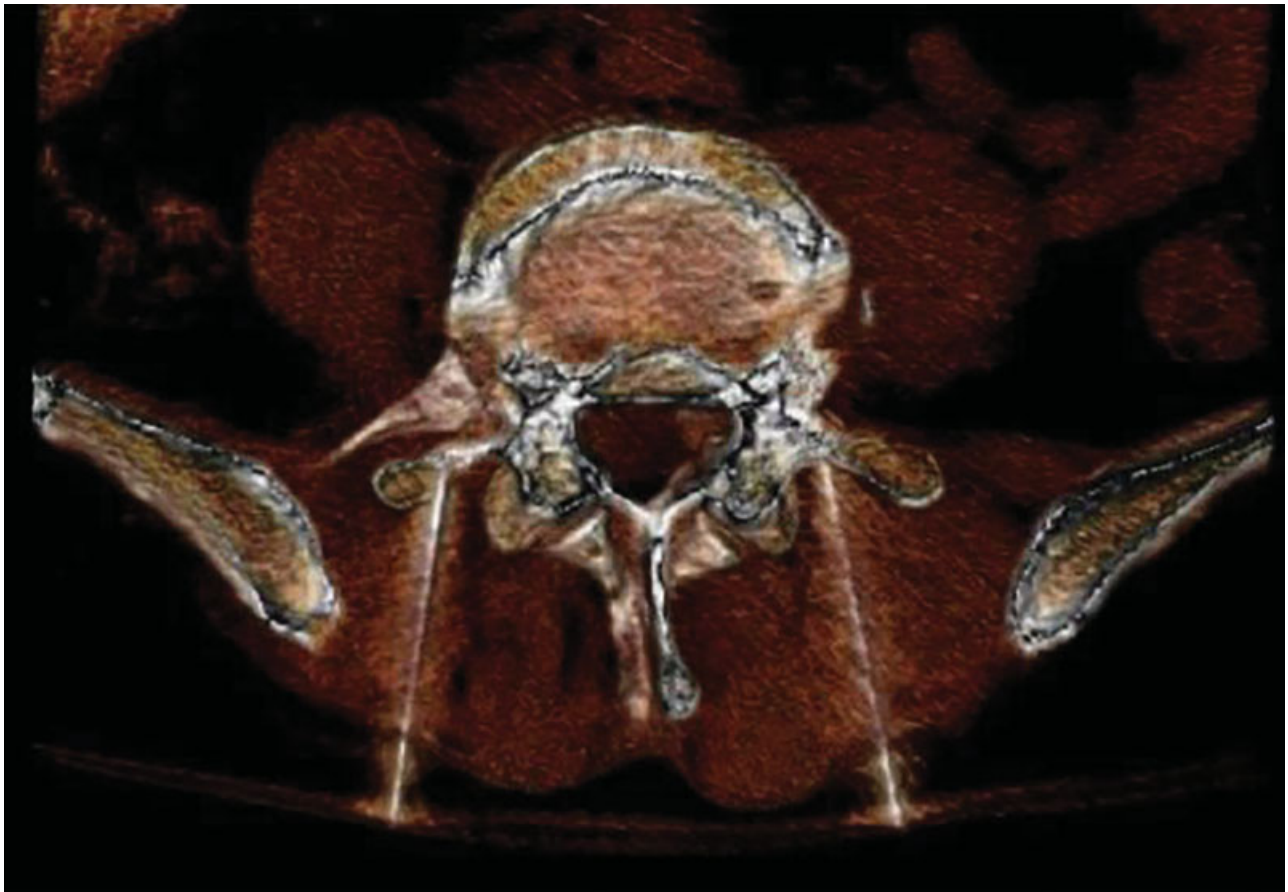At the 29<sup>th</sup> month, the pain relapsed despite the absence of triggering factors; medications were readjusted, according to ►Table 1, which lead to pain control. At the 35<sup>th</sup> month, the patient was able to walk with no assistance and presented tactile and painful hypoaesthesia, in addition to foot drop (treated with an ankle-foot orthosis). The patient was followed-up annually, with progressive reduction and adjustments of analgesic medication and patient-controlled analgesia (PCA) pump removed at the 91<sup>st</sup> month. At the 9<sup>th</sup> year (96<sup>th</sup> month), the patient still had a large, stable sacral tumor (►Fig. 4), but with no specific oncologic treatment, no pain or any analgesic medication. He resumed his DLAs and returned to work.

The present research project was reviewed and approved by the Comitê de ética em pesquisa/Associação das Pioneiras Sociais (CEP/APS).

## Discussion

Although GCT is a benign tumor, it can have an aggressive behavior and be inoperable. The greatest challenge, as demonstrated in the present case report, is the sacral location with extensive destruction, in which the surgical options are restricted, and the association with an aneurysmal cyst, causing progressive increase of the lesion and radicular and spinal compression, resulting in pain, weakness, and limb sensory disturbances. The aneurysmal cyst described in the histopathological and imaging examination of the present case may be associated with GCT; however, it would not change the surgical treatment, which would include, if possible, marginal resection in monobloc. Nevertheless,





**Fig. 3** Bilateral L4/L5 periradicular block with bupivacaine and methylprednisolone. Pre- and postembolization pain scores were 8/10 and 0/10, respectively.

according to our experience and to other authors, surgical treatment by excision with a wide margin or limit, involving upper sacral segments and the midline, would encompass a total sacrectomy. This procedure, in addition to the risks of massive hemorrhage, of infection, of neurological deficit, and of local recurrence, may cause sphincter disorders, pelvic and spinal instability, and may result in a significant worsening of the quality of life.<sup>1</sup> Embolization was indicated for this patient as an attempt to reduce the tumor size and the pain; moreover, it is described only for inoperable tumors. In the present case, two embolization procedures were performed, but the tumor size was not reduced, and the pain was exacerbated, maintaining the inoperability conditions. The embolization results could be effective, but temporary, including for pain, due to vessel recanalization and tumor growth.<sup>2,3</sup>

Chemotherapy was abandoned as a therapeutic option due to the benign behavior of the tumor and to the possible side-effects. In view of the poor response to embolization and the worsening of the pain, therapy with interferon alfa 2A, an antibody that blocks the osteoclastic action, was instituted; although this treatment was shown to be effective in reducing the size of these tumors for some time, it was unsuccessful in this case after 7 months of use.<sup>5</sup> Another treatment option described for unresectable bone tumors is radiotherapy. Radiotherapy at a 4,500 cGy dose at the

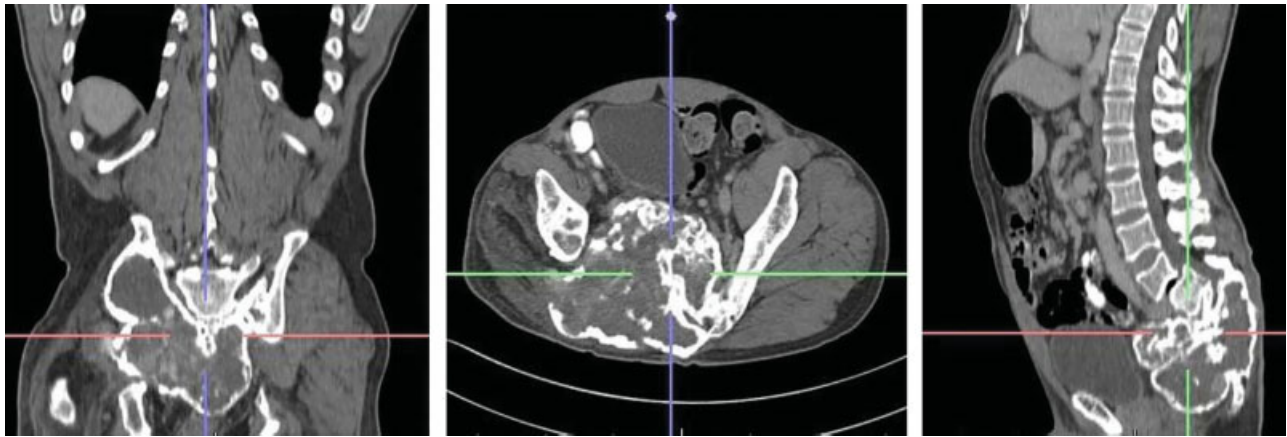
tumoral bed was started and resulted in a slight reduction of the tumor size. Its application in GCTs is controversial, since these are benign neoplasias with minor cellular atypia and risk of sarcomatous degeneration. It is indicated for advanced lesions, with massive bone destruction, multiple recurrences, secondary infections, and malignant degeneration in the vertebral spine or sacrum; as such, it was applied in this difficult case.<sup>6</sup>

Opioids, analgesics, anesthetics, and corticosteroids were used for pain control through bone infiltration, maintenance dose, or bolus during flares. These medications were used in the present case from admission to the 91<sup>st</sup> month, with dose adjustments according to flares, and included analgesic agents (paracetamol, acetaminophen), anti-inflammatory agents (tenoxicam, naproxen), tricyclic antidepressants, anticonvulsants, and muscle relaxants, in addition to drugs for side-effects control. Other options, although not present, such as bisphosphonates, may improve tumor hypercalcemia, with analgesic effect on bone pain secondary to remodeling, denosumab,<sup>7</sup> and antibody with monoclonal antibody protein, which interfere with the action of the other protein involved in the process of bone degradation, which is a determinant of the reduction in the number and function of osteoclasts (cells present in bones and those responsible for the degradation of bone), resulting in decreased bone resorption and bone destruction, commonly induced by

**Table 1** Monthly treatment and complications evolution

Month	Complication	Treatment
1 <sup>st</sup> month, admission Intra-arterial embolization in the tumoral territory irrigated by the left lateral sacral artery	Pain Pain intensified (score 10/10)	Morphine, 10 mg every 6 hours Amitriptyline, 50 mg/day Replacement with transdermal fentanyl (200 mcg) and gabapentin (1,200 mg/day)
3 <sup>rd</sup> month, unchanged tumoral volume Tumoral embolization Interferon alfa 2A (1.1MU/m <sup>2</sup> )	Pain flare-up	Gabapentin, 600 mg every 8 hours Transdermal fentanyl (200 µcg), Tenoxicam, 20 mg/day Paracetamol, 750 mg every 6 hours Amitriptyline, 75 mg/day
4 <sup>th</sup> month	Pain when walking. Difficulty in using transdermal fentanyl patches due to profuse sweating.	Intrathecal catheter placement with fentanyl PCA pump (5 µcg; blocking interval: 30 minutes; continuous infusion: 0.5 µcg/h; total continuous dose: 12 µcg/day)
5 <sup>th</sup> month, interferon alfa 2A (2.2MU/m <sup>2</sup> )	Fentanyl withdrawal syndrome Stabbing pain throughout the lower right limb due to L4 spondylolysis, grade I L4-L5 listhesis and neural foramen stenosis.	Synchromed II intrathecal pump placement, approximately at L3/L4 level. Fentanyl infusion started at a continuous daily dose of 10 µcg. Intrathecal fentanyl dose was progressively adjusted; latter, fentanyl was replaced with morphine. Increased intrathecal drug infusion, with tramadol addition and morphine maintenance for salvage therapy. Bilateral L4/L5 periradicular block with bupivacaine and methylprednisolone. Second bilateral L4/L5 periradicular block with bupivacaine and methylprednisolone.
10 <sup>th</sup> month, tumoral growth Interferon alfa 2A (4.4MU/m <sup>2</sup> )	Severe pain and burning sensation from the buttock to the posterior region of the lower right limb; profuse sweating, weight loss, moaning and pressure sore at the ulnar region due to load support.	Amitriptyline, 75 mg/day Gabapentin, 2,400 mg/day; intrathecal morphine, 2.5 mg/day; Bupivacaine, 1.25 mg/day (Pain score went from 9/10 to 4/10).
11 <sup>th</sup> month, Radiotherapy – 4,500 cGy at the tumoral bed	Severe burning sensation at the left plantar area, unable to touch the floor with the foot. Catheter in the subarachnoid space.	Clonidine, 42 µcg/day; intrathecal morphine solution; Gabapentin, 2,700 mg/day. The catheter was replaced; it was intact, but it rolled under the pump.
12 <sup>th</sup> to 14 <sup>th</sup> month – hydrotherapy and physical therapy	The patient is unstable and requiring assistance in all daily life activities.	Morphine (3.5 mg/day); bupivacaine; amitriptyline, 125 mg/day; gabapentin, 2,400 mg/day; tizanidine, 6 mg/day; methadone, 15mg/day; and naproxen, 1 g/day.
29 <sup>th</sup> month – ankle-foot orthosis	Pain relapse	Increase intrathecal morphine dose to 2 mg/day; methadone, 5 mg every 12 hours; amitriptyline, 25 mg/night; naproxen, 250 mg every 12 hours.
87 <sup>th</sup> month	End of PCA pump working time	PCA pump replaced
91 <sup>st</sup> month	PCA pump exteriorization	Intrathecal injection system removal; continuous venous infusion of morphine, 4 mg/hour, and methadone, 10 mg every 8 hours, reduced to 5 mg every 8 hours for 1 year; gabapentin, 300 mg 12 hours, and amitriptyline, 25 mg/night.
96 <sup>th</sup> month, tumoral growth stabilization		With no specific oncologic treatment, no pain or any analgesic medication, the patient resumed his daily life activities and returned to work

Abbreviation: PCA, patient-controlled analgesia.



**Fig. 4** Nuclear magnetic resonance imaging demonstrating control of the extensive sacral tumor.

cancer, is indicated for the treatment of high blood levels of cancer from cancer following a failure of bisphosphonate treatment. At the time of the study the use was limited by cost and other factors.

It is worth noting that, in Brazil, it is estimated that between 62 and 90% of the patients with bone neoplasms have pain.<sup>8</sup> Its possible causes include bone, visceral, nervous system, and soft tissues invasion (46 to 92%), increased intracranial pressure (12 to 29%), muscle spasm, lymphedema, decubital lesions, intestinal constipation, and treatment-related pain (5 to 20%), which may result from surgery (acute pain, postamputation pain, phantom pain) or chemotherapy (mucositis, peripheral neuropathy, post-herpetic neuralgia, bladder spasms, femoral head necrosis, osteoarthritis, spondylarthritis, fibromyalgia, migraine, etc.), in addition to the pain associated with comorbidities (8 to 22%).

The present report highlights the difficulty in controlling the tumoral growth and the pain related to it. During bone-associated pain flare-ups, caused by tumor growth, bone invasion, neuropathic pain, immobility-associated radicular compression, and muscular spasm, opioids, potent analgesics, and adjuvant medications were administered through the oral route and with an intrathecal PCA pump.<sup>4,8</sup> Myofascial and postural components, muscle mass and conditioning reduction, contractures, sleep disturbances, anxiety and depression were also observed.<sup>9</sup> In addition, these patients are commonly affected by an immobilism syndrome, managed with physical therapy, hydrotherapy, and psychological counseling.

The present report described the evolution of an inoperable, difficult-to-control sacral giant cell tumor in a young adult patient, in which embolization, interferon therapy,

radiotherapy, use of opioids and adjuvant medications, psychological and physical therapeutic follow-up were addressed, highlighting the difficult pain control. Tumor growth stabilization and pain control was achieved after several procedures, during a 9-year follow-up.

#### Conflicts of interests

The authors have no conflicts of interests to declare.

#### References

- 1 Camargo OP, Croci AT, Oliveira CR, Baptista AM, Caiero MT, Giannotti MA. Tumor de células gigantes: evolução histórica do seu diagnóstico e tratamento junto ao Instituto de Ortopedia e Traumatologia da FMUSP. *Acta Ortop Bras* 2001;9(04):46–52
- 2 Catalan J, Fonte AC, Lusa JRB, Oliveira AD, Melo ES, Justino Júnior RO, et al. Tumor de células gigantes ósseo: aspectos clínicos e radiográficos de 115 casos. *Radiol Bras, São Paulo* 2006;39(02): 119–122
- 3 Ciftidemir M, Kaya M, Selcuk E, Yalniz E. Tumors of the spine. *World J Orthop* 2016;7(02):109–116
- 4 King T, Porreca F. Opioids in cancer pain: new considerations. *Pain Clin Updates IASP*. 2010;18(01):1–5
- 5 Yasko AW. Interferon therapy for giant cell tumor of bone. *Curr Opin Orthop* 2006;17:568–572
- 6 Formenti SC, Demaria S. Systemic effects of local radiotherapy. *Lancet Oncol* 2009;10(07):718–726
- 7 Branstetter DG, Nelson SD, Manivel JC, Blay JY, Chawla S, Thomas DM, et al. Denosumab induces tumor reduction and bone formation in patients with giant-cell tumor of bone. *Clin Cancer Res* 2012;18(16):4415–4424
- 8 Ferreira KAS, Kimura M, Teixeira MJ, Nobrega JC. Preditores de controle inadequado da dor entre pacientes com dor oncológica. In: 7º Congresso Brasileiro de Dor, Gramado, RS, Brazil; 2006
- 9 Junming M, Cheng Y, Dong C, Jianru X, Xinghai Y, Quan H, et al. Giant cell tumor of the cervical spine: a series of 22 cases and outcomes. *Spine* 2008;33(03):280–288