



Differential diagnosis of memory impairment in areas affected by a natural disaster : a case report

Akemi Miyagawa¹⁾²⁾, Yasuto Kunii³⁾⁴⁾, Daisuke Gotoh³⁾, Masashi Ito³⁾, Shuntaro Itagaki³⁾,
Takatomo Matsumoto³⁾, Tetsuo Kumakura²⁾ and Hirooki Yabe³⁾

¹⁾Department of Disaster and Comprehensive Medicine, Fukushima Medical University, Fukushima City, Fukushima, Japan, ²⁾Hibarigaoka Hospital, Minamisoma City, Fukushima, Japan, ³⁾Department of Neuropsychiatry, School of Medicine, Fukushima Medical University, Fukushima City, Fukushima, Japan, ⁴⁾Department of Disaster Psychiatry, International Research Institute of Disaster Science, Tohoku University, Sendai City, Miyagi, Japan

(Received June 25, 2020, accepted February 16, 2021)

Abstract

We treated a man with a chief complaint of memory impairment after the Great East Japan Earthquake. Initially, he was diagnosed with dementia. However, after several tests, neither could a definitive diagnosis of dementia be reached, nor was there any apparent evidence for depression, epilepsy, delirium, or internal medicine diseases. During the earthquake, the patient experienced the severe trauma of watching his wife being swept away by a tsunami. Furthermore, he experienced separation from his family. Because of this traumatic experience, we suspected that dissociative disorder was involved in the development of the memory impairment and thus, we switched to treatments focusing on emotional support. Subsequently, the patient's memory impairment gradually improved. The present case demonstrates the importance of considering dissociative disorders when examining a patient with memory impairment in areas affected by disasters.

Key words : trauma, dissociative disorder, Great East Japan Earthquake, dementia

Introduction

The complex disasters that occurred on or after March 11, 2011—the Great East Japan Earthquake, the tsunami it caused, and the accident at the Fukushima Daiichi Nuclear Power Plant (FDNPP)—caused coastline residents of Fukushima Prefecture a great amount of psychological distress^{1,2)}. Of the residents that were forced to evacuate due to the accident at FDNPP, many who returned to their homes were elderly individuals³⁾. When elderly individuals complain of memory impairment, we must consider dementia, delirium, depression, epilepsy onset, cognitive impairment due to various diseases of internal medicine, and, in disaster-affected areas in particular, dissociative disorder. Herein, we report the case of a 69-year-old male who underwent a se-

verely traumatic experience during the disaster, and who, after returning home, presented with severe memory impairment, which improved slowly. By examining this case, we hope to highlight possibilities for the differential diagnosis of elderly individuals presenting with memory impairment in disaster-affected areas. Written informed consent was provided by the patient for the publication of this case report. At our institutions, case reports are exempted from the need for approval from an ethics committee.

Case report

After dropping out of high school, the patient began working in the construction industry, married in his 20s, and raised three children. He had a his-

Corresponding author : Akemi Miyagawa E-mail : a-miya@fmu.ac.jp

©2021 The Fukushima Society of Medical Science. This article is licensed under a Creative Commons [Attribution-NonCommercial-ShareAlike 4.0 International] license.
<https://creativecommons.org/licenses/by-nc-sa/4.0/>

tory of gastric ulcers and otitis media and had been prescribed amlodipine for hypertension prior to his first visit to our hospital. He had no previous history of mental illness.

On March 11, 2011, the patient witnessed his wife being swept away in front of him by the tsunami resulting from the Great East Japan Earthquake. Following the accident at the FDNPP, he evacuated with his family and returned to his hometown 1 year later. For 2 years after returning to his hometown, he lived with his father and his son's family while taking care of his father. After living with his son's family for more than 1 year after placing his father in a nursing home, he began to frequently lose valuable items. He began to suspect that his son had stolen them, and this issue eventually caused the son and his family to move out. Afterwards, his memory impairment gradually worsened, and he became unable to recall what he had done on any given day. As his son was worried, he was brought by his son to our hospital 1 year after separation. Until then, he had been visiting other internal medicine clinics throughout the previous 2 years, but no particular abnormalities other than hypertension were pointed out. During the first visit, the patient had no serious feelings about his memory loss. He went out almost every day to interact with his acquaintances and returned home without getting lost, but he could not report how he spent the day. He was able to contact his friends using his mobile phone and drove on his own without any trouble or traffic violations. He denied having any depressive feelings, and no obvious weight loss was observed. When we asked if he got lost when he went out, he gave an unrelated answer: "I'm going to see the sea." He was also able to recount in detail how his wife was swept away by the tsunami. During testing, the patient scored 16 on the Revised Hasegawa Dementia Scale (HDS-R), indicating a decline in cognitive function. Additionally, computed tomography (CT) showed findings of suspected dilatation of the lower horn of the right lateral ventricle (Figure 1). From these findings, he was diagnosed with Alzheimer's disease and prescribed donepezil. However, compliance was problematic due to his memory impairment. He went to the hospital once every 2 weeks; 4 months on, in November 20XX, after a very emotional fight with his son, he reported this fight with substantial details that were confirmed by the care manager. Two weeks later, he was able to report what happened without any error or misremembrance. Furthermore, in December 20XX, he remembered exactly what he was shopping for. In

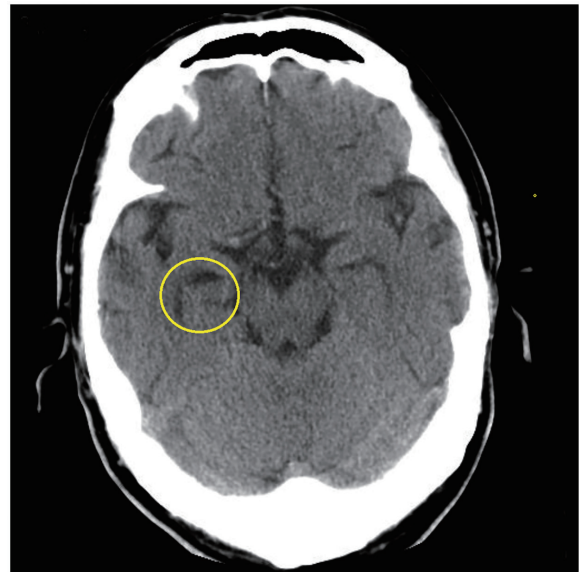


Figure 1. Brain computed tomography findings at the first visit. Dilatation of the lower horn of the right lateral ventricle was suspected.

addition, he recalled correctly about the contents of the examinations that he took 2 weeks prior. We thought that the patient's state changed from that of his first visit. Blood tests showed no evidence of anemia, hypoproteinemia, thyroid dysfunction, liver and renal dysfunction, or abnormal glucose metabolism. Although a Mini-Mental State Examination (MMSE) performed at this time showed 23 points, and delayed recall of 0 points, we thought memory impairment was tending to improve clinically. As this course was not typical for dementia, the patient was admitted to the Department of Psychiatry at Fukushima Medical University for more detailed testing.

During the first week after admission, the patient was relatively calm throughout the day, but would often become irritable after sunset. However, by the second week, he had calmed down and was able to appropriately interact with staff and other inpatients. He said at the interview that he had been heading to the sea when he regained control of his mental faculties. Cranial magnetic resonance imaging (MRI) revealed no cortical atrophy (Figure 2). A slight left-right asymmetry in the hippocampus was observed (Figure 3), but upon interpretation of these images by a radiologist, no particular abnormality was diagnosed (Figure 3). In addition, there were no high-intensity regions observed in the hippocampal region. In a dopamine transporter (DaT) scan, the specific binding ratios of the nigrostriatal pathway were 3.77 on the right and 3.86 on the left, which indicated a slight reduction relative to normal

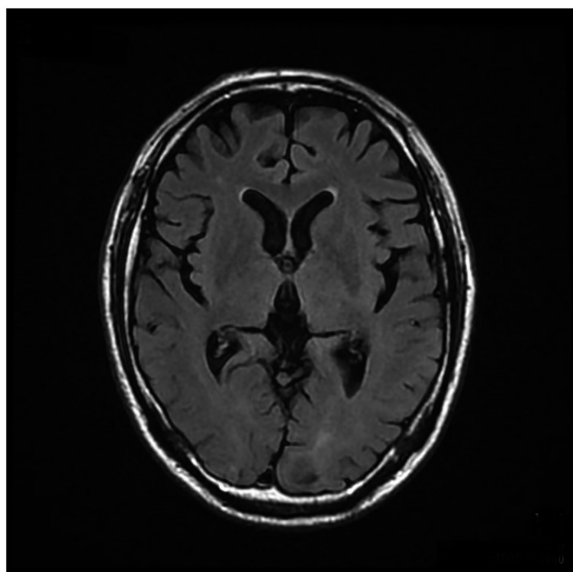


Figure 2. Brain magnetic resonance imaging findings (horizontal section). Cerebral cortex atrophy was not noted. There were no findings of high intensity in the hippocampus region, nor were there findings suggesting ischemia in the DWI.

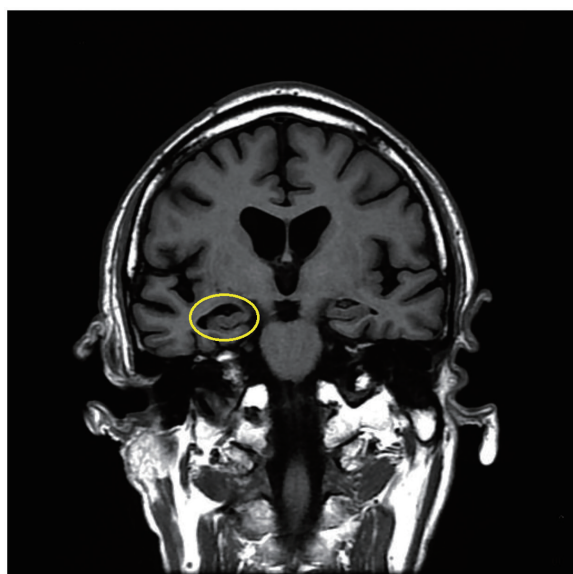

Figure 3. Brain magnetic resonance imaging findings (coronal section). There was a difference in hippocampal size on the left and right, but no abnormality was noted by the radiologist. We ultimately determined this finding to have little pathological significance.

values ; however, the radiologist interpreted these findings as having no significant abnormality. Ultimately, we determined that these MRI findings showed few pathological signs. In the electroencephalogram (EEG), α activity of 9–11 Hz and 30–80 μ V were observed and there were no abnormal find-

ings, including slow-wave.

In the Baum test, a drawing of a tree reminded him of the damage he suffered due to the tsunami and the loss of his wife ; he became quite emotional and the test had to be suspended. The Wechsler Adult Intelligence Scale (WAIS-III) revealed a full-scale intelligence quotient (IQ) of 81, a verbal IQ of 80, and a performance IQ of 87, all of which were within normal ranges. The patient produced many errors on the Benton Visual Retention Test, suggesting a decline in cognitive function. However, as no obvious abnormalities were observed in the imaging studies, we could not positively diagnose him with dementia. Similarly, as EEG and blood analyses revealed no abnormalities, the possibility of cognitive decline due to epilepsy, delirium, or other physical diseases was considered low. As his daily activity remained normal and he felt no depressive mood, the possibility of memory impairment due to depression was low. Overall, as he had serious psychological trauma and his experiences of separation from his father and his son's family affected him as further trauma, we considered that he suffered from continuing dissociation, resulting in memory impairment.

Therefore, we changed the treatment strategy from drug treatment and life support for dementia to focusing on creating a living environment that was supportive, comfortable, and felt at ease. Because the patient's relationship with his son was strained, we had nurses and support service providers assist the patient with daily tasks (e.g. cooking, cleaning, and taking medicine). Before beginning treatment, the patient spent the entirety of every day outside of the house and was unable to turn off the lights at night. We thought that he might be feeling anxious or nervous and began treating him with sertraline (25 mg daily) in May 20XX+1. Very quickly, he began to spend less time outside, started turning off the lights when going to sleep, and was able to remain calm while speaking about his wife. He would also sometimes spend time at senior care facility and began to look forward to the activities planned there. However, once his sertraline dose reached 100 mg/day in June 20XX+1, he began to spend money extravagantly, and we suspected that he was experiencing drug-induced hypomania. We were, therefore, forced to terminate the sertraline treatment after a total of 3 months. After terminating drug treatment, the patient's tendency to frequently leave the house did not return. He said that he could remember better than before. The patient was housed in a residential complex constructed for

Table 1. Cognitive scores over time.

Cognitive test \ Examination time	Initial visit	4 months later	13 months later	17 months later
HDS-R	16		22	21
MMSE		23	24	26

Abbreviations : HDS-R, Revised Hasegawa Dementia Scale ; MMSE, Mini-Mental State Examination

evacuees from the nuclear disaster at Fukushima, and he began to actively interact with others who were in similar circumstances. He was tenderly cared for by the other residents of this community, and his memory impairment improved gradually. Approximately 9 months after discharge, although delayed recall was at 2 points, the total MMSE score improved to 26, which is within the normal range (Table 1).

Discussion

The Pacific coastal area of Fukushima Prefecture that was affected by the Great East Japan Earthquake was home to communities of elderly people before the disaster occurred³. Therefore, it is believed that, even now, there are elderly individuals bearing various of disaster-related traumatic experiences in the area. When elderly individuals from disaster-affected areas complain of memory impairment, there are many possible diagnoses besides dementia, including depression, delirium, epilepsy, various physical illness that causes memory impairment, and dissociative disorder.

This patient had no particular abnormalities during his visit to the internal medicine clinic, and blood tests at our hospital showed no abnormalities in thyroid, liver, or kidney function. We did not check vitamin or folic acid levels in his blood, but he did not exhibit hypoproteinemia or reduction in his body weight. Hence, the possibility of cognitive impairment due to deficits in vitamins or folic acid was not high.

While he was admitted, he experienced mood swings between morning and evening over the course of a single day. However, there was never a clear relationship between his mood swings and memory impairment. Further, in the tests conducted while he was admitted, α -waves appeared normal and no epileptic waves were found on EEG, even when his memory impairment was severe. We did not find any evidence suggesting low consciousness. Therefore, both delirium and epilepsy were unlikely explanations for his memory impair-

ment.

In elderly individuals, depression does not manifest as a change in mood ; rather, it usually involves unexplained general physical malaise, issues with concentration, and memory impairment⁴. Because we opted to treat this patient with sertraline after discharge, his inability to calm down soon recovered, and he was able to recount stories of his wife without becoming emotional. Thus, we can surmise that he had been suffering from anxiety, frustration, and irritation, suggesting underlying depression. While it is generally recommended that as long as side effects are not a problem, antidepressants should be continued at the same dose employed during the acute period for at least 4-9 months after remission⁵, we were only able to administer sertraline for approximately 3 months. However, because the patient's MMSE and HDS-R scores slowly improved, even after the discontinuation of sertraline, it is unlikely that the improvement in the patient's memory impairment was due to the treatment of depression by sertraline. Additionally, the patient proactively left his house and often interacted with friends, indicating no issues with his motivation or activity levels. Given this course, depression was also an unlikely possibility.

In Japan, the HDS-R is a well-known screening test for dementia, similar to the MMSE. Together, the two have a Cronbach's α of 0.90, and a correlation coefficient of 0.94, indicating a high degree of correlation⁶. While the sensitivity of the MMSE is 81% and its specificity is 89%⁷, the HDS-R has a sensitivity and specificity of 90% and 82%, respectively⁸, and is relatively unaffected by education level⁹; thus, it is a very useful tool for diagnosing dementia. For this reason, the fact that the patient had a low HDS-R score at the first examination allows us to assume that his MMSE score was also low.

We initially began treatment for dementia due to the patient's low score on the delayed recall task at his initial evaluation. As there were also a high number of errors on the Benton Visual Retention Test administered during hospitalization, we further

suspected some kind of decline in cognitive function.

In the ICD-10, dementia (F00-F03) is described as a syndrome resulting from neuropathology, which is usually chronic or progressive, features disorders of multiple higher cortical functions, and is not accompanied by disturbance of consciousness¹⁰. As it is an organic brain disease, diagnostic imaging often shows abnormalities and slow waves are often detected on EEG beginning in the early stages¹¹. This patient was able to interact with his acquaintances via mobile phone. He could drive without committing traffic violations. Although his relationship with his son was deteriorating, he displayed no socially deviant behaviors, and his higher cortical function on the whole did not seem to be declining. Further, while it appeared that his forgetfulness had progressed from symptom onset to his first visit with us, there were several episodes suggesting that his memory disorder had improved since his first visit. For example, approximately 4 months after his first visit, he was able to correctly report the details of his troubles with his son, and he could accurately talk about the tests and instructions he had received 2 weeks previously. Thus, his condition did not align with the definition of chronic and progressive cognitive deterioration. Initial imaging tests showed findings suggesting enlargement of the inferior horn of the right lateral ventricle and this was similarly suggested by the head MRI performed after hospitalization, but a radiologist did not find it to be abnormal and it was ultimately determined to have little pathological significance. Further, there were no high-intensity findings suggesting sclerosis or ischemia in the hippocampus on head MRI.

Moreover, after the patient's father was institutionalized, it was several months before his relationship with his son began to deteriorate due to delusional accusations of theft. Thus, the symptoms seemed to progress too quickly to consider a diagnosis of dementia. Combining the above findings, the possibility of dementia could not be ruled out, but also could not be actively supported. Further, transient global amnesia (TGA) was ruled out because there were no findings suggesting hippocampal sclerosis or ischemia, and because TGA usually resolves within 24 hours.

It has been reported that during disaster-related events, elderly individuals are more likely than younger individuals to develop post-traumatic stress disorder (PTSD) and adjustment-related disorders, rather than depression¹². There are also reports indicating that it is possible for PTSD to occur due to illness or the death of a loved one^{13,14}. While

this patient had a severely traumatic experience, he did not present with particularly severe memory impairment while living with his family. However, after his father was placed in a nursing home, he began to experience memory impairment, and after his son's family moved out of his home, his symptoms worsened to a level where he could not remember what he had been doing that day. However, as mentioned above, his memory impairment showed a tendency to improve in the course of his outpatient period, and as no imaging or EEG abnormalities were observed, we considered the possibility of dissociative disorder.

Dissociative amnesia, grouped among dissociative disorders, is a form of retrograde amnesia, which often appears as impaired recall for a specific traumatic event. As such, it was ruled out for this patient. Dissociative stupor was also excluded, as the patient was able to hold normal conversations and drive, even if he could not recall those events.

Depersonalization most often arises under extreme stress and patients often complain of a loss of their sense of reality, yet there were no such complaints in this case. However, there are several reports concerning depersonalization in which short-term memory impairment is exhibited as a result of a deficit in perception, attention, and concentration toward new information^{15,16}. When the patient was asked at his first visit whether he gets lost when coming home from an outing, he gave an unrelated answer (that he goes to see the sea). He also stated that he sometimes heads to the sea before he even realizes it. If these complaints are taken to reflect a decline in attention and concentration, it is possible that the patient is exhibiting anterograde amnesia as a result of persistent depersonalization due to an inability to adapt to the severe stress of witnessing his wife being swept away by a tsunami and the additional stressors of beginning to live apart from his father and a deteriorating relationship with his son.

This report does not rule out the possibility that these symptoms are a result of dementia. In fact, his improvement on the delayed recall task was slow and he also had many errors on the Benton Visual Retention Test. Thus, the patient's symptoms are not explained by a dissociative disorder alone.

However, that the patient's memory disorder improved—although not completely—after he began to receive emotional support also suggests that psychological stress was involved in the memory disorder in this case. It is thus vital to recognize that if dissociative disorders had not been considered as a

potential cause of this patient's symptoms, intervention would not have focused on emotional support and improvement in cognitive function would likely not have been achieved as it was here.

Conclusion

Even when the course is not typical of dementia, memory disorder in older adults might be diagnosed as dementia only, and if interventions are not reassessed, opportunities for symptomatic improvement may be lost.

It is vital to bear in mind the possibility of dissociation when examining older adults complaining of memory disorder, particularly in areas that have been struck by disaster.

Abbreviations

CT, computed tomography ; DaT, dopamine transporter ; EEG, electroencephalogram ; FDNPP, Fukushima Daiichi Nuclear Power Plant ; HDS-R, Hasegawa Dementia Scale ; ICD-10, International Classification of Diseases, 10th Revision ; IQ, intelligence quotient ; MMSE, Mini-Mental State Examination ; MRI, magnetic resonance imaging ; PTSD, post-traumatic stress disorder ; WAIS, Wechsler Adult Intelligence Scale ; TGA, transient global amnesia.

Conflict of interest

The authors report no conflicts of interest in this work.

Ethics approval and informed consent

At our institutions, case reports are exempted from the need for approval from an ethics committee. Written informed consent was provided by the patient for the publication of this case report.

Consent for publication

Written informed consent was provided by the patient for the publication of this case report.

References

1. Kunii Y, Suzuki Y, Shiga T, *et al.* Severe psychological distress of evacuees in evacuation zone caused by the Fukushima Daiichi nuclear power plant accident : the Fukushima Health Management Survey. *PLOS One*, **11** : e0158821, 2016.
2. Yabe H, Suzuki Y, Masahiro H, *et al.* Psychological distress after the Great East Japan Earthquake and Fukushima Daiichi Nuclear Power Plant accident : results of a mental health and lifestyle survey through the Fukushima Health Management Survey in FY2011 and FY2012. *Fukushima J Med Sci*, **60** : 57-67, 2014.
3. Fukushima-kenn Gennjuuzinkou Chousa Nennpou [PDF]. Heisei 30 Nennbann [In Japanese]. Available from : <https://www.pref.fukushima.lg.jp/uploaded/attachment/317024.pdf>. Accessed September 26, 2019.
4. Fiske A, Wetherell JL, Gatz M. Depression in older adults. *Annu Rev Clin Psychol*, **5** : 363-389, 2009.
5. American Psychiatric Association. Practice guideline for the treatment of patients with major depressive disorder. The American Psychiatric Association Practice Guidelines for the Psychiatric Evaluation of Adults. 3rd ed. Washington, DC : American Psychiatric Publishing ; 2010.
6. Imai Y, Hasegawa K. The revised Hasegawa's Dementia Scale (HDS-R)-Evaluation of its usefulness as a screening test for dementia. *HK J Psychiatry*, **4** : 20, 1994.
7. Tsoi KK, Chan JY, Hirai HW, Wong SY, Kwok TC. Cognitive tests to detect dementia : A systematic review and meta-analysis. *JAMA Intern Med*, **175** : 1450-1458, 2015.
8. Katoh S, Simogaki H, Onodera A, *et al.* Development of the revised version of Hasegawa's Dementia Scale (HDS-R) [in Japanese]. *Jpn Geriatr Psychiatr Med*, **2** : 1339-1347, 1991.
9. Jeong JW, Kim KW, Lee DY, *et al.* A normative study of the Revised Hasegawa Dementia Scale : Comparison of demographic influences between the Revised Hasegawa Dementia Scale and the Mini-Mental Status Examination. *Dement Geriatr Cogn Disord*, **24** : 288-293, 2007.
10. World Health Organization. The ICD-10 classification of mental and behavioural disorders : Diagnostic criteria for research. Geneva : World Health Organization ; 1993.
11. Al-Qazzaz NK, Ali SHBM, Ahmad SA, Chellappan K, Islam MS, Escudero J. Role of EEG as biomarker in the early detection and classification of dementia. *Scientific World Journal*, **2014** : 906038, 2014.
12. Parker G, Lie D, Siskind DJ, *et al.* Mental health implications for older adults after natural disasters—a systematic review and meta-analysis. *Int Psychogeriatr*, **28** : 11-20, 2016.
13. Horesh D, Solomon Z, Keinan G, Ein-Dor T. The clinical picture of late-onset PTSD : a 20-year longitudinal study of Israeli war veterans. *Psychiatry*

- Res, **208** : 265-273, 2013.
14. Hermann N, Eryavec G. Delayed onset post-traumatic stress disorder in World War II veterans. *Can J Psychiatry*, **39** : 439-441, 1994.
 15. Guralnik O, Giesbrecht T, Knutelska M, Sirroff B, Simeon D. Cognitive functioning in depersonalization disorder. *J Nerv Ment Dis*, **195** : 983-988, 2007.
 16. Guralnik O, Schmeidler J, Simeon D. Feeling unreal : cognitive processes in depersonalization. *Am J Psychiatry*, **157** : 103-109, 2000.