

Contents lists available at [ScienceDirect](#)

## International Journal of Surgery Case Reports

journal homepage: [www.casereports.com](http://www.casereports.com)Atypical as well as anatomical liver resections are feasible by laparoendoscopic single-site surgery<sup>☆</sup>Dimitrios Tzanis<sup>a,b</sup>, Panagiotis Lainas<sup>a,b</sup>, Hadrien Tranchart<sup>a,b</sup>, Guillaume Pourcher<sup>a,b</sup>, Niaz Devaquet<sup>a</sup>, Gabriel Perlemuter<sup>b,c</sup>, Sylvie Naveau<sup>b,c</sup>, Ibrahim Dagher<sup>a,b,\*</sup><sup>a</sup> Department of General Surgery, Antoine-Béclère Hospital, AP-HP, 157 rue de la Porte de Trivaux, F-92140 Clamart cedex, France<sup>b</sup> University of Paris-Sud, Orsay F-91405, France<sup>c</sup> Department of Gastroenterology, Antoine-Béclère Hospital, AP-HP, 157 rue de la Porte de Trivaux, F-92140 Clamart cedex, France

## ARTICLE INFO

## Article history:

Received 16 September 2013

Received in revised form 28 October 2013

Accepted 15 November 2013

Available online 12 July 2014

## ABSTRACT

**INTRODUCTION:** Liver surgery was one of the last fields to be conquered by laparoscopy, which has become safe and effective, especially for left lateral sectionectomy (LLS) and limited peripheral resections. However, major hepatectomies remain challenging. Laparoendoscopic single-site (LESS) surgery is being employed for an increasing variety of surgical sites and indications.

**PRESENTATION OF CASE:** Three patients underwent LESS hepatectomy. A 36-year-old woman had LLS for a 38-mm adenoma, an 85-year-old woman an atypical resection of segment VI for a 12-mm hepatocellular carcinoma and a 41-year-old woman an atypical right anterior resection for a 9 cm symptomatic FNH. Procedures were performed transperitoneally with a single-port device, via a 20-mm or 30-mm incision. Operative times were 110 min for LLS, 100 min for the atypical segment VI resection and 120 min for the atypical right anterior liver resection. Blood loss was less than 50 ml in the first two patients and 150 ml in the third. Postoperative courses were uneventful. The first two patients were discharged on postoperative day 3 and the third on postoperative day 1.

**DISCUSSION:** To date, some case reports and series of LESS liver surgery have been published. We performed the reported hepatectomies after a considerable experience in laparoscopic hepatic surgery and after applying the LESS approach to other procedures. Our hepatectomy technique was not modified by the use of the single-port and results were very encouraging.

**CONCLUSION:** We believe that in selected patients, both peripheral resections and LLS are feasible by LESS surgery, with good intra-operative and post-operative results.

© 2014 The Authors. Published by Elsevier Ltd. on behalf of Surgical Associates Ltd. All rights reserved.

## 1. Introduction

From its beginning in the 1980s, laparoscopic surgery has marked a rapid progress and an almost astonishing expansion worldwide, becoming the standard approach for numerous indications in many surgical specialties. Important highlights that established its place in the surgical arena and further promoting this “revolution”, were: (i) the NIH Consensus Conference Statement in 1992, concluding that laparoscopic cholecystectomy is the standard of care in good risk patients,<sup>1</sup> (ii) the Clinical Outcomes of Surgical Therapy Study Group recognizing it as the gold standard in colorectal surgery in 2004,<sup>2</sup> and lately (iii) the Louisville Statement

in 2008 confirming laparoscopy as the standard approach for left lateral hepatic sectionectomy (LLS) and defining the international position on laparoscopic liver surgery.<sup>3</sup>

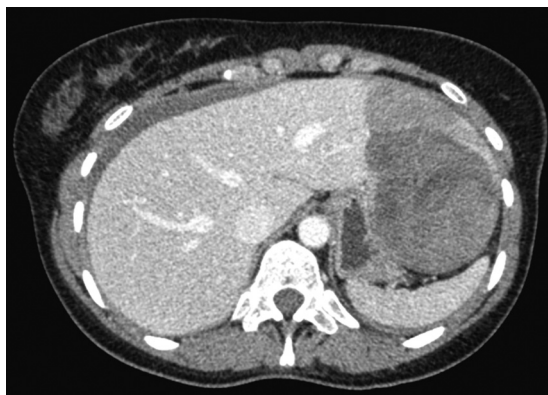Liver surgery was one of the last fortresses to fall, as laparoscopic hepatic resections demand for experience in both liver surgery and advanced laparoscopy. Once reported in 1992,<sup>4–7</sup> it had to wait until 2000 for the first prospective cohort of patients.<sup>8</sup> Today, and after more than 3000 laparoscopic liver resections performed internationally,<sup>9</sup> the laparoscopic approach is used routinely for LLS, is safe and effective for all the rest of resections of segments II–VI (the so-called laparoscopic segments), but remains a challenging procedure for major resections.<sup>10,11</sup> Apart from the well-established benefits of minimally-invasiveness (cosmesis, post-operative pain, short hospital stay), it has proved to be beneficial in terms of blood loss,<sup>12</sup> in reducing postoperative ascites in cirrhotic patients, and, furthermore, some benefits have also been established for major liver resections.<sup>13</sup>

LESS surgery, although tracing back to the 1960s, represents the most modern advance in the field of minimally invasive surgery and is currently being applied to a continuously increasing variety of both operating sites and pathologies.<sup>14</sup> The fact that it is being

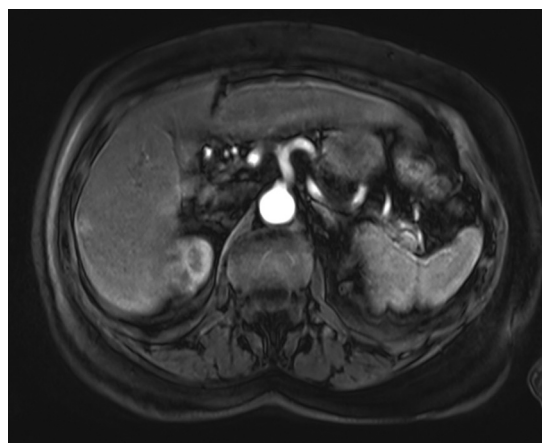
<sup>☆</sup> This is an open-access article distributed under the terms of the Creative Commons Attribution-NonCommercial-No Derivative Works License, which permits non-commercial use, distribution, and reproduction in any medium, provided the original author and source are credited.

\* Corresponding author at: Department of General Surgery, Antoine Béclère Hospital, 157 rue de la Porte de Trivaux, 92141 Clamart cedex, France.  
Tel.: +33 1 45 37 45 45.

E-mail address: [ibrahim.dagher@abc.aphp.fr](mailto:ibrahim.dagher@abc.aphp.fr) (I. Dagher).



**Fig. 1.** CT-scan showing the hematoma and the 38-mm tumor in the left hepatic lobe in patient 1.



**Fig. 2.** MRI showing the 12-mm subcapsular lesion in segment VI of patient 2.

promoted as “the new revolution” has made it the centre of a vigorous debate concerning the real benefits and the safety of the procedure. It is not surprising that it has been the subject of admirable technological progress and applications, has employed them to go further on to more demanding operations, such as hepatectomies, and is constantly urging for even more refined and sophisticated technological solutions.

The aim of this study is to present our initial experience in laparoscopic single-site liver surgery and demonstrate the feasibility of LESS surgery for atypical and anatomical hepatectomies.

## 2. Presentation of cases

### 2.1. Patient history

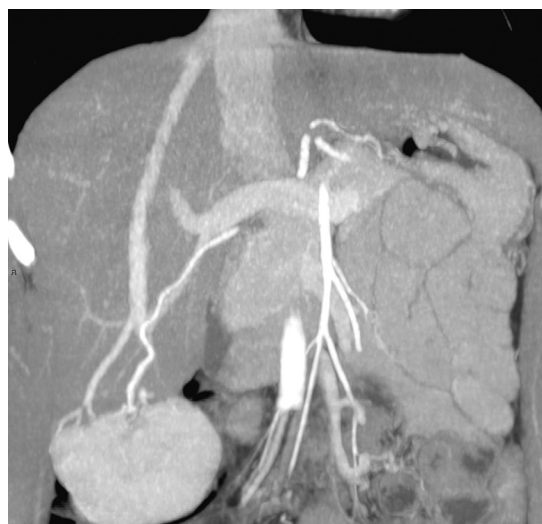
**Patient 1.** A 36-year-old woman with a history of untreated gastroesophageal reflux disease (GERD) presented with epigastric pain and vomiting. Her initial work-up found a deglobulisation with a hemoglobin at 7.6 g/dL and the abdominal CT-scan showed a hemorrhagic tumour of the left liver, probably an adenoma, and a hemoperitoneum. She received initial treatment by arterial embolization. A second CT-scan and a MRI showed an 11-cm hematoma and a 38-mm adjacent mass of the left hepatic lobe (Fig. 1). Additionally a 1-cm adenoma was revealed in segment VI. Three months later, the patient still complained for abdominal pain and lost 5 kg. She consulted twice in the emergency department.

**Patient 2.** An 85-year-old woman, with post-hepatitis C cirrhosis and having been treated seven years before for a hepatocellular carcinoma by radiofrequency ablation, presented a subcapsular lesion of segment VI in a control CT-scan. Alpha-fetoproteine (AFP) value was normal. MRI showed a 12-mm mass with radiologic characteristics in favour of hepatocellular carcinoma (Fig. 2).

**Patient 3.** A 41-year-old woman who complained for right abdominal pain and difficulty in sports presented with a 9-cm tumour of the right anterior section with extrahepatic development (Fig. 3). Radiologic characteristics on CT-scan and MRI were in favour of focal nodular hyperplasia (FNH). Two small hemangiomas were found in segments VI and VII.

### 2.2. Surgical procedures

All patients were operated on by a LESS approach *via* a single incision, using the QuadriPort (Olympus, Rungis, France) for the first two patients and the TriPort (Olympus, Rungis, France) device for the third, a 5-mm flexible laparoscope and curved as well as standard straight laparoscopic instruments.



**Fig. 3.** MRI showing the 9-cm tumour of the right anterior section of the liver with extrahepatic development in patient 3.

**Patient 1 (laparoscopic left lateral sectionectomy).** Peritoneal access was gained by a 30-mm supraumbilical incision in the open fashion. No clamping was performed, as in our standard technique for all hepatic resections. The pedicles of segments II and III were dissected extraparenchymally and divided separately between absorbable clips. Parenchymal transection was performed using the clamp crushing technique with the Ligasure (Covidien, Elancourt, France) and haemostasis and biliostasis were assured by bipolar electrocautery. The left hepatic vein was sectioned with an articulating vascular stapler (EndoGIA, Covidien, Elancourt, France). The specimen was placed in a bag, cut in two pieces and extracted through the umbilical incision after aspiration of the residual hematoma. Blood loss was estimated at less than 50 ml and the total operative time was 110 min.

**Patient 2 (atypical resection of segment VI).** A 30-mm supraumbilical incision in the open fashion was performed to gain peritoneal access. A subcapsular lesion of about 15-mm was visualized on the anterior surface of hepatic segment VI. An atypical resection was performed, encompassing the tumour and remaining at distance (2 cm margin) from it at all times. No clamping was performed; parenchymal transection was performed with the Ligasure (Covidien, Elancourt, France) and haemostasis and biliostasis were assured by bipolar electrocautery and absorbable clips for larger elements. The specimen was placed in a bag and extracted through

the incision. Blood loss was estimated at less than 50 ml and the total operative time was 100 min.

*Patient 3 (atypical right anterior resection).* We made a 20-mm infraumbilical incision in the open fashion. After satisfactory tumour exposure, transection of the liver parenchyma was started with the Ligasure (Covidien, Elancourt, France). Application of a vascular EndoGIA (Covidien, Elancourt, France) was performed for section of a branch of the right hepatic vein. An additional epigastric port for the irrigation–aspiration device and the bipolar electrocautery was used to control a bleeding on the transection line. The specimen was placed in a bag, cut into three pieces and removed from the umbilical incision. Total operative time was 120 min and blood loss was estimated at 150 ml.

### 2.3. Postoperative evolution

All patients received oral alimentation the same day and intravenous fluid administration was discontinued the next morning. They stated that they were very satisfied by the cosmetic result.

Patient 1 experienced minimal umbilical pain, but complained for right shoulder pain related to the pneumoperitoneum, and had a minor allergic reaction. For these reasons she was discharged on postoperative day 3. At follow-up consultation, one month later, her preoperative GERD-related symptoms had disappeared.

Patients 2 and 3 experienced minimal pain and had an otherwise totally uneventful postoperative course. They were discharged on postoperative days 3 and 1 respectively.

## 3. Discussion

Single incision laparoscopic surgery techniques trace back to the 1960s, when this approach was used for tubal ligation. The first reports in the modern era described single incision laparoscopy for cholecystectomy and appeared in the mid-1990s. The first two series were those of Navarra et al.<sup>15</sup> in 1997 and Piskun et al.<sup>16</sup> in 1999, who replaced the exposure instruments with stay sutures and placed two ports through a single skin wound.

Currently, as single incision has been increasingly employed by surgeons of different specialties for an expanding list of indications, there is a growing need for an even more advanced and sophisticated technology. In 2009, the consortium for assessment and research for laparoendoscopic single-site surgery unanimously concluded that the term laparoendoscopic single-site (LESS) surgery most accurately conveys the broad philosophical and practical aspects of the field.<sup>17</sup> In their systematic review of the literature for laparoscopic surgery performed through a single incision, Pfluke et al.<sup>18</sup> found 434 publications between January 2000 and May 2010 with 219 manuscripts meeting their inclusion criteria and including original patient data that had been published and were reviewed, which represented 4585 operations.

To date, some case reports<sup>19–23</sup> and 3 series of up to 8 cases<sup>24–26</sup> of LESS liver surgery have been published. We hereby present our initial experience of a LLS and two atypical right resections for benign and malignant tumours by LESS approach.

All procedures were completed by using our standard technique for all types of hepatectomy: no porta hepatis clamping and parenchymal transection by the clamp crushing technique with the Ligasure (Covidien, Elancourt, France). In particular for LLS, we perform the dissection of segments II and III pedicles extraparenchymally and we divide them separately in both open and laparoscopic procedures. The left hepatic vein is divided with an articulating vascular stapler. LESS surgery allows the application of all these techniques, such as transection by the clamp crushing technique, extraparenchymal dissection of portal pedicles and the use of bipolar electrocautery and clips. Lack of instrument

triangulation was one of the main issues that had to be dealt with, along with external crowding and clashing of instruments or deflection of the camera. This problem was sufficiently dealt with by the use of curved clamps. The need for bipolar coagulation and aspiration during parenchymal transection led to the addition of a second port in our third patient with the FNH lesion of the right liver. We believe this issue could have been sufficiently addressed with the QuadriPort device, which, unfortunately, was not at our disposal.

We met no particular problems in recognizing anatomic landmarks. Acquisition of correct haemostasis and biliostasis was the same as in conventional laparoscopic hepatectomies, by bipolar electrocautery and application of absorbable clips for larger vascular structures. Two out of three specimens were removed after being cut in the extraction bag from the umbilical incision with no particular difficulties. In the second case, the specimen was extracted intact. The postoperative course was practically uneventful for all patients with minimal peri-umbilical pain and a very good cosmetic result.

Cosmesis is the undeniable advantage of LESS surgery, which is probably the reason for which, of the 219 manuscripts reviewed by Pfluke et al.<sup>18</sup> only 50 commented on cosmetic outcomes. Canes et al.<sup>27</sup> in their matched-pair comparison study for LESS versus standard laparoscopic left donor nephrectomy, demonstrated that self-reported scar satisfaction scores were significantly higher in the LESS group.

For LESS hepatic resections a great additional interest resides in the use of the single incision for the extraction of the specimen, especially in benign tumors which can be cut in smaller pieces. This has a double impact on both cosmesis and postoperative pain. Reduction of postoperative pain has already been achieved in a very satisfactory manner by conventional laparoscopy, with a shorter hospital stay and earlier return to everyday activities. Chang et al.<sup>28</sup> in their case–control study of single-incision versus standard laparoscopic cholecystectomy, fail to demonstrate a statistically significant difference in postoperative pain, pain site and analgesia requirements, although the patients of the single-incision group returned to normal activity 1.8 days earlier. Ten of the 219 studies reviewed by Pfluke et al.<sup>18</sup> compared postoperative pain between single-incision and conventional laparoscopic groups using the VAS and three of them reported lower VAS scores in the single incision group. Moreover, we are of the opinion that the minimally invasive approach should be preferred for hepatic resections in potential transplant candidates. It has been demonstrated that transplantation can be facilitated by laparoscopy in terms of reduced operative time, blood loss and transfusion needs.<sup>12</sup> LESS surgery may be beneficial because the single incision is suitable for specimen extraction.

As regards specimen removal, cutting a benign tumour after placing it in a bag allows its extraction from the umbilical incision without enlargement. As for malignant tumours, by enlarging the single incision when necessary, there is no need for a supplemental incision (supra-pubic, previous appendectomy or other) and the patient is spared the incisions of the ports. We believe that this important reduction of incision sites causes less post-operative pain.

LESS surgery is one of the most modern advances in the field of minimally invasive techniques and has already been applied in various pathologies. Although many surgeons regard it as a second revolution after the introduction of classical laparoscopy, we think that it represents a natural evolution, a novel aspect of laparoscopy in the constant research of less traumatic and aesthetically better results, which has been the aim of minimally invasiveness from the first beginning. Patients are demanding for excellent cosmesis, less pain and faster rehabilitation. Laparoscopic surgeons will have to be able to offer all types of minimally invasive procedures in order to respond to their patients' needs.

#### 4. Conclusion

In our institution, after having acquired a considerable experience in laparoscopic hepatic surgery and after having applied the LESS approach to other procedures (cholecystectomy, sleeve gastrectomy), we performed the reported hepatectomies and suggest that anatomical as well as atypical resections are feasible by LESS surgery with good peri-operative and post-operative results. Larger series representing additional experience will be needed to confirm the safety of this novel technique. It might be useful for all teams who practice LESS surgery to keep in mind that adding supplemental ports is very quick and easy, directly establishes the conditions of conventional laparoscopy and should not be equated to a conversion, as the approach remains laparoscopic.

#### Ethical approval

Written informed consent was obtained from the patients for publication of this case report and accompanying images. A copy of the written consent is available for review by the Editor-in-Chief of this journal on request.

#### Authors contribution

ID: conception; SN, GP, GP, ND: acquisition of data; DT, PL: drafting; HT: revising.

#### Conflict of interest

The authors declare that they have no conflict of interest.

#### References

1. Consensus N.I.H. Conference. Gallstones and laparoscopic cholecystectomy. *JAMA* 1993;**269**(8):1018–24.
2. Clinical Outcomes of Surgical Therapy Study Group. A comparison of laparoscopically assisted and open colectomy for colon cancer. *N Engl J Med* 2004;**350**:2050–9.
3. Buell JF, Cherqui D, Geller DA, O'Rourke N, Iannitti D, Dagher I, et al. The international position on laparoscopic liver surgery: The Louisville Statement, 2008. *Ann Surg* 2009;**250**:825–30.
4. Gagner M, Rheault M, Dubuc J. Laparoscopic partial hepatectomy for liver tumor (abstract). *Surg Endosc* 1992;**6**:99.
5. Azagra JS, Goergen M, Gilbert E, Jacobs D. Laparoscopic anatomical (hepatic) left lateral segmentectomy—technical aspects. *Surg Endosc* 1996;**10**:758–61.
6. Kaneko H, Takagi S, Shiba T. Laparoscopic partial hepatectomy and left lateral segmentectomy: technique and results of a clinical series. *Surgery* 1996;**120**:468–75.
7. Huscher CG, Lirici MM, Chiodini S. Laparoscopic liver resections. *Semin Laparosc Surg* 1998;**5**:204–10.
8. Cherqui D, Husson E, Hammoud R, Malassagne B, Stéphan F, Bensaid S, et al. Laparoscopic liver resections: a feasibility study in 30 patients. *Ann Surg* 2000;**232**:753–62.
9. Nguyen KT, Gamblin TC, Geller DA. World review of laparoscopic liver resection—2,804 patients. *Ann Surg* 2009;**250**:831–41.
10. Dagher I, O'Rourke N, Geller DA, Cherqui D, Belli G, Gamblin TC, et al. Laparoscopic major hepatectomy: an evolution in standard of care. *Ann Surg* 2009;**250**:856–60.
11. Dagher I, Di Giuro G, Lainas P, Franco D. Laparoscopic right hepatectomy with selective vascular exclusion. *J Gastrointest Surg* 2009;**13**:148–9.
12. Laurent A, Tayar C, Andreoletti M, Lauzet JY, Merle JC, Cherqui D. Laparoscopic liver resection facilitates salvage liver transplantation for hepatocellular carcinoma. *J Hepatobiliary Pancreat Surg* 2009;**16**:310–4.
13. Dagher I, Di Giuro G, Dubrez J, Lainas P, Smadja C, Franco D. Laparoscopic versus open right hepatectomy: a comparative study. *Am J Surg* 2009;**198**:173–7.
14. Canes D, Desai MM, Aron M, Haber GP, Goel RK, Stein RJ, et al. Transumbilical single-port surgery: evolution and current status. *Eur Urol* 2008;**54**:1020–9.
15. Navarra G, Pozza E, Occhionorelli S, Carcoforo P, Donini I. One-wound laparoscopic cholecystectomy. *Br J Surg* 1997;**84**:695.
16. Piskun G, Rajpal S. Transumbilical laparoscopic cholecystectomy utilizes no incisions outside the umbilicus. *J Laparoendosc Adv Surg Tech A* 1999;**9**:361–4.
17. Gill IS, Advincula AP, Aron M, Cadeddu J, Canes D, Curcillo PG 2nd, et al. Consensus statement of the consortium for laparoendoscopic single-site surgery. *Surg Endosc* 2010;**24**:762–8.
18. Pfluke JM, Parker M, Stauffer JA, Paetau AA, Bowers SP, Asbun HJ, et al. Laparoscopic surgery performed through a single incision: a systematic review of the current literature. *J Am Coll Surg* 2011;**212**:113–8.
19. Cai XJ, Zhu ZY, Liang X, Yu H, Wang YF, He JK, et al. Single incision laparoscopic liver resection: a case report. *Chin Med J (Engl)* 2010;**123**:2619–22.
20. Kobayashi S, Nagano H, Marubashi S, Wada H, Eguchi H, Takeda Y, et al. A single-incision laparoscopic hepatectomy for hepatocellular carcinoma: initial experience in a Japanese patient. *Minim Invasive Ther Allied Technol* 2010;**19**:367–71.
21. Aldrighetti L, Guzzetti E, Ferla G. Laparoscopic hepatic left lateral sectionectomy using the laparoendoscopic single site approach: evolution of minimally invasive liver surgery. *J Hepatobiliary Pancreat Sci* 2011;**18**:103–5.
22. Belli G, Fantini C, D'Agostino A, Cioffi L, Russo G, Belli A, et al. Laparoendoscopic single site liver resection for recurrent hepatocellular carcinoma in cirrhosis: first technical note. *Surg Laparosc Endosc Percutan Tech* 2011;**21**:e166–8.
23. Patel AG, Belgaumkar AP, Jamas J, Singh UP, Carswell KA, Murgatroyd B. Video. Single-incision laparoscopic left lateral segmentectomy of colorectal liver metastasis. *Surg Endosc* 2011;**25**:649–50.
24. Gaujoux S, Kingham TP, Jarnagin WR, D'Angelica MI, Allen PJ, Fong Y. Single-incision laparoscopic liver resection. *Surg Endosc* 2011;**25**:1489–94.
25. Pan M, Jiang Z, Cheng Y, Xu X, Zhang Z, Zhou C, et al. Single-incision laparoscopic hepatectomy for benign and malignant hepatopathy: initial experience in 8 Chinese patients. *Surg Innov* 2012;**19**:446–51.
26. Aikawa M, Miyazawa M, Okamoto K, Toshimitsu Y, Okada K, Ueno Y, et al. Single-port laparoscopic hepatectomy: technique, safety and feasibility in a clinical case series. *Surg Endosc* 2012;**26**:1696–701.
27. Canes D, Berger A, Aron M, Brandina R, Goldfarb DA, Shoskes D, et al. Laparo-endoscopic single site (LESS) versus standard laparoscopic left donor nephrectomy: matched-pair comparison. *Eur Urol* 2010;**57**:95–101.
28. Chang SK, Tay CW, Bicol RA, Lee YY, Madhavan K. A case-control study of single-incision versus standard laparoscopic cholecystectomy. *World J Surg* 2011;**35**:289–93.

#### Open Access

This article is published Open Access at [scimedirect.com](http://scimedirect.com). It is distributed under the [IJSCR Supplemental terms and conditions](#), which permits unrestricted non commercial use, distribution, and reproduction in any medium, provided the original authors and source are credited.