

This is an Open Access article licensed under the terms of the Creative Commons Attribution-NonCommercial-NoDerivs 3.0 License (www.karger.com/OA-license), applicable to the online version of the article only. Distribution for non-commercial purposes only.

Hepatitis C-Related Cirrhosis with Sustained Prevention of Hepatocellular Carcinoma Recurrence by Long-Term Administration of Super-Low-Dose Peginterferon-Alpha 2b

Satoshi Mamori Hiroshi Mamori

Mamori Clinic, Kobe, Japan

Key Words

Hepatocellular carcinoma · Prevention · Recurrence · Hepatitis C virus · Pegylated interferon

Abstract

A 78-year-old male who experienced multiple recurrences of hepatocellular carcinoma (HCC) with hepatitis C virus (HCV)-related cirrhosis underwent transcatheter arterial chemoembolization and ablation and survived for more than 10 years. His serum HCV RNA level was 2.8 log IU/ml and the serotype of HCV was 2. He underwent long-term super-low-dose (20 µg/week) pegylated interferon-alpha 2b therapy to prevent recurrence of HCC. He became negative for HCV RNA 2 months later, and thereafter remained negative after the discontinuation of interferon therapy, and has not experienced a recurrence of HCC for more than 20 months.

Introduction

The main cause of death in patients with chronic hepatitis C is hepatocellular carcinoma (HCC) [1–4]. Moreover, HCC complicated with hepatitis C virus (HCV)-related chronic hepatitis or cirrhosis recurs frequently after curative therapies for the initial HCC [5]. Treatment has traditionally focused on curing only the recurrent HCC. Nevertheless, recent studies on the efficacy of interferon (IFN) in the prevention of recurrence of HCC and survival after curative resection of the HCC in patients with HCV cirrhosis have provided conflicting data [6–15]. Moreover, the Japanese Guidelines (The Study Group for the Standardization of Treatment of Viral Hepatitis Including Cirrhosis, Ministry of Health, Labour and Welfare of Japan) stated that long-term IFN therapy

should be considered for patients with compensated cirrhosis in order to prevent HCC in 2008 [16]. Arase et al. recently reported that long-term IFN monotherapy using a low dose of natural IFN- α was effective for preventing hepatocarcinogenesis in elderly patients with chronic hepatitis C [17]. No case report has so far documented the prevention of future HCC recurrence by the long-term use of low-dose pegylated IFN (Peg-IFN). This report presents a case of HCV associated with cirrhosis with a sustained prevention of HCC recurrence by long-term administration of super-low-dose Peg-IFN- α 2b.

Case Report

A 78-year-old male was diagnosed to have HCV infection and HCC in the right lobe of the liver in 1997. He had a sufficient hepatic reserve and underwent partial hepatectomy for the first HCC. His liver function was monitored and periodically checked for recurrent HCC by blood tests and computed tomography. Unfortunately, recurrence of HCC occurred in 2002, 5 years after the resection. A solitary tumor was detected in S7 of the liver, which was treated by percutaneous microwave coagulation therapy. The clinical course is shown [figure 1](#). Subsequent treatment of recurrence in both lobes with transarterial lipiodol chemoembolization (TACE) was performed on six occasions (2003, 2006, 2007, 2008, 2008 and 2009) and by the combination treatment of TACE and radiofrequency ablation in 2005, with clinical, analytical and imaging follow-up studies. The repeated intravascular chemoembolization caused severe vascular injury. The right hepatic artery became completely obstructed. Moreover, a narrow neovascularity from the gastroduodenal artery formed a collateral artery. Similarly, the left hepatic artery was strongly damaged and narrowed ([fig. 2](#)). Intravascular chemoembolization would have been difficult to perform after the last TACE in February 2009.

The Japanese Guidelines recommend that long-term IFN therapy should be considered for preventing HCC in patients with HCV-related cirrhosis [16]. However, IFN is expensive and has a number of serious side effects. Adverse events have a tendency to occur in elderly patients [18, 19]. Therefore, physicians often avoid IFN therapy in elderly patients because of side effects [20]. This was the situation in the current case. His serum HCV RNA level was 2.8 log IU/ml and serotype of HCV was 2. He was very concerned about the side effects of standard IFN. Therefore, he was treated with Peg-IFN, because standard IFN might have a more negative effect on his quality of life than Peg-IFN. Moreover, a previous paper reported that patients with low HCV RNA levels tend to eradicate HCV RNA with a low dose of IFN [21]. Therefore, super-low-dose Peg-IFN therapy (Peg-IFN- α 2b, 20 μ g/week) was started in February 2009 after providing the patient with detailed information regarding his condition and treatment, and after gaining his informed consent. Peg-IFN (a total of 1,240 μ g) was administered over an extended period. Serum ALT showed a tendency to decrease after Peg-IFN therapy was started, and it has remained within the normal range since March 2009. Moreover, HCV RNA has remained negative since April 2009 ([fig. 3](#)). No side effects such as flu-like symptoms occurred during the Peg-IFN treatment period. The clinical laboratory data are shown in [table 1](#). The most common side effect of Peg-IFN therapy is bone marrow suppression with leukopenia, thrombocytopenia and anemia. He did not have to withdraw the treatment due to this Peg-IFN side effect throughout this treatment. Moreover, this treatment had little effect on his daily life. He has been free from HCC recurrence for more than 20 months, even though IFN treatment was discontinued.

Discussion

Many patients with chronic hepatitis C infection are generally elderly. In addition, the age of HCV-related HCC patients has been increasing, with a peak around age 70 [22, 23]. Treatment of elderly patients with IFN is problematic. Nevertheless, a study concluded that elderly patients with genotype 2a and 2b should receive IFN therapy [20]. Moreover, a recent meta-analysis showed that IFN treatment after curative resection or ablation of

HCC in HCV-related cirrhotic patients prevents HCC recurrence and improves survival [24].

IFN therapy reduces the incidence of hepatocarcinogenesis in patients with HCV infection who achieve sustained virological response [25]. The inhibitory effect of IFN on development of HCC in patients with chronic hepatitis C aged 60 and over is limited to patients achieving sustained virological response following 6 months of IFN monotherapy [26]. Sustained prevention of HCC recurrence was accomplished when the current patient achieving sustained virological response.

Peg-IFNs have long elimination half-lives and steady serum concentrations that may prevent viral rebound between doses and reduce the risk of ‘escape mutants’ [27]. The super-low-dose Peg-IFN therapy which was administered to the current case may have contributed to the favorable outcome.

A nonrandomized retrospective study observed the beneficial effect of long-term natural IFN-alpha therapy on hepatocarcinogenesis in elderly chronic hepatitis C patients. This paper showed that the alpha-fetoprotein (AFP) baseline was decreased after initiation of IFN therapy in most patients. Moreover, the cumulative rate of HCC development in patients whose serum level of AFP was within normal limits after initiation of IFN therapy was lower than that of patients with a high level of AFP despite IFN therapy. This paper concluded that AFP was a suitable indicator in long-term IFN therapy for protecting against HCC [17]. In this case, the serum level of AFP had remained within the normal limits before the last TACE performance. Nevertheless, the tumor marker PIVKA II showed a tendency to decrease after Peg-IFN therapy was started in the current patient, and it has remained within normal limits. This is very important for the sustained prevention of HCC recurrence with Peg-IFN therapy as well.

The serum level of PIVKA II showed a slow decline to the normal range over 5 months. A previous paper demonstrated that IFN-alpha potentiated the apoptotic effect of TRAIL in human hepatoma cells by regulating the expression of DR5 or survivin and by repressing TRAIL-mediated NF- κ B activation [28]. This low-dose Peg-IFN therapy might induce the death and apoptosis of remaining HCC cells.

Fortunately, in patients with genotype 2 and low virus load, HCV RNA tends to be eradicated with a small dose of IFN [29–32]. Super-low-dose Peg-IFN therapy was administered over a long period at the request of our patient. His HCV RNA rapidly became negative. Generally, Peg-IFN is expensive and has a number of serious side effects. It is thus considered to be preferable to shorten the treatment period. A shorter period of Peg-IFN therapy should be considered in future studies.

In conclusion, this case report indicates that low-dose Peg-IFN administration may successfully inhibit hepatitis C-related HCC recurrence of elderly patients.

Table 1. Laboratory data of pre-TACE, post-1st, post-4th, post-24th and post-last IFN therapy

Characteristic	Pre-TACE	Post-1st IFN	Post-4th IFN	Post-24th IFN	Post-last IFN
HCV-RNA, log IU/ml	2.8	not checked	negative	negative	negative
AST, IU/l	45	31	21	21	21
ALT, IU/l	128	37	17	18	15
PIVKA II, mAU/ml	344	62	64	24	24
Hemoglobin, g/dl	13.4	14.1	12.9	13.0	12.4
Platelets, $\times 10^4$ /ml	18.2	12.5	13.8	12.1	13.9
WBC, ml	5,420	4,080	4,980	3,920	4,170

ALT = Alanine aminotransferase; AST = aspartate aminotransferase; HCV = hepatitis C virus; IFN = interferon; TACE = transarterial lipiodol chemoembolization; WBC = white blood cell count. Normal reference ranges under 40 mAU/ml for PIVKA II, 5–45 IU/l for ALT, 10–40 IU/l for AST.

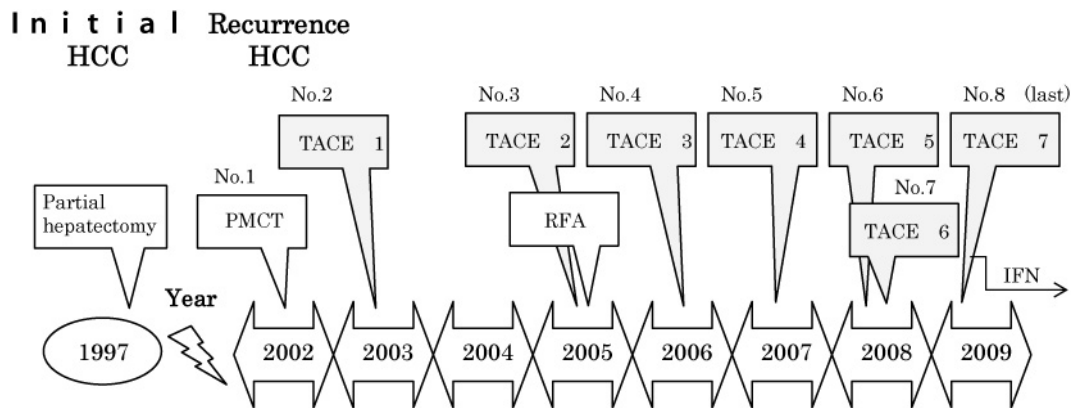


Fig. 1. Clinical course of the initial and recurrent HCC treatment. TACE = Transarterial lipiodol chemoembolization; PMCT = percutaneous microwave coagulation therapy; RFA = radiofrequency ablation.

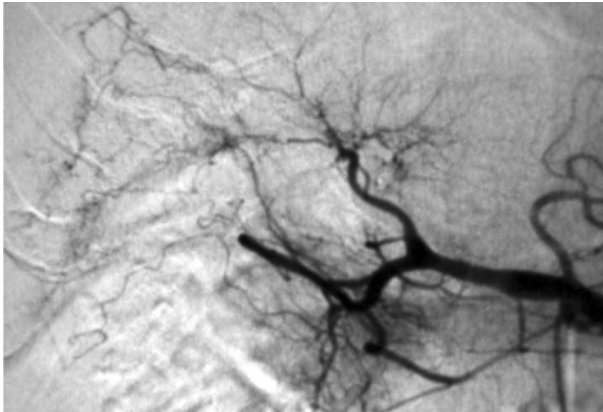


Fig. 2. Celiac arteriogram of last TACE showed severe vascular injury. The right hepatic artery had become completely obstructed. Moreover, a narrow neovascularity from the gastroduodenal artery formed a collateral artery. The left hepatic artery was severely damaged and narrowed.

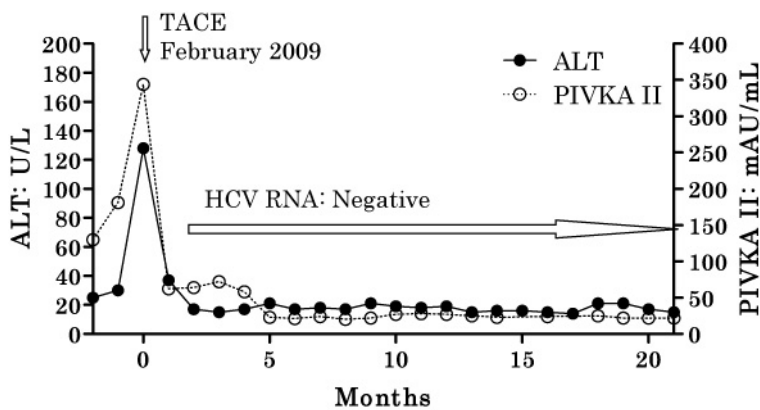


Fig. 3. Clinical course of super-low-dose Peg-IFN-alpha 2b therapy (20 µg/week, total 1,240 µg, 16 months). Starting month: February 2009.

References

- 1 Tanaka H, Tsukuma H, Kasahara A, et al: Effect of interferon therapy on the incidence of hepatocellular carcinoma and mortality of patients with chronic hepatitis C: a retrospective cohort study of 738 patients. *Int J Cancer* 2000;87:741–749.
- 2 Yoshida H, Arakawa Y, Sata M, Nishiguchi S, Yano M, Fujiyama S, Yamada G, Yokosuka O, Shiratori Y, Omata M: Interferon therapy prolonged life expectancy among chronic hepatitis C patients. *Gastroenterology* 2002;123:483–491.
- 3 Kasahara A, Tanaka H, Okanoue T, et al: Interferon treatment improves survival in chronic hepatitis C patients showing biochemical as well as virological responses by preventing liver-related death. *J Viral Hepat* 2004;11: 148–156.
- 4 Imai Y, Kasahara A, Tanaka H, et al: Interferon therapy for aged patients with chronic hepatitis C: improved survival in patients exhibiting a biochemical response. *J Gastroenterol* 2004;39:1069–1077.
- 5 Ikeda K, Saitoh S, Tsubota A, Arase Y, Chayama K, Kumada H, Watanabe G, Tsurumaru M: Risk factors for tumor recurrence and prognosis after curative resection of hepatocellular carcinoma. *Cancer* 1993;71:19–25.

- 6 Mazzaferro V, Romito R, Schiavo M, et al: Prevention of hepatocellular carcinoma recurrence with alpha-interferon after liver resection in HCV cirrhosis. *Hepatology* 2006;44:1543–1554.
- 7 Ikeda K, Arase Y, Saitoh S, Kobayashi M, Suzuki Y, Suzuki F, Tsubota A, Chayama K, Murashima N, Kumada H: Interferon beta prevents recurrence of hepatocellular carcinoma after complete resection or ablation of the primary tumor – a prospective randomized study of hepatitis C virus-related liver cancer. *Hepatology* 2000;32:228–232.
- 8 Suou T, Mitsuda A, Koda M, Matsuda H, Maruyama S, Tanaka H, Kishimoto Y, Kohno M, Hirooka Y, Kawasaki H: Interferon alpha inhibits intrahepatic recurrence in hepatocellular carcinoma with chronic hepatitis C: a pilot study. *Hepatol Res* 2001;20:301–311.
- 9 Kubo S, Nishiguchi S, Hirohashi K, Tanaka H, Shuto T, Kinoshita H: Randomized clinical trial of long-term outcome after resection of hepatitis C virus-related hepatocellular carcinoma by postoperative interferon therapy. *Br J Surg* 2002;89:418–422.
- 10 Lin SM, Lin CJ, Hsu CW, Tai DI, Sheen IS, Lin DY, Liaw YF: Prospective randomized controlled study of interferon-alpha in preventing hepatocellular carcinoma recurrence after medical ablation therapy for primary tumors. *Cancer* 2004;100:376–382.
- 11 Shiratori Y, Shiina S, Teratani T, Imamura M, Obi S, Sato S, Koike Y, Yoshida H, Omata M: Interferon therapy after tumor ablation improves prognosis in patients with hepatocellular carcinoma associated with hepatitis C virus. *Ann Intern Med* 2003;138:299–306.
- 12 Hung CH, Lee CM, Wang JH, Tung HD, Chen CH, Lu SN: Antiviral therapy after non-surgical tumor ablation in patients with hepatocellular carcinoma associated with hepatitis C virus. *J Gastroenterol Hepatol* 2005;20:1553–1559.
- 13 Sakaguchi Y, Kudo M, Fukunaga T, Minami Y, Chung H, Kawasaki T: Low-dose, long-term, intermittent interferon-alpha-2b therapy after radical treatment by radiofrequency ablation delays clinical recurrence in patients with hepatitis C virus-related hepatocellular carcinoma. *Intervirology* 2005;48:64–70.
- 14 Jeong SC, Aikata H, Katamura Y, et al: Effects of a 24-week course of interferon-alpha therapy after curative treatment of hepatitis C virus-associated hepatocellular carcinoma. *World J Gastroenterol* 2007;13:5343–5350.
- 15 Kudo M, Sakaguchi Y, Chung H, et al: Long-term interferon maintenance therapy improves survival in patients with HCV-related hepatocellular carcinoma after curative radiofrequency ablation. A matched case-control study. *Oncology* 2007;72(suppl 1):132–138.
- 16 Kumada H, Okanoue T, Onji M, et al: Guidelines for the treatment of chronic hepatitis and cirrhosis due to hepatitis C virus infection for the fiscal year 2008 in Japan. *Hepatol Res* 2010;40:8–13.
- 17 Arase Y, Ikeda K, Suzuki F, et al: Prolonged interferon therapy reduces hepatocarcinogenesis in aged patients with chronic hepatitis C. *J Med Virol* 2007;79:1095–1102.
- 18 Okanoue T, Sakamoto S, Itoh Y, et al: Side effects of high-dose interferon therapy for chronic hepatitis C. *J Hepatol* 1996;25:283–291.
- 19 Arase Y, Suzuki F, Suzuki Y, et al: Side effects of combination therapy of peginterferon and ribavirin for chronic hepatitis C. *Intern Med* 2007;46:1827–1832.
- 20 Arase Y, Suzuki F, Sezaki H, et al: The efficacy of interferon-beta monotherapy for elderly patients with type C hepatitis of genotype 2. *Intern Med* 2009;48:1337–1342.
- 21 Kawamura Y, Arase Y, Ikeda K, et al: The efficacy of short-term interferon-beta therapy for chronic hepatitis C patients with low virus load. *Intern Med* 2008;47:355–360.
- 22 Yoshizawa H: Hepatocellular carcinoma associated with hepatitis C virus infection in Japan: projection to other countries in the foreseeable future. *Oncology* 2002;62(suppl 1):8–17.
- 23 Tanaka H, Imai Y, Hiramatsu N, et al: Declining incidence of hepatocellular carcinoma in Osaka, Japan, from 1990 to 2003. *Ann Intern Med* 2008;148:820–826.
- 24 Singal AK, Freeman DH Jr, Anand BS: Meta-analysis: interferon improves outcomes following ablation or resection of hepatocellular carcinoma. *Aliment Pharmacol Ther* 2010;32:851–858.
- 25 Hirakawa M, Ikeda K, Arase Y, et al: Hepatocarcinogenesis following HCV RNA eradication by interferon in chronic hepatitis patients. *Intern Med* 2008;47:1637–1643.
- 26 Imai Y, Tamura S, Tanaka H, et al: Reduced risk of hepatocellular carcinoma after interferon therapy in aged patients with chronic hepatitis C is limited to sustained virological responders. *J Viral Hepat* 2010;17:185–191.
- 27 Sharieff KA, Duncan D, Younossi Z: Advances in treatment of chronic hepatitis C: ‘pegylated’ interferons. *Cleve Clin J Med* 2002;69:155–159.
- 28 Shigeno M, Nakao K, Ichikawa T, et al: Interferon-alpha sensitizes human hepatoma cells to TRAIL-induced apoptosis through DR5 upregulation and NF-kappa B inactivation. *Oncogene* 2003;22:1653–1662.
- 29 Dalgard O, Mangia A: Short-term therapy for patients with hepatitis C virus genotype 2 or 3 infection. *Drugs* 2006;66:1807–1815.

- 30 Tabaru A, Narita R, Hiura M, Abe S, Otsuki M: Efficacy of short-term interferon therapy for patients infected with hepatitis C virus genotype 2a. *Am J Gastroenterol* 2005;100:862–867.
- 31 Sato Y, Tokue H, Kawamura N, Nezu-Yajima S, Nakajima H, Ishida H, Takahashi S: Short-term interferon therapy for chronic hepatitis C patients with low viral load. *Hepatogastroenterology* 2004;51:968–972.
- 32 Fujiyama S, Chikazawa H, Honda Y, Tomita K: Effective interferon therapy for chronic hepatitis C patients with low viral loads. *Hepatogastroenterology* 2003;50:817–820.