

## Original Article

## External cortical landmarks for localization of the hippocampus: Application for temporal lobectomy and amygdalohippocampectomy

R. Shane Tubbs, Marios Loukas<sup>1</sup>, Nicholas M. Barbaro<sup>2</sup>, Kushal J. Shah<sup>2</sup>, Aaron A. Cohen-Gadol<sup>2</sup>

Seattle Science Foundation, Seattle, Washington, <sup>1</sup>Department of Anatomic Sciences, St. George's University School of Medicine, St. George's, Grenada, <sup>2</sup>Goodman Campbell Brain and Spine, Department of Neurological Surgery, Indiana University School of Medicine, Indianapolis, Indiana, USA

E-mail: R. Shane Tubbs - shanet@seattlesciencefoundation.org; Marios Loukas - mloukas@sgu.edu; Nicholas M. Barbaro - nbarbaro@goodmancampbell.com; Kushal J. Shah - kshah@goodmancampbell.com; \*Aaron A. Cohen-Gadol - acohenmd@gmail.com

\*Corresponding author

Received: 27 November 17 Accepted: 20 June 18 Published: 22 August 18

### Abstract

**Background:** Accessing the hippocampus for amygdalohippocampectomy and minimally invasive procedures, such as depth electrode placement, require an accurate knowledge regarding the location of the hippocampus.

**Methods:** The authors removed 10 human cadaveric brains from the cranium and observed the relationships between the lateral temporal neocortex and the underlying hippocampus. They then measured the distance between the hippocampus and superficial landmarks. The authors also validated their study using magnetic resonance imaging (MRI) scans of 10 patients suffering from medial temporal lobe sclerosis where the distance from the hippocampal head to the anterior temporal tip was measured.

**Results:** In general, the length of the hippocampus was along the inferior temporal sulcus and inferior aspect of the middle temporal gyrus. Although the hippocampus tended to be more superiorly located in female specimens and on the left side, this did not reach statistical significance. The length of the hippocampus tended to be shorter in females, but this too failed to reach statistical significance. The mean distance from the anterior temporal tip to the hippocampal head was identical in the cadavers and MRIs of patients with medial temporal lobe sclerosis.

**Conclusions:** Additional landmarks for localizing the underlying hippocampus may be helpful in temporal lobe surgery. Based on this study, there are relatively constant anatomical landmarks between the hippocampus and overlying temporal cortex. Such landmarks may be used in localizing the hippocampus during amygdalohippocampectomy and depth electrode implantation in verifying the accuracy of image-guided methods and as adjuvant methodologies when these latter technologies are not used or are unavailable.

**Key Words:** Anatomy, epilepsy surgery, hippocampectomy, landmarks, neurosurgery, temporal lobe

#### Access this article online

**Website:**

[www.surgicalneurologyint.com](http://www.surgicalneurologyint.com)

**DOI:**

10.4103/sni.sni\_446\_17

**Quick Response Code:**

This is an open access journal, and articles are distributed under the terms of the Creative Commons Attribution-NonCommercial-ShareAlike 4.0 License, which allows others to remix, tweak, and build upon the work non-commercially, as long as appropriate credit is given and the new creations are licensed under the identical terms.

For reprints contact: [reprints@medknow.com](mailto:reprints@medknow.com)

**How to cite this article:** Tubbs RS, Loukas M, Barbaro NM, Shah KJ, Cohen-Gadol AA. External cortical landmarks for localization of the hippocampus: Application for temporal lobectomy and amygdalohippocampectomy. *Surg Neurol Int* 2018;9:171.

<http://surgicalneurologyint.com/External-cortical-landmarks-for-localization-of-the-hippocampus:-Application-for-temporal-lobectomy-and-amygdalohippocampectomy/>

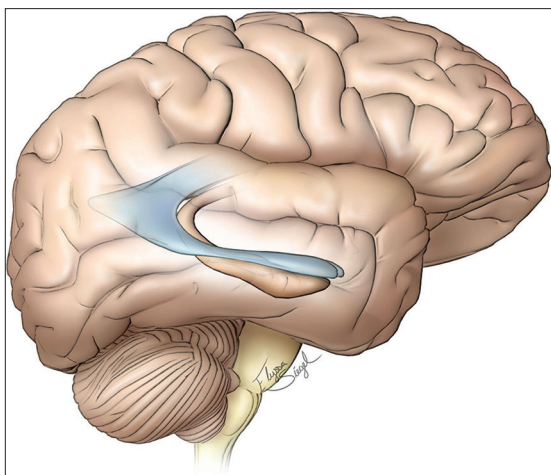
## INTRODUCTION

Even with advancements in the pharmacological treatment of epilepsy, there is still a group of patients whose seizures have a higher tendency to be refractory to medical therapy. Medial temporal lobe epilepsy is often caused by medial temporal lobe sclerosis or lesional epileptogenic foci within the amygdala and hippocampal formation. The hippocampus and surrounding formation are made up of the cornu ammonis (hippocampus proper), subiculum, dentate gyrus, supracallosal gyrus, alveus, fimbria, and fornix.<sup>[2,4]</sup> Traditionally attributed to the formation and storage of memory, manipulation of the dominant hippocampal formation may result in cognitive and memory dysfunction after surgery.<sup>[5-7]</sup>

Anterior temporal lobectomy with amygdalohippocampectomy has proven efficacious for cessation of intractable seizures of medial temporal lobe origin. Aggressive resection of these medial temporal lobe structures has been associated with improved surgical outcomes.<sup>[10]</sup> Here, we have attempted to study more precise superficial anatomical landmarks to guide the surgeon to the deeper lying hippocampus [Figure 1]. Such landmarks can be used to refine or verify the accuracy of intraoperative image-guidance, and especially when such navigation is not used or is unavailable.

## MATERIALS AND METHODS

Ten formalin-fixed cadaveric brains (20 hemispheres) were removed from the craniums. The specimens were derived from 6 male and 4 female cadavers aged 35 to 75 years (mean 65 years) at death. Brains were next hemisected in the midline and the fornix identified and followed toward the left and right hippocampus. Once the hippocampus was isolated from a mesial approach, 6-cm long straight needles were placed into its head,



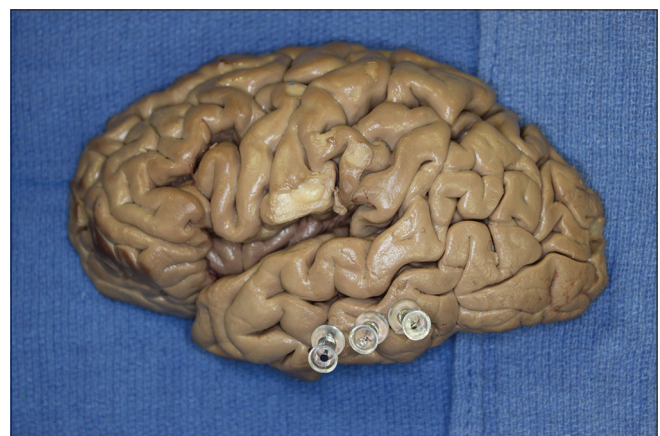
**Figure 1:** The relationship of right hippocampus and temporal horn to the superficial structures. Copyright, *The Neurosurgical Atlas*, used with permission

tail, and the midpoint between these structures, and passed laterally in the axial plane until they reached the cortical surface. The specimens were then turned and pin exit sites were marked externally using smaller pins [Figures 2 and 3]. The pia and arachnoid mater had been previously removed to better visualize the cortical surface. Measurements between the outer temporal lobe cortical landmarks (sulci and gyri) and the underlying hippocampus (both its head and tail) were then made with digital calipers (Mitutoyo, Japan). Axial sections through the overlying cortex were made with the hippocampus intact to verify the overlying relationships [Figure 4]. Statistical analysis between sides and gender were made using Statistica 12 (Tulsa, OK) with statistical significance set at  $P < 0.05$ .

The authors also validated their study using magnetic resonance imaging (MRI) scans of 10 patients suffering from medial temporal lobe sclerosis. Axial, coronal, and sagittal MRI scans were used to localize the head of the hippocampus on the affected side based on superficial landmarks. Reference lines from the PACS (Picture Archiving and Communication System) software allowed localization of the head of the hippocampus on the sagittal series where the distance from the anterior temporal tip to the head of the hippocampus was measured and recorded.

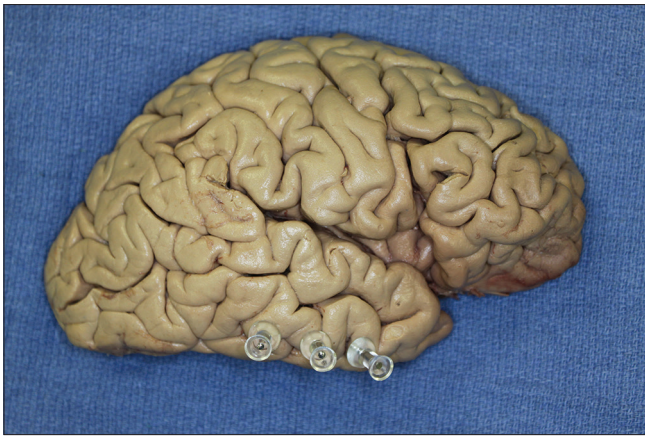## RESULTS

We did not observe any gross intracranial pathology or evidence of previous surgery in any specimen. The distance from the tip of the temporal lobe to the head of the hippocampus ranged from 3.5 to 4.3 cm (mean 3.8 cm) [Figures 2-6]. The distance from the tip of the temporal lobe to the junction of the fornix with the hippocampus ranged 6–6.7 cm (mean, 6.5 cm) [Figures 2, 3, 5, and 6]. The distance between the tail and head of the hippocampus ranged 3–4.1 cm (mean, 3.5 cm) [Figures 5 and 6]. The head of the

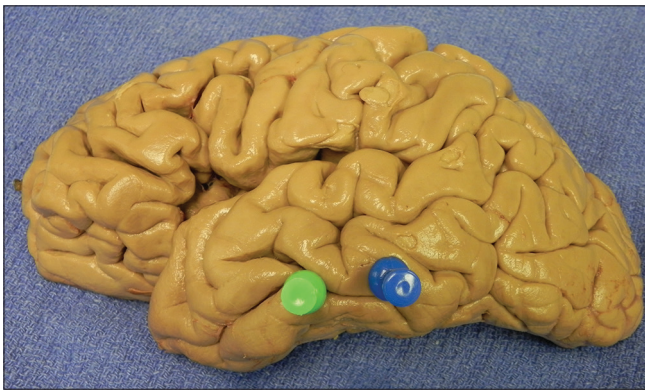

**Figure 2:** Left hemisphere with pins noting the anterior, middle, and posterior parts of the hippocampus





**Figure 3: Right hemisphere with pins noting the anterior, middle, and posterior parts of the hippocampus**

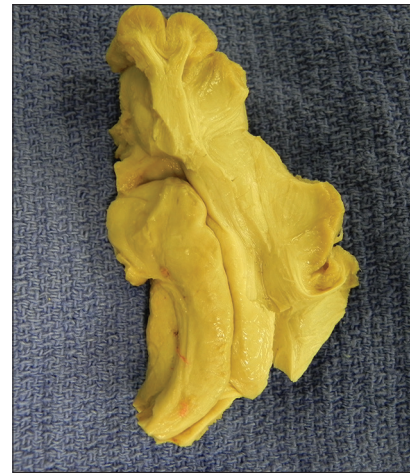

**Figure 5: Left hemisphere with pins marking the head and tail of the hippocampus. Here, the head (anterior pin) is seen at the level of the inferior temporal sulcus and the tail (posterior pin) is seen at the level of the lower part of the middle temporal gyrus**

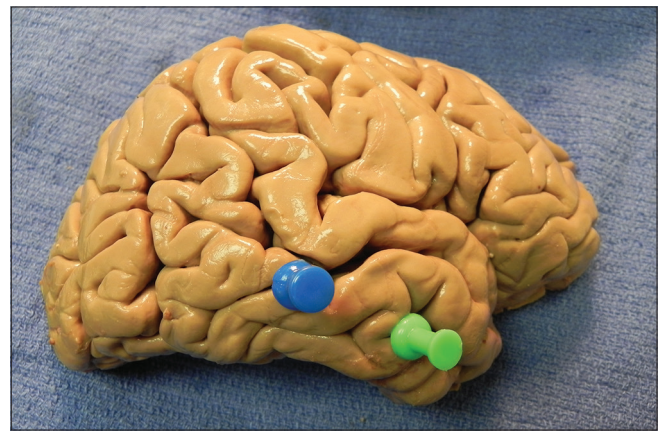
hippocampus ranged 0–5 mm inferior to the inferior temporal sulcus. The tail of the hippocampus ranged 2.2–7 mm superior to the inferior temporal sulcus.

In two right-sided specimens, the tail was deep to the superior temporal sulcus [Figure 6]. In general, the length of the hippocampus was along the inferior temporal sulcus and inferior aspect of the middle temporal gyrus. From anterior to posterior, the hippocampus always sloped upward. No statistical difference for these measurements was noted between the left and right sides. Although the hippocampus tended to be more superiorly located in female specimens and on left, this did not reach statistical significance. In addition, the length of the hippocampus tended to be shorter in females, but this also failed to reach statistical significance.

MRI scans of patients suffering from medial temporal lobe sclerosis were evaluated and the distance from the hippocampal head to the anterior temporal tip was recorded on the sagittal axis. The lengths varied from 3.3 cm to 4.2 cm (mean, 3.8 cm) [Figure 7; Table 1]. This mean length was identical to our cadaveric measurements.



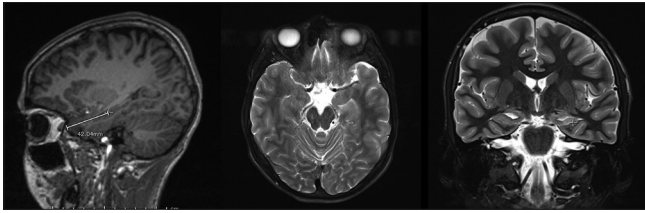
**Figure 4: Axial section through the right temporal lobe for verification of outer cortical landmarks to internally positioned hippocampus**



**Figure 6: Right hemisphere with pins marking the head and tail of the hippocampus. In this specimen, the head (anterior pin) of the hippocampus is deep to the inferior temporal sulcus. However, the tail (posterior pin) is located in the superior temporal sulcus**

## DISCUSSION

Localization of the hippocampus in relation to superficial structures is important for exposing the hippocampus during anteromedial temporal lobectomy and amygdalohippocampectomy procedures while minimizing the extent of neocortical resection, especially on the dominant hemisphere. Furthermore, intraoperative depth electrodes placed within the hippocampus can provide useful information regarding the relative epileptogenicity of this medial structure versus the temporal neocortex. Therefore, it is important to localize the hippocampus as accurately as possible using all the available data, including image guidance and surface landmarks. In our study, we found that the inferior temporal sulcus and middle temporal gyrus were relatively constant landmarks to the underlying hippocampus. In addition, and within approximately a centimeter, the length of the hippocampus was similar in length between sides and genders.



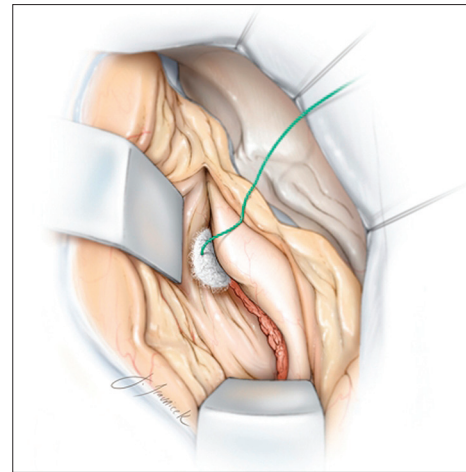
**Figure 7:** Sagittal, axial, and coronal sequences were used to identify the anatomical landmarks. Using the IntelliLink tool, the hippocampal head was marked on the axial plane and that position was identified on the sagittal plane. A measurement was taken from the anterior temporal tip to the hippocampal head and recorded

### Surgical anatomy

The hippocampus sits in the medial part of the temporal lobe and on the floor of the temporal horn of the lateral ventricle. The amygdala is situated anterior and superior to the head of the hippocampus. The uncus, which is part of the entorhinal cortex, wraps around the inferior border of the hippocampus and appears as a continuous homogeneous ovoid mass with the amygdala on MRI.<sup>[5]</sup> The hippocampal head, or pes hippocampus, emerges from the temporal horn of the lateral ventricle and can be recognized from the body by its “digitations hippocampi.” The head is usually 1.5 to 2 cm wide<sup>[9]</sup> and tapers into the hippocampal body, becoming roughly 1 cm wide on average.<sup>[1]</sup> The body of the hippocampus is further subdivided into intraventricular and extraventricular parts. The intraventricular part is the floor of the temporal horn. Its convex shape is smooth compared to the head with its digitations. The medial and lateral borders of the intraventricular part are the fimbria and narrow collateral eminence, respectively.

### Applications for selective amygdalohippocampectomy and depth electrode placement

The data presented about the localization of the head of the hippocampus 3–4 cm from the anterior temporal tip may have important implications regarding the extent of temporal neocortical resection necessary to perform an amygdalohippocampectomy. Based on the above data, a 3–4 cm anteromedial temporal neocortical resection will be adequate to expose the anterior aspect of the hippocampus. If a localized lesion is present along this anterior region, further neocortical resection will not be necessary. However, if an extensive hippocampectomy for medial temporal lobe sclerosis is contemplated, disconnection of the occipitotemporal fasciculus along the lateral aspect of the hippocampus will allow lateral mobilization of the temporal cortex (instead of its resection) to provide enough exposure to allow for a posterior hippocampectomy [Figure 8]. Furthermore, based on these data, resection of the superior temporal gyrus is not necessary for exposure of the ventricle. Finally, a corticotomy within the middle temporal gyrus, along the mid portion of the temporal lobe, will expose the ventricle [Figure 7]. It should be noted



**Figure 8:** Disconnection of the occipitotemporal fasciculus along the lateral aspect of the hippocampus will allow lateral mobilization the temporal cortex (instead of its resection), to provide enough exposure to allow for a posterior hippocampectomy. A corticotomy within the middle temporal gyrus, along the mid portion of the temporal lobe, will expose the ventricle. Copyright, *The Neurosurgical Atlas*, used with permission

**Table 1: MRI measurements of MTLs anterior temporal tip to hippocampal head**

Patient Number	Laterality	Anterior temporal tip to hippocampal head length (cm)
1	Left	4.2
2	Left	3.8
3	Right	3.8
4	Right	3.8
5	Left	3.5
6	Right	3.7
7	Right	3.3
8	Right	3.8
9	Left	3.8
10	Left	3.8
	Average	3.8 cm

that the measurements taken in these specimens were not from individuals with known temporal lobe pathology or epilepsy syndromes. In mesial temporal sclerosis, the most common pathological finding in temporal lobe epilepsy, the hippocampus is slightly smaller in diameter than in normal patients. This change may not significantly affect the anteroposterior measurements presented here. In our study, MRI measurements were similar to our cadaveric dimensions.

In a study by Davies *et al.*,<sup>[3]</sup> electrodes were placed into the hippocampus within the middle temporal gyrus at a depth of 3.5 cm. Therefore, the surgeon may use the freehand technique to insert depth electrodes at a distance of 3–4 cm from the temporal tip through and perpendicular to the inferior temporal gyrus to reach the anterior hippocampus. A second electrode may be placed 6–7 cm posteriorly to evaluate the electrical activity in

the posterior hippocampus. Placement of the electrodes through the middle temporal gyrus, as previously advised,<sup>[8]</sup> may insert the electrodes within the ventricle and avoid accurate recording from the medial structures.

## CONCLUSIONS

We performed the above cadaveric study to better identify the relationships between the outer temporal cortex and the deeper lying hippocampus. Such landmarks may be useful to neurosurgeons in localizing the hippocampus in conjunction with or to verify imaged-guided technologies or when these devices are not used or are unavailable.

## Financial support and sponsorship

Nil.

## Conflicts of interest

There are no conflicts of interest.

## REFERENCES

1. Ayberk G, Yagli OE, Comert A, Esmer AF, Canturk N, Tekdemir I, et al. Anatomic relationship between the anterior sylvian point and the pars triangularis. *Clin Anat* 2012;25:429-36.
2. Bronen RA, Cheung G. Relationship of hippocampus and amygdala to coronal MRI landmarks. *Magn Reson Imaging* 1991;9:449-57.
3. Davies KG, Phillips BLB, Hermann BP. MRI confirmation of accuracy of freehand placement of mesial temporal lobe depth electrodes in the investigation of intractable epilepsy. *Br J Neurosurg* 1996;10:175-8.
4. Duvernoy HM, Cattin F, Naidich TP, Fatterpekar G, Raybaud C, Risold PY, et al. *The Human Hippocampus*. Berlin Heidelberg: Springer-Verlag; 2005.
5. Naidich TP, Daniels DL, Haughton VM, Williams A, Pojunas K, Palacios E. Hippocampal formation and related structures of the limbic lobe: Anatomic-MR correlation. Part I. Surface features and coronal sections. *Radiology* 1987;162:747-54.
6. Siadat MR, Soltanian-Zadeh H, Elisevich KV. Knowledge-based localization of hippocampus in human brain MRI. *Comput Biol Med* 2007;37:1342-60.
7. Sindou M, Guenet M. Surgical anatomy of the temporal lobe for epilepsy surgery. *Adv Tech Stand Neurosurg* 2003;28:315-43.
8. Van Gompel JJ, Meyer FB, Marsh WR, Lee KH, Worrell GA. Stereotactic electroencephalography with temporal grid and mesial temporal depth electrode coverage: Does technique of depth electrode placement affect outcome? *J Neurosurg* 2010;113:32-8.
9. Wen HT, Rhoton AL, de Oliverira E, Cardoso ACC, Tedeschi H, Baccanelli M, et al. Microsurgical anatomy of the temporal lobe: Part I: Mesial temporal lobe anatomy and its vascular relationships as applied to amygdalohippocampectomy. *Neurosurgery* 1990;45:549-92.
10. Wyler AR, Hermann BP, Somes G. Extent of medial temporal resection on outcome from anterior temporal lobectomy: A randomized prospective study. *Neurosurgery*. 1995;37:982-90.