

INTRARENAL COMPLEMENT FIXATION BY CYTOTOXIC ANTIBODIES*

BY D. SELLIN, M.D., M. KÖVARY, U. ROTHER, M.D. AND K. ROTHER, M.D.

(From the Max-Planck-Institute of Immunobiology, DFG-Forschungsgruppe Rother, 7800 Freiburg/Br., Germany)

(Received for publication 29 April 1970)

The rejection of allografted tissue is thought to be mediated by cellular immune mechanisms. Over the last years, however, increasing evidence has accumulated indicating that humoral mechanisms also participate in the destructive process. Serum antibodies to histocompatibility antigens of the grafted tissue are regularly found in response to allografts in mice (1), rats (2), dogs (3), rabbits (4), or in the human (5-7). Such cytotoxic antibodies are readily demonstrable *in vitro* by the cytotoxicity test (8). An increasing body of evidence suggests that cytotoxic antibodies may also react with donor tissue *in vivo* and may be involved in the rejection reaction (9). From rejected dog kidney allografts antibodies could be eluted which fixed serum complement (C)¹ in the presence of a kidney tissue homogenate *in vitro* (10). From results obtained with C-deficient rabbits (11) and mice (12, 13) it was recently proposed that the tissue fixation of such cytotoxic antibodies may initiate the activation of serum C and that the participation of C may contribute to the rejection reaction (11). The contribution of the biological activities of the C factors in the destruction of the grafts was believed to be only of marginal pathological significance in most cases, and to become decisive only in some host-donor combinations.

The antibody mediated C activation is well known to initiate the tissue damage in other immune lesions, such as glomerulonephritis or the Arthus reaction. While the participation of antibody and C was documented by morphological evidence of the localization of the immune globulins in these tissue lesions (14-17) attempts to trace antibody or C deposits in rejected allografts up to now were either unsuccessful (18) or the results were equivocal (19). When immune globulin deposition was found in rejected tissue (20-22), the experimental design did not exclude a participation of cellular elements in the chain of events. An additional interpretational difficulty arose in the case of immune deposits in rejected human kidney transplants (23-29). The basic disease of the recipients was mostly glomerulonephritis which by itself is characterized by immune

* Supported by the Deutsche Forschungsgemeinschaft.

¹ Abbreviations used in this paper: C, serum complement; PBS, phosphate buffered saline; FITC, fluorescein-isothiocyanate.

globulin deposition in the nephritic kidney (30). In view of this criticism, in the present study a short term model was developed to investigate the reactivity of preformed serum immune globulins and transplant. We expect to show by morphological means the interaction *in vivo* of rat isoantibodies to histocompatibility antigens with donor kidney tissue and the activation of C at similar sites.

Materials and Methods

Choice of Animals.—Preliminary experiments² were performed on rabbits. While cytotoxic antisera underwent a significant loss of titer upon perfusion through a donor kidney, attempts to demonstrate the possible localization of the immunoglobulin within the organ failed. This may have been due to the relatively low cytotoxic antibody response in the rabbit. Hence rats were used for the following experiments. Rats readily form antibodies to histocompatibility antigens and are still large enough for convenient kidney surgery. Inbred strains of Lewis and DA rats of either sex and of 100–150 g body weight were kindly supplied by Dr. Irmgard Zeiss of this institute. The two inbred strains have a strong histocompatibility difference at the AgB locus (31).

Cytotoxic Antisera were produced by placing $\frac{3}{4}$ inch square suprapannicular skin grafts from members of one strain of rats onto members of the other. The animals were boosted 21 days later by the injection of donor spleen cells in Freund's complete adjuvant into the footpads. The animals were bled another 14 days later. The sera were pooled and stored at -70°C .

Cytotoxic Test.—Lymph node cells of the donor strain were suspended in medium 199 to a concentration of 5×10^6 cells per ml. Of this suspension, 0.05 ml was incubated at 37°C for 20 min with 0.05 ml of the antibody containing serum at various dilutions. After addition of 0.05 ml rabbit C of a 1:4 dilution, the tubes were reincubated for 30 min. Percentage of lysed cells was counted under the microscope after staining with 0.15 ml of a 1:1000 trypan blue solution. At serum dilutions in the range of 1:800, 50% lysis was achieved. Care was taken to use for source of C the serum of an individual rabbit which was known to be free of natural antibodies to mouse cells.

Perfusion of the Kidneys with Cytotoxic Antisera.—Rats were anesthetized and the kidneys were exposed *in situ*. The aorta was cannulated below the renal arteries with a No. 1 needle and was then ligated below the needle and above the renal arteries. The left v. renalis was incised and the perfusion started by light pressure with a syringe attached to the needle. The temperature of the perfusate and of the kidneys was kept at 37°C during the entire period of the perfusion. Cytotoxic rat serum (5 ml each) of different dilutions in phosphate-buffered saline (PBS; 0.15 M; pH 7.2) was infused within 2 min, followed by 10 ml of normal isologous rat serum as an additional source of C. The kidneys were then removed and left at 37°C for another 5 min after which they were frozen in a dry ice-acetone mixture and stored at -70°C .

Control Perfusion.—The perfusion technique presupposes that all elements of the kidney are reached by the perfusate. To verify this, China ink (Gunter Wagner, Hannover, Germany) at a dilution of 1:100 in saline was perfused through the kidney instead of the antiserum. The ink particles were found evenly distributed throughout the organ (Fig. 1).

Fluorescent Rabbit-Anti-Rat Gamma Globulin (Cappel Laboratories, Downingtown, Pa.) was

² The authors are indebted to Drs. P. Nathan, D. Ballantyne, Jr., and Ch. G. Cochrane for their valuable help and advice.

checked for specificity by immunoelectrophoresis, using normal rat serum, rat γ -globulin or rat serum albumin respectively as antigens.

Rabbit Antiserum to Rat Serum Albumin was prepared by immunization with the isolated albumin fraction of rat serum. Isolation of albumin was achieved by the ammonium sulfate

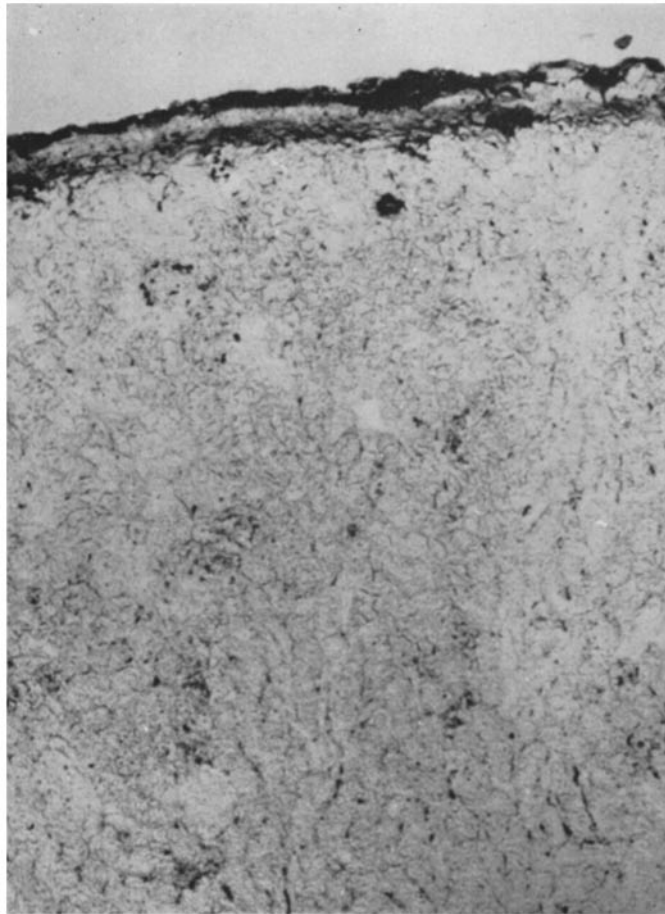


FIG. 1. DA rat kidney perfused with a 1:100 dilution of China ink in PBS. The distribution of the ink particles indicates an even flow of the perfusate through the vasculature. Cryostat section, nonstained; $\times 100$.

method (32), followed by preparative zone electrophoresis on pevicon (33). The specificity of the antiserum was confirmed by immunoelectrophoresis using normal rat serum as antigen.

Anti-rat β_{1C} Serum was prepared in ducks according to Mardiney and Mueller-Eberhard (34). The specificity of the antiserum was ascertained by the Ouchterlony technique and by immunoelectrophoresis, again using normal rat serum as antigen.

Conjugation of Gamma Globulin to Fluorescein-Isothiocyanate (FITC).—To prepare a fluorescent γ -globulin fraction of the anti- β_{1C} serum and of the anti-albumin serum, the γ -globulins of the antisera were precipitated by ammonium sulfate at 40%. They were then conjugated to FITC following the method of Wood et al. (35). For control purposes, normal duck serum γ -globulin was similarly treated.

Histology.—Frozen kidney sections were prepared in three ways: (a) a section of each kidney was stained with hematoxylin and eosin. (b) cryostat sections of 5 μ thickness were air dried and rehydrated in PBS. (c) in another series, sections were first fixed in ethanol and then treated as in step (b). The sections (b) and (c) were covered with the fluorescent γ -globulin fraction of the antisera and incubated at room temperature for 30 min in a moist chamber. The sections were then gently washed four times for 5 min in PBS and mounted in glycerine-saline (1:10).

Fluorescence Microscopy.—A Zeiss standard Universal microscope was used with dark-field condenser (aperture 1.2/1.4) and a mercury super pressure lamp (HBO 200, Osram, Berlin, Germany). For filtration, a BG 38 filter was employed and a BG 12 exciter filter in connection with barrier filters 53 and 44 (Schott u Gen., Mainz, Germany) was used.

Photomicrographs—were taken on a high speed black and white panchromatic film (Ilford HP 4, ASA 400, Ilford Ltd., Ilford, Essex, England).

Control Procedures.—Controls for the binding specificity of the fluorescent gamma globulins were set up as follows: (a) normal rat kidneys were subjected to the fluorescent staining procedure; (b) DA kidneys were perfused with normal Lewis serum and Lewis kidneys with normal DA serum after which tissue sections were prepared and stained; (c) sections of kidneys perfused with cytotoxic antisera were covered with fluorescent rabbit-antirat albumin or with fluorescent normal duck γ -globulin; (d) sections of kidneys perfused with cytotoxic antisera were covered with nonfluorescent specific antibody to β_{1C} protein, and then treated with the fluorescent anti- β_{1C} globulin; (e) fluorescent antiserum to β_{1C} protein was absorbed by incubation with zymosan-adsorbed rat β_{1C} . The mixture was then centrifuged and the supernatant antiserum placed on sections of perfused kidneys. Aside from the normal autofluorescence of the tissue constituents, none of the controls showed positive fluorescence.

RESULTS

The kidney perfusion technique was employed as a short term model of allograft rejection to study the possible humoral mechanisms involved in the rejection process. The technique assures the absence of cell-mediated influences: DA rat kidneys were perfused *in situ* with Lewis serum containing cytotoxic antibodies to DA tissue and vice versa. Cryostat sections were made from the kidneys immediately after perfusion and stained with fluorescent anti-rat kidney γ -globulin or anti-rat β_{1C} respectively.

Light Microscopy.—No tissue damage due to anoxia or excessive perfusion pressure was seen in the sections of perfused kidneys.

A conspicuous finding was seen following perfusion of the kidneys with antisera against histocompatibility antigens. The endothelial cells of the intima of the vessels were enlarged and the nuclei protruded into the lumen (Fig. 2). The changes were accompanied by a slight edema of the entire thickness of the vessel wall. The localization of the lesions corresponded to the deposits of γ -globulin and of β_{1C} protein (see below). The pathological alterations were never observed

in control kidneys perfused with normal isologous serum or with isologous antiserum containing cytotoxic antibodies against the respective other strain.

Tissue Localization of the Cytotoxic Antibodies.—Cytotoxic antibodies were formed by DA and by Lewis rats in response to skin grafting followed by the injection of spleen cells from the respective other strain. When the antisera were perfused through the kidneys of members of the donor strain, rat γ -globulins,

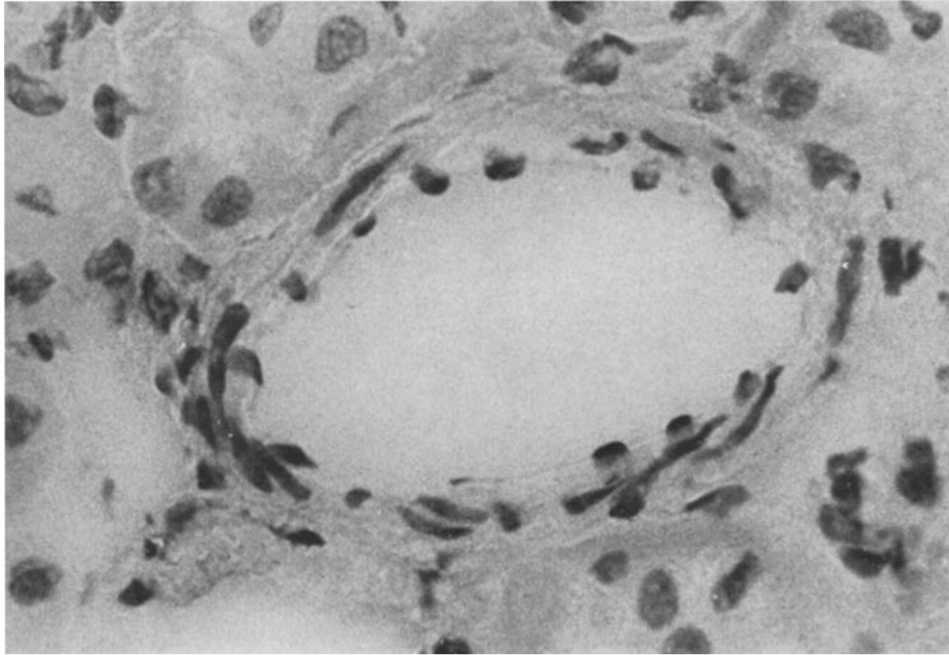


FIG. 2. DA rat kidney perfused with 5 ml of Lewis-anti-DA cytotoxic serum followed by 10 ml of normal Lewis serum as an additional source of complement. Note enlargement of endothelial cells of the arteriole with protrusion of the nuclei and slight edema of the vessel wall. Unaltered tubuli. Cryostat section; 5 μ ; hematoxylin and eosin; \times 500.

the presumed transplantation antibodies, localized in the tissue. They were demonstrable by means of a fluorescent antiserum against rat γ -globulin (Fig. 3). The observations including the controls are summarized in Table I.

The specific bright green fluorescence thought to represent antibodies was typically localized in the large and medium sized arteries and less intense fluorescence was found in the arterioles. The vessels were evenly delineated by the fluorescence. In some cases there was also a diffuse imbibition of the vessel walls (Fig. 3). Some cells and especially some of those located towards the lumen, showed a bright fluorescent cytoplasm. Other authors have described in ne-

phritic conditions a localization of the immune globulin almost exclusively in the glomeruli (reviewed in reference 36). In sharp contrast our experimental results indicated that the immune globulins of cytotoxic sera were localized primarily in the large vessels.

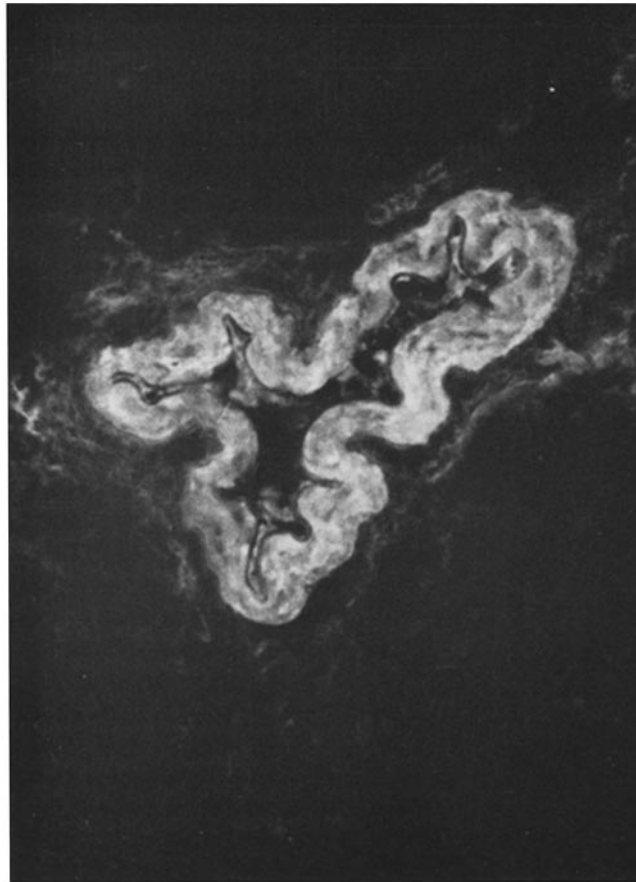


FIG. 3. DA kidney as in Fig. 2. A bright fluorescence of the arterial intima is seen upon staining with a fluorescein-conjugated antiserum to rat γ -globulin. In this case, fluorescence is also seen throughout the thickness of the vessel wall. Cryostat section; 5 μ ; \times 200.

Tissue Localization of Complement Protein.—When cytotoxic antibodies react with donor histocompatibility antigens in vitro, the immune complexes are known to initiate the reaction sequence of the serum C system (37, 38). The possible activation of C by similar complexes, such as those demonstrated above, under the present conditions was investigated by use of a fluorescent

antibody to rat β_{1C} globulin. The latter protein is known to be associated with the activity of the third component of C (C3) (39). In the perfused kidneys, C-specific fluorescence upon staining with anti- β_{1C} was seen at sites congruent with those of the gamma globulin deposits (Figs. 3 and 4). Typically, the distribution of the fixed C protein was confined to the arterial vascular system including the arterioles of the intertubular region. Some larger veins were also involved. In general, the fluorescence was brighter in the larger vessels when compared with the smaller ones. In Figs. 5 and 6 the same kidney is depicted showing a large

TABLE I
Tissue Localization of Rat γ -Globulin and of β_{1C} Protein Following Perfusion of Rat Kidneys with Isologous Cytotoxic Antisera

No. of DA rats*	Perfusion of kidneys with	
	(a) cytotoxic Lewis serum (5 ml)	(b) plus normal Lewis serum (10 ml)
<i>1. Positive staining observed</i>		
2	Undiluted	Undiluted
1	Undiluted	1:5
5	1:5	1:5
2	1:10	1:10
No. of DA rats*	Perfusion of kidneys with	
	(a) DA serum, cytotoxic to Lewis rats (5 ml)	(b) normal Lewis serum (10 ml)
<i>2. Negative staining (controls†)</i>		
1	Undiluted	Undiluted
1	—	Undiluted
1	—	1:5
2	—	1:5

* Similar observations including those of the controls were made when Lewis rat kidneys were perfused with DA sera cytotoxic to Lewis rats.

† For additional controls see Materials and Methods.

artery with bright fluorescence indicative of massive C deposits (Fig. 5) and an arteriole with only a slight fluorescent lining of the intima (Fig. 6).

In contrast to the bright fluorescence in the rest of the vasculature, no staining with either anti- γ -globulin or anti- β_{1C} was observed in the glomeruli of 10 out of 12 kidneys. In the remaining two kidneys there was a weak fluorescence outlining the lumen of the glomerular capillaries. However, even in these organs the questionable fluorescence was seen only in some of the glomeruli while the majority of the glomerular tufts remained negative.

The fluorescence observed along the basal membranes of some segments of the proximal tubuli upon exposure of the sections to fluorescent antiserum to β_{1C}

globulin was puzzling (Figs. 4, 6, 7). This particular staining was specifically inhibited by pretreatment of the sections with nonconjugated anti- β_{1C} globulin or by absorption of the fluorescent antiserum with zymosan-adsorbed rat β_{1C} globulin. Whatever the explanation of the peculiar localization of autologous

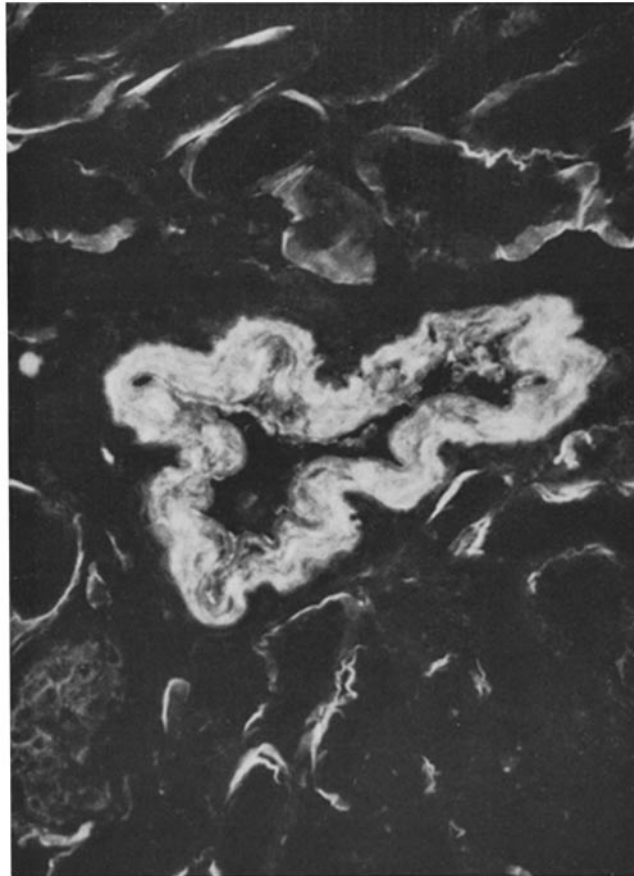


FIG. 4. The same vessel as in Fig. 3 stained with fluorescent anti-rat- β_{1C} . The distribution pattern corresponds to the γ -globulin deposits seen in Fig. 3. The meaning of the additional binding of anti- β_{1C} globulin also to the basal membranes of proximal tubuli is discussed in the text. Cryostat section; 5 μ ; $\times 200$.

β_{1C} protein at these sites may be, it had no relation to the passage of the cytotoxic antisera through the kidney. Similar deposits of rat β_{1C} globulin were seen in nonperfused kidneys and in kidneys perfused with autologous antisera cytotoxic to the other strain of rats. The finding is in line with similar observations by Feldman and Lee (18) on Lewis and DA rats.

DISCUSSION

The present perfusion technique of rat kidneys with cytotoxic antisera can be viewed as a short term model of allograft rejection. When compared with the usual grafting procedure and the exposure of the grafted organ to the host environment over prolonged periods of time, the model entails the following advantages. (a) The possible involvement of cell-mediated mechanisms is ex-

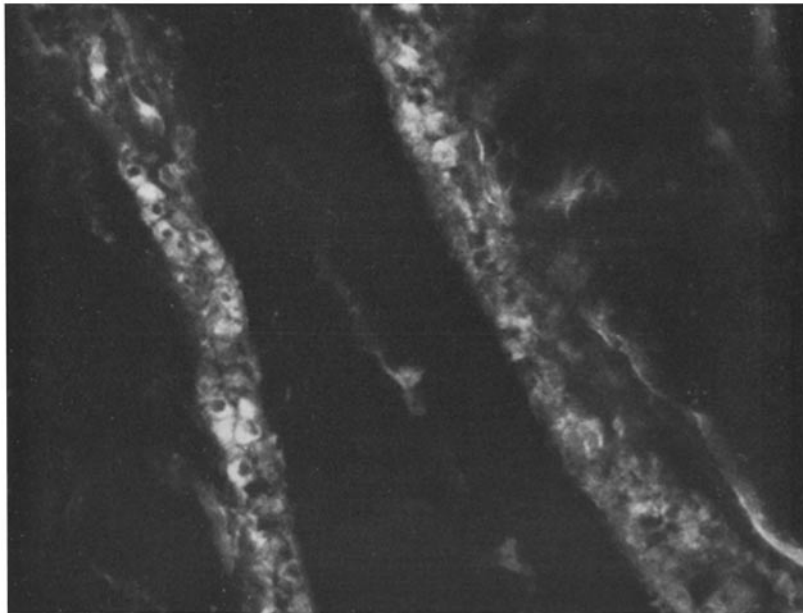


FIG. 5. DA rat kidney perfused with cytotoxic antiserum as in Figs. 3 and 4. The section was stained with a fluorescent antiserum to rat β_{1C} globulin. The cytoplasm of some intima cells of an artery shows a bright fluorescence, partly in a granular fashion. The nonspecific fluorescence along the basement membranes of the tubuli is discussed in the text. Cryostat section; 5μ ; $\times 300$.

cluded. The serum perfusates are free of cells and the isolation of the kidneys from the circulation prevents the entering of autologous cells. (b) In immunofluorescence analyses of human kidney transplants, intrarenal deposits of immune globulins were difficult to interpret since the majority of the recipients were nephritic patients. Glomerulonephritis per se is characterized by intrarenal deposition of γ -globulin and β_{1C} protein (15). This may also occur in the grafted organ (30). Similar interpretational difficulties are also encountered in experimental transplantation of long duration. The implantation of homologous kidney material may result in a sensitization of the host to the foreign glomeru-

lar basal membranes. An autosensitization could develop resulting in the deposition in the kidneys of immune globulins that are not cytotoxic antibodies (40). (c) The perfusion of the kidney *in situ* ensures the reaction of the antisera with kidneys not previously altered by ischemia.

In the present study, positive staining of sections of the perfused kidneys with fluorescent antisera against rat γ -globulin was observed on and in the walls of the arteries and arterioles (Fig. 3) and, to a lesser degree, in the walls of the

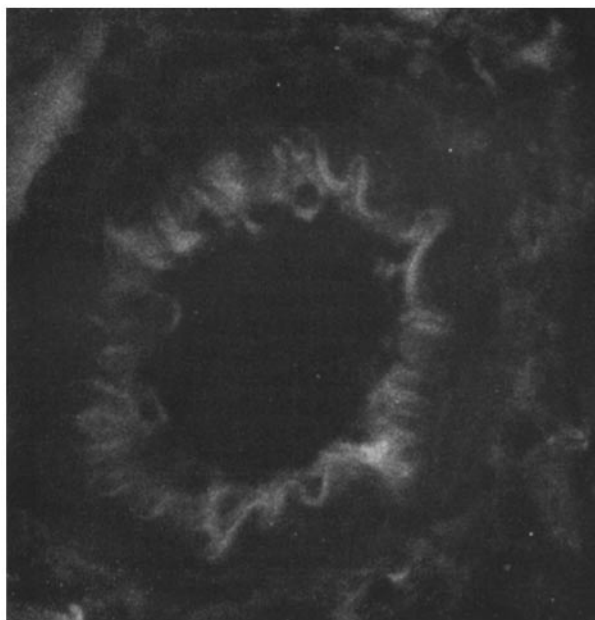


FIG. 6. Another section of the same rat kidney as in Fig. 5. The arteriole in the center exhibits an even pattern of linear fluorescence outlining the intima layer. Slight fluorescence around some endothelial nuclei protruding into the lumen also occurs. Fluorescent antiserum to rat β_{1C} globulin; cryostat section; 5μ ; $\times 250$.

larger veins. Characteristically, the immunofluorescence was of a smooth and linear pattern (Fig. 3). The deposits of γ -globulin are interpreted to represent tissue-fixed cytotoxic antibodies absorbed from the antiserum: Perfusion with (a) normal homologous rat sera or (b) isologous normal sera or (c) isologous sera containing cytotoxic antibodies against another inbred strain of rats, did not result in any intrarenal deposition of γ -globulin. The antibody nature of the γ -globulin is also indicated by the local activation of the serum C system. Tissue fixation of γ -globulin and of β_{1C} protein, known to be associated with the activity of the third component of C (C3), was consistently detected at identical sites (Figs. 3 and 4).

While the localization of the immune globulins was unequivocal in the medium and small caliber arterial vessels, the deposition was questionable within the glomerular capillaries. The majority of the glomeruli did not stain with anti- γ -globulin or with anti- β_{1C} sera. There were only a few glomeruli in each kidney that showed a weak fluorescence outlining the capillaries following staining with either of the reagents (Fig. 7). The poor staining of the glomerular

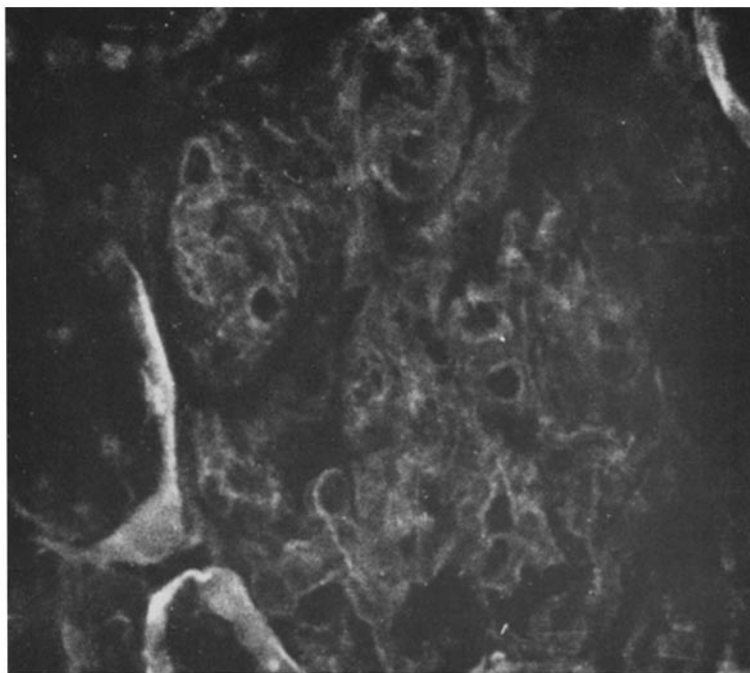


FIG. 7. DA rat kidney after perfusion with cytotoxic antiserum as in Figs. 2, 3, 4 and 5. The photograph exemplifies the equivocal fluorescence observed in some of the glomeruli. Staining was with fluorescent anti- β_{1C} protein. Cryostat section; $5\ \mu$; $\times 600$).

capillaries may be attributed to three different possibilities. (a) The cytotoxic antibodies by binding to the vessel walls may have been removed before they reached the glomeruli; (b) the glomeruli may carry less tissue compatibility antigens in comparison with the larger vessels; or, (c) the glomeruli may have been shut off from the intrarenal circulation during the perfusion experiment. The latter possibility, however, is unlikely in view of the results of the control experiment. When China ink was perfused through the kidneys under similar conditions, an even distribution of the marker was observed throughout the kidney, including the glomeruli (Fig. 1). The distribution pattern of the immune

globulins of cytotoxic sera clearly contrasts with the deposition seen in nephritic kidneys. In this study, the cytotoxic antibodies and β_{1C} protein predominantly localized in the larger vessels and not in the glomeruli. In contrast, in human and in experimental glomerulonephritis of the various forms, the globulins predominantly localized in the glomeruli and not in the larger vessels (reviewed in reference 36).

The present findings are in line with earlier observations on experimental kidney transplants (20, 22, 41). The deposition of γ -globulin in the arterial intima was seen in allografted dog kidneys by Horowitz et al. (20) and in goat kidneys by Perper and Najarian (41) and by Cochrum et al. (22). The possible activation, however, by the γ -globulins of proteins associated with C functions was not analyzed in these studies. Such analyses were attempted in rats. While Feldman and Lee (18) reported negative results when looking for deposits of γ -globulin or β_{1C} globulin, possibly for quantitative reasons, the positive findings of Lindquist et al. (21) apparently are at variance with ours. The authors described a tissue fixation of γ -globulin and of β_{1C} globulin in the peritubular capillaries of allografted rat kidneys while the arteria and the arterioles remained virtually free. When trying to explain these discrepancies, differences in the experimental design should be considered: the participation of cellular elements was not excluded in the long term transplantation of Lindquist et al. and is indeed described by the authors as the leading feature in the histology of the early phase of the rejection reaction. The γ -globulin deposits were closely associated with the mononuclear cells infiltrating the peritubular area. To what degree, if any, the differences can be explained on the basis of cellular influences in Lindquist's experiments remains open at this time.

The localization of the immune globulin deposits in the present study also corresponds to similar observations on human kidney transplants (23–25, 27, 29). For the reasons mentioned above, any interpretation in these cases is problematic and may be helped by the present results. The characteristic pattern of the deposits in the perfusion experiments would support the interpretation that similar deposits in rejected human kidney grafts may also represent cytotoxic antibodies and serum C activated by them. Such globulins were indeed shown in elution experiments (7) to be cytotoxic to donor cells. And vice versa, the description of Jonasson et al. (24) of a long persisting, but finally rejected human kidney transplant with γ -globulin and β_{1C} globulin deposits also in the glomeruli would then indicate a glomerulonephritic process along with the rejection reaction. The interpretation of this case is further supported by the granular pattern of the perivascular glomerular deposits, as it is typically known in nephritis due to antigen-antibody complexes (42), in contrast to the smooth and linear pattern of deposition of cytotoxic antibodies seen in the present study (Figs. 3 and 4).

The possible pathogenic significance of the immune globulin deposits was not

investigated in the present study. Nevertheless, some indirect evidence seems to favor an involvement of the globulins in the graft destruction process. The perfusion of the kidney with cytotoxic serum was followed by a marked swelling of the endothelial cells and by an enlargement of the nuclei which became prominent and protruded into the lumen (Fig. 2). Similar reactions have been reported in allografted dog kidneys undergoing rejection (43). Since such alterations were not seen in the control kidneys, they are viewed to indicate a deleterious effect of the antiserum. Similarly, the localization of the immune globulins throughout the entire depth of the vessel walls (Figs. 3 and 4) may reflect an intima lesion with loss of permeability control caused by the antiserum. This view would be in line with recent and more direct evidence in favor of a pathogenic significance in the allograft rejection of the antibody-mediated C activation (22, 44, 45). Especially, it would correlate well with the histology of the initial lesions seen in human kidney transplants undergoing rejection. Similar vascular areas as marked in the present study by the deposition of immune globulins are also the areas of incipient damage when a grafted human organ is rejected (46).

SUMMARY

The reactivity of histocompatibility antigens with serum antibodies and complement was studied in a short term model of allotransplantation. Lewis and DA rat kidneys were perfused with cytotoxic antisera and tissue sections analyzed for adsorption of fluorescent antibodies against γ -globulin and complement (β_{1C} protein). Both, the presumed cytotoxic antibody and C were localized at similar sites in the endothelial lining and in the walls of the arterial vessels and of the larger veins.

The pattern of immune globulin deposition was distinct from that observed in glomerulonephritis. It may thus become helpful in the differential diagnosis between graft rejection and glomerulonephritis.

At the sites of the deposits, the endothelial cells appeared enlarged and their nuclei protruded into the lumen.

The findings are in line with the hypothesis that an antibody-mediated local activation of serum complement may be involved in the destruction of allografted tissue.

BIBLIOGRAPHY

1. Jensen, E., and C. A. Stetson. 1961. Humoral aspects of the immune response to homografts. II. Relationship between the haemagglutinating and cytotoxic activities of certain isoimmune sera. *J. Exp. Med.* **113**:785.
2. Guttman, R. D., R. R. Lindquist, R. M. Parker, C. B. Carpenter, and J. P. Merrill. 1967. Renal transplantation in the inbred rat. *Transplantation.* **5**:668.
3. Simonsen, M. 1953. Biological incompatibility in kidney transplantation in dogs. II. Serological investigations. *Acta Pathol. Microbiol. Scand.* **32**:36.
4. Terasaki, P. I., E. J. Bold, J. A. Cannon, and W. P. Longmire, Jr. 1961. Anti-

- body response to homografts. VI. In vitro cytotoxins produced by skin homografts in rabbits. *Proc. Soc. Exp. Biol. Med.* **106**:133.
5. Iwasaki, J., D. Talmage, and T. E. Starzl. 1967. Humoral antibodies in patients after renal homotransplantation. *Transplantation*. **5**:191.
 6. Manzler, A. D. 1968. Serum cytotoxin in human kidney transplant recipients. *Transplantation*. **6**:787.
 7. Cochrum, K. C., and S. L. Kountz. 1969. Cytotoxic antibodies following human renal transplantation. *Fed. Proc.* **28**:485.
 8. Gorer, P. A., and P. O'Gorman. 1956. The cytotoxic activity of isoantibodies in mice. *Transplantation Bull.* **3**:142.
 9. Stetson, Ch. A. 1963. The role of humoral antibody in the homograft rejection. *Advan. Immunol.* **3**:97.
 10. Hampers, C. L., K. Kolker, and E. B. Hager. 1967. Isolation and characterization of antibodies and other immunologically reactive substances from rejecting renal allografts. *J. Immunol.* **99**:514.
 11. Rother, U., D. L. Ballantyne, C. Cohen, and K. Rother. 1967. Allograft rejection in C'6 defective rabbits. *J. Exp. Med.* **126**:565.
 12. Phillips, M. E., U. Rother, and K. Rother. 1968. Serum complement in the rejection of sarcoma I ascites tumor grafts. *J. Immunol.* **100**:493.
 13. Weitzel, K., and K. Rother. 1970. Studies on the role of serum complement in allograft rejection and in immunosuppression by antithymocyte serum (ATS). *Europ. Surg. Res.* **2**:310.
 14. Klein, P., and P. Burkholder. 1959. Ein Verfahren zur fluoreszenzoptischen Darstellung der Komplementbindung und seine Anwendung zur histo-immunologischen Untersuchung der experimentellen Nierenanaphylaxie. *Deut. Med. Wochenschr.* **84**:2001.
 15. Lachmann, P. J., H. J. Müller-Eberhard, H. G. Kunkel, and F. Paronetto. 1962. The localization of in vivo bound complement in tissue sections. *J. Exp. Med.* **115**:63.
 16. Freedman, P., and A. S. Markowitz. 1962. γ -globulin and complement in the diseased kidney. *J. Clin. Invest.* **41**:328.
 17. Levenson, H., and Ch. G. Cochrane. 1964. Nonprecipitating antibody and the arthus vasculitis. *J. Immunol.* **92**:118.
 18. Feldman, J. D., and S. Lee. 1967. Renal homotransplantation in rats. I. Allogeneic Recipients. *J. Exp. Med.* **126**:783.
 19. Spong, F. W., J. D. Feldman, and S. Lee. 1968. Transplantation antibody associated with first set renal homografts. *J. Immunol.* **101**:418.
 20. Horowitz, R. E., L. Burrows, F. Paronetto, D. Dreiling, and A. E. Kark. 1965. Immunologic observations on homografts. II. The canine kidney. *Transplantation*. **3**:318.
 21. Lindquist, R. R., R. D. Guttmann, and J. P. Merrill. 1968. Renal Transplantation in the inbred rat. II. An immunohistochemical study of acute allograft rejection. *Amer. J. Pathol.* **52**:531.
 22. Cochrum, K. C., W. C. Davis, S. L. Kountz, and H. H. Fudenberg. 1969. Renal autograft rejection initiated by passive transfer of immune plasma. *Transplant. Proc.* **1**:301.

23. Hadley, W. K., and W. Rosenau. 1967. Study of human renal disease by immunofluorescent methods. *Arch. Pathol.* **83**:342.
24. Jonasson, O., H. J. Winn, M. H. Flax and P. S. Russell. 1967. Renal biopsies in long term survivors of renal transplantation: immunofluorescent studies. *Transplantation.* **5**:859.
25. Rock, R., W. Rosenau, and J. S. Najarian. 1967. A clinicopathologic study of human renal homotransplantation. *Surg. Gynecol. Obstet.* **125**:289.
26. Glassock, R. J., D. Feldman, E. S. Reynolds, G. J. Dammin, and J. P. Merrill. 1968. Human renal isografts: a clinical and pathologic analysis. *Medicine.* **47**:411.
27. Lindquist, R. R., R. D. Guttman, J. P. Merrill, and G. J. Dammin. 1968. Human renal allografts. Interpretation of morphologic and immunochemical observations. *Amer. J. Pathol.* **53**:851.
28. Porter, K. A., G. A. Andres, M. W. Calder, J. B. Dossetor, K. C. Hsu, Jane M. Rendall, Beatrice C. Seegal, and T. E. Starzl. 1968. Human Renal Transplants. II. Immunofluorescent and Immunoferritin Studies. *Lab. Invest.* **18**:159.
29. McKenzie, I. F. C., and S. Whittingham. 1968. Deposits of immunoglobulin and fibrin in human allografted kidneys. *Lancet.* **2**:1313.
30. Dixon, F. J., J. J. McPhaul, and R. A. Lerner. 1969. The contribution of kidney transplantation to the study of glomerulonephritis.—The recurrence of glomerulonephritis in renal transplants. *Transplant. Proc.* **1**:194.
31. Ramseier, H., and J. Palm. 1967. Further study of histocompatibility loci in rats. *Transplantation.* **5**:721.
32. Kabat, E. A., and M. M. Mayer. 1961. *In* Kabat and Mayer's Experimental Immunochemistry. Charles C. Thomas, Springfield, Ill. 2nd edition.
33. Müller-Eberhard, H. J. 1960. A new supporting medium for preparative electrophoresis. *Scand. J. Clin. Lab. Invest.* **12**:33.
34. Mardiney, M. R. Jr., and H. J. Müller-Eberhard. 1965. Mouse β_{1C} globulin. Production of antiserum and characterization of the complement reaction. *J. Immunol.* **94**:877.
35. Wood, B. T., S. H. Thompson, and G. Goldstein. 1965. Studies on fluorescent antibody staining. III. Preparation of fluorescein-isothiocyanate-labeled antibodies. *J. Immunol.* **95**:225.
36. Dixon, F. J. 1969. The multiple pathogenesis of glomerulonephritis. *In* International Convocation on Immunology. N. R. Rose, and F. Milgrom, editors. S. Karger, AG, Basel-New York. 279.
37. Sanderson, A. R. 1965. Quantitative titration, kinetic behavior and inhibition of cytotoxic mouse isoantisera. *Immunology.* **9**:287.
38. Rubin, D., U. Rother, and K. Rother. 1967. The reactivity of complement in cytotoxicity by isoantibodies. *Fed. Proc.* **26**:603.
39. Müller-Eberhard, H. J., and U. Nilsson. 1960. Relation of a β_{1C} glycoprotein of human serum to the complement system. *J. Exp. Med.* **111**:217.
40. Klassen, J., and F. Milgrom. 1969. Autoimmune concomitants of renal allografts. *Transplant. Proc.* **1**:605.
41. Perper, R. J., and J. S. Najarian. 1967. Experimental renal heterotransplantation. 3. Passive transfer of transplantation immunity. *Transplantation.* **5**:514.

42. Unanue, E. R., and F. J. Dixon. 1967. Experimental glomerulonephritis: immunological events and pathogenetic mechanisms. *Advan. Immunol.* **6**:1.
43. Porter, K. A. 1965. Morphological aspects of renal homograft rejection. *Brit. Med. Bull.* **21**:171.
44. Clark, D. S., J. E. Foker, R. A. Good, and R. L. Varco. 1968. Humoral factors in canine renal allograft rejection. *Lancet.* **1**:8.
45. Foker, J. E., D. S. Clark, R. J. Pickering, R. A. Good, and R. L. Varco. 1969. Studies on the mechanism of canine renal allograft rejection. *Transplant. Proc.* **1**:296.
46. Bohle, A., H. Edel, and H. Pichlmaier. 1969. Über die Beziehungen von Struktur und Funktion bei der akuten, perakuten und chronischen Abstossung von Nierentransplantaten. *In Organtransplantation, Immunologie und Klinik.* A. Heymer, and D. Ricken, editors. F. K. Schattauer-Verlag, Stuttgart, New York. 89.