

Image-guided Spine Stabilization for Traumatic or Osteoporotic Spine Injury: Radiological Accuracy and Neurological Outcome

Nobuyuki SHIMOKAWA,¹ Junya ABE,¹ Hidetoshi SATOH,¹ Hironori ARIMA,² and Toshihiro TAKAMI²

¹Department of Neurosurgery, Tsukazaki Hospital, Himeji, Hyogo;

²Department of Neurosurgery, Osaka City University Graduate School of Medicine, Osaka, Osaka

Abstract

Significant progress has been made in image-guided surgery (IGS) over the last few decades. IGS can be effectively applied to spinal instrumentation surgery. In the present study, we focused our attention on the feasibility and safety of image-guided spine stabilization for traumatic or osteoporotic spine injury. The IGS spine fixation with or without minimally invasive surgery (MIS) techniques such as percutaneous screw placement, balloon kyphoplasty (BKP), or vertebroplasty (VP) were accomplished in 80 patients with traumatic or osteoporotic spine injury between 2007 and 2015. The injured vertebral levels included the following: cervical spine, 41; thoracic spine, 22; and lumbar spine, 17. Neurological condition before and after surgery was assessed using the American Spinal Injury Association Impairment Scale (AIS). A total of 419 pedicle, lateral mass, or laminar screws were placed, and 399 screws (95.2%) were found to be placed correctly based on postoperative computed tomography scan. Although 20 screws (4.8%) were found to be unexpectedly placed incorrectly, no neural or vascular complications closely associated with screw placement were encountered. Neurological outcomes appeared to be acceptable or successful based on AIS. The IGS is a promising technique that can improve the accuracy of screw placement and reduce potential injury to critical neurovascular structures. The integration of MIS and IGS has proved feasible and safe in the treatment of traumatic or osteoporotic spine injury, although a thorough knowledge of surgical anatomy, spine biomechanics, and basic technique remain the most essential aspects for a successful surgery.

Key words: spine injury, image-guided surgery, intraoperative navigation system, O-arm, spinal instrumentation

Introduction

Significant progress has been made in image-guided surgery (IGS) using a computer navigation system over the last few decades.^{1–18)} IGS can be effectively applied to spinal instrumentation surgery using pedicle screw (PS),¹⁹⁾ lateral mass screw (LMS),^{20–23)} or laminar screw²⁴⁾ and is now quite helpful in safe surgical management. An intraoperative three-dimensional computed tomography (3D CT)-based navigation system can help surgeons ensure accurate reconstruction of spinal alignment as well as precise placement of all spinal instruments during surgery. Another advantage of IGS is that surgeons can use

multi-planar visualization of the spinal anatomy without direct exposure of the deep surgical field. An IGS allows surgeons to track any surgical instrument virtually in reference to the displayed anatomy in real time. This can be particularly helpful when a spinal instrument or implant is placed into unexposed or partially exposed spinal structures that may not be directly visible, such as with percutaneous pedicle screwing. This has led surgeons to introduce minimally invasive surgery (MIS) for the treatment of traumatic spine injury.^{25–30)} The IGS technology may be best thought of as a supplement to the surgeon's experience and judgment. In the present study, we focused our attention on the feasibility and safety of image-guided spine stabilization for traumatic or osteoporotic spine injury.

Received December 12, 2015; Accepted March 11, 2016

Materials and Methods

I. Patients

Image-guided spinal instrumented stabilization including balloon kyphoplasty (BKP) or vertebroplasty (VP)^{31,32} was accomplished in 80 patients of traumatic or osteoporotic spine injury at our institute between 2007 and 2015. The patients included 54 men and 26 women, and the mean age at surgery was 65.1 years (range, 15–92 years). The injured vertebral levels included the following: cervical spine, 41; thoracic spine, 22; and lumbar spine, 17. The clinical diagnosis was vertebral body fracture, including compression fracture and burst fracture of the vertebral body in 45; partial fracture of the vertebra including odontoid fracture of the axis, lateral mass fracture, or pedicle fracture in 16, vertebral dislocation injury including discoligamentous injury in 12, facet interlocking in 7, and flexion-distraction injury related to a Chance fracture in 3. Patient characteristics are summarized in Table 1. Neurological condition before and late after surgery was assessed using the American Spinal Injury Association Impairment Scale (AIS) (Table 2).³³

II. Preoperative evaluation

Comprehensive radiological evaluation including plain radiography, CT scan, and magnetic resonance imaging (MRI) were routinely performed. Pedicle morphology (coronal, axial, and sagittal) and medial inclination of the pedicle axis were carefully

Table 1 Patient characteristics

Characteristics	No. (range)
Total no. of patients	80
Sex (male/female)	54/26
Mean age at surgery (years)	65.1 (15–92)
Postoperative follow-up (months)	32.4 (6–94)
Injured vertebral level	
Cervical	41
Thoracic	22
Lumbar	17
Preoperative diagnosis	
Vertebral body fracture (compression or burst)	45
Other vertebral fracture (odontoid, lateral mass or pedicle fracture)	16
Dislocation injury	12
Facet interlocking	7
Chance fracture	3

Table 2 ASIA Impairment Scale (AIS) for classifying spinal cord injury³³

Grade	Description
A	Complete injury. No motor or sensory function is preserved in the sacral segment S4 or S5.
B	Sensory incomplete. Sensory but not motor function is preserved below the level of injury, including the sacral segments.
C	Motor incomplete. Motor function is preserved below the level of injury, and more than half of muscles tested below the level of injury have a muscle grade less than 3.
D	Motor incomplete. Motor function is preserved below the level of injury, and at least half of the key muscles below the neurological level have a muscle grade of 3 or more.
E	Normal. No motor or sensory deficits, but deficits existed in the past.

ASIA: American Spinal Injury Association.

evaluated. In the case of cervical spine injury, the development and course of the vertebral artery (VA) in the transverse foramen at each vertebra and the collateral vascular network were carefully evaluated using MR angiography and/or CT angiography. When unilateral VA occlusion due to cervical spine injury was recognized before surgery, cervical pedicle screw (CPS) placement was avoided on the remaining side. In such cases, a CPS was placed on the VA-occluded side and an LMS was placed on the remaining side to secure VA circulation. The appropriate pathway, diameter, and length of each screw were decided using preoperative high-resolution 3D CT. Abdominal CT angiography was done for lateral interbody fixation to evaluate the course of the urinary tract and arterial and venous circulation in the operative field. Axial imaging using lumbar MRI was useful to evaluate the development and shape of the psoas muscle and the position of the lumbar nerve plexus, including the femoral nerve.

III. Surgical procedure

In our institute, we used a preoperative 3D CT-based navigation system (Medtronic Inc., Memphis, Tennessee, USA) in the first study period (2007–2012) and an intraoperative 3D CT-based navigation system (O-arm) (Medtronic Inc.) in the second study period (2012–2015). When neural compression due to bone fracture or hematoma was recognized based on preoperative images, decompressive procedure was performed first. Correction of destructive structures due to spine injury, such as locked facets, was also done before placement of spinal instrumentation such as PSs or LMSs (Fig. 1).

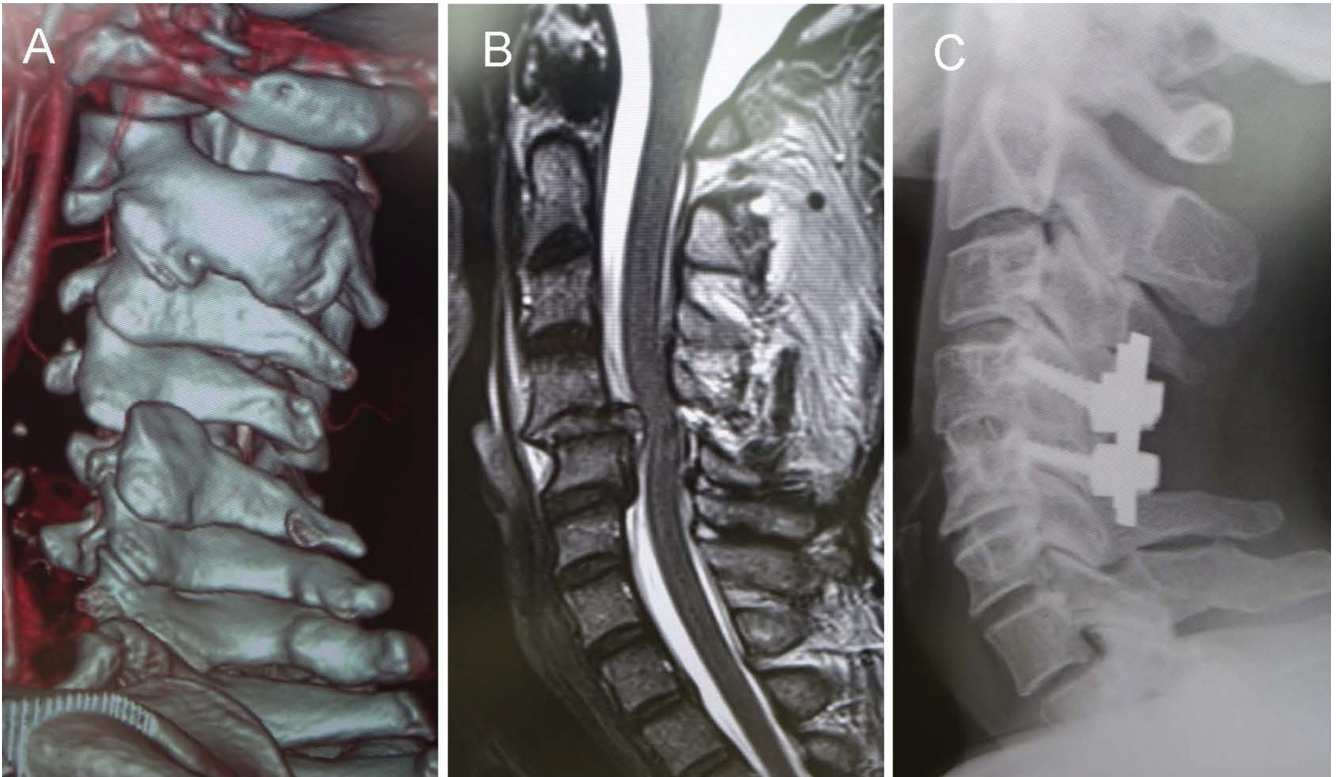


Fig. 1 An illustrative case of unilateral facet interlocking at C4–5 with moderate compression of the spinal cord. Emergent surgery of combined anterior and posterior fixation of the cervical spine was performed. A: Preoperative computed tomography, B: preoperative magnetic resonance imaging, and C: postoperative plain cervical radiograph.

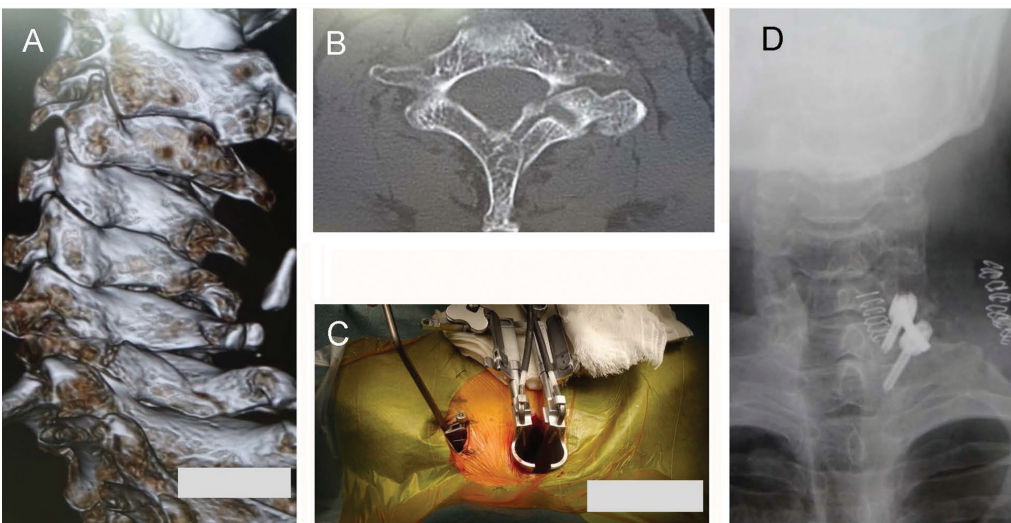


Fig. 2 An illustrative case of C7 pedicle and lamina fracture of the left side. Emergent surgery of posterior unilateral fixation of the cervical spine was performed. A, B: Preoperative computed tomography, C: intraoperative photograph showing the placement of unilateral cervical pedicle screws using minimally invasive surgery technique, and D: postoperative plain cervical radiograph.

The navigation reference frame was carefully attached at the spinous process of the injured vertebra, where navigation error needed to be minimized, particularly when severe instability of the spine was suspected before surgery (Fig. 2). In the case of craniocervical injury, the navigation reference frame was attached to the head clamp. Careful

and meticulous placement of spinal instruments was accomplished with the help of intraoperative image guidance to avoid any additional damage to the important anatomical structures such as the spinal cord, cauda equina, spinal nerve roots, or VA. In cases of severe instability of the spine, temporary rod fixation on a unilateral spinal structure was an

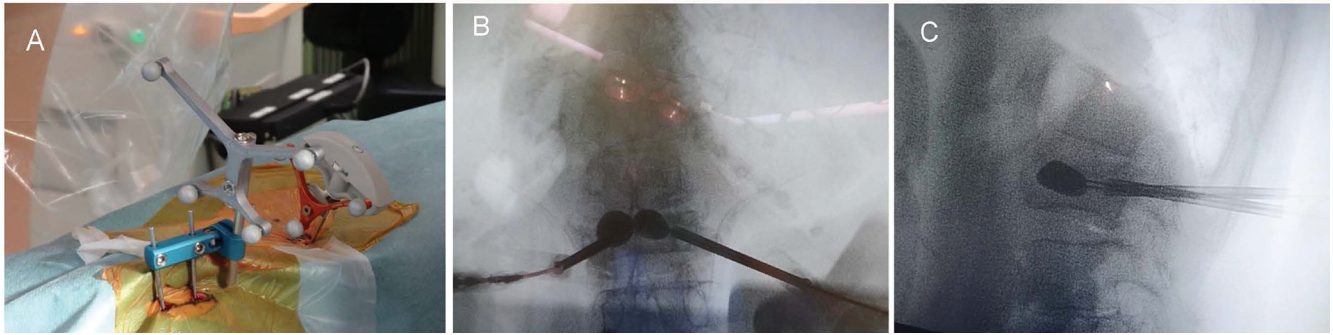


Fig. 3 A: An intraoperative photograph showing the use of a navigation reference frame fixed to the posterior iliac bone and an inserted Pak needle. B, C: Intraoperative fluoroscopic images showing the successful introduction of the balloons into the vertebral body.

optional procedure to stabilize the spine and secure a safe surgery.

In cases of a BKP or a VP for thoracolumbar vertebral body fracture, the navigation reference frame was fixed to the posterior iliac bone (Fig. 3A). Intraoperative 3D CT images using an O-arm or 2D intraoperative fluoroscopic images using a preoperative 3D CT-based navigation system were obtained, and these images were transferred to the surgical navigation workstation, StealthStation® (Medtronic Inc.). Surgical trajectory for BKP or VP was carefully determined on the surface of the operative field, and a small skin incision (about 1 cm) was made on each side. An introducer (Pak needle) was safely navigated into the vertebral body through the entry point of each pedicle. BKP or VP procedures were well controlled by conventional fluoroscopy (Fig. 3B, C).

In cases of MIS technique for percutaneous pedicle screw (PPS) placement, the navigation reference frame was fixed to the appropriate spinous process in the midline (Fig. 4). A Pak needle was safely advanced to the entry point of each pedicle as displayed on the workstation monitor. A Kirchner wire (K-wire) was inserted into the internal lumen of the Pak needle and was then slightly advanced toward the deep vertebral body (about 0.7 cm) to prevent it from being pulled out together with removal of the Pak needle. After removal of the Pak needle, a tapping device was advanced over the K-wire using image-guided feedback. Finally, cannulated screws were placed over the K-wire. After the setting of the screw-rod contouring, spinal alignment and safe placement of all spinal instruments were examined using conventional fluoroscopy or intraoperative 3D CT with an O-arm.

IV. Radiological analysis

The accuracy of each individual screw, including PS, LMS, or laminar screw, was evaluated using

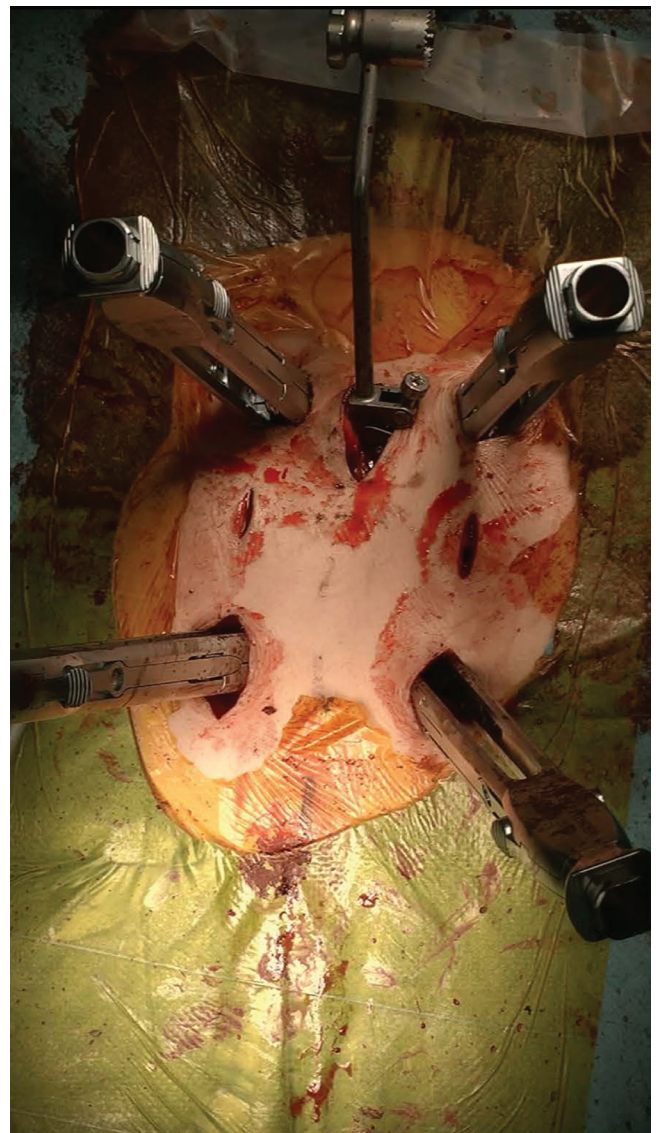


Fig. 4 An intraoperative photograph showing minimally invasive surgery technique of percutaneous pedicle screw placement with the help of intraoperative image guidance.

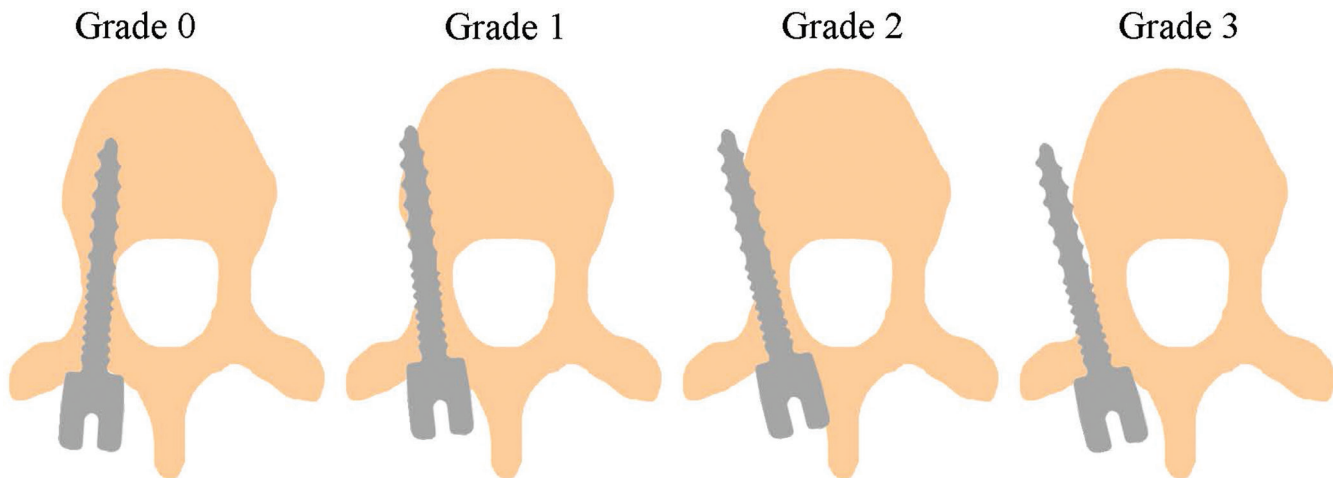


Fig. 5 Illustrations showing the grading scale of the radiological accuracy of screw placement evaluated using postoperative computed tomography scan that was originally proposed by Mirza et al.³⁴⁾

Table 3 Summary of accuracy of spinal instruments using pedicle screw, lateral mass screw, or laminar screws

Grade	No.	%	Spine level			Type of misplacement	
			Cervical	Thoracic	Lumbar	Medial	Lateral
0	399	95.2					
1	13	3.1	5	6	2	2	11
2	7	1.7	3	4			7
3	0	0					

postoperative CT scan and graded on a four-tiered classification system according to a previously published grading system proposed by Mirza et al.³⁴⁾: Grade 0, no cortical breach; Grade 1, cortical perforation is present and the screw protrudes up to 2 mm; Grade 2, cortical perforation is > 2 mm, but < 4 mm; and Grade 3, cortical perforation > 4 mm (Fig. 5).

Results

A total of 419 screws were placed, and total accuracy of screw placement was 95.2% (399 of 419 screws) in Grade 0, 3.1% (13 of 452 screws) in Grade 1, 1.7% (7 of 419 screws) in Grade 2, and 0% (0 of 419 screws) in Grade 3, respectively. In total, 20 of 419 screws (4.8%) were found to perforate the cortex of the pedicle, although no neural or vascular complications closely associated with screw placement were encountered in the present study. Eighteen of those 20 screws (90.0%) were found to perforate laterally and 2 screws (10.0%) were found to perforate medially. There were no screws that perforated

superiorly and inferiorly. Misplaced screws were distributed as follows: 40% in the cervical spine (8 of 20 screws), 50% in the thoracic spine (10 of 20 screws), and 10% in the lumbar spine (2 of 20 screws). Accuracy of spinal instrument placement to include PS, LMS, or laminar screws is summarized in Table 3. Neurological outcomes after surgery appeared to be either acceptable or successful based on AIS, and are summarized in Table 4.

Discussion

In the era from the 1980s to the 1990s, IGS had been initially applied to lumbar spine injuries.¹⁻⁷⁾ However, there was a significant problem with inaccuracy because of usage with intracranial frameless stereotaxy, which used skin surface markers for registration, and which did not allow for proper and reliable placement of the registration frame for spine surgery. Skin surface markers for registration were easily moved between the mobile skin surface and the underlying bony anatomical structures.^{5,6)}

Table 4 Summary of neurological outcomes

ASIA Impairment Scale (AIS)					
Preoperative AIS	Postoperative AIS				
	A	B	C	D	E
A					
B			1	2	
C			4	21	7
D				10	20
E					15

ASIA: American Spinal Injury Association.

After that a dynamic reference array (DRA) as a fiducial reference has been developed, and this DRA which attached directly to the spine replaced the skin surface markers and provided reliable registration accuracy.⁷⁾ As well, IGS for spinal surgery using CT scan obtained preoperatively resulted from the worldwide use in the early first decades of the 2000s.^{8,9)} In cases using a preoperative CT-based navigation system, anatomical landmarks need to be widely exposed, to serve as registration points and to be registered. The computer workstation calculates a registration error during paired-point matching and surface matching which takes several times (about 5–10 minutes/vertebrae) and procedure-specific limitations of acceptable registration error exists.¹⁰⁾ Although the registration process appears straightforward in an experienced surgeon's hands, there is a significant learning curve involved with the proper selection of anatomical landmarks and smooth matching technique. This anatomical information is then relayed to the computer workstation, and the spatial location of spinal instruments can then be displayed on the computer monitor. Another important concern is that there may be a significant discrepancy between spinal alignment on the preoperative 3D CT obtained in the supine position versus the spinal alignment visualized during the surgery. This discrepancy surely results in navigation errors when one-stage, multi-segment vertebral registration is attempted. Around the same time, a 2D fluoroscopy-based navigation system was utilized and was mainly applied to the safe placement of PSs in the lumbar spine, although safe placement of lumbar PSs can be performed under the surgeon's direct visualization of the anatomical landmarks with the help of fluoroscopic images.¹¹⁾ One of advantages of 2D fluoroscopy-based IGS is that surgeon-derived registration step is unnecessary. This advantage relates to shortening of the operating

time. Disadvantages of 2D fluoroscopy-based IGS are as follows: two-dimensional (anteroposterior and lateral dimensions) image guidance does not provide axial images like CT-based IGS provides. The quality of the images directly depends on the resolution of the acquired fluoroscopic projections, so usually be affected with patients condition, such as obesity or osteoporosis.

From 2000 to 2015, 3D fluoroscopy-based IGS and intraoperative 3D CT-based IGS (O-arm) were utilized all over the world.^{12–18)} Instead of using preoperative 3D CT data, the intraoperative 3D CT-based navigation system (O-arm) is now a remarkable advancement. The O-arm is an intraoperative full-rotation, multi-dimensional image system producing higher resolution 3D image, more similar to conventional CT scan rather than that of 3D fluoroscopy-based navigation system, especially in the condition of bone resolution. These image data immediately can be downloaded to the navigation system. This system can simplify the registration process and decrease navigation errors, particularly in spine injury cases with severe instability or dislocation or facet interlocking. Another advantage of this advanced system is that surgeons can have an opportunity to fix any errors due to mismatch between preoperative and intraoperative imaging. It is no doubt that this kind of recent advancement of IGS can improve the accuracy of PS placement to secure a safe surgery, but technical consideration needs to be further included. Despite the initial difficulty of IGS with spine injury, further technological developments, such as preoperative and intraoperative CT-based IGS, have enabled adaptation not only to the lumbar spine, but also to the cervical and thoracic spine.

With regard to the accuracy of PS screw placement, Gelalis et al.²⁶⁾ reported in 2012 that in a systematic review of 26 prospective clinical studies including 6,617 PSs inserted at the thoracic and lumbar spine in 1,105 patients, 89–100% of screws placed with CT navigation were correctly inserted in the pedicle without perforation of the pedicle, whereas correct placement was achieved in 81–92% with fluoroscopy-based navigation system, 28–85% with fluoroscopy, and 69–94% using a free-hand technique, with statistical significance. In the lower cervical and upper thoracic vertebral levels, intraoperative lateral fluoroscopy could not clearly distinguish vertebral body images that were overlapped by the shoulder joint and scapula of the patient. In this situation, the intraoperative navigation system was quite useful. The possible reason for PS misplacement in this present study may include anatomical complexity such as shape, size, or angle of the cervical or thoracic pedicle, in particular.

An MIS using a percutaneous cannulated screw technique is also gaining popularity for any spinal level.^{27–30} Advantages of this technique include a smaller incision, less muscle dissection, less blood loss, and postoperative pain. Many authors have reported malposition rates of lumbar PSs inserted with the percutaneous procedure, i.e., 6.6% by Wiesner et al.,²⁸ 2.3–3.3% by Schizas et al.,²⁹ 2.9% by Park et al.,³⁰ and 3.7–6.2% by Smith et al.³⁵ There is another concern that guide-wire migration can occur easily in elderly patients with poor bone quality, causing injury to neurovascular or visceral structures. These injuries are catastrophic to patients, e.g., the complication of fatal cardiac tamponade due to K-wire migration was reported by Heini et al.³⁶ Mobbs and Raley³⁷ reported that of 525 PPS insertions, seven anterior breaches were found and two patients had a postoperative ileus with a retroperitoneal hematoma. In cases of VP or BKP, an intraoperative 3D CT-based navigation system is particularly useful for elderly patients. It is occasionally difficult for the surgeon to identify a clear anteroposterior or lateral image of the injured vertebrae because vertebral body fractures in elderly patients are usually highly degenerative and result in rotational or translational changes in spinal alignment compared to young patients. The percutaneous procedure of BKP, VP, or PPS is technically demanding and requires a learning curve especially for the safe use of guide-wire. Surgeons cannot recognize the position of guide-wire using navigation system. It is of great importance to navigate the guide-wire using conventional fluoroscopic images to visualize the anatomical landmarks during the percutaneous procedure. The integration of MIS and IGS is feasible and safe, but surgeons do need to understand the importance of safe management.

Conclusion

The IGS is a promising technique that can improve the accuracy of screw placement and reduce potential injury to critical neurovascular structures. The integration of MIS and IGS proved to be feasible and safe in the treatment of traumatic or osteoporotic spine injury, although a thorough knowledge of surgical anatomy, spine biomechanics, and basic technique remain the most essential aspects for successful surgery. An IGS for traumatic or osteoporotic spine injury may represent the most current modification of spine surgery, and this has been an important advancement.

Conflicts of Interest Disclosure

The authors report no conflict of interest concerning the materials or methods used in this study or the

findings specified in this article. All authors who are members of The Japan Neurosurgical Society (JNS) have registered and completed the online Self-reported COI Disclosure Statement Forms through the website for JNS members.

References

- 1) Weinstein JN, Spratt KF, Spengler D, Brick C, Reid S: Spinal pedicle fixation: reliability and validity of roentgenogram-based assessment and surgical factors on successful screw placement. *Spine* 13: 1012–1018, 1988
- 2) Kalfas IH, Kormos DW, Murphy MA, McKenzie RL, Barnett GH, Bell GR, Steiner CP, Trimble MB, Weisenberger JP: Application of frameless stereotaxy to pedicle screw fixation of the spine. *J Neurosurg* 83: 641–647, 1995
- 3) Nolte LP, Zamorano LJ, Jiang Z, Wang Q, Langlotz F, Berlemann U: Image-guided insertion of transpedicular screws. A laboratory set-up. *Spine* 20: 497–500, 1995
- 4) Schulze CJ, Munzinger E, Weber U: Clinical relevance of accuracy of pedicle screw placement. A computed tomographic-supported analysis. *Spine* 23: 2215–2220; discussion 2220–2221, 1998
- 5) Brodwater BK, Roberts DW, Nakajima T, Friets EM, Strohbehn JW: Extracranial application of the frameless stereotactic operating microscope: experience with lumbar spine. *Neurosurgery* 32: 209–213; discussion 213, 1993
- 6) Roessler K, Ungersboeck K, Dietrich W, Aichholzer M, Hittmeir K, Matula C, Czech T, Koos WT: Frameless stereotactic guided neurosurgery: clinical experience with an infrared based pointer device navigation system. *Acta Neurochir (Wien)* 139: 551–559, 1997
- 7) Foley KT, Smith MM: Image-guided spine surgery. *Neurosurg Clin N Am* 7: 171–186, 1996
- 8) Kotani Y, Abumi K, Ito M, Minami A: Improved accuracy of computer-assisted cervical pedicle screw insertion. *J Neurosurg* 99(3 Suppl): 257–263, 2003
- 9) Richter M, Cakir B, Schmidt R: Cervical pedicle screws: conventional versus computer-assisted placement of cannulated screws. *Spine* 30: 2280–2287, 2005
- 10) Rampersaud YR, Simon DA, Foley KT: Accuracy requirements for image-guided spinal pedicle screw placement. *Spine* 26: 352–359, 2001
- 11) Foley KT, Simon DA, Rampersaud YR: Virtual fluoroscopy: computer-assisted fluoroscopic navigation. *Spine* 26: 347–351, 2001
- 12) Hott JS, Deshmukh VR, Klopfenstein JD, Sonntag VK, Dickman CA, Spetzler RF, Papadopoulos SM: Intraoperative Iso-C C-arm navigation in craniocervical surgery: the first 60 cases. *Neurosurgery* 54: 1131–1136; discussion 1136–1137, 2004
- 13) Ito Y, Sugimoto Y, Tomioka M, Hasegawa Y, Nakago K, Yagata Y: Clinical accuracy of 3D fluoroscopy-assisted cervical pedicle screw insertion. *J Neurosurg* *Spine* 9: 450–453, 2008

- 14) Beck M, Mittlmeier T, Gierer P, Harms C, Gradl G: Benefit and accuracy of intraoperative 3D-imaging after pedicle screw placement: a prospective study in stabilizing thoracolumbar fractures. *Eur Spine J* 18: 1469–1477, 2009
- 15) Ishikawa Y, Kanemura T, Yoshida G, Ito Z, Muramoto A, Ohno S: Clinical accuracy of three-dimensional fluoroscopy-based computer-assisted cervical pedicle screw placement: a retrospective comparative study of conventional versus computer-assisted cervical pedicle screw placement. *J Neurosurg Spine* 13: 606–611, 2010
- 16) Ishikawa Y, Kanemura T, Yoshida G, Matsumoto A, Ito Z, Tauchi R, Muramoto A, Ohno S, Nishimura Y: Intraoperative, full-rotation, three-dimensional image (O-arm)-based navigation system for cervical pedicle screw insertion. *J Neurosurg Spine* 15: 472–478, 2011
- 17) Ammirati M, Salma A: Placement of thoracolumbar pedicle screws using O-arm-based navigation: technical note on controlling the operational accuracy of the navigation system. *Neurosurg Rev* 36: 157–162; discussion 162, 2013
- 18) Ling JM, Dinesh SK, Pang BC, Chen MW, Lim HL, Louange DT, Yu CS, Wang CM: Routine spinal navigation for thoraco-lumbar pedicle screw insertion using the O-arm three-dimensional imaging system improves placement accuracy. *J Clin Neurosci* 21: 493–498, 2014
- 19) Abumi K, Ito H, Taneichi H, Kaneda K: Transpedicular screw fixation for traumatic lesions of the middle and lower cervical spine: description of the techniques and preliminary report. *J Spinal Disord* 7: 19–28, 1994
- 20) Roy-Camille R, Gailliant G, Bertreaux D: Early management of spinal injuries, in McKibben B (ed): *Recent Advances in Orthopedics*. Edinburgh, Churchill-Livingstone, 1979, pp 57–87
- 21) Anderson PA, Henley MB, Grady MS, Montesano PX, Winn HR: Posterior cervical arthrodesis with AO reconstruction plates and bone graft. *Spine (Phila Pa 1976)* 16(3 Suppl): S72–S79, 1991
- 22) Jeanneret B, Magerl F, Ward EH, Ward JC: Posterior stabilization of the cervical spine with hook plates. *Spine (Phila Pa 1976)* 16(3 Suppl): S56–S63, 1991
- 23) An HS, Gordin R, Renner K: Anatomic considerations for plate screw fixation of the cervical spine. *Spine (Phila Pa 1976)* 16(10 Suppl): S548–S551, 1991
- 24) Wright MN: Posterior C2 fixation using bilateral, crossing C2 laminar screws: case series and technical note. *J Spinal Disord Tech* 17: 158–162, 2004
- 25) Holly LT, Foley KT: Intraoperative spinal navigation. *Spine* 28: S54–S61, 2003
- 26) Gelalis ID, Paschos NK, Pakos EE, Politis AN, Arnaoutoglou CM, Karageorgos AC, Ploumis A, Xenakis TA: Accuracy of pedicle screw placement: a systematic review of prospective in vivo studies comparing free hand, fluoroscopy guidance and navigation techniques. *Eur Spine J* 21: 247–255, 2012
- 27) Foley KT, Holly LT, Schwender JD: Minimally invasive lumbar fusion. *Spine* 28: S26–S35, 2003
- 28) Wiesner L, Kothe R, Schulitz KP, Rütther W: Clinical evaluation and computed tomography scan analysis of screw tracts after percutaneous insertion of pedicle screws in the lumbar spine. *Spine* 25: 615–621, 2000
- 29) Schizas C, Michel J, Kosmopoulos V, Theumann N: Computer tomography assessment of pedicle screw insertion in percutaneous posterior transpedicular stabilization. *Eur Spine J* 16: 613–617, 2007
- 30) Park DK, Thomas AO, St Clair S, Bawa M: Percutaneous lumbar and thoracic pedicle screws: a trauma experience. *J Spinal Disord Tech* 27: 154–161, 2014
- 31) Mehdod A, Aunoble S, Le Huec JC: Vertebroplasty for osteoporotic spine fracture: prevention and treatment. *Eur Spine J* 12 Suppl 2: S155–S162, 2003
- 32) Franck H, Boszczyk BM, Bierschneider M, Jaksche H: Interdisciplinary approach to balloon kyphoplasty in the treatment of osteoporotic vertebral compression fractures. *Eur Spine J* 12(Suppl 2): S163–S167, 2003
- 33) http://www.asia-spinalinjury.org/elearning/ASIA_ISCOS_high.pdf. Accessed June 16, 2015
- 34) Mirza SK, Wiggins GC, Kuntz C, York JE, Bellabarba C, Knodoli MA, Chapman JR, Shaffrey CI: Accuracy of thoracic vertebral body screw placement using standard fluoroscopy, fluoroscopic image guidance, and computed tomographic image guidance: a cadaver study. *Spine* 28: 402–413, 2003
- 35) Smith ZA, Sugimoto K, Lawton CD, Fessler RG: Incidence of lumbar spine pedicle breach after percutaneous screw fixation: a radiographic evaluation of 601 screws in 151 patients. *J Spinal Disord Tech* 27: 358–363, 2014
- 36) Heini P, Schöll E, Wyler D, Eggli S: Fatal cardiac tamponade associated with posterior spinal instrumentation. A case report. *Spine* 23: 2226–2230, 1998
- 37) Mobbs RJ, Raley DA: Complications with K-wire insertion for percutaneous pedicle screws. *J Spinal Disord Tech* 27: 390–394, 2014

Address reprint requests to: Nobuyuki Shimokawa, MD, Department of Neurosurgery, Tsukazaki Hospital, 68-1 Waku, Aboshi-ku, Himeji, Hyogo, Japan.
e-mail: nobu-shimo0215@snow.odn.ne.jp