

# A rare case of pancreatic macrocystic serous cystadenoma in an adolescent: a case report and literature review

Journal of International Medical Research

2022, Vol. 50(10) 1–9


© The Author(s) 2022

Article reuse guidelines:

[sagepub.com/journals-permissions](https://sagepub.com/journals-permissions)

DOI: 10.1177/03000605221129102

[journals.sagepub.com/home/imr](https://journals.sagepub.com/home/imr)

Yu-Jui Chang<sup>1</sup>, Hung-Chang Lee<sup>2,3</sup> ,  
Chun-Yan Yeung<sup>2,3,4</sup>, Wai-Tao Chen<sup>2,3</sup> and  
Chuen-Bin Jiang<sup>2,3</sup>

## Abstract

While serous cystadenomas of the pancreas usually consist of small cysts, one rare variant has been reported to be composed of macrocysts. Herein, we present the case of the youngest patient with macrocystic serous cystadenoma (MSC) to be reported in the literature. The patient was a 17-year-old girl who presented with the major symptoms of a palpable abdominal mass accompanied by epigastric pain and vomiting for several months. A potential malignancy could not be excluded on the basis of imaging studies, which showed a large macrocystic pancreatic tumor that was 7 cm in diameter. Owing to the patient's symptoms, after diagnosing the mass as a pancreatic cystic tumor with potential malignancy and large tumor size, surgical intervention was arranged. Pathological analysis of the biopsy sample suggested MSC. By reviewing the literature, we found several unique characters of MSCs that cause them to be frequently misdiagnosed as potential malignancies. Additionally, the age of MSC occurrence was found to be lower than of general serous cystadenomas. The potential of MSC should be kept in mind by clinicians when diagnosing young people with pancreatic macrocystic lesions.

<sup>1</sup>Department of Pediatrics, Taipei City Hospital Zhongxiao Branch, Taipei City

<sup>2</sup>Division of Gastroenterology and Hepatology, Department of Pediatrics, MacKay Children's Hospital, Taipei City

<sup>3</sup>Department of Medicine, MacKay Medical College, New Taipei City

<sup>4</sup>Department of Medical Research, MacKay Memorial Hospital, Taipei City

### Corresponding author:

Hung-Chang Lee, MacKay Memorial Hospital, No. 92, Sec. 2, Zhongshan N. Rd., Zhongshan Dist., Taipei City 104217 (R.O.C.).

Email: [ped2435@ms2.mmh.org.tw](mailto:ped2435@ms2.mmh.org.tw)



## Keywords

Pancreatic neoplasm, serous cystadenoma, mucinous cystic neoplasm, macrocystic lesion, adolescent, case report

Date received: 22 July 2022; accepted: 8 September 2022

## Background

Serous cystadenomas (SCAs) of the pancreas are classified as benign pancreatic tumors and are often found in older individuals. SCAs are often composed of small cysts (<2 cm in diameter) with serous-type epithelial cells. However, one variant form of SCA was later found to be composed of large cysts ( $\geq 2$  cm in diameter) and the same serous-type epithelial cells, so this variant subtype was named macrocystic serous cystadenoma (MSC).<sup>1</sup> MSC is often preoperatively misdiagnosed as other cystic lesions due to its macrocystic architecture.<sup>2</sup> Currently, many studies are searching for a better method of differentiating pancreatic cystic lesions, including MSC.

## Case Report

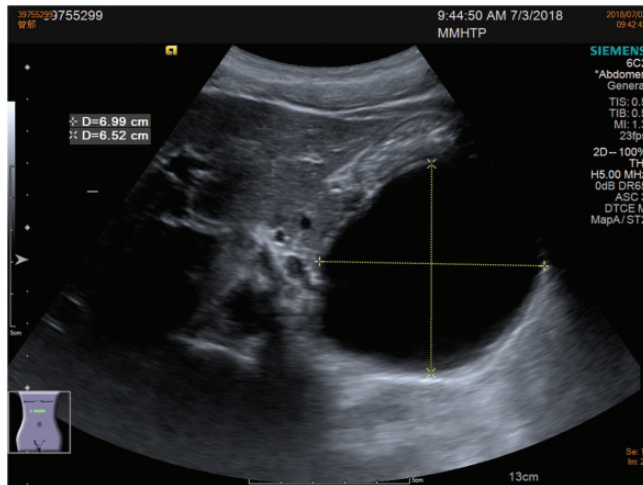
A 17-year-old Asian girl who was a senior at a high school in Taiwan presented with an occasional protruding mass in her left upper quadrant for several months. The mass seemed to vary in size, being palm-sized at its largest, which especially occurred after consuming dairy products, and persisted for periods ranging from hours to days. The accompanying symptoms were intermittent epigastric pain and vomiting.

The patient visited our outpatient department because of the above problems. Laboratory data including hematology, biochemistry, coagulopathy profiles, and levels of the tumor markers carbohydrate antigen 19-9 (CA 19-9), carcinoembryonic antigen (CEA), human chorionic gonadotropin (hCG), and alpha fetoprotein

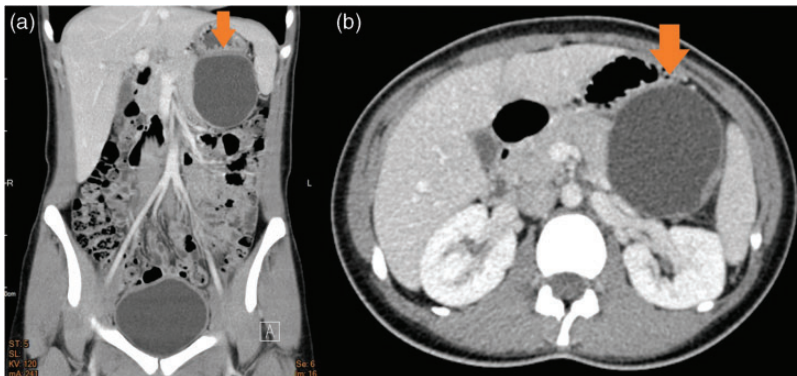
(AFP) were within normal ranges. However, sonography revealed a hypoechoic cystic lesion (6.99 × 6.52 cm) posterior to the stomach and pancreas (Figure 1). Hence, abdominal computed tomography (CT) was performed, which revealed a cystic pancreatic tail lesion (6.3 × 7.1 × 7.1 cm) without splenic vessel involvement or peripancreatic lymphadenopathy (Figure 2). Laparoscopic surgery was then arranged to remove the cyst because the pancreatic cystic tumor had grown to a size that caused the patient discomfort (Figure 3). During the distal pancreatectomy procedure, the surgeons found that the splenic hilar vein varices were encased in the tumor, so simultaneous splenectomy was performed. The whole operation was completed in 8 hours, with an estimated 200 mL blood loss. The patient recovered well without postoperative complications and was discharged after 9 days in the hospital.

The pancreatic cyst specimen measured 8.4 cm in the greatest dimension. Sections revealed that the cystic wall was composed of fibrotic tissues. Microscopically, the epithelial cells of the fibrotic tissue displayed a cuboid pattern (Figure 4a). Additionally, these cells were positive for cytokeratin7 (CK7) and carbonic anhydrase 9 (CA9) but negative for  $\alpha$ -inhibin, which was consistent with the features reported for serous cystadenoma lining cells (Figure 4b,4c,4d). However, there was no evidence of malignancy in the pancreatic specimens.

During the 2 years of postoperative follow-up, the patient has been in good health and without abnormal findings of newly onset tumors or pancreatic



**Figure 1.** Sonography showing a hypoechoic cystic lesion (6.99 × 6.52 cm) posterior to the pancreas.



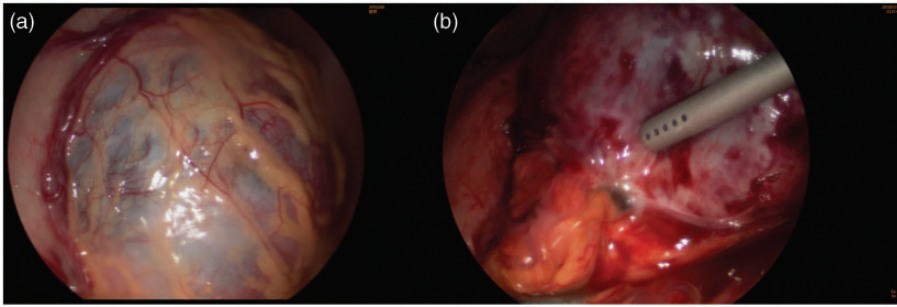
**Figure 2.** (a) Abdominal computed tomography showing a cystic tumor in the tail of the pancreas (arrow) and (b) tumor (arrow) in the abdominal transverse view.

insufficiency. However, the patient sometimes suffers from mild abdominal discomfort such as bloating and nausea when eating greasy food, and her body weight has slightly decreased from 48 to 46 kg after the operation, which has been maintained over the 2 years.

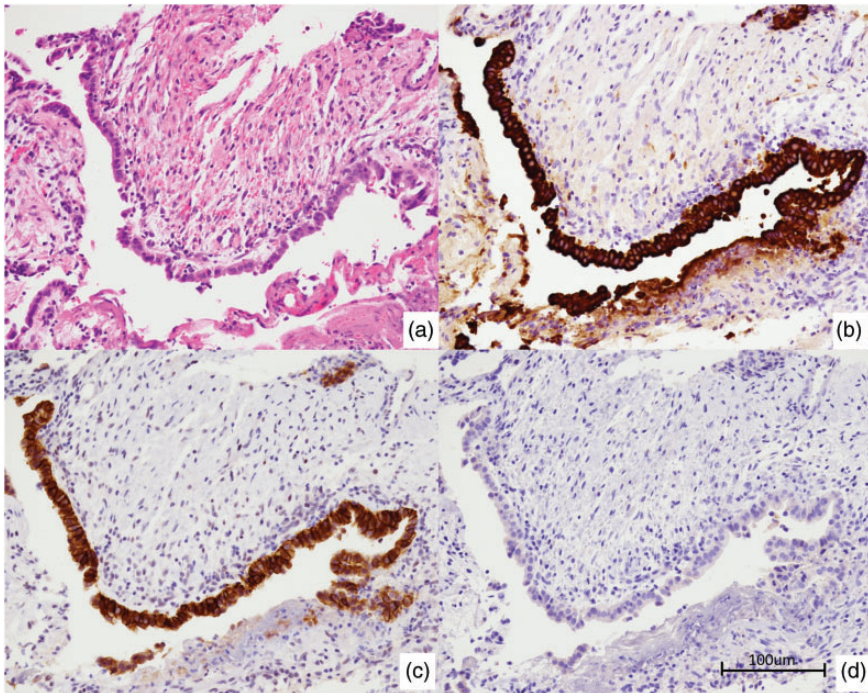
## Discussion

SCA is a rare type of pancreatic cystic lesion, accounting for 2% of all such lesions

in the pancreas.<sup>3</sup> Only 0.5% of SCAs have been diagnosed in individuals under 40-years-old, whereas 80% of SCAs are found in women over 60-years-old. Hence, SCA is also referred to as a “grandmother” tumor.<sup>4</sup> In general, pancreatic cystic lesions are categorized into four types: the microcystic type, macro(oligo)cystic type (such as mucinous tumors), cystic type with a solid component (such as solid pseudopapillary tumors), and diffuse cysts type (such as Von Hippel-Lindau [VHL]-associated



**Figure 3.** (a) Gross appearance of the tumor during surgery and (b) surgery was performed for tumor resection.



**Figure 4.** (a) Hematoxylin and eosin staining (magnification: 200 $\times$ ) of the pancreatic cuboid lining cells; (b) lining cells were positive for cytokeratin 7 (CK7); (c) lining cells were positive for carbonic anhydrase 9 (CA9) and (d) no specific  $\alpha$ -inhibin staining was found in lining cells.

mixed tumors). Most SCAs are composed of multiple small cysts (1–2 cm in diameter) separated by thick fibrous septa and covered by cuboid serous epithelial cells, resembling a honeycomb.<sup>5</sup> Therefore, most SCAs are classified as the microcystic type.

Later, the MSC variant type of SCA was documented to consist of large macrocysts (>2 cm in diameter) rather than multiple small cysts. Additionally, no calcification or stellate scar has been reported over the central cyst of a MSC to date, while this



feature is often applied as a diagnostic tool for SCA. Despite their distinct gross architectures, MSCs are still categorized as a type of SCA due to the presence of cuboid serous epithelial cells. Although MSC was first reported in 1992 by Lewandowski et al.<sup>6</sup>, subsequent case reports of MSC have been rare. We searched for case reports of MSC in PubMed over the past decade (2011–2021) using the keywords “macro-cystic serous cystadenoma” and summarized the characteristics of these cases in Table 1.

Seven case reports of MSC have been published over the past 10 years (2011–2021). Of note, all 10 patients described in these case reports were female. Contrary to the nomenclature of “grandmother tumor” for SCA, the mean age of these MSC patients was 45 years old. Similarly, one retrospective study in 2020 collected data from 26 MSC patients,<sup>2</sup> and their mean age was 48.2 years old. Thus, it is clear that MSC patients are younger than typical SCA patients. Additionally, MSCs can develop at any site within the pancreas, including the head, body, and tail, and can grow up to 20 cm in diameter. However, irrespective of the site of MSC development within the pancreas, tumor size, or age at occurrence, the outcomes were all uneventful after surgery. Interestingly, half of these patients were initially misdiagnosed as having a potential malignancy before surgery. Of note, MSCs are frequently misdiagnosed as mucinous cystic neoplasms (MCNs), primarily due to their similar macrocystic structures. Coincidentally, the age of occurrence is also similar for MCN and MSC (40–50 years), and both tumors tend to develop in women.

To solve the difficulties associated with the differential diagnosis between MCN and MSC, a retrospective study in 2020 collected data from 57 patients and analyzed cyst characteristics. Among the radiological

**Table 1.** Case series of macrocystic serous cystadenoma of the pancreas from the literature.

No.	Age	Sex	Symptoms	Tumor location	Tumor size (cm)	Preoperative diagnosis	FNA cytomorphological features	Postsurgical outcome	Reference year
1	60	F	Abdominal pain	Head	5 × 5 × 4	Tumor	Not done	Uneventful	2021 <sup>7</sup>
2	34	F	Abdominal pain	Head	11 × 8 × 7	Malignancy	Not done	Uneventful	2019 <sup>8</sup>
3	46	F	Abdominal pain	Tail	20 × 15 × 15	Pseudocyst	Not done	Uneventful	2019 <sup>9</sup>
4	40	F	Upper abdominal pain and jaundice	Head and body	9 × 6.7	Benign tumor	Basophilic materials	Uneventful	2016 <sup>10</sup>
5	62	F	Upper abdominal pain and mass	Body	12 × 10	MCN	Not done	Uneventful	2015 <sup>11</sup>
6	39	F	Upper abdominal pain	Tail	9.4 × 7.5	MCN	Not done	Uneventful	2015 <sup>11</sup>
7	38	F	Asymptomatic	Tail	2.3	MCN/SCA	Not conclusive	Uneventful	2015 <sup>11</sup>
8	40	F	Acute pancreatitis	Body	6.2	Pseudocyst/SCA	Not conclusive	Uneventful	2015 <sup>11</sup>
9	63	F	Chronic abdominal pain	Uncinate process	5	MCN	Cells with nuclear atypia	Uneventful	2014 <sup>12</sup>
10	28	F	Asymptomatic	Head	3	MCN	Mucoid contents	Uneventful	2012 <sup>13</sup>

Notes: FNA, fine needle aspiration; MCN, mucinous cystic neoplasm; SCA, serous cystadenoma.

features, they found more frequent occurrences of thicker walls, increased wall enhancement, and oval shape in MCN, while thinner walls, lobulated shape, and absence of wall enhancement were predominantly found in MSC. Nevertheless, the sensitivity and specificity of the resulting model that incorporated radiological features were unsatisfactory (sensitivity: 74.2%, specificity: 80.8%, and accuracy: 77.2%).<sup>2</sup>

Imaging results for MSCs show that they can mimic other pancreatic tumors, and laboratory data show non-specific findings in early stages.<sup>4</sup> Hence, some clinicians have suggested that fine-needle aspiration (FNA) may be helpful for diagnosing SCAs or MSCs. The cytomorphological features of SCA/MSC cyst fluid should include scattered cuboidal cells over a clear background without extracellular mucin or hemosiderin-laden macrophages, but diagnoses that solely rely on judging the cytomorphological features of cystic fluid are also not satisfactory. Reviewing the cases listed in Table 1, FNA examination was performed in 50% (5) of the cases, but only one case presented appropriate FNA cytomorphological features that were compatible with the final diagnosis. Thus, the diagnostic accuracy of cytomorphological features was only 10%. Likewise, in a retrospective study that included 51 SCA patients who underwent cystic aspiration, a correct preoperative diagnosis was established in only five patients, also accounting for approximately 10%.<sup>14</sup>

Therefore, other methods of evaluating FNA specimens have been raised to solve this dilemma. For example, cyst fluid viscosity and CA19-9 and CEA levels have been found to be increased in mucinous cysts, while these values are typically low in benign cystic lesions (CA19-9: <18.5 U/mL, CEA: <34.5 ng/mL). Additionally, amylase levels in cystic fluid have also been applied to distinguish pseudocysts

(>5000 U/L) from serous tumors (<350 U/L).<sup>15-17</sup> A meta-analysis published in 2022 suggested that low glucose levels in cystic fluid (cut-off point: 50 mg/dL) could be used to differentiate mucinous from non-mucinous cysts of the pancreas (sensitivity: 90.8%, specificity: 90.5%).<sup>18</sup> For SCA/MSC, a study from 2020 reported that  $\alpha$ -inhibin-positive cuboidal cells from aspirated cystic fluid could be helpful for diagnosing SCA.<sup>19</sup> However, these conclusions need to be verified by more large-scale studies.

To date, several points of consensus have been made by medical associations regarding surgical intervention criteria for pancreatic cystic lesions. First, according to the 2015 American Gastroenterological Association guidelines for asymptomatic patients, cysts <3 cm in size without risk factors (such as main pancreatic duct dilatation) may be kept under observation instead of immediate surgery.<sup>20</sup> However, further examination is indicated when symptoms develop, if any risk factors are presented, or if there is any development of a solid component. Moreover, the 2018 European study group guidelines recommend surgery for suspected MCN patients harboring >4 cm pancreatic cysts or suffering from symptoms.<sup>21</sup> For the patient in this case report, surgical intervention was the appropriate way to treat the symptomatic pancreatic cystic lesion.

A definitive diagnosis of SCA/MSC is established through biopsy examination. Cuboid serous epithelial cells without malignant characteristics are the most crucial feature to prove SCA or MSC.<sup>22</sup> Additionally, some studies have suggested that immunochemical data can aid in pathological diagnoses. A study of 11 patients reported positive expression of CK7, CK18, and CK19, but negative expression of CK14, CK17, and CK20.<sup>23</sup> Other studies have shown that  $\alpha$ -inhibin and CA9 expression are associated with SCA.<sup>22,24</sup> In our case,

the biopsy examination revealed CK7 and CA9 expression. Interestingly, no  $\alpha$ -inhibin expression was observed in this case.

Although MSC has been reported to be a benign tumor and patients recover well after surgery, close follow-up should be adhered to. This is because a pancreatic lesion could be an initial symptom of VHL disease. VHL disease is an inherited disorder that involves a germline mutation on the short arm of chromosome 3, causing tumors and cysts to grow in multiorgan systems of the body. The percentage of pancreatic neuroendocrine tumors among VHL-disease patients has been reported to range between 8% and 17%, and cystadenoma can occasionally be found in VHL disease.<sup>25,26</sup> So far, MSC alone without other tumors has been observed in this patient for 2 years, and there is no associated family history of VHL disease.

Almost all MSC cases have been reported in patients above middle age. However, this case of a 17-year-old girl is possibly the youngest MSC patient diagnosed to date. It is clear that the tumor grew faster than is expected during a normal clinical course, so the patient developed symptoms earlier, meaning the MSC was diagnosed in adolescence. In conclusion, this special clinical course of MSC is worth surveying, and clinicians should be alert when dealing with adolescents harboring pancreatic cystic lesions.

## Conclusion

We presented the youngest MSC patient so far in the literature. Although MSC is seldom found in young individuals, adolescents can still suffer from MSCs. For young patients harboring pancreatic macro-cystic lesions, MSCs should be kept in mind. Finally, MSCs are often misdiagnosed as mucinous tumors due to their similar imaging results.

## Acknowledgements

We thank Mackay Hospital for support with data collection and appreciate the instructions by the clinical teachers.

## Author contributions

Supervision: HCL, CYY, WTC, and CBJ.

Writing – original draft: YJC

Writing – review and editing: YJC

## Consent to publish

Written consent to publish has been obtained from the study participant. The study participant was over 18-years-old when she signed the written consent.

## CARE guidelines

The reporting of this study conforms to CARE guidelines.<sup>27</sup>

## Consent to treatment

Consent to treatment was obtained from the study participant.

## Data Availability statement

Data are available upon request due to privacy/ethical restrictions.

## Declaration of conflicting interests

The authors have declared that no conflicting interests exist.

## Ethics approval

This study was approved by the Ethics Committee of MacKay Children's Hospital, Taipei City (21MMHIS103e, 2021/05/05).

## Funding

This study was not funded by any company, non-profit, or governmental agency.

## ORCID iD

Hung-Chang Lee  <https://orcid.org/0000-0001-5135-7294>

## References

1. Hsieh YY, Hsueh S, Chen RJ, et al. Macrocystic serous cystadenoma of the pancreas in a young patient resembling a pseudocyst: case report and literature review. *Chang Gung Med J* 2003; 26: 602–606. 2003/11/12.
2. Xie H, Ma S, Guo X, et al. Preoperative differentiation of pancreatic mucinous cystic neoplasm from macrocystic serous cystic adenoma using radiomics: Preliminary findings and comparison with radiological model. *Eur J Radiol* 2020; 122: 108747. 2019/11/25. DOI: 10.1016/j.ejrad.2019.108747.
3. Lombardo C, Iacopi S, Menonna F, et al. Incidence and reasons of pancreatic resection in patients with asymptomatic serous cystadenoma. *Pancreatology* 2018; 18: 577–584. 2018/06/16. DOI: 10.1016/j.pan.2018.06.001.
4. Liu QY, Zhou J, Zeng YR, et al. Giant Serous Cystadenoma of the Pancreas (10cm): The Clinical Features and CT Findings. *Gastroenterol Res Pract* 2016; 2016: 8454823. 2016/09/10. DOI: 10.1155/2016/8454823.
5. Karoumpalis I and Christodoulou DK. Cystic lesions of the pancreas. *Ann Gastroenterol* 2016; 29: 155–161. 2016/04/12. DOI: 10.20524/aog.2016.0007.
6. Lewandrowski K, Warshaw A and Compton C. Macrocystic serous cystadenoma of the pancreas: a morphologic variant differing from microcystic adenoma. *Hum Pathol* 1992; 23: 871–875. 1991/10/01. DOI: 10.1016/0046-8177(92)90397-1.
7. Duzcu SE and Tunc N. Benign macrocystic serous cystadenoma of the pancreas. *Indian J Pathol Microbiol* 2021; 64: S166–S168. 2021/06/18. DOI: 10.4103/ijpm.Ijpm\_945\_19.
8. Theodorou DJ, Theodorou SJ, Kakitsubata Y, et al. Giant serous cystadenoma of the pancreas appearing sonographically as a remote pararenal mass. *J Clin Ultrasound* 2019; 47: 304–307. 2019/03/26. DOI: 10.1002/jcu.22725.
9. Pastor Pérez P, González Valverde FM and Pastor Quirante F. Macrocystic serous cystadenoma of the pancreas. *Hepatobiliary Pancreat Dis Int* 2019; 18: 587–589. 2019/04/27. DOI: 10.1016/j.hbpd.2019.04.005.
10. Koncoro H, Putra IK and Wibawa ID. Obstructive Jaundice as a Complication of Macrocystic Serous Cystadenoma of the Pancreas. *Acta Med Indones* 2016; 48: 129–133. 2016/08/24.
11. Pravisani R, Intini SG, Girometti R, et al. Macrocystic serous cystadenoma of the pancreas: Report of 4 cases. *International journal of surgery (London, England)* 2015; 21: S98–S101. 2015/06/30. DOI: 10.1016/j.ijso.2015.04.097.
12. Leite I, Palmeiro M, Farchione A, et al. Unilocular macrocystic serous cystadenoma of the pancreas—atypical features: a case report. *Clin Imaging* 2014; 38: 336–339. 2014/01/28. DOI: 10.1016/j.clinimag.2013.12.008.
13. Morales-Oyarvide V and Guzmán-Huerta EA. [Macrocystic serous cystadenoma of the pancreas masquerading as a mucinous cystadenoma: case report]. *Cir Cir* 2012; 80: 278–282. 2013/02/19.
14. Lilo MT, VandenBussche CJ, Allison DB, et al. Serous Cystadenoma of the Pancreas: Potentials and Pitfalls of a Preoperative Cytopathologic Diagnosis. *Acta Cytol* 2017; 61: 27–33. 2016/11/28. DOI: 10.1159/000452471.
15. Alkaade S, Chahla E and Levy M. Role of endoscopic ultrasound-guided fine-needle aspiration cytology, viscosity, and carcinoembryonic antigen in pancreatic cyst fluid. *Endosc Ultrasound* 2015; 4: 299–303. 2015/12/09. DOI: 10.4103/2303-9027.170417.
16. Snozek CL, Mascarenhas RC and O’Kane DJ. Use of cyst fluid CEA, CA19-9, and amylase for evaluation of pancreatic lesions. *Clin Biochem* 2009; 42: 1585–1588. 2009/07/07. DOI: 10.1016/j.clinbiochem.2009.06.020.
17. Talar-Wojnarowska R, Pazurek M, Durko L, et al. Pancreatic cyst fluid analysis for differential diagnosis between benign and malignant lesions. *Oncol Lett* 2013; 5: 613–616. 2013/02/20. DOI: 10.3892/ol.2012.1071.
18. Mohan BP, Madhu D, Khan SR, et al. Intracystic Glucose Levels in Differentiating Mucinous From Nonmucinous Pancreatic Cysts: A Systematic Review and Meta-analysis. *J Clin Gastroenterol* 2022; 56: e131–e136. 2021/03/19. DOI: 10.1097/mcg.0000000000001507.



19. Sydney GI, Ioakim KJ, Michaelides C, et al. EUS-FNA diagnosis of pancreatic serous cystadenoma with the aid of cell blocks and  $\alpha$ -inhibin immunochemistry: A case series. *Diagn Cytopathol* 2020; 48: 239–243. 2019/12/01. DOI: 10.1002/dc.24348.
20. Vege SS, Ziring B, Jain R, et al. American gastroenterological association institute guideline on the diagnosis and management of asymptomatic neoplastic pancreatic cysts. *Gastroenterology* 2015; 148: 819–822; quiz:812-813. 2015/03/26. DOI: 10.1053/j.gastro.2015.01.015.
21. European Study Group on Cystic Tumours of the Pancreas. European evidence-based guidelines on pancreatic cystic neoplasms. *Gut* 2018; 67: 789–804. 2018/03/27. DOI: 10.1136/gutjnl-2018-316027.
22. Charville GW and Kao CS. Serous Neoplasms of the Pancreas: A Comprehensive Review. *Arch Pathol Lab Med* 2018; 142: 1134–1140. 2018/08/25. DOI: 10.5858/arpa.2017-0195-RS.
23. Yasuhara Y, Sakaida N, Uemura Y, et al. Serous microcystic adenoma (glycogen-rich cystadenoma) of the pancreas: study of 11 cases showing clinicopathological and immunohistochemical correlations. *Pathol Int* 2002; 52: 307–312. 2002/05/29. DOI: 10.1046/j.1440-1827.2002.01352.x.
24. Kosmahl M, Wagner J, Peters K, et al. Serous cystic neoplasms of the pancreas: an immunohistochemical analysis revealing alpha-inhibin, neuron-specific enolase, and MUC6 as new markers. *Am J Surg Pathol* 2004; 28: 339–346. 2004/04/24. DOI: 10.1097/00000478-200403000-00006.
25. Laks S, Van Leeuwen R, Patel D, et al. Management recommendations for pancreatic manifestations of von Hippel-Lindau disease. *Cancer* 2022; 128: 435–446. 2021/11/05. DOI: 10.1002/cncr.33978.
26. Lonser RR, Glenn GM, Walther M, et al. von Hippel-Lindau disease. *Lancet* 2003; 361: 2059–2067. 2003/06/20. DOI: 10.1016/s0140-6736(03)13643-4.
27. Gagnier JJ, Kienle G, Altman DG, et al. The CARE guidelines: consensus-based clinical case reporting guideline development. *Headache* 2013; 53: 1541–1547. 2013/11/26. DOI: 10.1111/head.12246.