

Recurrent mucormycosis – Better understanding of treatment and management

Karthika Panneerselvam¹, M. Sathish Kumar¹, Karthikeyan²,
A. Mathan Mohan²

Departments of ¹Oral Pathology and Microbiology, ²Oral and Maxillofacial Surgery, Karpaga Vinayaga Institute of Dental Sciences, Chinna Kolambakkam, Kanchipuram Dist., Madurantagam, Tamil Nadu, India

ABSTRACT

Mucormycosis is a rare opportunistic, aggressive, fatal fungal infection. The fungal organisms are ubiquitous and easily affect immunocompromised patients. It is spread on inhalation, inoculation and wound contamination and is more common in diabetic and other immunocompromised individuals in a population. The clinical and radiological features of Mucormycosis can overlap with other conditions for which a thorough diagnosis should be made. The rate of recurrence in Mucormycosis cases is high. This article reports one such case in which recurrence occurred twice and was controlled only with resection. The main aim of this article is to emphasize the importance of practicing aggressive resection and also on regular follow up of the patient after surgical management. Knowledge on different diagnostic and treatment methods, availability of newer drugs and regular follow up can greatly help in the management and recurrence of Mucormycosis even in immunocompromised patients in a population where diabetes is more common and mortality of rhino cerebral form is high.

Keywords: Drugs, follow up, mucormycosis, recurrence, surgeries

Introduction

Mucormycosis is caused by fungi organism belonging to Zygomycetes class. Mucorales and Entomophthorales are the two orders belonging to the Zygomycetes class. Most common organism, Rhizopus that causes Mucormycosis belongs to Mucorales order.^[1] The organisms occur predominantly in individuals with compromised immunity, burn injuries, trauma.^[2] There are various clinical forms of mucormycosis and Rhino cerebral is one of the most common.^[1] The mode of spread of the infection is through inhalation of spores, wound contamination, consumption and direct inoculation.^[3] Cases of

mucormycosis through open mucosal wound following dental extractions are also reported.^[4]

Case Report

A 45-year-old female patient came to OP with complaints of pain in left upper jaw for the past one month. On examination patient was moderately built and nourished. The patient gave a medical history of diabetes for the past 10 years and was under medication. Further, patient revealed history of extraction of posterior teeth done in left upper jaw followed by curettage due to fungal infection. On clinical examination extra orally the skin appeared normal. Intraorally multiple, lobulated swelling with pus discharge were seen. The swelling extended from 23 to 28 on buccal and palatal surface. Partial maxillectomy along with curettage was done. The histopathological study showed pseudo stratified ciliated columnar epithelium and underlying fibro vascular connective tissue with branching fungal hyphae and

Address for correspondence: Dr. Karthika Panneerselvam, Karpaga Vinayaga Institute of Dental Sciences, GST Road, Chinna Kolambakkam, Palayanoor (PO), Chengalpattu (Dt), Madhurantagam - 603 308, Tamil Nadu, India.
E-mail: karthikaomfp@gmail.com

Received: 21-06-2020

Revised: 08-09-2020

Accepted: 08-10-2020

Published: 31-12-2020

Access this article online

Quick Response Code:



Website:
www.jfmpc.com

DOI:
10.4103/jfmpc.jfmpc_1220_20

This is an open access journal, and articles are distributed under the terms of the Creative Commons Attribution-NonCommercial-ShareAlike 4.0 License, which allows others to remix, tweak, and build upon the work non-commercially, as long as appropriate credit is given and the new creations are licensed under the identical terms.

For reprints contact: WKHLRPMedknow_reprints@wolterskluwer.com

How to cite this article: Panneerselvam K, Kumar MS, Karthikeyan, Mohan AM. Recurrent mucormycosis – Better understanding of treatment and management. J Family Med Prim Care 2020;9:6279-81.

necrotic area. The case was diagnosed as Mucormycosis. The patient was advised to be under medication of Amphotericin-B. After 2 and half months the same patient reported with pain and swelling in left malar region. On examination, extra orally a diffuse swelling was present on the left zygomatic region. Intraorally the swelling extended antero posteriorly from 23 to 28 (edentulous region), medially upto the mid palatal region with pus discharge. CT showed erosion of postero lateral wall of left maxillary sinus with fungal sinusitis. Since the lesion recurred even after primary partial maxillectomy management and Amphotericin – B total maxillectomy of left maxilla was done with adequate curettage. The histopathological findings revealed polyploid mass lined by pseudostratified columnar epithelium and focus of epithelioid cells granuloma surrounded by lymphocytes and foreign body type of giant cells. The centre of the granuloma showed ill-defined, broad, aseptate fungal hyphae, confirming Mucormycosis. The case was again diagnosed as Mucormycosis. [Figures 1 and 2] Patient is now under regular follow up and control of blood sugar level is ensured.

Discussion

Mucormycosis has indistinct clinical and radiographic presentation that can overlap with other conditions. Histopathology is considered as the gold standard for diagnosis.^[5] Histopathologically, the lesion is characterized by presence of fungal hyphae. Under microscope the aseptate hyphae are ribbon-like with smaller width, branched at acute angles to right angles. The hyphae are identified by hematoxylin and eosin stain, Periodic acid Schiff stain (PAS) and GMS (Grocotts-Gomori Methenamine Silver Stain).^[5] GMS is the ideal stain to identify the fungus. It is best cultured in potato dextrose agar, sabourads dextrose agar and brain heart infusion agar.^[6]

Aspergillus also can cause Rhino orbito cerebral infection and the differentiation between the two is important for effective antifungal treatment. In cases of co-infection with Aspergillus, molecular techniques like Mucorales-specific PCR technique

and ITS2 PCR could be used for Mucorales and Aspergillus respectively for specific identification.^[7]

In this case report we would like to highlight the possible causes of recurrence. The various factors could be (1) Inappropriate treatment and follow up. (2) Inappropriate medications. (3) neglecting adjunct therapies that improve the patients' immunity.

Surgeries are significant in treating mucormycosis. In initial cases endoscopic approach is preferred and in extensive cases open surgery is the choice of treatment. Open surgeries involve maxillectomy, craniofacial resection and orbital exteneration. In a study involving 22 patients, determining the relationship between the extent of surgery and local control, in 90% of patients local control was achieved following radical surgery compared to 41.6% in patients with alternate methods.^[2]

In our case the patient had undergone curettage primarily followed by partial maxillectomy due to recurrence of the lesion. It was only after aggressive treatment of total maxillectomy, the recurrence was controlled. Complete resection of the lesion was done to prevent the spread of the infection and to ensure effective use of drugs.

It is important to know that the microorganism has angioinvasive property which leads to formation of thrombus and ischemia. Both encourage the growth of microorganism and prevent proper delivery of drugs to the infected site facilitating its spread. In those conditions early, aggressive surgical intervention is very essential for successful management of infection and to enhance the survival of the patient.^[8]

New formulations of Amphotericin B like Liposomal Amphotericin B is successful in the management of Mucormycosis. Azoles like Isavuconazole and Posaconazole (oral suspension, delayed release tablets and infusion) are also used as first line treatment drugs. There is no definite data for combination therapy though some authors have mentioned combination of

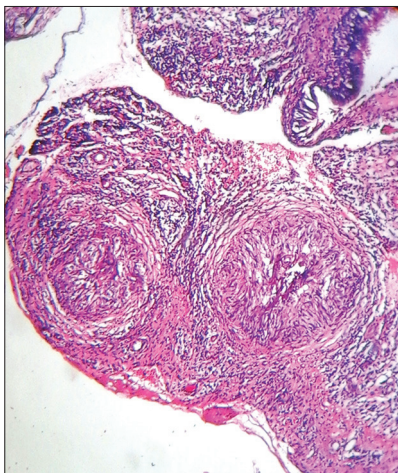


Figure 1: The connective tissue with epithelioid cells granuloma surrounded by inflammatory cells

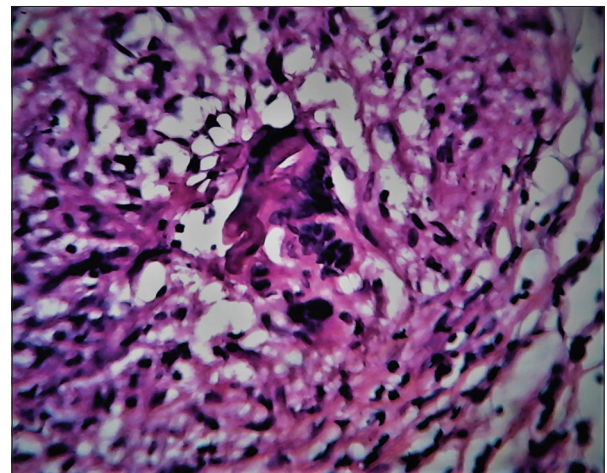


Figure 2: Ill-defined broad aseptate fungal hyphae in the centre of the granuloma

polyenes with echinocandin/azoles. In salvage treatment for Mucormycosis both the azoles are used.^[9]

Adjunct therapies should be considered in the management of Mucormycosis. Use of hyperbaric oxygen kills the fungus by providing oxygen to neutrophils. Diabetic patients should be monitored for regular intake of insulin and oral hypoglycemic medication. Likewise, patients on immunosuppressant and steroids could be advised to stop consumption or minimize the dosage. Overall immunity could be improved by administering granulocyte colony stimulating factors.^[10] In our case, adequate post – surgical care was taken to improve the overall immunity of the patient and blood sugar level was monitored.

Conclusion

Mucormycosis is a common fungal infection in diabetic patients and has greater rate of recurrence. In a population where diabetes is very common, knowledge regarding management of Mucormycosis is essential. Aggressive treatment of resection could be employed immediately after studying the patient's status as it can greatly reduce the recurrence. Administration of drugs that are appropriate to the patient and regular follow up is essential to improve the overall immunity of the patient which also controls recurrence.

Declaration of patient consent

The authors certify that they have obtained all appropriate patient consent forms. In the form the patient(s) has/have given his/her/their consent for his/her/their images and other clinical information to be reported in the journal. The patients understand that their names and initials will not be published and due efforts will be made to conceal their identity, but anonymity cannot be guaranteed.

Financial support and sponsorship

Nil.

Conflicts of interest

There are no conflicts of interest.

References

1. Jayachandran S, Krithika C. Mucormycosis presenting as palatal perforation. *Indian J Dent Res* 2006;17:139-42.
2. Sipsas NV, Gamaletsou MN, Anastasopoulou A, Kontoyiannis DP. Therapy of mucormycosis. *Fungi* 2018;4:90.
3. Manjunatha BS, Das N, Sutariya RV, Ahmed T. Mucormycosis of the hard palate masquerading as carcinoma. *Clin Pract* 2012;2:e28.
4. Tran D, Schmit B. An aggressive mucormycosis. *Cureus* 2020;12:e9610.
5. Rai S, Misra D, Misra A, Jain A, Jain P, Dhawan A. Palatal mucormycosis masquerading as bacterial and fungal osteomyelitis: A rare case report. *Contemp Clin Dent* 2018;9:309-13.
6. Bist SS, Varshney S, Bisht M, Gupta N, Bhatia R. Isolated palate ulcer due to mucormycosis. *Indian J Otolaryngol Head Neck Surg* 2008;60:79-82.
7. Zaman K, Rudramurthy SM, Das A, Panda N, Honnavar P, Kaur H, *et al.* Molecular diagnosis of rhino-orbito-cerebral mucormycosis from fresh tissue samples. *J Med Microbiol* 2017;66:1124-9.
8. Rapidis AD. Orbitomaxillary mucormycosis (Zygomycosis) and the surgical approach to treatment: Perspectives from a maxillofacial surgeon. *Clin Microbiol Infect* 2009;15(Suppl 5):98-102.
9. Cornely OA, Alastruey-Izquierdo A, Arenz D, Chen SC, Dannaoui E, Hochhegger B, *et al.* Global guideline for the diagnosis and management of mucormycosis: An initiative of the European confederation of medical mycology in cooperation with the Mycoses study group education and research consortium. *Lancet Infect Dis* 2019;19:e405-21.
10. Bhandari J, Thada PK, Nagalli S. Rhinocerebral Mucormycosis. *StatPearls [Internet]* 2020.