

Ultrasonographic optic nerve sheath diameter as a noninvasive marker for intracranial hypotension

Li-juan Wang, Ying Zhang, Cong Li, Ying Liu, Ya-nan Dong, Li Cui and Ying-qi Xing 

Ther Adv Neurol Disord

2022, Vol. 15: 1–9

DOI: 10.1177/
17562864211069744

© The Author(s), 2021.
Article reuse guidelines:
sagepub.com/journals-
permissions

Abstract

Background: Invasive intracranial pressure (ICP) can result in complications, pain, or even aggravate intracranial hypotension (IH) or headache in patients with IH.

Objective: To investigate whether ultrasonographic measurements of optic nerve sheath diameter (ONSD) could serve as a noninvasive IH marker.

Methods: Ultrasonographic ONSD was measured prior to lumbar puncture (LP) and ONSD measurements compared to LP's opening pressure. We analyzed correlations between ONSD and ICP and determined the optimal ONSD cut-off point for IH. According to their LP on admission, patients were divided into three groups: IH group, normal ICP group, and elevated ICP group. Correlations between ONSD and ICP were analyzed using Pearson's correlation. A receiver operating characteristic (ROC) curve was generated to determine the optimal cut-off point for IH.

Results: In total, 136 subjects (75 men, 55.1% men) were included, and 1088 ONSDs were measured. The ONSD of the IH group (2.96 ± 0.15 mm) was significantly lower than that of the normal (3.59 ± 0.33 mm) and elevated ICP groups (4.90 ± 0.42 mm, $p < 0.001$). There was a significant difference in ONSD within all groups ($p < 0.001$), and the differences between the two groups were also statistically significant. ONSD and ICP values were strongly correlated, with an $r = 0.952$ [95% confidence interval [CI]: 0.924–0.969; $p < 0.001$]. After adjusting for age, diastolic blood pressure, systolic blood pressure, body mass index, waistline, and head circumference, ONSD was positively associated with ICP. ROC curve analysis revealed an area under the curve of 0.990 [95% CI: 0.975–1.000]. The ONSD cut-off point for identifying decreased opening pressure on LP was 3.15 mm, with 98.3% sensitivity and 91.7% specificity.

Conclusions: Ultrasonographic ONSD may be a noninvasive, valuable, and easy-to-perform bedside technology for evaluating IH.

Keywords: intracranial hypotension, invasive intracranial pressure, optic nerve sheath diameter, receiver operating characteristic, ultrasound

Received: 20 August 2021; revised manuscript accepted: 9 December 2021.

Introduction

Intracranial hypotension (IH) or elevated intracranial pressure (ICP) mainly manifests through headaches. IH is a syndrome with various etiologies and clinical presentations, characterized by orthostatic headache and low cerebrospinal fluid (CSF) pressure. IH mainly manifests by the postural features of headaches and the presence of associated symptoms.¹ However, the clinical

spectrum is surprisingly varied. Headache does not invariably occur within a short time after adopting the upright posture, as many other patterns of headache have been reported, such as nonpositional headache, exertional headache, or second half-of-the-day headache.² The opening pressure on lumbar puncture (LP) is typically used to diagnose this disease. Although this invasive measurement is often helpful, it is complicated by miseries;

Correspondence to:

Li Cui
Department of Neurology,
The Neuroscience Center,
The First Hospital of Jilin
University, Xinmin Street
71, Changchun 130021,
China.
lcui@jlu.edu.cn

Li-juan Wang
Ying Zhang
Cong Li
Ying Liu
Ya-nan Dong
Department of Neurology,
The Neuroscience Center,
The First Hospital of Jilin
University, Changchun,
China

Ying-qi Xing
Department of Neurology,
The Neuroscience Center,
The First Hospital of Jilin
University, Changchun,
China
Center of Vascular
Ultrasonography,
Beijing Institute of
Brain Disorders and
Department of Vascular
Ultrasonography, Xuanwu
Hospital, Capital Medical
University, Beijing, China

even one-third of patients might experience post-LP headache.³ Furthermore, due to CSF outflow, LP might aggravate IH or headache in patients with IH. In addition, IH-induced headaches are caused by reduced CSF volume or pressure, and headaches may develop secondary to LP.⁴ Therefore, a simple, noninvasive and repeatable diagnostic technology that can aid diagnosis and follow-up is needed.

In recent years, ultrasonographic optic nerve sheath diameter (ONSD) has been increasingly used to assess elevated invasive ICP.⁵⁻⁸ However, there is currently insufficient data to determine the utility of ultrasonographic ONSD in IH.⁶ Since abnormal ICP, not just high but low, causes clinical headaches, it is important to determine whether ONSD can specifically identify high and low ICP. Therefore, this study investigated whether ultrasonographic measurements of ONSD could serve as a noninvasive marker of IH.

Methods

Study setting

The study was performed in the US center in the Department of Neurology at the First Hospital of Jilin University, a general public hospital in China. The protocol was designed from September 15, 2018, to November 31, 2018, and approved by the ethics committee of the First Hospital of Jilin University on January 10, 2019 (approval number, 2019-209). All methods adhered to relevant guidelines and regulations. The institutional review board approved the enrollment of patients who needed LP. All participants were informed that the obtained ultrasonic ONSD measurements would be compared to their opening pressure on LP, to which they provided written informed consent.

Patients

We prospectively recruited patients admitted to our neurology department who needed to undergo LP between February 2019 and December 2020. ONSD was measured using ultrasound in each patient prior to LP. $ICP \leq 60$ mmH₂O was considered as IH,⁹ whereas $ICP > 200$ mmH₂O was considered elevated.¹⁰ According to their LP on admission, patients were divided into three groups as follows: group 1 (≤ 60 mmH₂O), group 2 ($60 < LP \leq 200$ mmH₂O), and group 3 ($LP > 200$

mmH₂O). The exclusion criteria were as follows: age < 18 years, ophthalmic diseases, such as optic atrophy, history of glaucoma, tumors or traumas, and administration of medications that may have affected the ICP. In addition, the following patient data were recorded: sex, age, diastolic blood pressure (DBP), systolic blood pressure (SBP), and body mass index (BMI).

Measurements

Ultrasound ONSD examinations were performed in B-mode on a Philips iU22 ultrasound system (Andover, Massachusetts, USA), using a 9.3 MHz linear array transducer. The acoustic output of the ultrasound system needed to be adjusted to the requirements of orbital sonography according to the ALARA ('as low as reasonable achievable') principle to avoid damage to the retina and lens.¹¹ Patients were examined in the supine position. The investigation of both ONSDs for all patients was independently performed by two experienced practitioners, blind to each other's study results or the patients' disease state. Consistent with previous protocols, the probe was placed lightly over the closed upper eyelid with a thick ultrasound gel to prevent pressure on the eye. The probe position was adjusted to clearly display the entry of the optic nerve into the eyeball. The first measurement was performed in the sagittal plane (with the probe in a vertical orientation), and the second in the transverse plane (with the probe in a horizontal orientation).^{12,13} ONSD was assessed bilaterally, 3 mm behind the globe.^{14,15} Each eye was examined twice, and the mean value of the eight total measurements for both eyes was recorded as one observer's measurement. The final ONSD measurement of each patient was derived from the average of the 16 values from the two observers to minimize variability. After ONSD measurements, LP was immediately performed by an experienced neurological resident blinded to the ultrasonographic ONSD results. The CSF opening pressure by LP was recorded in millimeters of water pressure (mm H₂O). Patients were awake and placed in the left lateral position with their hips and knees flexed, and their heads as close to their knees as comfortably possible. The area around the lower back was prepared using an aseptic technique, and patients were asked to relax. After entering the subarachnoid space, patients were asked to straighten their legs, after which the opening pressure on the LP was recorded and fluid samples obtained.

Table 1. Patient characteristics.

| Characteristic | Low ICP group (<i>n</i> = 24) | Normal group (<i>n</i> = 58) | Increased ICP group (<i>n</i> = 54) | <i>p</i> value |
|--------------------------|-----------------------------------|----------------------------------|---|----------------|
| Male (<i>n</i> , %) | 6 (24%) | 35 (60.3%) | 34 (63%) | 0.005 |
| Age (year) | 42.83 ± 11.69 | 44.19 ± 15.66 | 36.11 ± 11.93 | 0.006 |
| ONSD (mm) | 2.96 ± 0.15 | 3.59 ± 0.33 | 4.90 ± 0.42 | <0.001 |
| BMI (kg/m ²) | 23.13 ± 2.53 | 22.73 ± 3.30 | 24.39 ± 4.47 | 0.058 |
| Waistline (cm) | 80.29 ± 6.74 | 80.5 ± 9.35 | 81.74 ± 12.28 | 0.768 |
| Head circumference (cm) | 55.13 ± 1.94 | 55.21 ± 2.01 | 55.28 ± 1.67 | 0.786 |
| SBP (mm) | 123.17 ± 20.03 | 126.66 ± 15.41 | 124.67 ± 18.72 | 0.301 |
| DBP (mm) | 74.45 ± 9.30 | 81.47 ± 9.47 | 80.13 ± 9.58 | 0.015 |

BMI, body mass index; DBP, diastolic blood pressure; ICP, intracranial pressure; ONSD, optic nerve sheath diameter; SBP, systolic blood pressure.

Statistical analysis

For sample size estimation, the PASS software (NCSS) was used. Based on the assumption that the correlation between ONSD and ICP was 0.758,⁸ the required sample size was calculated as 13 participants, with an α error of 0.05 and a statistical power of 91%. All statistical analyses were performed using SPSS (version 24.0; IBM SPSS, IBM Corp, Armonk, NY, USA) and R version 3.4.3 (University of Auckland, Oakland, New Zealand). Continuous variables are presented as median and interquartile range and compared using the Wilcoxon rank sum test. Categorical variables are represented as frequency and percentage and compared using the chi-square test (for unordered categorical variables) or the Wilcoxon rank sum test (ordinal categorical variable). We established scatterplot and generalized additive models (GAMs) using the 'mgcv' package to explore the associations between ONSD and ICP. For ONSD and IH, binary logistic regression analysis was performed to identify the factors that affected this association. A receiver operating characteristic (ROC) curve was generated to determine the optimal cut-off point for IH. Statistical significance was set at $p < 0.05$.

Results

A total of 136 subjects (75, 55.1% males) were included in the study, and 1088 ONSDs were measured. The mean patient age was 40.7 ± 14.04

years (range: 18–80 years). ONSD and ICP ranges were 2.72–6.22 mm and 30–400 mm H₂O, respectively. IH, normal ICP, and elevated ICP were diagnosed in 24, 58, and 54 patients, respectively. A comparison of characteristic data between the elevated opening pressure and normal opening pressure groups is shown in Table 1. Statistically significant differences were found for sex, age, ONSD, DBP, waistline, and head circumference. The ONSD of the IH group (2.96 ± 0.15 mm) was significantly lower than that of the normal (3.59 ± 0.33 mm) and elevated ICP groups (4.90 ± 0.42 mm, $p < 0.001$; Table 1).

Pearson correlation coefficient between the two eyes was 0.989 and that between the two observers was 0.961. A Bland–Altman analysis yielded a mean (SD) difference of -0.0089 (0.048) mm for ONSD. To understand the relationship between ONSD and ICP, we drew a scatter plot to observe the trend distribution (Figure 1). Among the total 136 subjects, ONSD and ICP values were strongly correlated, with an $r = 0.952$ (95% CI: 0.924–0.969; $p < 0.001$). There was a significant correlation between ONSD and ICP, with an r of 0.677 (95% CI: 0.376–0.873; $p < 0.001$), 0.606 (95% CI: 0.441–0.731; $p < 0.001$), and 0.871 (95% CI: 0.757–0.934; $p < 0.001$) in IH, normal ICP, and elevated ICP groups, respectively.

The Wilcoxon rank sum test showed a significant difference in ONSD between the three groups

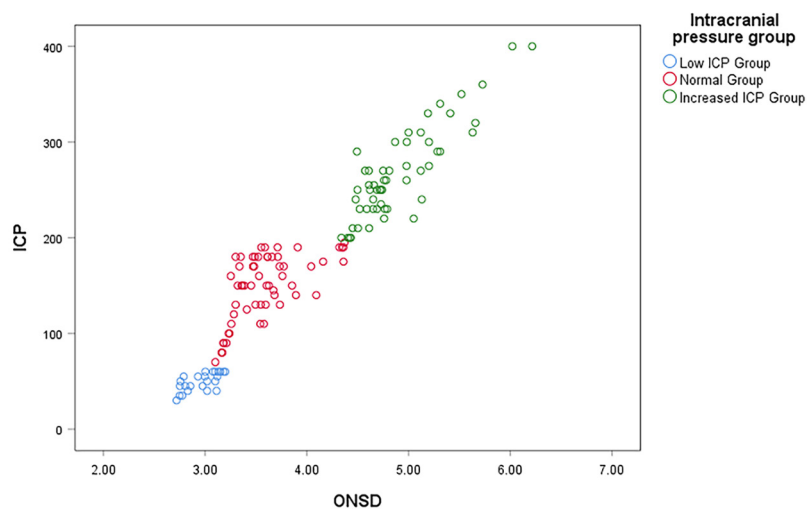


Figure 1. Scatterplot between optic nerve sheath diameter (ONSD) and intracranial pressure (ICP). X-axis represents ONSD, Y-axis ICP.

($p < 0.001$) and that differences between the following two groups were also statistically significant: Elevated-Normal ICP groups ($Z = -56.116$, $p < 0.001$); IH-Normal ICP groups ($Z = -40.236$, $p < 0.001$), and elevated ICP-IH groups ($Z = -96.352$, $p < 0.001$; Table 2).

Since abnormal ICP, both high and low, lead to headache, it is important to determine whether ONSD can specifically identify them. A probability density diagram showed no overlap between the elevated and decreased ICP groups (Figure 2). Furthermore, to confirm this result, we calculated the P95's (3.186) 95% CI as 3.1213–3.1980 for the decreased ICP group and the elevated ICP group P2's (4.375) 95% CI as 4.3424–4.4724. A GAM was performed to confirm the association between them after adjusting for the effects of age, DBP, SBP, BMI, waistline, and head circumference. Figure 3 shows that ONSD was positively associated with ICP. We selected age, sex, BMI, SBP, DBP, waistline, head circumference, and ONSD as the independent variables, and the dependent variable was the ICP group. Only ONSD was included in the logistic regression analysis. Using the opening pressure on LP as the standard criterion, we generated an ROC curve (Figure 4) to determine the optimal cut-off point for sensitivity and specificity. ROC curve analysis revealed an area under the curve (AUC) of 0.990 (95%CI: 0.975–1.000). The ONSD cut-off point for identifying decreased opening pressure on LP was 3.15 mm, with a sensitivity of 98.3% and a specificity of 91.7%.

Table 2. Wilcoxon rank sum test among the different groups.

| Variable | <i>n</i> | <i>Z</i> | <i>p</i> |
|--------------------|----------|----------|----------|
| Three groups | 136 | 114.3 | <0.001 |
| Elevated group | 54 | | |
| Normal group | 58 | | |
| Decreased group | 24 | | |
| Two groups | | | |
| Elevated-normal | 112 | -56.116 | <0.001 |
| Elevated-decreased | 78 | -96.352 | <0.001 |
| Normal-decreased | 82 | -40.236 | <0.001 |

Discussion

This study examined the ONSD and ICP of 136 patients and found that ONSD was positively associated with ICP. In addition, we determined that ultrasonographic ONSD measurement is potentially useful for identifying patients with IH.

Our previous study found that ultrasonographic ONSD correlated with ICP on admission and suggested that this noninvasive method could be potentially useful for identifying patients with elevated ICP.¹⁶ The results of this study are consistent with that of ICP and ONSD values obtained on admission being strongly correlated in different samples. Furthermore, this study focused on the ONSD of patients with IH and confirmed ONSD as a predictor of IH.

To our knowledge, only a few studies have described ONSD in patients with IH. A study including three patients found that the subarachnoid space on magnetic resonance imaging (MRI) is decreased in patients with CSF hypovolemia.¹⁷ Another study using qualitative signs in MRI of 19 patients with CSH showed decreased ONSD diameters.¹⁸ In recent years, a retrospective study of computed tomography (CT) found that ONSD in patients with IH was significantly lower than in hypertension cases.¹⁹ Some reports measured ONSD using MRI^{17,20} or ocular sonography.^{4,21,22} Our study also demonstrated that ONSD decreases in patients with IH. We conjecture that the ONSD depends on pressure and is associated with its peculiar elastic properties. It was reported that the subarachnoid space of the human optic

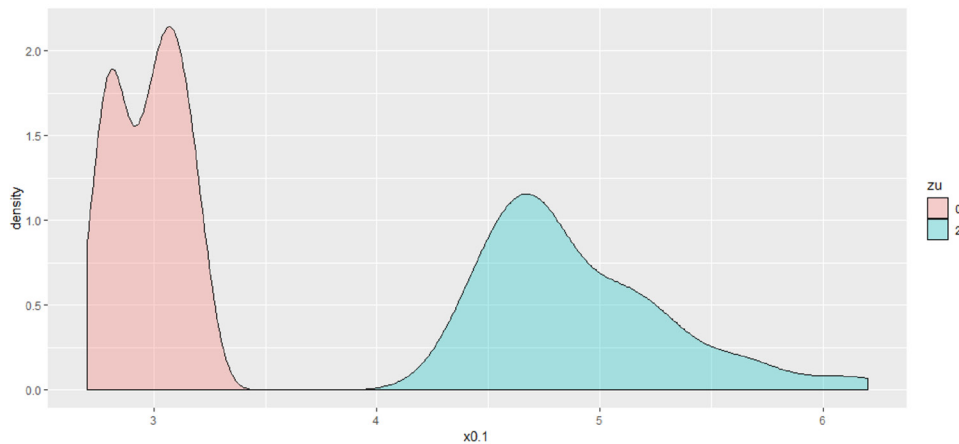


Figure 2. Probability density diagram of increased and decreased intracranial pressure (ICP) groups. X-axis represents optic nerve sheath diameter (ONSD) values, y-axis the probability density. Red represents decreased ICP and blue increased ICP group.

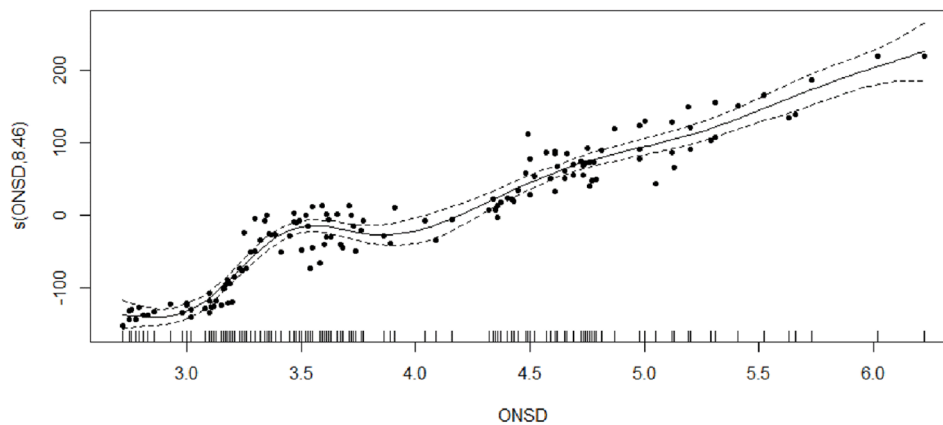


Figure 3. Association between optic nerve sheath diameter (ONSD) and intracranial pressure (ICP) after adjusting for other factors. Y-axis shows the smoothness function value, and the numbers in brackets the estimated degrees of freedom (EDF). The solid line represents the estimated relationship and dotted lines the 95% confidence interval.

nerve contains various trabeculae, septa, and pillars which are arranged between the pia mater and arachnoid. Those elastic complex structures could stretch and shrink.²³ Therefore, the presumably folded trabeculae likely stretch, leading to dilated ONSD when the ICP is elevated. Similarly, the trabeculae could re-fold, and the dilated optic nerve sheath shrinks when ICP is reduced. Our study confirmed that ONSD examinations could evaluate the elevated ICP and IH because of the elastic complex structure of the optic nerve sheath noninvasively and at the bedside (Figure 5).

MRI and CT can also be of diagnostic value in these disorders and have many advantages, such as

high image accuracy and measurements. However, their use is limited by cost, radiation exposure, and transportation. Conversely, ultrasound is a safe, bedside, inexpensive, rapid, well-tolerated modality with the potential to evaluate ICP. Interestingly, in some cases where the MRI showed collapsed subarachnoid space, the optic nerve sheath could not be measured.^{17,20} However, sonographic ONSD can be detected and measured in patients with IH. This is significant for the initial IH diagnosis, and the dynamic observation of changes in IH and assessment of treatment approaches. In addition, other measurement issues of MRI or CT are eye motion artifacts. However, advising the patient to look at a single point in the gantry of the

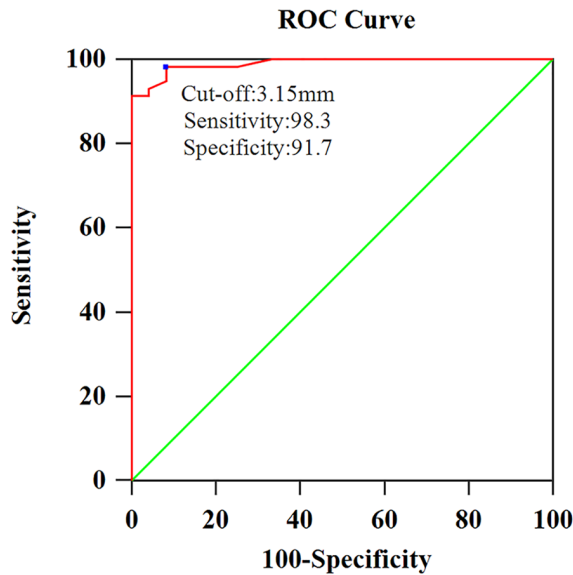


Figure 4. Receiver operating characteristic (ROC) curve for the optic nerve sheath diameter (ONSD). AUC = 0.990. X-axis represents 100-specificity and y-axis sensitivity.

MR or CT scanner may minimize this artifact.²⁴ Furthermore, the duration of MR or CT scans is longer than that of ultrasonography, which can also quickly save images at any time.

Moreover, it is difficult to ensure a specified measurement slice in MRI because the eyes cannot move according to the scan imagery. In addition, MRI slices were not consistently located with respect to eyeball position.²⁰ In contrast, the patient can adjust eye movements in real-time during ultrasound examination to save the best ultrasonographic images and measured sites.

For IH, patients typically complain of orthostatic headaches accompanied by various symptoms, such as photophobia, nausea, neck stiffness, tinnitus, and hearing impairment. In some patients, however, headaches are not orthostatic and may mimic other types of headaches. Elevated ICP can also cause headaches. Therefore, it is important to evaluate ICP in patients with headaches using a noninvasive, easy-to-perform, and

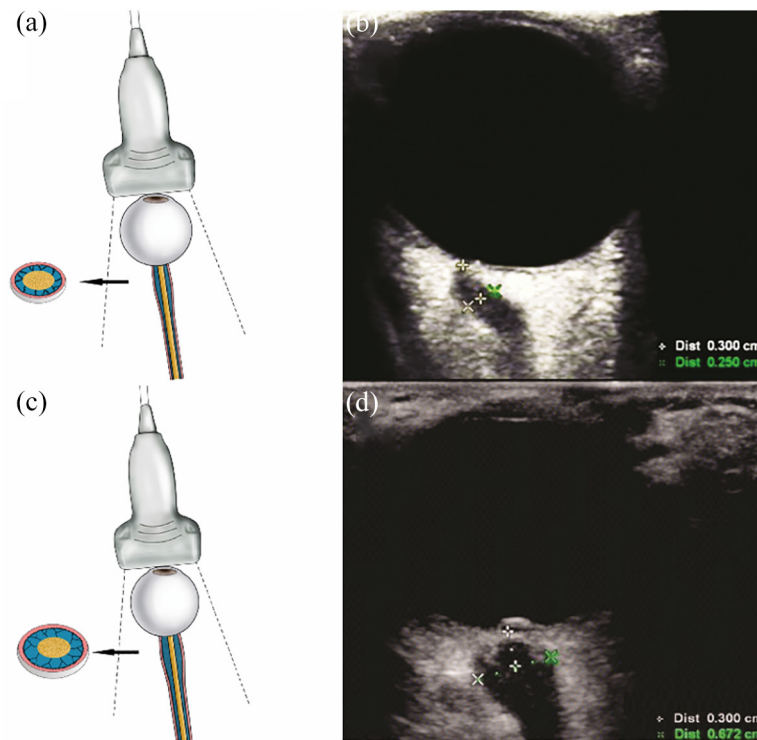


Figure 5. Illustrations and ultrasonography images showing the changes in optic nerve sheath diameter (ONSD): (a) The trabeculae are refolded and the ONSD shrinks during intracranial hypotension. (b) The ultrasonic ONSD was 2.5 mm while the lumbar puncture pressure of this patient was 40 mm H₂O. (c) The folded trabeculae are stretched leading to dilated ONSD while the intracranial pressure (ICP) is elevated. (d) The ultrasonic ONSD was 6.72 mm while the lumbar puncture pressure of this patient was 400 mm H₂O.

cheap technology. Based on this study results, this technology was useful to identify patients with abnormal ICP and efficiently avoid lower ICP in patients with IH undergoing LP (Figure 5). Although LP was regarded as a diagnostic criterion standard, it can cause lower ICP and/or increased headaches; therefore, it is not an ideal diagnostic procedure and should be avoided in these patients. In addition, ultrasound ONSD can avoid invasive monitoring. Infections, hemorrhage, and decalibration in long-term observations are known complications of invasive ICP monitoring. The basic objectives of this study were to explore the benefits of time-saving, effective and complication reduction in noninvasive ICP monitoring.

Furthermore, in recent years, pediatric studies have usually performed ultrasonographic ONSD measurements in patients with increased ICP.^{25,26} The prevention and treatment of IH is always neglected because atypical symptoms and expression are limited in children. It is noninvasive convenient, painless, fast, and could facilitate repeat inspection. Therefore the advantages of ultrasonographic ONSD may be investigated for IH in future pediatric studies. An ONSD protocol posed that the diagnostic accuracy of ONSD ultrasonography varies according to patient characteristics (e.g. age, weight, etc.).²⁵ However, few studies have confirmed whether interindividual factors affect the use of ultrasonographic ONSD measurements as a screening tool for IH. Age, sex, BMI, SBP, DBP, waistline, and head circumference were found to have no significant influence on the relationship between ONSD and ICP in our study. In recent years, some studies have found a decreased ONSD in patients with IH. However, few studies attempted to investigate the cut-off point for IH. In this study, we determined a preliminary cut-off point for IH as a basis for future investigations on the diagnostic value of sonographic ONSD in IH. Our previous study found that ethnic differences or genetic distinctions in ONSD might affect the cut-off point for elevated ICP. Thus, we propose that ethnic differences should be noted and maybe appropriately applied to the corresponding ultrasonographic ONSD criteria for IH in future studies.

Limitations

First, this was a single-center study, and as such, it should be considered a basis for future investigations of sonographic ONSD in IH. Second, the

diagnostic value of ONSD measurements may be limited because of individual variations; therefore, our results are considered preliminary. In the future, the most accurate standard should be confirmed by studies with larger samples to validate the implementation of the technique in the general population. Third, this study included a relatively heterogeneous patient group with various etiologies for IH.

Conclusion

Ultrasonographic ONSD may be a noninvasive, valuable, and easily performable bedside technology for evaluating IH.

Acknowledgements

The authors thank the patients who participated in this study and their relatives.

Author contributions

Li-juan Wang: Data curation; Writing – original draft; Writing – review & editing.

Ying Zhang: Investigation; Methodology.

Cong Li: Investigation; Methodology.

Liu Ying: Investigation; Methodology.

Ya-nan Dong: Data curation.

Li Cui: Conceptualization; Data curation.

Ying-qi Xing: Conceptualization; Data curation.

Conflict of interest statement

The authors declared no potential conflicts of interest with respect to the research, authorship, and/or publication of this article.

Funding

The authors disclosed receipt of the following financial support for the research, authorship, and/or publication of this article: This work was supported by the Fund Project of Jilin Provincial Finance Department (JLSWSRCZX2021-066).

ORCID iD

Ying-qi Xing  <https://orcid.org/0000-0002-7403-5789>

References

1. Headache Classification Subcommittee of the International Headache Society. The International

- Classification of Headache Disorders: 2nd edition. *Cephalgia* 2004; 24: 9–160.
2. Schievink WI. Spontaneous spinal cerebrospinal fluid leaks and intracranial hypotension. *JAMA* 2006; 295: 2286–2296.
 3. Evans RW, Armon C, Frohman EM, *et al.* Assessment: prevention of post-lumbar puncture headaches: report of the therapeutics and technology assessment subcommittee of the American Academy of Neurology. *Neurology* 2000; 55: 909–914.
 4. Beşir A, Tertemiz OF, Akdoğan A, *et al.* The importance of optic nerve sheath diameter in post-dural puncture headache diagnosis and follow-up. *Noro Psikiyatı Ars* 2019; 56: 195–199.
 5. Amini A, Kariman H, Arhami Dolatabadi A, *et al.* Use of the sonographic diameter of optic nerve sheath to estimate intracranial pressure. *Am J Emerg Med* 2013; 31: 236–239.
 6. Tawfik EA, Walker FO and Cartwright MS. Neuromuscular ultrasound of cranial nerves. *J Clin Neurol* 2015; 11: 109–121.
 7. Wang L, Feng L, Yao Y, *et al.* Optimal optic nerve sheath diameter threshold for the identification of elevated opening pressure on lumbar puncture in a Chinese population. *PLoS ONE* 2015; 10: e0117939.
 8. Wang LJ, Yao Y, Feng LS, *et al.* Noninvasive and quantitative intracranial pressure estimation using ultrasonographic measurement of optic nerve sheath diameter. *Sci Rep* 2017; 7: 42063.
 9. Ducros A and Biousse V. Headache arising from idiopathic changes in CSF pressure. *Lancet Neurol* 2015; 14: 655–668.
 10. Kimberly HH, Shah S, Marill K, *et al.* Correlation of optic nerve sheath diameter with direct measurement of intracranial pressure. *Acad Emerg Med* 2008; 15: 201–204.
 11. Ertl M, Barinka F, Torka E, *et al.* Ocular color-coded sonography – a promising tool for neurologists and intensive care physicians. *Ultraschall Med* 2014; 35: 422–431.
 12. Geeraerts T, Launey Y, Martin L, *et al.* Ultrasonography of the optic nerve sheath may be useful for detecting raised intracranial pressure after severe brain injury. *Intensive Care Med* 2007; 33: 1704–1711.
 13. Moretti R, Pizzi B, Cassini F, *et al.* Reliability of optic nerve ultrasound for the evaluation of patients with spontaneous intracranial hemorrhage. *Neurocrit Care* 2009; 11: 406–410.
 14. Tayal VS, Neulander M, Norton HJ, *et al.* Emergency department sonographic measurement of optic nerve sheath diameter to detect findings of increased intracranial pressure in adult head injury patients. *Ann Emerg Med* 2007; 49: 508–514.
 15. Romagnuolo L, Tayal V, Tomaszewski C, *et al.* Optic nerve sheath diameter does not change with patient position. *Am J Emerg Med* 2005; 23: 686–688.
 16. Wang L, Chen L, Chen Y, *et al.* Ultrasonography assessments of optic nerve sheath diameter as a noninvasive and dynamic method of detecting changes in intracranial pressure. *JAMA Ophthalmol* 2018; 136: 250–256.
 17. Watanabe A, Horikoshi T, Uchida M, *et al.* Decreased diameter of the optic nerve sheath associated with CSF hypovolemia. *Am J Neuroradiol* 2008; 29: 863–864.
 18. Rohr A, Jensen U, Riedel C, *et al.* MR imaging of the optic nerve sheath in patients with craniospinal hypotension. *Am J Neuroradiol* 2010; 31: 1752–1757.
 19. Bekerman I, Sigal T, Kimiagar I, *et al.* The quantitative evaluation of intracranial pressure by optic nerve sheath diameter/eye diameter CT measurement. *Am J Emerg Med* 2016; 34: 2336–2342.
 20. Takeuchi N, Horikoshi T, Kinouchi H, *et al.* Diagnostic value of the optic nerve sheath subarachnoid space in patients with intracranial hypotension syndrome. *J Neurosurg* 2012; 117: 372–377.
 21. Dubost C, Le Gouez A, Zetlaoui PJ, *et al.* Increase in optic nerve sheath diameter induced by epidural blood patch: a preliminary report. *Br J Anaesth* 2011; 107: 627–630.
 22. Bauerle J, Gizewski ER, von Stockhausen K, *et al.* Sonographic assessment of the optic nerve sheath and transorbital monitoring of treatment effects in a patient with spontaneous intracranial hypotension: case report. *J Neuroimaging* 2013; 23: 237–239.
 23. Killer H, Laeng H, Flammer J, *et al.* Architecture of arachnoid trabeculae, pillars, and septa in the subarachnoid space of the human optic nerve: anatomy and clinical considerations. *Br J Ophthalmol* 2003; 87: 777–781.
 24. Seitz J, Held P, Strotzer M, *et al.* Magnetic resonance imaging in patients diagnosed with papilledema: a comparison of 6 different high-resolution T1- and T2(*)-weighted 3-dimensional and 2-dimensional sequences. *J Neuroimaging* 2002; 12: 164–171.

25. Dubourg J, Messerer M, Karakitsos D, *et al.* Individual patient data systematic review and meta-analysis of optic nerve sheath diameter ultrasonography for detecting raised intracranial pressure: protocol of the ONSD research group. *Syst Rev* 2013; 2: 62.
26. Bhargava V, Tawfik D, Tan Y, *et al.* Ultrasonographic optic nerve Sheath diameter measurement to detect intracranial hypertension in children with neurological injury: a systematic review. *Pediatr Crit Care Med* 2020; 21: e858–e68.

Visit SAGE journals online
[journals.sagepub.com/
home/tan](https://journals.sagepub.com/home/tan)

 SAGE journals