

Combating Constraints of the Functional Matrix: The Importance of Overcorrection in Pediatric Craniofacial Surgery

Nicholas T. K. Do, MD*
Steven R. Buchman, MD†

Background: To effectively manipulate the bone, particularly in the growing patient, the craniofacial surgeon must understand the principles related to bone-based reconstruction. A theory of craniofacial growth that is both biologically accurate and clinically relevant is thus needed.

Methods: A historical review of major findings across various disciplines (including orthopedic surgery, anatomy, embryology, orthodontics, and cell biology) will be covered, as it pertains to the concept of the functional matrix of the craniofacial skeleton.

Results: The functional matrix dictates the interplay between the soft tissue envelope and bone grafts, thus guiding donor site choice and inset methods. The soft tissue may also warrant the use of bony hypercorrection especially in cranial vault remodeling. Control of both bone and boundaries of the soft tissue functional matrix can be achieved via distraction osteogenesis.

Conclusion: The soft tissue functional matrix must be accounted for during craniofacial bone grafting, mobilizing osteotomies, and distraction osteogenesis if optimal aesthetic results are to be obtained using the least amount of procedures. (*Plast Reconstr Surg Glob Open* 2021;9:e3604; doi: [10.1097/GOX.0000000000003604](https://doi.org/10.1097/GOX.0000000000003604); Published online 24 June 2021.)

INTRODUCTION

The manipulation of the bone is the primary defining skill of the craniofacial surgeon. Although most of plastic surgery concerns itself with the fine handling of the soft tissue, craniofacial surgery necessitates that the surgeon takes his/her education deeper and understands the principles guiding bone reconstruction, specifically the interaction between the skeleton and the soft tissue envelope. Producing a durable, aesthetically pleasing result demands that the craniofacial surgeon understands not just graft physiology but also the biomechanical effects of the soft tissue and anticipating growth-related changes. Skilled bone work in the craniofacial skeleton thus requires the development of a theory of craniofacial growth that is both biologically accurate and clinically relevant.

From the *Division of Plastic Surgery, Harbor-UCLA Medical Center, Torrance, Calif.; †Section of Plastic Surgery, University of Michigan, Ann Arbor, Michigan.

Received for publication November 29, 2020; accepted April 8, 2021.

Copyright © 2021 The Authors. Published by Wolters Kluwer Health, Inc. on behalf of The American Society of Plastic Surgeons. This is an open-access article distributed under the terms of the [Creative Commons Attribution-Non Commercial-No Derivatives License 4.0 \(CCBY-NC-ND\)](https://creativecommons.org/licenses/by-nc-nd/4.0/), where it is permissible to download and share the work provided it is properly cited. The work cannot be changed in any way or used commercially without permission from the journal.

DOI: [10.1097/GOX.0000000000003604](https://doi.org/10.1097/GOX.0000000000003604)

Our knowledge of the genetic underpinnings of bone formation has expanded greatly over the last decades.¹⁻⁵ Although undoubtedly important, genes are only part of the broader set of factors determining morphology. The genomic paradigm assumes a relative immutability of craniofacial skeletal growth and form. However, the origin, growth, and maintenance of all skeletal tissue is always a secondary, compensatory, and obligatory response to temporally and operationally antecedent processes that occur in related non-skeletal tissues, organs, or functioning spaces. In other words, the enveloping soft tissues (brain, eyes, muscles) play a deterministic role in craniofacial development. An overarching theoretical framework for craniofacial growth is needed: one that integrates an understanding of soft tissue, not just as a source of coverage and perfusion, but as a biomechanical force shaping the bone to a form optimized to its functional demands. Such a framework would guide the choice and inset of bone grafts, the design and execution of advancing osteotomies, and the clinical indications for distraction osteogenesis.

To understand the functional interplay between the soft tissue and the bone is to anticipate and even harness its effects and, therefore, execute more intelligent and efficacious interventions in a craniofacial surgery.

Disclosure: The authors have no financial interest to disclose in relation to the content of this article.



Fig. 1. Surgeon Julius Wolff. Published with permission from https://commons.wikimedia.org/wiki/File:Julius_Wolff_CIPB0720.jpg#file.

The dynamic relationship between the soft tissue and the underlying bone is best encapsulated in the concept of the functional matrix. This article therefore aims to provide a description of the functional matrix, and the major scientific advancements leading to it, to better inform operative design and execution in the treatment of craniofacial maladies.

WOLFF'S LAW OF BONE REMODELING AND FUNCTIONAL ORTHOPEDICS

The functional matrix of the craniofacial skeleton is best understood in the broader historical context of bone research. Our current understanding of craniofacial development is built upon the pioneering work of many, including German researchers in the 1800s. The combined efforts of an anatomist, a structural engineer and mathematician, and a surgeon culminated in what is now known as Wolff's Law of Bone Remodeling.

Georg Hermann von Meyer (1815–1892) was one of 19th Century Germany's renowned anatomists. In his key

1867 publication *The Architecture of Cancellous Trabeculae*, he recognized that the *substantia spongiosa* had a “well motivated architecture” with a high degree of mechanical stability.⁶ The references to architectural engineering were the result of a fateful exchange with German structural engineer and mathematician Karl Culmann (1821–1881) at the 1866 Society for Natural Science in Zurich. As noted in his 1867 text, upon von Meyer demonstrating the arched trabecular patterns in sagittal sections of human metatarsals and calcanea, Culmann suggested that these appeared to be aligned along directions of principal stress as would be produced by functional loading.^{6–9} Culmann had already drawn the analogy between the trabecular patterns in the bone and the stress trajectories sustained in a short, solid, cantilevered beam in his own seminal text *Graphical Statics*.¹⁰ At the 1866 meeting, von Meyer and Culmann compared the trabecular architecture in a coronal section of a human proximal femur with the mathematically constructed stress trajectories of a curved, solid crane-like beam resembling a human femur.⁷ The similarities between these calculated stress trajectories and the arched patterns in bony trabeculae would profoundly influence the work of another contemporary German researcher, surgeon Julius Wolff (1836–1902) (Fig. 1).¹¹ Although von Meyer did not mathematically analyze the cancellous trabeculae patterns, Wolff believed there has to be a mathematical relationship between the bone form and the loads borne. Convinced that these similarities between structural engineering and bone architecture could not be coincidental, Wolff would put forth his trajectory theory,^{11–16} summarized as: “the trabeculae of cancellous bone follow the lines of trajectories in the homogeneous body of the same form as the bone and stressed in the same way (Fig. 2).”¹⁷ This theory in turn informed Wolff's most enduring contribution: Wolff's Law of Bone Remodeling.

Building upon the trajectory theory, Wolff would later conclude that not only the internal architecture but the external morphology were both the result of trophic stimulation of function, or functional adaptation, with continuous change taking place in the bone reflecting the mechanical demands placed on it (Fig. 2).^{15,16} Thus, the bone could no longer be considered a static entity but one in a state of dynamic equilibrium in response to its environment. Wolff took his concept further and explained that if the functional adaptation of the bone could explain normative morphology, then it could also explain aberrant pathology as a result of changes in its functional demands.^{15,16} Thus, the *defective form* itself would not be pathological, but rather the *defective stressing* that resulted in the adapted form, was pathological. Linking external forces to explain both the normal and the aberrant, Wolff put forth the clinical implications of functional adaptation: that the surgeon could apply external force and utilize the natural force of remodeling to treat bony deformity.

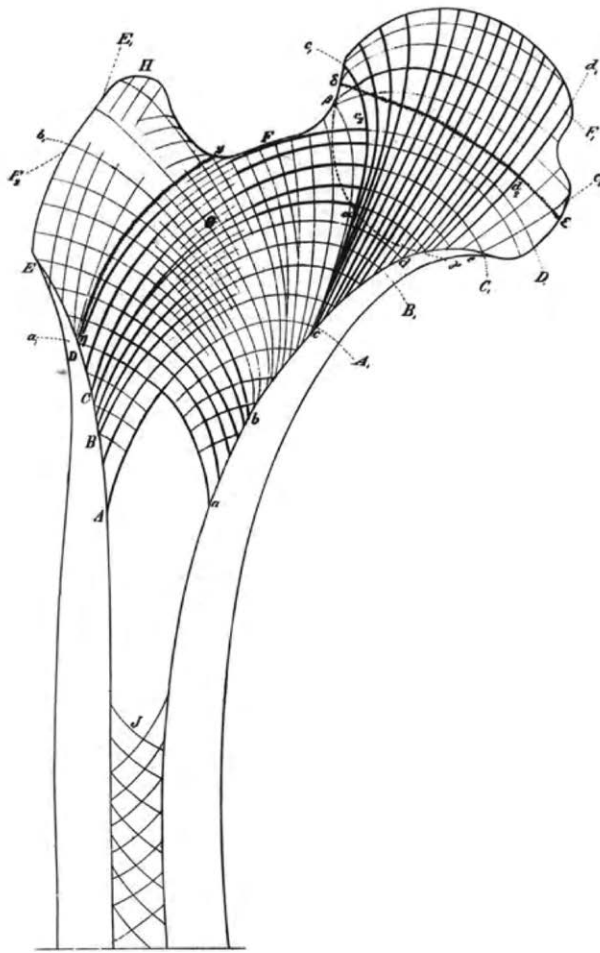


Fig. 2. Images from Wolff's 1892 monograph demonstrating his development of the "trajectory theory" of cancellous bone. A, Illustrations on the mathematical discussion regarding the stress trajectories in structures. B, Wolff's own interpretation of the trabecular structure of the proximal femur and mathematical analysis.¹⁶ Published with permission from Wolff J. *The Law of Bone Remodeling*. In: *The Law of Bone Remodeling*. Berlin, Germany: Springer;1986:126.

FUNCTIONAL ORTHODONTICS AND THE FUNCTIONAL MATRIX

While Julius Wolff was establishing the scientific foundation behind applying forces to treat extremity deformities, developments were afoot across the Atlantic that would set the stage for applying the same basic concept to the craniofacial skeleton. Edward H. Angle (1855–1930), known for his classification of malocclusion,¹⁸ taught in Pennsylvania and Minnesota. His increasing interest in malocclusion and its correction led directly to his development of the field of orthodontics as a distinct dental specialty. He devised a variety of devices, including the edgewise bracket and rectangular arch wire, to apply mechanical force to position teeth into optimal occlusion (Fig. 3). Decades later, basic science investigations revealed that by applying external force to teeth, alveolar bone would remodel in

response to accommodate the manipulated dentition.^{19–21} Angle's concepts tended to be "tooth-centric" and did not wholly integrate in soft tissue considerations. He did concede that the lips and cheeks played a role in shaping the dental arches in malocclusions.¹⁸

Another American dentist would then proceed to put forth evidence of the key role of facial soft tissue in determining shape in the craniofacial skeleton. Melvin Moss was a Columbia-University-trained dentist who returned to Columbia to pursue a PhD in anatomy and physical anthropology (Fig. 4). He had the good fortune to return to one of the great international centers in experimental embryology of that time.²² Moss's doctoral thesis examined the role of sutures in the growth of the skull. Extirpation of the calvarial sutures produced no dimensional decrease in the growing rat skull, thus leading to the conclusion that sutures (bony tissue) were not the primary growth centers acting to force bones apart.²³ Moss later deduced that it was actually the soft tissue contained within (ie, brain) that drove neurocranial growth and that sutures formed as compensatory responses to that growth.²⁴ These findings were key to the development of Moss's most significant intellectual contribution: the functional matrix hypothesis.

One of Moss's critical earlier insights was to move away from the static named entities of traditional osteology (eg, maxilla, mandible) and instead consider bone more dynamically as segments responding in growth to functional demands. Moss published his functional matrix hypothesis in 1962²⁵ and finally clinicians had a theory of bone growth specific to the craniofacial skeleton that was both biologically accurate and clinically relevant. In his theory, Moss posited that growth in the craniofacial skeleton was in contradistinction to that at the epiphyseal plates in long bones. Rather than bone or cartilage as the primary determinant for growth, it appeared that growth in the craniofacial skeleton was reactive to, and thus controlled by, the surrounding soft tissues. Cartilages of the nasal septum, mandibular condyle, nor skull base were the primary drivers of craniofacial growth but instead the cranium and face grew in response to functional needs and neurotrophic influences mediated by soft tissue. Moss was also able to establish that there were 2 distinct types of functional matrix and 2 distinct types of growth: periosteal and capsular matrices; and transformative and translative growth.²⁶ Periosteal matrices occurred where muscle pulled on bone and resulted in direct transformative growth. Capsular matrices occurred where the function of a space stimulated bone. Concurrently, another American scientist, Donald Enlow, developed his corroborating theory of resorptive and depository fields. Enlow posited that transformative and translational growth occurred in some areas by bony deposition and in others by resorption but always in response to soft tissue displacement and not the cause of it.²⁷ At its core, Moss's functional matrix theory was the application of Wolff's Law of bone remodeling to the craniofacial skeleton with an explicit emphasis on soft tissue.

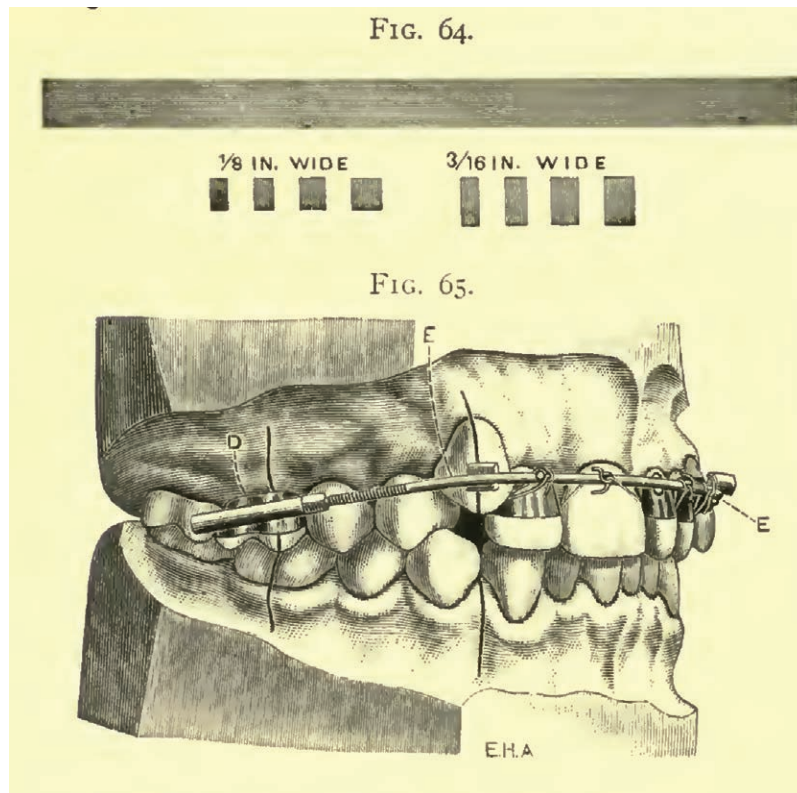


Fig. 3. One of Edward H. Angle's designs for orthodontic appliances from Angle's textbook. Reprinted from Angle EH. Treatment of malocclusion of the teeth and fractures of the maxillae. In: *Angle's System*. 6th ed. Philadelphia, Pa.: SS White Dental Mfg Co;1900 (public domain).

Just as Wolff's work laid the rationale for applying force to therapeutically shape the extremities, so too was it for Moss's work that applying force could be used to treat craniofacial deformities.

MECHANOTRANSDUCTION

Neither Wolff nor Moss explained how functional demands were transmitted to the underlying bone. The question of how tissues "sense" mechanical signals and then transduce them into biological responses still remains, as a whole, incompletely answered. Moss did recognize this deficit and his later work explored the mechanosensory role of osteocytes.²⁸ He sought to integrate these and other cell biology concepts with those of the functional matrix to provide a basis in cellular biology for the response of skeletal tissues to the functional demands of the soft tissue.²⁹⁻³²

However, it would be those formally trained in cell biology that would ultimately bring the brightest illumination to answer how tissues sensed and responded to mechanical stimuli. The concept of mechanotransduction, where mechanical forces can induce intracellular signals and thereby convert biophysical force into cellular response, was pioneered in the early 1990s. Evidence was steadily accumulating that mechanical force was a regulator of cell

function in a variety of tissues. Initiation and elongation of neural axons were regulated by tension.^{33,34} Vascular endothelial cells produced a complex set of responses to shear stress.³⁵ Cultured differentiating myoblasts were found to organize into parallel arrays of fibers and tendons, thereby forming muscle.³⁶

It would be Donald Ingber's laboratory, however, that would establish the architectural basis of cellular mechanotransduction. His laboratory confirmed a mechanical connection amongst extracellular matrix components, cell surface integrin proteins, and the intracellular cytoskeleton, that are responsible for changes in cellular form and function.³⁷ These findings led further support to Ingber's broader concept of cellular *tensegrity* (tensional integrity) in which a continuous network of molecules, including integrins, under tension is supported by discrete compressive struts (cytoskeletal actin fibers, microtubules, etc) (Fig. 5).³⁸ This architectural concept of complementary force interactions among structural elements is in fact the same described by Buckminster Fuller in his geodesic domes. Toward the end of the 20th Century, other researchers would indeed confirm within the bone itself that mechanical stresses yielded changes in signaling cascades by way of integrins and the cytoskeleton.³⁹⁻⁴¹




Fig. 4. Dentist and anatomist Melvin Moss, DDS, PhD. Published with permission from https://en.wikipedia.org/wiki/File:MLMoss_1968.jpg.

CLINICAL UTILITY OF THE FUNCTIONAL MATRIX THEORY IN CRANIOFACIAL SURGERY

Research spanning the fields of anatomy, structural engineering, mathematics, orthopedic surgery, orthodontics, physical anthropology, experimental embryology, and cell biology have culminated in our understanding of the functional matrix, as it pertains to craniofacial growth and form. These broader concepts in bone biology, however, have immediate clinical utility in the specific context of craniofacial surgery. Understanding the functional matrix can inform the use of bone grafts, distraction osteogenesis, and cranial vault remodeling.

Bone Grafting Dynamics

Bone grafting is one of the primary techniques of craniofacial surgery. Grafts can be used to fill defects, provide structural support, and augment/effect projection in deficient dimensions of the craniofacial skeleton. Some of the main challenges in using this technique are graft survival and resorption. Collective clinical experience has demonstrated that bone grafts using calvarial donor sites have superior volumetric maintenance versus those

taken from the ribs, tibia, or ilium. Earlier work ascribed this to factors intrinsic to the bone graft, particularly its embryologic origin.^{42,43} Later efforts revealed that the relative composition of cortical versus cancellous bone is the primary intrinsic factor of bone grafts determining their survival (Fig. 6).^{44,45}

More comprehensive clinical insight has been provided by research evaluating graft inset and recipient site factors, particularly the interplay between recipient environment and bone graft. Bone graft inset can be divided into inlay and onlay techniques. Inlay grafting is primarily for bone gaps (eg, alveolar grafting) where mechanical force is primarily sustained through the graft via being embedded in recipient bone away from soft tissue. Onlay grafting, in contrast, is used to effect bone projection and thus is subject to mechanical force from soft tissue compression onto the graft. Whitaker introduced the concept of biological boundaries, which stated that the soft tissue envelope has a genetically predetermined shape that is inclined to remain constant.⁴⁶ This is admittedly an extension of Moss's functional matrix theory. Applying Moss's theory specifically to bone grafting, Whitaker hypothesized that onlay grafts violate natural soft tissue boundaries and, in turn, a homeostatic response is initiated to maintain that boundary, resulting in graft resorption.

LaTrenta et al corroborated this hypothesis, reporting that inlay bone grafts maintained greater volume and mass than onlay grafts, and attributed this to the favorable remodeling forces with the inlay position.⁴⁷ Buchman examined the influence of both bone graft architecture (cancellous versus cortical) and recipient mechanical environment (inlay versus onlay).^{48,49} With the inlay position, both types of bone graft experience growth but cancellous does so more than cortical (Fig. 7). With the onlay position, both types of bone graft undergo resorption but cortical is more resistant than cancellous (Fig. 8).

Together, these works reveal an essential clinical consideration in bone grafting: the interplay between the mechanical environment and the bone graft architecture is a critical determinant of graft survival. Onlay grafts projecting into a tight soft tissue envelope (ie under muscle) must endure a significant compressive force for which cortical bone grafts can better resist (Fig. 9). Inlay bone grafts are shielded from soft tissue recoil and receive identical physical stresses as the recipient site bone for which cancellous bone more quickly vascularizes.

Modifying the soft tissue to "shield" the bone graft from recoil forces has been hypothesized as another potential strategy to improve bone graft take.⁵⁰ Goldstein et al observed that only bone grafts placed under soft tissue envelopes that had been previously tissue expanded displayed superior survival versus without tissue expansion.⁵¹ Although the authors attributed this to increased local vascularity, mitigated soft tissue mechanical force may also have contributed (Fig. 10).

Alveolar Bone Grafting

While alveolar bone grafting is done to give continuity to the maxillary arcade, the craniofacial surgeon must

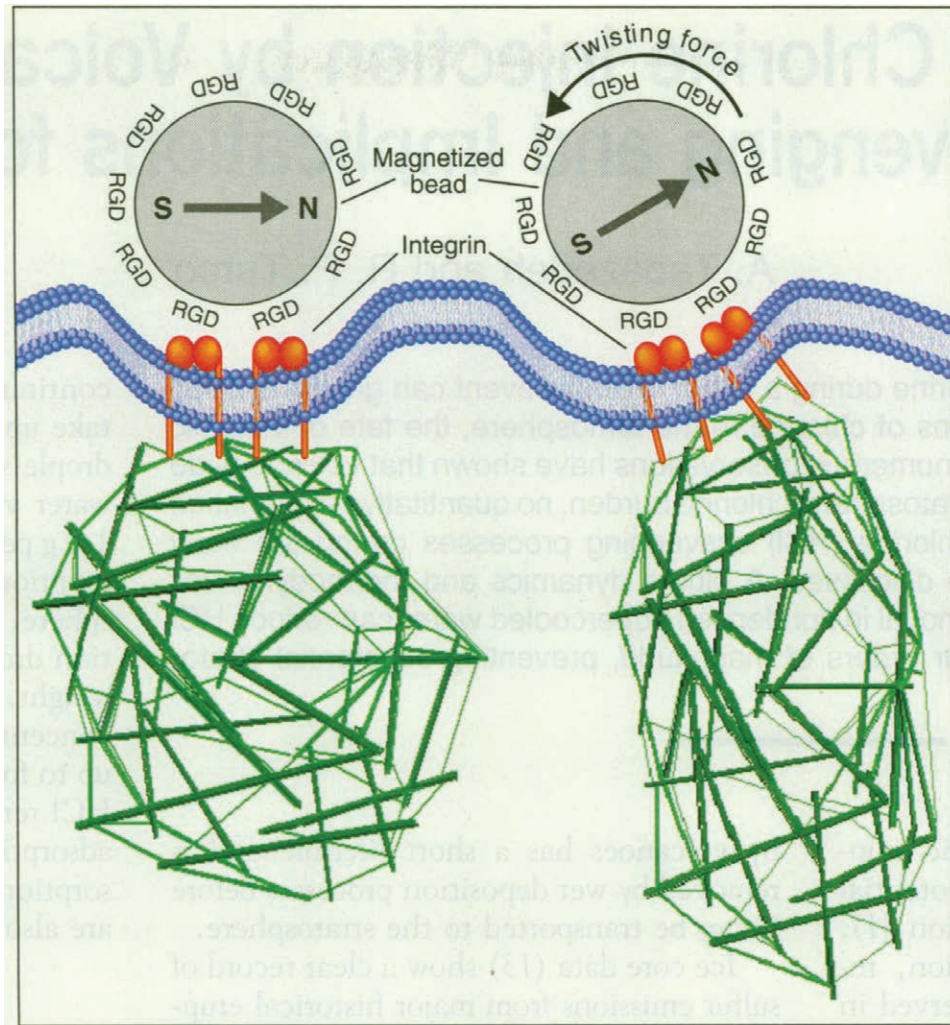


Fig. 5. Diagrammatic representation of Ingber's landmark article. Magnetic beads attached to integrins are restrained by the cytoskeleton in their twisting response to a magnetic field. The constrained extent of twisting suggests tensegrity structure of the cytoskeleton. Published with permission from *Science* 260:1080–1081.

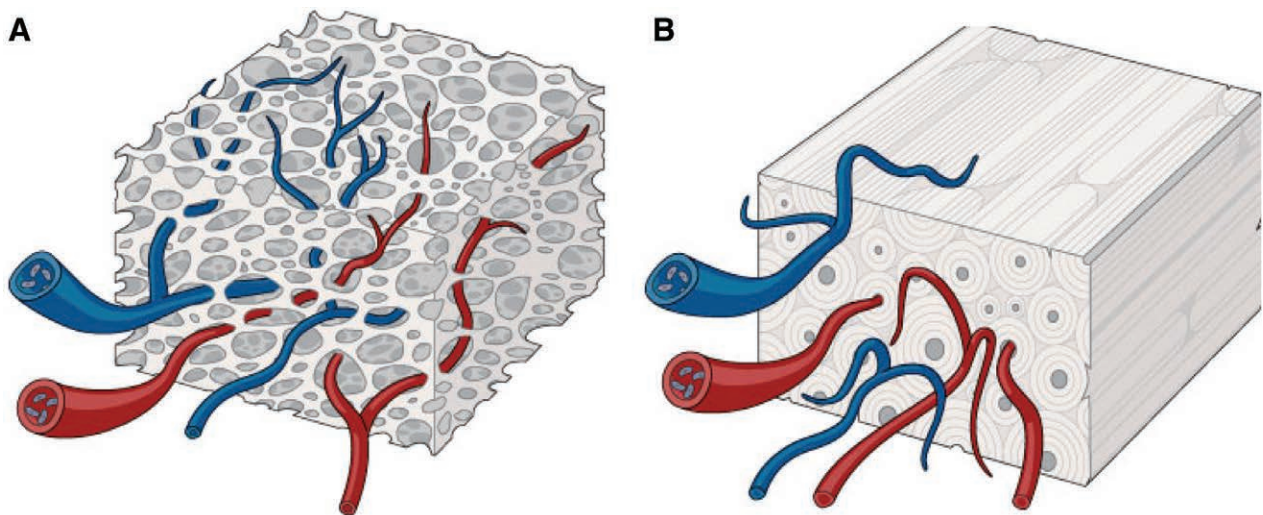


Fig. 6. Influence of bone microstructure on graft take. A, Cancellous bone graft revascularization occurs rapidly and completely due to open, porous architecture. B, Cortical bone graft revascularization occurs slowly and incompletely due to dense, lamellar architecture. Vessels must invade along Haversian & Volkmann's canals. Published with permission from *Craniomaxillofac Trauma Reconstr.* 2008;1:49–61.

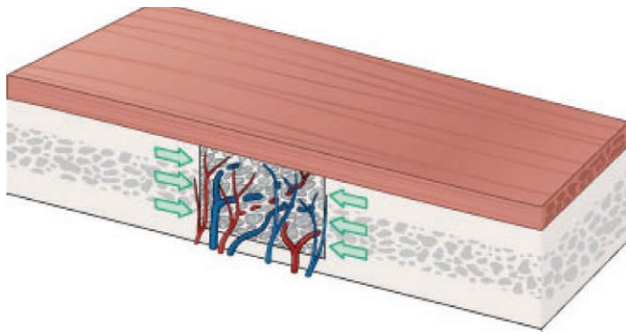


Fig. 7. With the inlay position, bone graft is not subject to compressive soft tissue force but does share the same mechanical force as the surrounding recipient site bone (arrows). Cancellous bone more easily integrates owing to its porous microstructure. Published with permission from *Craniofacial Trauma Reconstr.* 2008;1:49–61.

not lose this opportunity in the growing cleft lip patient to improve facial aesthetics. The characteristic posteriorly displaced ipsilateral nasal alae can be advanced with an overcorrection of inlay cancellous iliac bone in the bony cleft. The soft tissue recoil of the face onto the graft can then be buttressed against using onlay cortical bone spanning the defect edges.

Cranial Vault Remodeling

Pediatric craniofacial surgery demands that the surgeon “operate in the 4th dimension” (ie, time) to attain a superior result using the least amount of procedures. Anticipating the growth and constraints of all tissues, particularly the soft tissue functional matrix, is thus paramount. The treatment of craniosynostosis, where one must anticipate growth of the skull, scalp, and brain, is demonstrative of this. The classic features of metopic craniosynostosis (trigonocephaly, supraorbital rim recession, and bitemporal constriction) have proved difficult to treat and are prone to relapse.^{52,53} Temporal hollowing and lateral orbital retrusion occur in up to half of all patients⁵⁴ with re-operative rates approaching 28%.⁵⁵ Scalp closure tension, and recoil of the soft tissue after significant

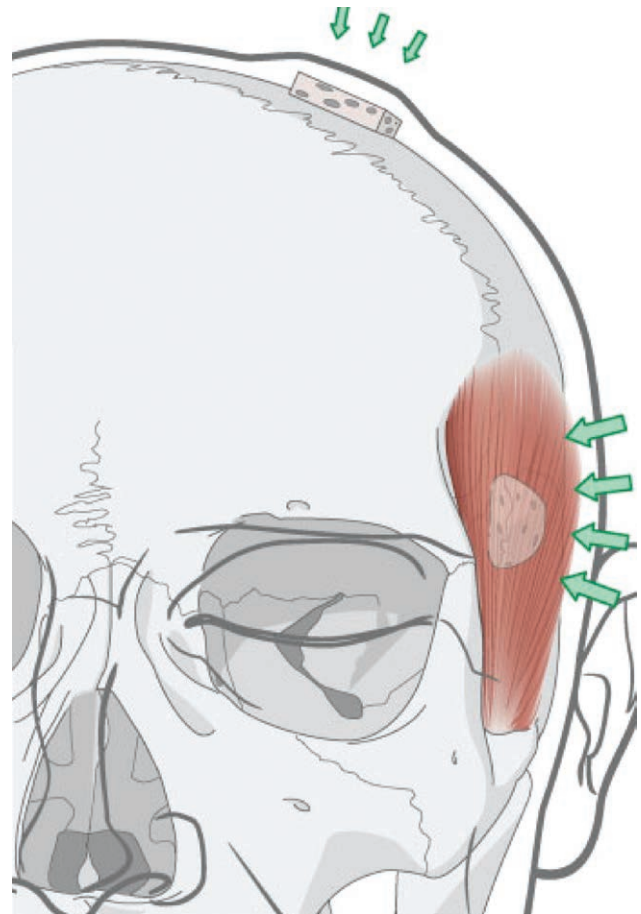


Fig. 9. Differences in soft tissue envelope will result in differing degrees of resorption as a function of the degree of overlying mechanical force. Bone graft under the scalp will resorb to a lesser degree than bone graft under the more mechanically compressive temporalis muscle. Published with permission from *Craniofacial Trauma Reconstr.* 2008;1(1):49–61.

cranial vault expansion, exerts compressive forces on even a rigidly fixated supraorbital bar, thus resulting in trigonocephaly relapse.

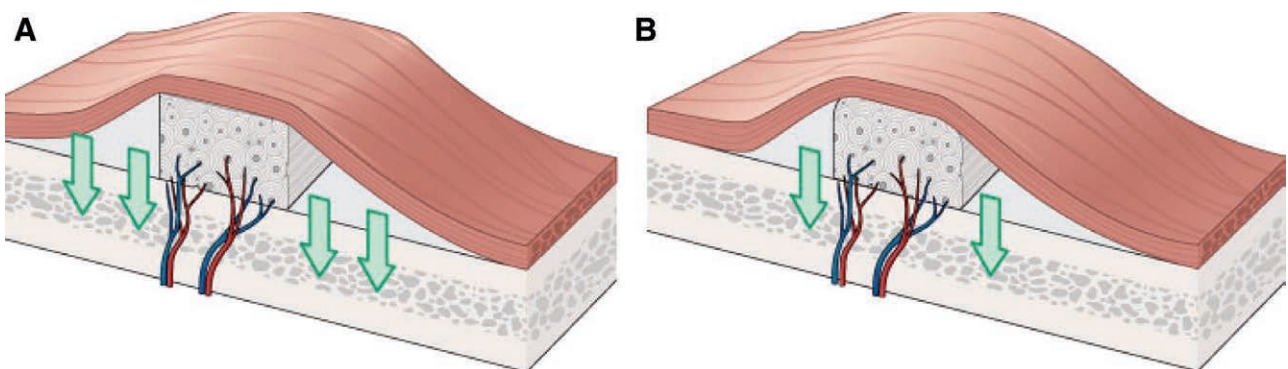


Fig. 8. Onlay bone grafting. With the onlay position, bone graft is now subject to the compressive forces (arrows) of the overlying soft tissue functional matrix (A) and will undergo resorption (B). Cortical bone better resists this remodeling and projection/volume loss due to its dense microstructure. Published with permission from *Craniofacial Trauma Reconstr.* 2008;1:49–61.

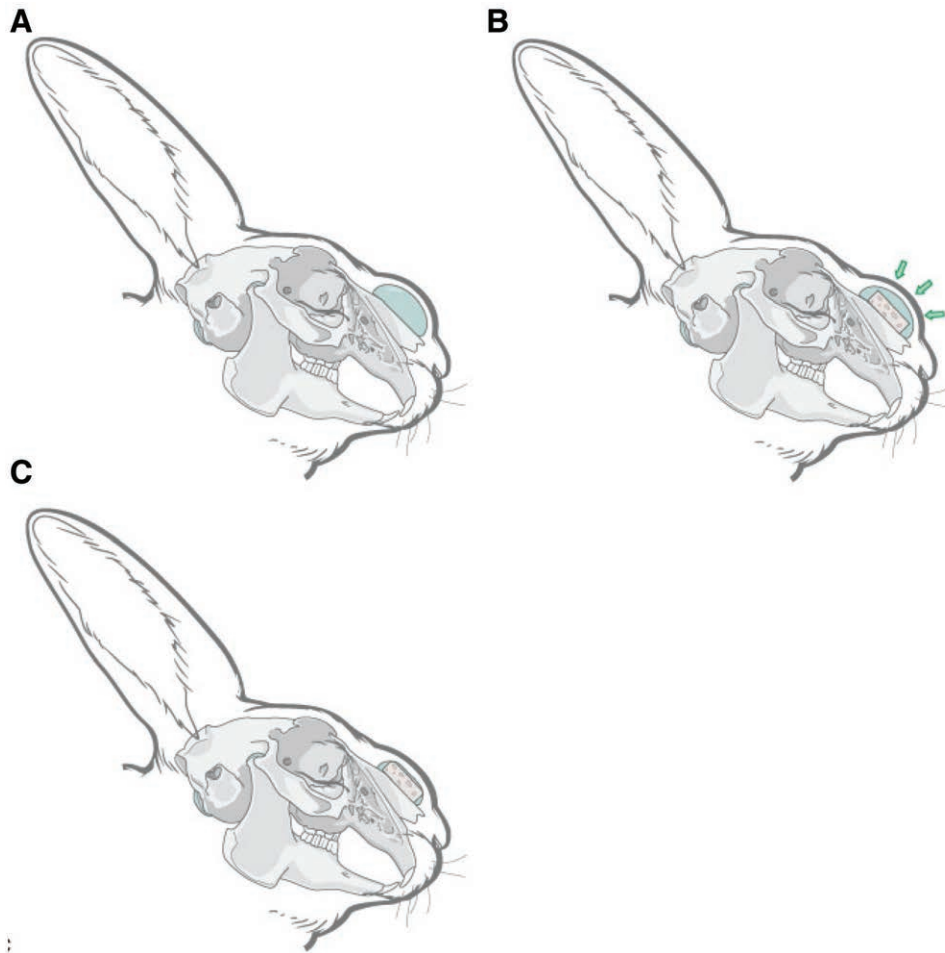


Fig. 10. Tissue expansion “shielding effect.” A–C, A shielding effect is demonstrated when tissue expansion proceeds bone grafting. This is hypothesized to reduce the compression forces on the graft, which in turn lead to resorption. Published with permission from *Craniomaxillofac Trauma Reconstr.* 2008;1:49–61.

To overcome the mechanical and biological boundaries of the soft tissue envelope, Buchman proposed to not merely overcorrect but to “hypercorrect.” Although a dramatic bandeau advancement of 3.5 cm sagittally and transversely is possible, the caveat is that scalp perfusion must not be compromised and that families must be closely counseled that a normal appearance will return by the age of 18–36 months (well before school age) (Figs. 11, 12). This same method of hypercorrection could be used in the cases of only unilateral supraorbital recession and temporal constriction as encountered in unicoronal craniosynostosis. Hypercorrection thus addresses both the soft tissue matrices of the recoiling galea and the growing brain.

Distraction Osteogenesis

Distraction osteogenesis is arguably the most robust clinical application of the functional matrix theory and mechanotransduction. Soft tissue is not merely a limitation to be considered but is itself directly manipulated

and effectively grown in concert with the underlying distracted bone. In other words, the boundaries of the functional matrix are surgically expanded and controlled. Whereas bone grafting is subject to forces supplied by the patient’s soft tissue, in distraction mechanical force is applied directly by the surgeon in an effort to engineer the bone in situ. Mirroring the discoveries underlying the molecular cell biology of mechanotransduction, the molecular underpinnings of distraction have also begun to be elucidated.^{56,57}

Distraction thus can be used where both bone and soft tissue deficits occur and where substantial skeletal dimensional changes are needed. It can be used to generate mandibular bone and even assist with forming a joint in the most severe cases of hemi-facial microsomia but obviating donor site morbidity and bone graft resorption (Fig. 13).⁵⁸ It has also minimized infectious complications and skeletal relapse in monobloc and LeFort III advancement patients.

Distraction can also be deployed tactically when functional matrix constraints make for unstable maneuvers in

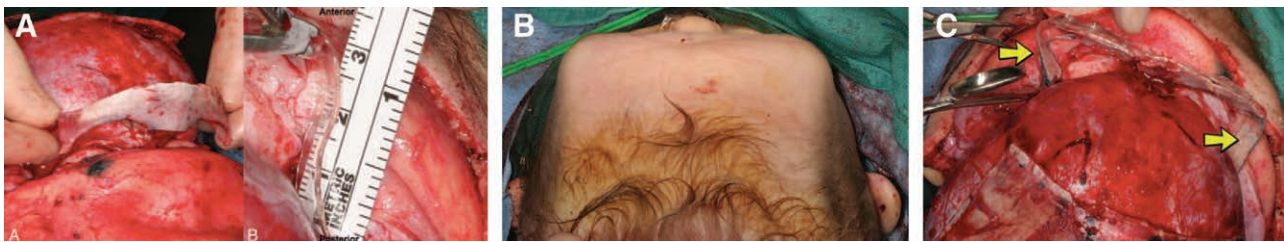

Fig. 11. Overcorrection technique in trigonocephaly: Advancement of the supraorbital bar from anterior. A, Resorbable plates are applied laterally as a bridge of support and reinforced with interpositional bone graft. B, Advancement of the supraorbital bar of up to 2.5–3.5 cm can be achieved. C, Resultant on-table hypercorrection of a supraorbital bitemporal recession. Parents must be counseled that a normative and lasting head shape will result. Published with permission from *J Craniofac Surg.* 2018;29:56–61.

orthognathic surgery. Widening a transversely deficient maxilla with a 2-piece LeFort alone is inherently unstable and prone to relapse. Placement of a palatal expander postoperatively after splint removal can be used to combat relapse by imposing a continual expansile force on the transversely widened maxilla to maintain the desired width, while completion of the orthodontics is finished up. Finally, external distraction can be used on the LeFort segment for negative overjets >10mm where a scarred

functional matrix would otherwise preclude substantial bony advancements.^{59,60}

CONCLUSIONS

In our understanding of clinically applicable bone biology, we are beholden to surgeons and scientists spanning geography, time, and a multitude of academic disciplines. Although all bone responds to mechanical force

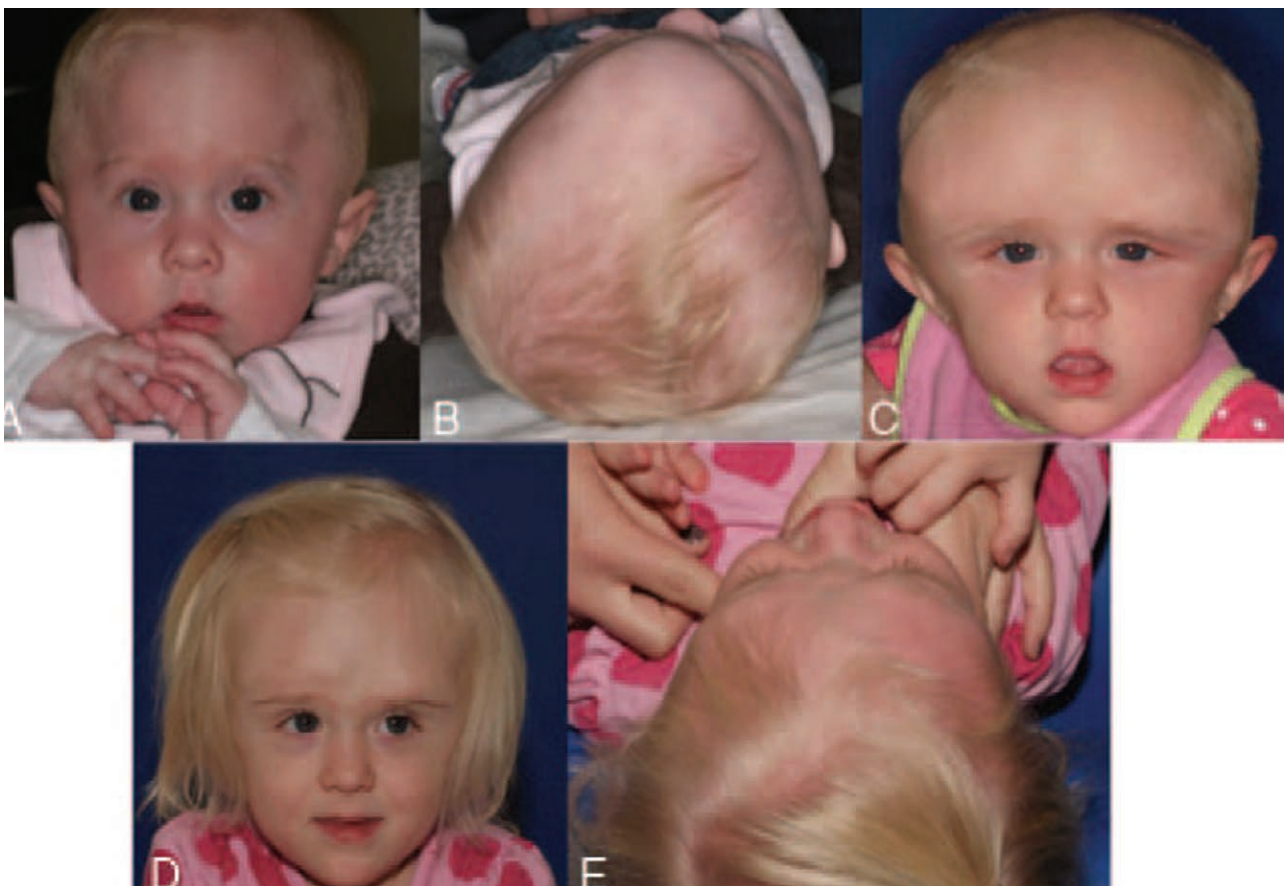


Fig. 12. Overcorrection in trigonocephaly longitudinal result: A, Severe preoperative trigonocephaly in a female patient. B, Preoperative bird's eye view. C, Severe hypercorrection 1 mo postoperatively. D, Resolution of hypercorrection 15 mo postoperatively. E, Bird's eye view at 15 mo postoperatively. Significant remodeling is seen from images C to E. Minimal remaining remodeling continues to improve over time. Published with permission from *J Craniofac Surg.* 2018;29:56–61.

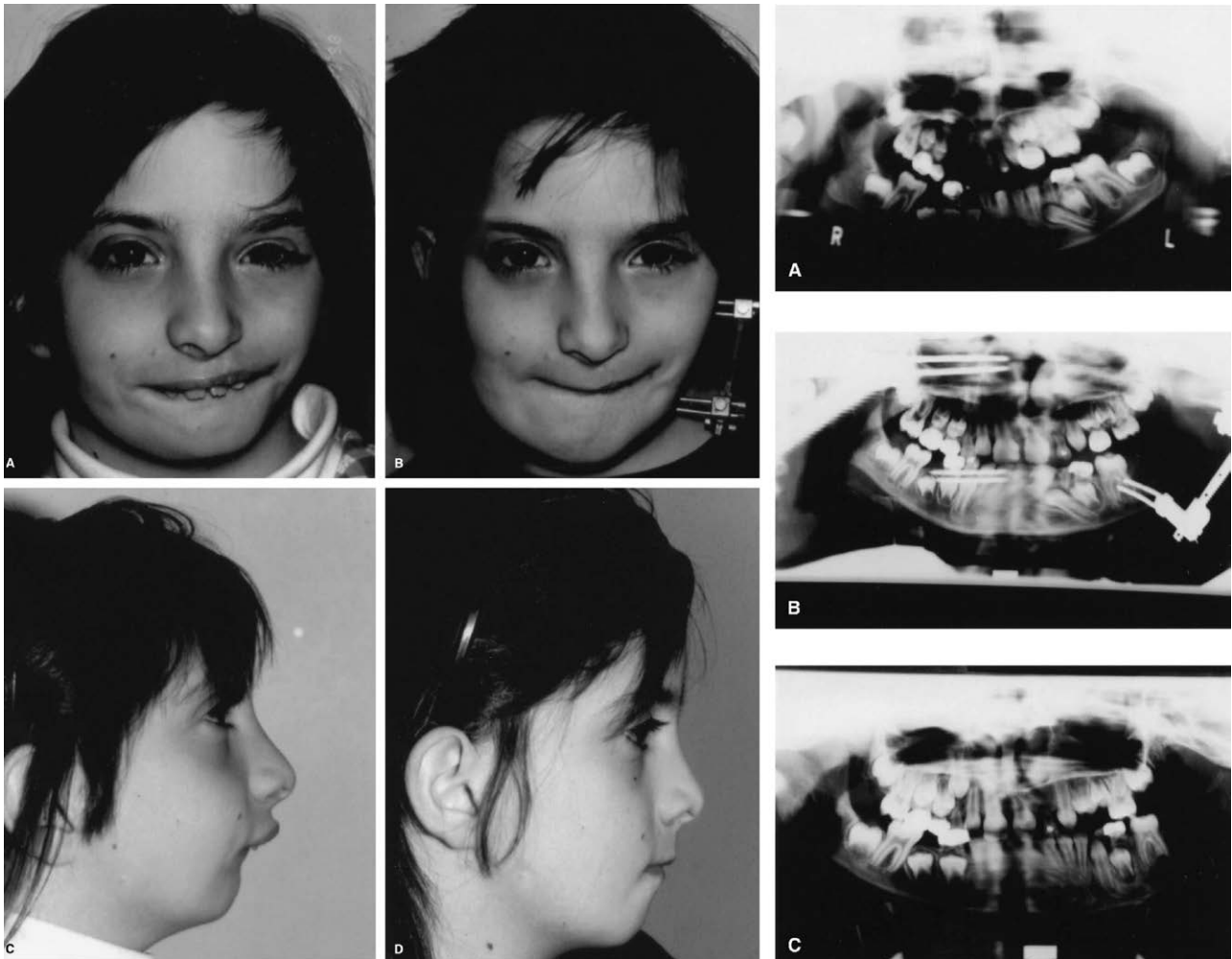


Fig. 13. Left: Seven-year-old girl before (A, C) and after (B, D) external mandibular distraction osteogenesis. Note significant projection medialization of chin point. Right: Panoramic radiographs in the (A) preoperative, (B) consolidation, and (C) postoperative periods. Published with permission from *J Craniofac Surg.* 2002;13:527–532.

and though the techniques of bone grafting, advancing osteotomies, and distraction are not restricted to the skull, bone biology of craniofacial skeleton is best understood by the concept of the functional matrix. The enveloping soft tissue is not merely a source of blood supply and coverage but determines, through mechanical interactions, the morphology of surgically manipulated bone.

Anticipating influence of the soft tissue functional matrix guides bone graft donor site selection (cortical versus cancellous) depending on the degree of anticipated soft tissue recoil (onlay versus inlay). The functional matrix may be best dealt with in certain circumstances, like craniosynostosis, with hypercorrection. In other scenarios, the functional matrix and bone alike can both be expanded and controlled using distraction osteogenesis.

Nicholas T.K. Do, MD
 Division of Plastic Surgery
 Los Angeles County Harbor-UCLA
 Medical Center, 1000 W Carson St
 Bldg D9, Box 40, Torrance, CA 90502
 E-mail: ndo@dhs.lacounty.gov

REFERENCES

1. García-Castro MI, Marcelle C, Bronner-Fraser M. Ectodermal Wnt function as a neural crest inducer. *Science.* 2002;297:848–851.
2. Couly GF, Coltey PM, Le Douarin NM. The triple origin of skull in higher vertebrates: a study in quail-chick chimeras. *Development.* 1993;117:409–429.
3. Jiang X, Iseki S, Maxson RE, et al. Tissue origins and interactions in the mammalian skull vault. *Dev Biol.* 2002;241:106–116.
4. Brugmann SA, Allen NC, James AW, et al. A primary cilia-dependent etiology for midline facial disorders. *Hum Mol Genet.* 2010;19:1577–1592.
5. Chiang C, Litung Y, Lee E, et al. Cyclopia and defective axial patterning in mice lacking Sonic hedgehog gene function. *Nature.* 1996;383:407–413.
6. von Meyer G. Die Architektur der Spongiosa. *Arch Anat Physiol und wissenschaftliche Medizin, Reichert und DuBois-Reynolds Arch.* 1867;34:615–628. Available at <https://ci.nii.ac.jp/naid/10003529116>. Accessed August 12, 2020.
7. Rüttimann B. A noteworthy meeting of the society for nature research in Zurich two important precursors of Julius Wolff: Carl Culmann and Hermann von Meyer. In: Regling G, ed. *Wolff's Law and Connective Tissue Regulation.* New York, N.Y.: Walter de Gruyter; 1992:13–22.

8. Thompson DW. On growth and form. In: *On Growth and Form*. Cambridge, UK: Cambridge University Press; 1917:793.
9. Thompson DW. On form and mechanical efficiency. In: *On Growth and Form*. New York, N.Y.: MacMillan Company; 1943:958–1005.
10. Culmann K. *Die Graphische Statik*. Zurich, Switzerland: Verlag Von Meyer & Zeller; 1866.
11. Wolff J. Ueber die Bedeutung der Architectur der spongiösen Substanz für die Frage vom Knochenwachstum. *Cent fur die Med Wissenschaften*. 1869;54:849–851.
12. Wolff J. Über die innere architektur der knochen und ihre bedeutung für die frage vom knochenwachstum. *Arch Pathol Anat Physiol Klin Med*. 1870;50:389–453.
13. Wolff J. Beiträge zur lehre von der heilung der fracturen. *Arch Klin Chir*. 1872;14:270–312.
14. Wolff J. Zur Knochenwachstumsfrage. *Arch Pathol Anat Physiol Klin Med*. 1874;61:417–456.
15. Wolff J. Das Gesetz der Transformation der Knochen. In: *Das Gesetz Der Transformation Der Knochen*. Berlin, Germany: Springer Verlag; 1892:126.
16. Wolff J. The law of bone remodeling. In: *The Law of Bone Remodeling*. Berlin, Germany: Springer; 1986:126.
17. Murray PDF. Bones: a study of the development and structure of the vertebrate skeleton. In: *Bones: A Study of the Development and Structure of the Vertebrate Skeleton*. Cambridge, UK: Cambridge University Press; 1936:99–100.
18. Angle EH. Treatment of malocclusion of the teeth and fractures of the maxillae. In: *Angle's System*. 6th ed. Philadelphia, Pa.: SS White Dental Mfg Co; 1900.
19. Khouw FE, Goldhaber P. Changes in vasculature of the periodontium associated with tooth movement in the rhesus monkey and dog. *Arch Oral Biol*. 1970;15:1125–1132.
20. Chen YW, Wang HC, Gao LH, et al. Osteoclastogenesis in local alveolar bone in early decortication-facilitated orthodontic tooth movement. *PLoS One*. 2016;11:e0153937.
21. Roberts W. Bone physiology, metabolism, and biomechanics in orthodontic practice. In: Graber L, Vanarsdall R, Vig K, Huang G, eds. *Orthodontics: Current Principles and Techniques*. 6th ed. St Louis, Mo.: Elsevier; 2017.
22. Moss-Salentine L, Melvin L. Moss and the functional matrix. *J Dent Res*. 1997;76:1814–1817.
23. Moss ML. Growth of the calvaria in the rat; the determination of osseous morphology. *Am J Anat*. 1954;94:333–361.
24. Moss ML. The effect of rhombencephalic hypoplasia on posterior cranial base elongation in rodents. *Arch Oral Biol*. 1975;20:489–492.
25. Moss ML. The functional matrix. In: Kraus B, Riedel R, eds. *Vistas in Orthodontics*. Philadelphia, Pa.: Lea & Febiger; 1962:85–98.
26. Moss ML, Salentine L. The capsular matrix. *Am J Orthod*. 1969;56:474–490.
27. Enlow DH. *The Handbook of Facial Growth*. Philadelphia, Pa.: WB Saunders; 1982.
28. Cowin SC, Moss-Salentine L, Moss ML. Candidates for the mechanosensory system in bone. *J Biomech Eng*. 1991;113:191–197.
29. Moss ML. The functional matrix hypothesis revisited. 1. The role of mechanotransduction. *Am J Orthod Dentofacial Orthop*. 1997;112:8–11.
30. Moss ML. The functional matrix hypothesis revisited. 2. The role of an osseous connected cellular network. *Am J Orthod Dentofacial Orthop*. 1997;112:221–226.
31. Moss ML. The functional matrix hypothesis revisited. 3. The genomic thesis. *Am J Orthod Dentofacial Orthop*. 1997;112:338–342.
32. Moss ML. The functional matrix hypothesis revisited. 4. The epigenetic antithesis and the resolving synthesis. *Am J Orthod Dentofacial Orthop*. 1997;112:410–417.
33. Bray D. Axonal growth in response to experimentally applied mechanical tension. *Dev Biol*. 1984;102:379–389.
34. Zheng J, Lamoureux P, Santiago V, et al. Tensile regulation of axonal elongation and initiation. *J Neurosci*. 1991;11:1117–1125.
35. Davies PF, Tripathi SC. Mechanical stress mechanisms and the cell. An endothelial paradigm. *Circ Res*. 1993;72:239–245.
36. Vandenburgh HH, Swadlow S, Karlisch P. Computer-aided mechanogenesis of skeletal muscle organs from single cells *in vitro*. *Faseb J*. 1991;5:2860–2867.
37. Wang N, Butler JP, Ingber DE. Mechanotransduction across the cell surface and through the cytoskeleton. *Science*. 1993;260:1124–1127.
38. Ingber DE. Cellular tensegrity: defining new rules of biological design that govern the cytoskeleton. *J Cell Sci*. 1993;104 (Pt 3):613–627.
39. Bierbaum S, Notbohm H. Tyrosine phosphorylation of 40kDa proteins in osteoblastic cells after mechanical stimulation of beta1-integrins. *Eur J Cell Biol*. 1998;77:60–67.
40. Meazzini MC, Toma CD, Schaffer JL, et al. Osteoblast cytoskeletal modulation in response to mechanical strain *in vitro*. *J Orthop Res*. 1998;16:170–180.
41. Schmidt C, Pommerenke H, Dürr F, et al. Mechanical stressing of integrin receptors induces enhanced tyrosine phosphorylation of cytoskeletally anchored proteins. *J Biol Chem*. 1998;273:5081–5085.
42. Peer LA. Fate of autogenous human bone grafts. *Br J Plast Surg*. 1951;3:233–243.
43. Zins JE, Whitaker LA. Membranous versus endochondral bone: implications for craniofacial reconstruction. *Plast Reconstr Surg*. 1983;72:778–785.
44. Hardesty RA, Marsh JL. Craniofacial onlay bone grafting: a prospective evaluation of graft morphology, orientation, and embryonic origin. *Plast Reconstr Surg*. 1990;85:5–14.
45. Buchman SR, Ozaki W. The ultrastructure and resorptive pattern of cancellous onlay bone grafts in the craniofacial skeleton. *Ann Plast Surg*. 1999;43:49–56.
46. Whitaker LA. Biological boundaries: a concept in facial skeletal restructuring. *Clin Plast Surg*. 1989;16:1–10.
47. LaTrenta GS, McCarthy JG, Breitbart AS, et al. The role of rigid skeletal fixation in bone-graft augmentation of the craniofacial skeleton. *Plast Reconstr Surg*. 1989;84:578–588.
48. Rosenthal AH, Buchman SR. Volume maintenance of inlay bone grafts in the craniofacial skeleton. *Plast Reconstr Surg*. 2003;112:802–811.
49. Sugg KB, Rosenthal AH, Ozaki W, et al. Quantitative comparison of volume maintenance between inlay and onlay bone grafts in the craniofacial skeleton. *Plast Reconstr Surg*. 2013;131:1014–1021.
50. Tong L, Buchman SR. Facial bone grafts: contemporary science and thought. *J Craniomaxillofac Trauma*. 2000;6:31–41.
51. Goldstein J, Mase C, Newman MH. Fixed membranous bone graft survival after recipient bed alteration. *Plast Reconstr Surg*. 1993;91:589–596.
52. Havlik RJ, Azurin DJ, Bartlett SP, et al. Analysis and treatment of severe trigonocephaly. *Plast Reconstr Surg*. 1999;103:381–390.
53. Metzler P, Ezaldein HH, Persing JA, et al. Comparing two fronto-orbital advancement strategies to treat trigonocephaly in metopic synostosis. *J Craniomaxillofac Surg*. 2014;42:1437–1441.
54. Wes AM, Paliga JT, Goldstein JA, et al. An evaluation of complications, revisions, and long-term aesthetic outcomes in nonsyndromic metopic craniosynostosis. *Plast Reconstr Surg*. 2014;133:1453–1464.
55. Paige KT, Cohen SR, Simms C, et al. Predicting the risk of reoperation in metopic synostosis: a quantitative CT scan analysis. *Ann Plast Surg*. 2003;51:167–172.
56. Rhee ST, Buchman SR. Colocalization of c-Src (pp60src) and bone morphogenetic protein 2/4 expression during mandibular

- distraction osteogenesis: *in vivo* evidence of their role within an integrin-mediated mechanotransduction pathway. *Ann Plast Surg.* 2005;55:207–215.
57. Rhee ST, El-Bassiony L, Buchman SR. Extracellular signal-related kinase and bone morphogenetic protein expression during distraction osteogenesis of the mandible: *in vivo* evidence of a mechanotransduction mechanism for differentiation and osteogenesis by mesenchymal precursor cells. *Plast Reconstr Surg.* 2006;117:2243–2249.
 58. Cavaliere CM, Buchman SR. Mandibular distraction in the absence of an ascending ramus and condyle. *J Craniofac Surg.* 2002;13:527–532.
 59. Kloukos D, Fudalej P, Sequeira-Byron P, et al. Maxillary distraction osteogenesis versus orthognathic surgery for cleft lip and palate patients. *Cochrane Database Syst Rev.* 2018;2018:CD010403.
 60. Kumar A, Gabbay JS, Nikjoo R, et al. Improved outcomes in cleft patients with severe maxillary deficiency after Le Fort I internal distraction. *Plast Reconstr Surg.* 2006;117:1499–1509.