



# Idiopathic endogenous lipid pneumonia: A case report of a young Syrian man

Maarouf Gorra Al Nafouri<sup>a</sup>, Michel Azar<sup>a,\*</sup>, Nour sbainy<sup>a</sup>, Hussam Al-bardan<sup>b</sup>

<sup>a</sup> Faculty of Medicine, Damascus University, Damascus, Syria

<sup>b</sup> Department of pulmonary medicine, Al Mouwasat University Hospital, Faculty of Medicine, Damascus University, Damascus, Syrian Arab Republic

## ARTICLE INFO

### Keywords:

Lipid pneumonia  
Endogenous  
Idiopathic  
Interstitial lung disease  
Prednisolone

## ABSTRACT

Lipid pneumonia is pneumonia due to aspiration or inhalation of various oily or fatty substances. It can be divided into exogenous and endogenous depending on the source of the lipids. In endogenous lipid pneumonia (ELP), lipid accumulates in the intra alveoli as a result of obstruction, chronic lung infection/disease, or a lipid storage disorder.

This study presents a case of a 47 year-old man with a history of smoking, surgically repaired ventricular septal defect, pulmonary stenosis, and no history of lipid intake. He complained of worsened exertional dyspnea and a chronic non-productive cough with no signs and symptoms of infection. The patient was diagnosed with idiopathic endogenous lipid pneumonia after excluding any inflammatory or systemic disease as a possible cause. Open lung biopsy showed lipid-laden macrophages. Corticosteroids were the mainstay therapy with no radiological improvement, eventually death occurred due to pulmonary embolism.

## 1. Introduction

Lipid pneumonia is pneumonia due to aspiration or inhalation of various oily or fatty substances. It was first noticed by Laughlen in 1925, in children who had a history of oily nasal drops use [1]. Lipid pneumonia has been reported using different names: lipid pneumonia; fat pneumonia; steatosis of the lungs; pneumonoliposis; lipoid cell pneumonia; paraffin pneumonia; oil pneumonia and oil aspiration pneumonia [2], which all indicate the presence of oily substances in the lung. Lipid pneumonia can be divided into exogenous and endogenous depending on the source of the lipids. Exogenous lipid pneumonia is associated with inhalation or aspiration of fatty substances. In endogenous lipid pneumonia (ELP), lipids accumulate in the intra alveoli as a result of obstruction, chronic lung infection/disease, or a lipid storage disorder [3].

ELP is a rare condition and several mechanisms were suggested to explain its pathogenesis such as retained epithelia secretions [4], prolonged hypoxia [5], and local oxygen and carbon dioxide tension [6]. Its etiologies are grouped into 3 main categories: obstructive, idiopathic, or systemic [7].

The diagnosis of ELP is usually confirmed by the presence of lipid laden macrophages similarly to exogenous lipid pneumonia [3], but without any evidence of external lipid exposure.

This article presents the case of a patient with endogenous lipid pneumonia admitted to Almouwasat hospital in Damascus, Syria confirmed by histopathological study.

\* Corresponding author.

E-mail address: [michelazar19971@gmail.com](mailto:michelazar19971@gmail.com) (M. Azar).

## 2. Case presentation

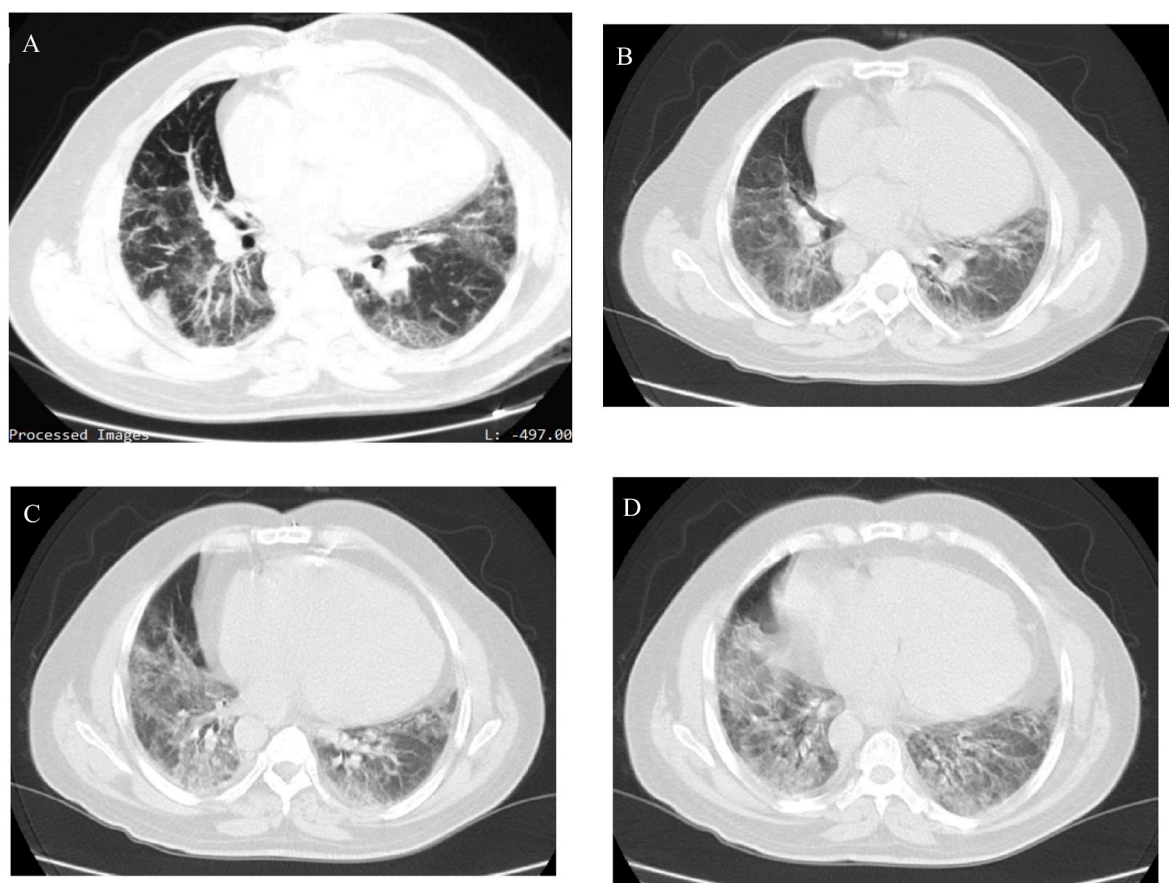
A 47-year-old man with history of smoking (about 20 pack-year), no history of alcohol consumption, with a clerical job, was admitted to Almouwasat hospital Damascus-Syria complaining of a chronic nonproductive cough, worsening exertional dyspnea grade three on mMRC scale, general fatigue and malaise through the last two months. No fever or sputum were found. His past medical history included a ventricular septal defect (VSD) and pulmonary stenosis, which were surgically repaired 25 years ago. His vital signs were as follows: blood pressure 130/80 mm hg, heart rate 95 beats per minute, respiratory rate 24 breaths per minute and temperature within normal range.

On physical examination, Finger clubbing was noted, a diastolic murmur was heard at Erb's point. Fine crackles were heard especially at the base of the lung and the rest of the physical examination was unremarkable. Chest X-Ray revealed bilateral reticular infiltrations with basal lobes predominance, routine lab work including white blood count, cholesterol, erythrocyte sedimentation rate (ESR), C-reactive protein (CRP). All were normal but hemoglobin concentration, which was 17 g/dl.

An echocardiogram was performed and showed the following: ejection fraction = 39%, systolic pulmonary artery pressure at rest 45 mm Hg, surgically repaired VSD & pulmonary stenosis, moderate aortic valve insufficiency and mild tricuspid valve insufficiency. A following multi-slice CT-scan was preformed which showed bilateral interstitial and alveolar densities (ground glass opacities with areas of consolidation) with air bronchogram and signs of hypoventilation of the lungs (Fig. 1). Arterial blood gas test showed the following: PH = 7.34, PaO<sub>2</sub> = 69 mm Hg, SO<sub>2</sub> = 92%, PCO<sub>2</sub> = 38 mm Hg, HCO<sub>3</sub> = 28meq/L.

An empiric course of antibiotics was started (ceftriaxone 1g bis in die, clarithromycin 500 mg bis in die). No clinical improvement was noted and the tests results ruled out infection as a possible cause. Corticosteroids were then administered (prednisolone 40 mg). The patient showed slight clinical improvement. A pulmonary function test was preformed and the results were: Fev<sub>1</sub> = 55% FVC = 63% FEV<sub>1</sub>/FVC = 93%.

Bronchoscopy and bronchial lavage were performed and showed the following results: the larynx, vocal cords, and trachea were normal. The left bronchial tree showed an oedematose appearance in the bronchi of the upper lobe and lingula. Another lavage was performed showing the inferior lobar bronchus opening to be normal. In the right bronchial tree, a stenosis was found in the apical bronchial opening of the upper lobe bronchus with diffuse erythema, leading to another lavage procedure. The procedure showed the middle and lower lobes bronchi to be normal. The lavages were negative for mycobacterium tuberculosis on microscopy and on



**Fig. 1.** Showing bilateral infiltrations of different radiological patterns: (A) patchy consolidation, with areas of air bronchogram (D) ground glass opacities and interstitial infiltration (B–C). (notice lower lobes predominance).

GeneXpert MTB. They also showed negative bacterial culture.

Since the results of bronchoscopy were inconclusive, the patient underwent an open lung biopsy. Pathological examination revealed large alveoli lined by columnar hyperplastic epithelium filled with macrophages, foam cells, and foreign body giant cells, with the presence of hemorrhage, interstitial fibrosis, and severe chronic inflammatory infiltrate composed mainly of lymphoplasmacytic and lymphoid follicles, which is compatible with lipid pneumonia with alveolar epithelial hyperplastic and focal organizing pneumonia (Fig. 2).

The patient was discharged and given a prescription of 40 mg of prednisolone with a written plan for gradual tapering. Eight weeks later, the patient was admitted to the emergency department with worsening dyspnea as he reached a dose of 20 mg daily. Physical examination revealed type 1 respiratory failure, which led to hospital readmission.

The patient was treated with an antibiotic (levofloxacin 750 mg daily), incrementally increasing the dose of prednisolone to 60 mg daily. Minor clinical improvements were noticed in the first few days, but a week later the patient experienced an acute onset of dyspnea with profound hypoxemia (oxygen saturation fell down to 50% even with high flow nasal cannula). The patient then was admitted to the ICU, intubated, and commenced on anti-coagulation agents due to a high risk of pulmonary embolism. A CT pulmonary angiography revealed a pulmonary embolism, which led to the patient's death.

### 3. Discussion

Lipid pneumonia can be divided into endogenous and exogenous; endogenous lipid pneumonia patients usually have non-specific symptoms like cough, dyspnea, tachypnea, chest pain or respiratory distress [7]. The presence of bronchial arthrofibrosis (BAF) was unique to the endogenous form [7], which may be the cause of differences in the clinical presentation between endogenous and exogenous lipid pneumonia [7]. In our case the patient presented with cough and dyspnea, however, when bronchoscopy was done, BAF was absent.

Opacities in both lungs is the most common presentation (85%) on CT-scans in both forms [8]. However, unlike the exogenous form, which in majority of cases shows a predominance involvement of the middle lobes (63%); all cases of endogenous form predominate at the lower lobes [8]. The chest X-Ray and CT-scan in our case showed bilateral infiltration with lower lobes predominance.

Endogenous lipid pneumonia can be a manifestation of various conditions including infectious, inflammatory, rheumatologic, and oncologic diseases [7]. The clinical history, lab works, and physical examination of our patient excluded any metabolic or chronic diseases and the CT-scan ruled out the presence of any mass that may be linked to the case. Unlike lipid pneumonia due to obstructive or systemic diseases, the symptoms in idiopathic ELP tends to have insidious onset and slow progression [7]. Due to all of that, this case was diagnosed as an idiopathic endogenous lipid pneumonia. Regarding treatment, corticosteroids were administered (prednisolone 40 mg) which showed a slight clinical improvement with no radiological changes. Although many reports showed improvement upon administering corticosteroids [9], some did not [7], as in our patient who continued to deteriorate leading to an admission in the ICU then death.

Our case suffered from hypoxemia (low arterial oxygen pressure (69 mm Hg) and fingers clubbing). This hypoxemia may have caused his condition, since prolonged hypoxia is hypothesized to have a role in the disease pathophysiology [5]. Further studies should investigate the association between people suffering from prolonged hypoxemia and lipid pneumonia and studies guided toward alternative treatment plans for these patients should be considered.

### 4. Conclusion

Idiopathic lipid pneumonia is a rare entity that can only be diagnosed after excluding systemic and inflammatory causes with no history of lipid intake. Its clinical and radiological presentation can mimic other lung diseases therefore, its diagnosis can be missed. In our case, corticosteroids made no significant radiological improvement, thus other approaches should be considered.

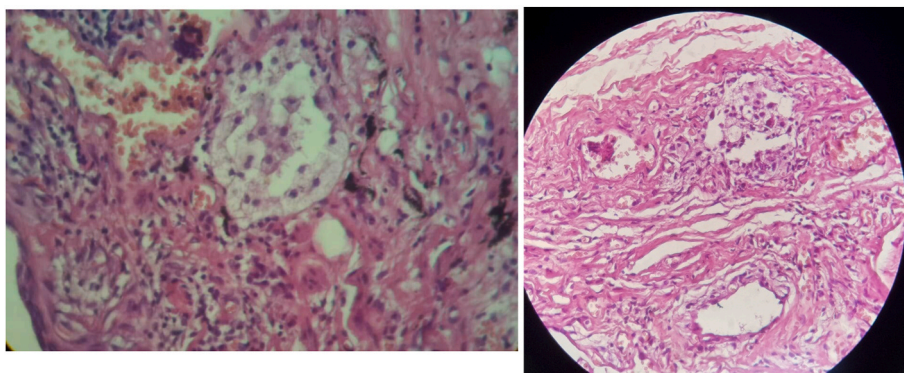


Fig. 2. Histopathology findings in endogenous lipid pneumonia patients showing lipid-laden macrophages inside alveoli.

## Author contributions

MG.MA and NS have contributed equally in drafting the manuscript and HS has reviewed and edited the manuscript.

## Funding

The research did not receive any specific grant from funding agencies in the public, commercial, or not-for-profit sectors.

## Declaration of interest

None.

## Acknowledgment

Authors would like to appreciate Ibrahim Hanafi, Randa abou-harb and Lina al haffar for his hard work in reviewing and editing the manuscript.

## References

- [1] G.F. Laughlen, Studies on pneumonia following naso-pharyngeal injections of oil, *Am. J. Pathol.* 1 (4) (1925) 407–414.1.
- [2] P.R. Cannon, The problem OF lipid pneumonia: a brief review, *J. Am. Med. Assoc.* 115 (25) (1940) 2176–2179, <https://doi.org/10.1001/jama.1940.72810510009014>.
- [3] V. Hadda, G.C. Khilnani, Lipoid pneumonia: an overview, *Expet Rev. Respir. Med.* 4 (6) (2010) 799–807, <https://doi.org/10.1586/ers.10.74>.
- [4] M. Burke, R. Fraser, Obstructive pneumonitis: a pathologic and pathogenetic reappraisal, *Radiology* 166 (3) (1988) 699–704, <https://doi.org/10.1148/radiology.166.3.3340764>.
- [5] A.B. Cohen, M.J. Cline, In vitro studies of the foamy macrophage of postobstructive endogenous lipid pneumonia in man, *Am. Rev. Respir. Dis.* 106 (1) (1972) 69–78, <https://doi.org/10.1164/arrrd.1972.106.1.69>.
- [6] E.K. Verbeken, M. Demedts, J. Vanwing, G. Deneffe, J.M. Lauweryns, Pulmonary phospholipid accumulation distal to an obstructed bronchus. A morphologic study, *Arch. Pathol. Lab Med.* 113 (8) (1989) 886–890.
- [7] J.S. Byerley, M.L. Hernandez, M.W. Leigh, J.W. Antoon, Clinical approach to endogenous lipid pneumonia, *Clin. Res. J* 10 (2) (2016) 259–263, <https://doi.org/10.1111/crj.12203>.
- [8] C.H. Kim, E.J. Kim, J.K. Lim, et al., Comparison of exogenous and endogenous lipid pneumonia: the relevance to bronchial anthracofibrosis, *J. Thorac. Dis.* 10 (4) (2018) 2461–2466, <https://doi.org/10.21037/jtd.2018.04.06>.
- [9] L.R.L.D. Beck, Lipoid pneumonia - StatPearls - NCBI bookshelf. <https://www.ncbi.nlm.nih.gov/books/NBK554577/>. (Accessed 30 March 2021).