

# Minimally invasive corpectomy and percutaneous transpedicular stabilization in the treatment of patients with unstable injuries of the thoracolumbar spine: Results of retrospective case series

## ABSTRACT

**Objective:** The objective of this study was to analyze the results of surgical treatment of patients with unstable injuries of the thoracolumbar spine using simultaneous minimally invasive corpectomy and percutaneous transpedicular stabilization.

**Materials and Methods:** The retrospective study included 34 patients with isolated single-level unstable injuries of the thoracolumbar spine (5 or more points according to the Thoracolumbar Injury Classification and Severity Score (TLICS), operated on from the moment of injury from 8 to 24 h using the technique of minimally invasive corpectomy and percutaneous transpedicular stabilization simultaneously. The technical features of surgery, clinical data (pain level according to the Visual Analog Scale, quality of life according to the SF-36 questionnaire, subjective satisfaction with the operation according to the MacNab scale, and the presence of complications), and instrumental data (angle of segmental kyphotic deformity and sagittal index to and after surgery). The assessment of clinical data was carried out before surgery, at discharge, after 6 months, and in the long-term period, on average, 30 months after surgery.

**Results:** When evaluating the clinical data, a significant decrease in the severity of pain syndrome was found on average from 90 mm to 5.5 mm in the late follow-up ( $P < 0.001$ ), as well as a significant improvement in the physical and psychological components of health according to the SF-36 questionnaire on average from 28.78 to 39.26 ( $P < 0.001$ ), from 36.93 to 41.43 ( $P = 0.006$ ), respectively. In the long-term period, according to the MacNab scale, the patients noted the result of the operation: excellent – 18 (52.9%), good – 13 (38.3%), and satisfactory – 3 (8.8%); no unsatisfactory results were registered. Four (11.8%) perioperative surgical complications were registered, which were successfully treated conservatively. A significant restoration of the sagittal profile with an insignificant change in blood pressure was recorded in the long-term postoperative period. An average follow-up assessment of 30 months according to the American Spinal Injury Association scale showed the presence of E and D degrees in 85.4% of patients.

**Conclusion:** Minimally invasive corpectomy with percutaneous transpedicular stabilization in the treatment of patients with unstable injuries of the thoracolumbar spine can effectively eliminate kyphotic deformity and prevent the loss of its reduction with a low number of postoperative surgical complications. The technique has minimal surgical trauma with the possibility of early postoperative rehabilitation and provides a significant stable reduction in vertebrogenic pain syndrome, improvement of neurological deficits, and restoration of the quality of life of patients and in the follow-up.

**Keywords:** Minimally invasive corpectomy, percutaneous transpedicular stabilization, telescopic implant, thoracic-lumbar spine, unstable traumatic injuries of the spine

**VADIM A. BYVALTSEV<sup>1,2</sup>, ANDREI A. KALININ<sup>1,2</sup>,  
ROMAN A. POLKIN<sup>1,2</sup>, VALERII V. SHEPELEV<sup>1</sup>,  
MARAT A. ALIYEV<sup>1,3</sup>, YERMEK K. DYUSSEMBEKOV<sup>3</sup>**

<sup>1</sup>Department of Neurosurgery, Irkutsk State Medical University,

<sup>2</sup>Department of Neurosurgery, Railway Clinical Hospital, Irkutsk, Russia, <sup>3</sup>Department of Neurosurgery, Asfendiyarov Kazakh National Medical University, Almaty, Kazakhstan

**Address for correspondence:** Prof. Vadim A. Byvaltsev, Irkutsk State Medical University, 1 Krasnogo Vosstaniya St., Irkutsk 664003, Russian Federation.  
E-mail: byval75vadim@yandex.ru

**Submitted:** 05-Apr-21


**Accepted:** 07-Jun-21

**Published:** 08-Sep-21

This is an open access journal, and articles are distributed under the terms of the Creative Commons Attribution-NonCommercial-ShareAlike 4.0 License, which allows others to remix, tweak, and build upon the work non-commercially, as long as appropriate credit is given and the new creations are licensed under the identical terms.

**For reprints contact:** WKHLRPMedknow\_reprints@wolterskluwer.com

**How to cite this article:** Byvaltsev VA, Kalinin AA, Polkin RA, Shepelev VV, Aliyev MA, Dyussembekov YK. Minimally invasive corpectomy and percutaneous transpedicular stabilization in the treatment of patients with unstable injuries of the thoracolumbar spine: Results of retrospective case series. *J Craniovert Jun Spine* 2021;12:294-301.

Access this article online	
<b>Website:</b> www.jcvjs.com	<b>Quick Response Code</b> 
<b>DOI:</b> 10.4103/jcvjs.jcvjs_47_21	

## INTRODUCTION

Open methods are traditionally used in the surgical treatment of unstable injuries of the thoracolumbar spine.<sup>[1]</sup> Open thoracotomy and thoracoabdominal approaches remain classical options for the ventral approach.<sup>[2]</sup> The anterolateral approach to the thoracolumbar spine is well described in the literature and is a priority option for surgical treatment of pathology in this area.<sup>[3]</sup> However, approach to the thoracic spine is associated with the rib resection, intrapleural manipulations with the lungs and mediastinal organs, and transection of the diaphragm, and approach to the lumbar vertebrae is associated with significant soft-tissue dissection, impact on the lumbar plexus, and retroperitoneal manipulations with the peritoneum.<sup>[4]</sup> All of the above is associated with significant postoperative pain syndrome, as well as a high risk of perioperative complications.<sup>[5,6]</sup>

Due to the minimization of the anatomical corridor with the advent of retraction systems, the use of optical magnification, and specialized instrumentation for placing implants, low-traumatic lateral retropleural and retroperitoneal approaches have become a safe and effective choice for many spinal surgeons.<sup>[7]</sup> In combination with the percutaneous technique of transpedicular stabilization, the minimally invasive approach has a number of advantages, including less damage to the skin, ligamentous apparatus and muscles, no need for rib resection, limited manipulation of the chest and abdominal organs, reduced intraoperative blood loss, early activation, reduced postoperative pain syndrome, and the duration of inpatient treatment.<sup>[8]</sup>

In this study, we consider a retrospective case series of 34 patients who underwent minimally invasive corpectomy and percutaneous transpedicular stabilization for unstable injuries of the thoracolumbar spine.

### Objective

The objective of this study was to analyze the results of surgical treatment of patients with unstable injuries of the thoracolumbar spine with simultaneous use of minimally invasive corpectomy and percutaneous transpedicular stabilization.

## MATERIALS AND METHODS

### Study design

This was a retrospective series of cases.

### Conditions

During the period from 2008 to 2018, 526 surgical interventions for spinal injuries were performed at the

neurosurgical center of the private health-care institution “Clinical Hospital of Russian Railways-Medicine” in Irkutsk, out of which 158 cases were decompressive-stabilizing interventions for injuries at the thoracic and lumbar levels. The study included 34 patients who met the inclusion criteria and did not have exclusion criteria, as well as those subjects who provided information in the long-term postoperative period.

### Compliance criteria

#### Inclusion criteria

1. Isolated injury of the thoracolumbar spine
2. Single-level injury in the thoracic or lumbar spine
3. Unstable injuries of the thoracolumbar spine (5 or more points according to the Thoracolumbar Injury Classification and Scoring System)<sup>[9]</sup>
4. Terms from the moment of injury from 8 to 24 h.

#### Exclusion criteria

1. Damage to the thoracolumbar spine of osteoporotic and neoplastic genesis
2. Multiple injuries to the vertebrae of the thoracolumbar localization
3. More than 24 h after injury
4. Presence of concomitant diseases in the decompensation stage.

### Surgical technique

Patients were operated by one surgical team in one surgical session simultaneously. Projection minitoracotomy (without rib resection) or minilumbotomy was performed in the first stage in the patient's right side position [Figure 1a] using an Oracle retractor (Switzerland), under the magnification of a Pentero 900 operating microscope (Zeiss, Germany) and intraoperative fluoroscopic control of an electron-optical converter (Siemens, Germany), depending on the location of the spinal fracture [Figure 1b]. After fluoroscopic detection of the level of damage, microsurgical decompression of the spinal canal structures was performed by resection of fragments of the damaged vertebral body, removal of adjacent intervertebral discs, and evacuation of the epidural hematoma, followed by revision of the anterolateral parts of the spinal cord under optical magnification [Figure 1c] and installation of a telescopic implant [Figure 1d]. At the second stage, the patient was turned onto his stomach; marking was performed with the determination of the bases of the pedicles and their transverse processes adjacent to the damaged vertebrae. Subsequently, four paravertebral incisions up to 1.5 cm long were performed, into which bone puncture and guidance needles and monoaxial transpedicular screws were gradually installed. Subsequently, subfascial traction of longitudinal rods, previously modeled for the physiological

curvature of the spine, was performed on both sides, and when using instruments for deformity correction, distraction and reduction of kyphotic deformity were performed, followed by fixation of transpedicular screws and longitudinal rods with locking screw-nuts through a system of guide ports [Figure 1e].

### Study duration

In the study group, clinical and instrumental data were evaluated before surgery, at discharge, after 6 months, and in the long-term period from 24 to 56 months after surgery (30 months on average).

### Study results

#### Clinical outcomes

The assessment was based on the severity of pain syndrome according to the Visual Analog Scale (VAS), quality of life according to the SF-36 questionnaire, subjective satisfaction with the result of surgical treatment according to the MacNab scale, and the presence of complications.

#### Instrumental outcomes

The degree of spinal deformity was studied using lateral spondylograms before and after surgery by measuring the angle of segmental kyphotic deformity (SKD) using the Cobb method and the sagittal index.<sup>[10]</sup>

#### Statistical analysis

Statistical data were obtained using the Statistica-8 program. To analyze the significance of differences, the criteria of nonparametric statistics were used; the level of  $P < 0.05$  was taken as the lower limit of statistical significance. Information is indicated by the median and interquartile range as Me (25%–75%).

The study was carried out in accordance with the Good Clinical Practice standards and the principles of the Declaration of Helsinki of the World Medical Association. The study protocol was approved by the Ethics Committee. The article lacks information that is not subject to publication. Written informed consent was obtained from patients prior to inclusion in the study.

## RESULTS

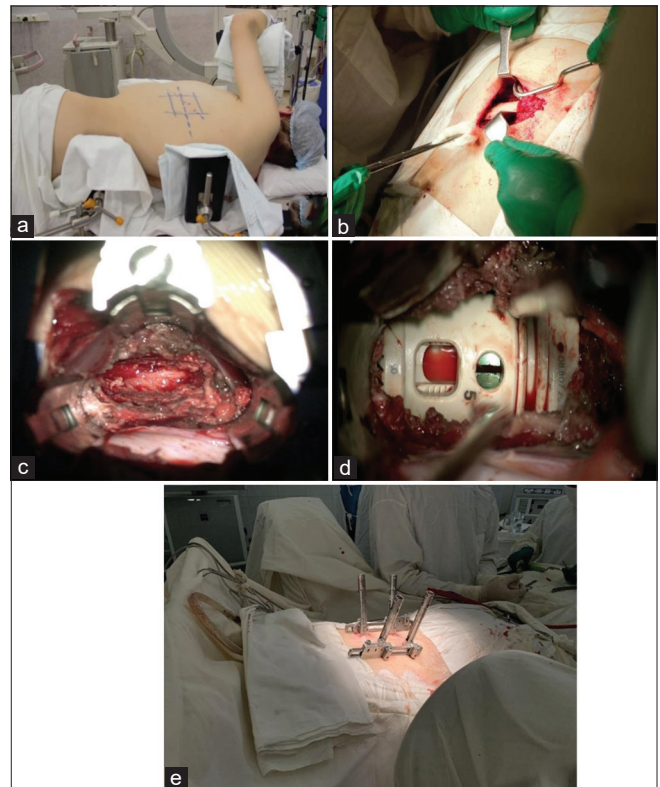
Summary data on the studied patients are shown in Table 1. The analysis revealed the prevalence of middle-aged men ( $n = 23$ , 67.6%). The second degree of anesthetic and operational risk according to ASA was registered most frequently ( $n = 19$ , 55.9%). In most cases, the level of damage was localized in the region of the thoracolumbar junction ( $n = 13$ , 38.3%). A larger number of patients were diagnosed with rotational and distraction mechanisms of

damage (82.4%) with preoperative neurological deficits of varying severity (61.8%). None of the cases required autologous blood transfusion and conversion to open surgery.

Assessment of pain syndrome according to the VAS [Figure 2] showed a significant decrease in its severity by the time of discharge from 90 (81, 95) mm to 12 (10, 16) ( $P < 0.001$ ). At the same time, in the long-term period (on average, 30 months after surgery), a minimum level of pain syndrome of 5.5 (3, 8) mm ( $P < 0.001$ ) was noted, which indicates its stable decrease.

When analyzing the quality of life of patients using the SF-36 questionnaire [Figure 3], a significant improvement was determined in physical health components from 28.78 (20.75, 35.25) to 39.26 (36.69, 51.49) ( $P < 0.001$ ) and in psychological health components from 36.93 (21.22, 44.04) to 41.43 (36.20, 54.75) ( $P = 0.006$ ).

The study revealed a significant improvement in indicators on the American Spinal Injury Association (ASIA) scale. On an average follow-up of 30 months, 29 patients (85.4%) showed no neurological deficit or mild residual clinical impairments (Grades E and D), Grade A was noted in



**Figure 1:** Intraoperative photographs: (a) the position of the patient on the operating table, (b) minimally invasive approach with the isolation of the rib; (c) prepared bed for the implant; (d) appearance of a telescopic body prosthesis; (e) general view of the installed percutaneous transpedicular screws and a set of instruments for carrying out the reduction moment

**Table 1: Demographic and perioperative data of patients included in the study**

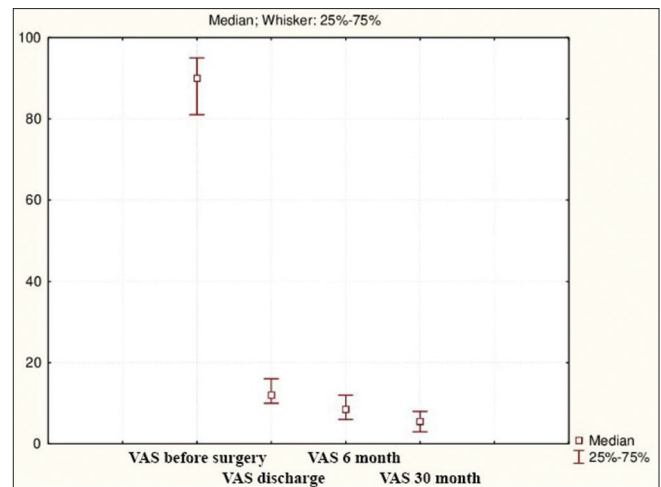
Characteristic	Study group (n=34)
Age (years)	36.4 (26; 58)
Sex, n (%)	
Male	23 (67.6)
Female	11 (32.4)
BMI (kg/m <sup>2</sup> )	23.1 (21.9; 27.3)
ASA physical status, n (%)	
II	19 (55.9)
III	13 (38.2)
IV	2 (5.9)
Localization of the burst segment, n (%)	
Th <sub>vii</sub>	1 (2.9)
Th <sub>viii</sub>	1 (2.9)
Th <sub>ix</sub>	3 (8.8)
Th <sub>x</sub>	4 (11.8)
Th <sub>xi</sub>	3 (8.8)
Th <sub>xii</sub>	6 (17.7)
L <sub>i</sub>	7 (20.6)
L <sub>ii</sub>	3 (8.8)
L <sub>iii</sub>	4 (11.8)
L <sub>iv</sub>	2 (5.9)
Injury severity according to ASIA scale, <sup>[11]</sup> n (%)	
A	2 (5.9)
B	4 (11.8)
C	6 (17.7)
D	9 (26.4)
E	13 (38.2)
Damage type according to AO spine classification, <sup>[12]</sup> n (%)	
A	6 (17.6)
B	11 (32.4)
C	17 (50)
Operative time (min)	240 (215; 290)
Estimate blood loss (ml)	230 (150; 310)
Activation time (days)	1 (1; 2)
Length of stay from surgery (days)	11 (9; 13)

BMI - Body mass index, ASA - American Society of Anesthesiologists, ASIA - American Spinal Injury Association

1 (2.9%) case, Grade B in 1 (2.9%) case, and Degree C in 3 (8.8%) cases.

In the long-term postoperative period (on average after 30 months), the distribution of patient outcomes according to the MacNab scale was noted: excellent – 18 (52.9%), good – 11 (32.4%), and satisfactory – 6 (17.7%); unsatisfactory results were not registered.

In total, 4 (11.8%) perioperative surgical complications were identified: in 2 cases, an infection of the surgical site developed, which required additional debridement of the surgical wound; 1 patient was diagnosed with nosocomial pneumonia after minithoracotomy, which required prolongation of antibiotic therapy; in 1 case, a



**Figure 2: Dynamics of the level of pain syndrome according to the Visual Analog Scale in patients with traumatic injuries of the thoracic and lumbar spine**

clinical picture of lesions of the genitofemoral nerve (n. genitofemoralis) was noted, and therefore, a course of antineuritic therapy was conducted.

The study of the degree of the deformity correction in the damaged spine revealed a significant change in the angle of segmental kyphosis after surgical treatment with a slight change in SKD in the long-term postoperative period [Table 2].

A clinical example of using corpectomy and percutaneous transpedicular stabilization is shown in Figure 4.

## DISCUSSION

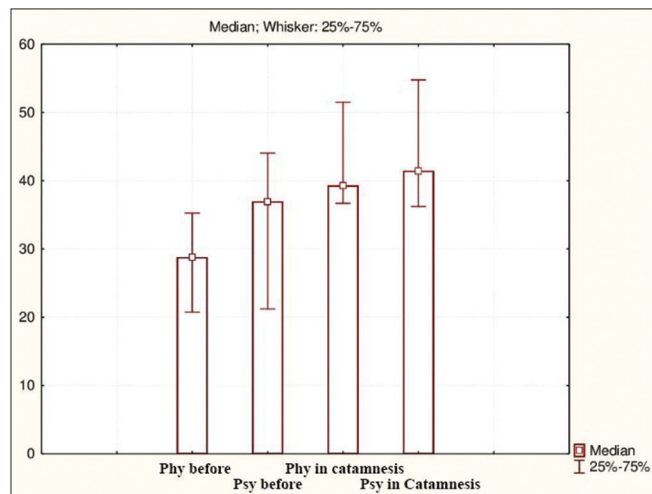
Decision-making for the choice of the technique and method of treatment of patients with injuries of the thoracolumbar spine is based mainly on the degree of fracture stability, the presence of spinal cord injury, and the integrity of the posterior supporting complex.<sup>[13]</sup>

Surgical treatment of fractures of the thoracic and lumbar spine traditionally consisted of open posterior extended fixation with or without intervention on the anterior column, depending on the morphology of the fracture.<sup>[14]</sup> Despite the success, extensive open techniques are associated with significant complications: the development of pneumothorax, damage to the chest and abdominal organs, trauma to the lumbar plexus, the formation of diaphragmatic or ventral hernias, prolonged postthoracotomy pain syndrome, and denervation of the anterolateral abdominal wall muscles.<sup>[1,4]</sup> With the advent of Minimally Invasive Spine Surgery, MISS procedures in the treatment of degenerative pathology of the spine, these methods have been actively used for the treatment of spinal injuries.<sup>[8,15]</sup>



**Table 2: Dynamics of correction of segmental deformity in patients with traumatic injuries of the thoracic and lumbar spine**

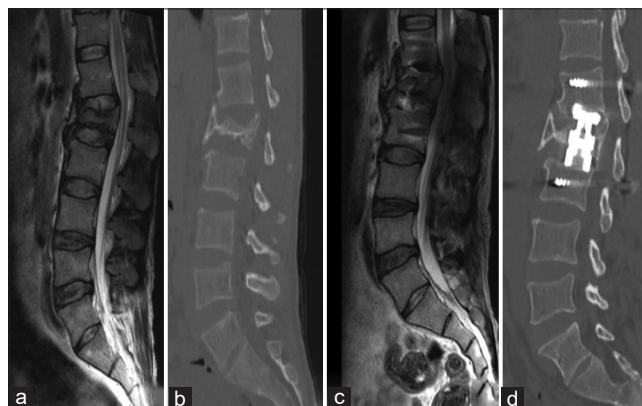Spine	Angle of sagittal kyphotic deformity (°)			Strain reduction loss rate (°)	P (before surgery – at discharge)	P (at discharge – after 30 months)
	Before surgery	At discharge	After 30 months			
Thoracic	37 (29; 41)	23 (20; 25)	25 (21; 29)	2 (1; 4)	0.02	0.28
Lumbar	16 (9; 26)	8.5 (6;15)	10.5 (8; 19)	2 (2; 4)	0.01	0.31



**Figure 3: Dynamics of the quality of life according to the SF-36 questionnaire in patients with traumatic injuries of the thoracic and lumbar spine (Phy – the physical component of health and Psy – the psychological component of health)**

The dominant goal of MISS is to reduce the complications associated with approach, while obtaining results comparable to traditional open surgery.<sup>[7,16]</sup> In the treatment of traumatic vertebral pathology, the main tasks remain decompression and prevention of the development of secondary damage to neural structures, ensuring segmental stability and reducing posttraumatic deformity.<sup>[4]</sup> Reconstruction of the physiological balance of the spine accelerates the recovery of clinical disorders and reduces the risk of worsening of existing neurological deficits.<sup>[17]</sup> In addition, ensuring effective fixation of the damaged segment, especially in unstable fractures of the vertebral bodies, is a key factor preventing the progression of traumatic deformity and destabilization of the metal structure.<sup>[18]</sup> Thus, biomechanical cadaver studies have confirmed greater stability during flexion-extension movements, lateral tilting and rotation of circumferential stabilization (corpectomy and transpedicular fixation) compared to corpectomy and lateral plate placement, as well as with isolated dorsal stabilization.<sup>[19,20]</sup> Data published in the specialized literature have demonstrated the clinical effectiveness of using a combination of body prosthesis and dorsal screw fixation for unstable injuries of the lumbar and thoracic segments.<sup>[21,22]</sup>

It has been shown that minimally invasive methods are a safe alternative to open surgical methods when patients have various contraindications or high risks of traditional



**Figure 4: The patient M., age of 35. Unstable burst fracture of the L<sub>1</sub> vertebra with local kyphotic deformity and spinal canal stenosis: (a) sagittal magnetic resonance imaging of the lumbar spine before surgery; (b) sagittal multislice computed tomography of the lumbar spine before surgery; (c) sagittal magnetic resonance imaging of the lumbar spine in 6 months after surgery; (d) sagittal multislice computed tomography of the lumbar spine in 6 months after surgery**

interventions.<sup>[23]</sup> One of the options for less traumatic surgical treatment of injuries of the thoracolumbar spine is thoracoscopic spinal fusion and percutaneous transpedicular stabilization.<sup>[24,25]</sup> At the same time, endoscopic technologies have significant limitations to their use, which is associated with a long learning curve, the need for additional expensive equipment, high risks of developing pulmonary complications, prolonged surgery time, and difficulties in intraoperative positioning of the implant.<sup>[26]</sup> In addition, the use of videoendoscopic technologies in the surgical treatment of patients with traumatic spinal injuries is often associated with the inability to fully decompress neural structures, insufficiently effective stopping of epidural bleeding, which requires conversion of the intervention into open surgery.<sup>[24]</sup>

The above has led to the popularization of minimally invasive techniques in the form of minithoracotomy or minilumbotomy in combination with percutaneous transpedicular stabilization in patients with injuries of the thoracolumbar spine allowing to reduce surgical aggression and postoperative pain syndrome, provide a better cosmetic effect, and reduce the risk of developing perioperative surgical complications.<sup>[27,28]</sup> At the same time, in the specialized literature, there are a small number of clinical series devoted to the analysis of low-traumatic thoracolumbar transbody fusion with percutaneous screw fixation in patients with unstable spinal injuries, and their results are largely ambiguous.

Thus, the study conducted by Smith *et al.*<sup>[22]</sup> evaluated the treatment results of 52 patients with fractures of mainly rotational and distraction types (92.4%) who were operated with reconstruction of the anterior column using expanding titanium cages, followed by anterolateral fixation, installation of transpedicular screws, or a combination of them. The average operation time was 127 min, and the volume of blood loss was 300 ml. The authors reported a complication rate in 15% of cases, which included damage to the dura mater ( $n = 2$ ), intercostal neuralgia ( $n = 2$ ), deep vein thrombosis ( $n = 2$ ), pleural effusion ( $n = 1$ ), and surgical site infection ( $n = 1$ ). Recovery of neurological deficits to Grades D and E according to the ASIA scale was verified in 73% of patients.

According to Shin *et al.*,<sup>[29]</sup> the results of surgical treatment of 22 patients with unstable fractures of the thoracolumbar localization using minimally invasive corpectomy with percutaneous transpedicular stabilization were analyzed. The average intraoperative parameters were recorded: the duration of surgery – 293.9 min, the volume of blood loss – 1566.6 ml, and the length of stay in hospital – 40.8 days. Changes in the sagittal profile were recorded: the Cobb angle before surgery was  $18.3 \pm 5.60$ ; in the long-term period, it was  $21.8 \pm 11.30$ ; the loss of correction was noted  $-9.8 \pm 10.60$ . Among the complications, infection of the intervention area was detected in 2 cases (9%) and instability of the screw fixation in 1 case.

The long-term clinical efficacy of MISS in spinal injury is high. When analyzing the clinical outcomes of minimally invasive thoracolumbar corpectomy with percutaneous transpedicular stabilization in 12 patients, Theologis *et al.*<sup>[30]</sup> in the average follow-up period of 38 (16–68) months noted the following indicators: ODI –  $20\% \pm 17\%$ , physical health component according to SF-36 –  $41.7\% \pm 10.4\%$ , mental health component according to SF-36 –  $50.2\% \pm 11.6\%$ , and average pain level – 2.6 cm.

The results of comparing combined approaches with isolated ventral or dorsal approaches, as well as MISS and open technologies in the treatment of patients with thoracolumbar injuries, are contradictory. Reinhold *et al.*<sup>[31]</sup> conducted a multicenter study that included 424 (57.8%) cases of Type A injuries, 178 (24.3%) cases of Type B injuries, and 131 (17.9%) cases of Type C injuries using posterior decompression and stabilization interventions in 380 (51.8%) patients, anterior – in 34 (4.6%), and combined – in 319 (43.5%). The authors registered large parameters for the duration of hospitalization, the volume of blood loss and the number of perioperative complications, as well as a less favorable functional outcome

in patients after combined stabilization. At the same time, in the follow-up period of 24 months in this group, a lesser traumatic deformity of the damaged segment was recorded in comparison with anterior and dorsal decompression and stabilization interventions.

In the study conducted by Tabaraee *et al.*,<sup>[32]</sup> a comparative analysis of minimally invasive thoracolumbar corpectomy with percutaneous transpedicular stabilization ( $n = 6$ ), open circumferential stabilization ( $n = 2$ ), and isolated traditional dorsal decompression-stabilizing interventions ( $n = 1$ ) was performed in patients with traumatic injuries of the thoracolumbar region. The analysis revealed that the use of minimally invasive technology made it possible to shorten the duration of the intervention, reduce the volume of perioperative blood loss and the number of infectious postoperative complications, as well as reduce the need for the use of narcotic analgesics.

Furthermore, the disputability of the use of open and minimally invasive decompression and stabilization techniques in patients with trauma of the thoracolumbar spine is due to the possibility of effective decompression of neural structures with a wide revision of the epidural space, associated with the nature and technique of the approach to the damaged area.<sup>[8,14]</sup> It is assumed that minimization of the anatomical corridor when using minimally invasive technologies in patients with spinal injury is not a risk factor for residual neurological deficit due to postoperative neuroimaging confirmation of the fact of full decompression of the spinal canal structures.<sup>[22,29]</sup> Despite all the obvious advantages of MISS in the treatment of patients with traumatic injuries of the thoracolumbar localization, the main disadvantages of such procedures remain: the complexity of working in a narrow operating field, the need for deep knowledge of surgical and X-ray anatomy, a long learning curve, and a significant intraoperative radiation exposure.<sup>[33,34]</sup>

A retrospective study of clinical and instrumental data of the simultaneous use of minimally invasive corpectomy and percutaneous transpedicular stabilization in the surgical treatment of 34 patients with unstable injuries of the thoracolumbar spine confirmed the high efficiency and safety of the combination of the technologies used. In most cases, a significant improvement in impaired neurological functions was verified with effective stabilization of the damaged segments and restoration of the sagittal profile of the spine.

Thus, the analysis of the literature data showed that minimally invasive surgery for spinal injuries is a promising area of modern vertebrology, while the current data are largely

ambiguous and require studies with evidence of a high level of priority over open methods.

### Study limitations

In the presented work, there are several fundamental shortcomings associated with the specific features of its design that can affect the interpretation of the results of the study. First, the clinical series is retrospective, which may affect the accuracy of the collected data associated with defects in filling out medical records. Second, there may be a systematic selection error associated with the nonrandomized selection of cases included in the further analysis. Moreover, third, the paper does not present a control group, which makes it difficult to objectively compare open and MISS methods.

### CONCLUSION

Minimally invasive corpectomy with transcutaneous transpedicular stabilization is an effective method of treating patients with unstable injuries of the thoracolumbar spine. The technique used has minimal surgical trauma with the possibility of early postoperative rehabilitation and provides a significant persistent reduction in vertebral pain syndrome, a significant improvement in neurological disorders, and restoration of the quality of life of patients in the follow-up.

The technology makes it possible to effectively eliminate kyphotic deformity and prevent the loss of its reduction with a low number of postoperative surgical complications.

It is necessary to conduct prospective multicenter studies with high methodological quality on a larger number of respondents for a comparative assessment of long-term clinical and instrumental data of minimally invasive and open surgical interventions in the treatment of traumatic injuries of the thoracolumbar spine.

### Financial support and sponsorship

Nil.

### Conflicts of interest

There are no conflicts of interest.

### REFERENCES

1. Faciszewski T, Winter RB, Lonstein JE, Denis F, Johnson L. The surgical and medical perioperative complications of anterior spinal fusion surgery in the thoracic and lumbar spine in adults. A review of 1223 procedures. *Spine (Phila Pa 1976)* 1995;20:1592-9.
2. Kim YB, Lenke LG, Kim YJ, Kim YW, Blanke K, Stobbs G, *et al.* The morbidity of an anterior thoracolumbar approach: adult spinal deformity patients with greater than five-year follow-up. *Spine (Phila Pa 1976)* 2009;34:822-6.
3. Javidan Y, Hurley MR. Minimally invasive lateral approach to thoracic and lumbar spine: For discectomy and corpectomy for trauma, tumor, infection, and deformity. *Oper Tech Orthop* 2019;29:100721.
4. Rajasekaran S, Kanna RM, Shetty AP. Management of thoracolumbar spine trauma: An overview. *Indian J Orthop* 2015;49:72-82.
5. D'Aliberti G, Talamonti G, Villa F, Debernardi A, Sansalone CV, LaMaida A, *et al.* Anterior approach to thoracic and lumbar spine lesions: Results in 145 consecutive cases. *J Neurosurg Spine* 2008;9:466-82.
6. Landreneau RJ, Hazelrigg SR, Mack MJ, Dowling RD, Burke D, Gavlick J, *et al.* Postoperative pain-related morbidity: Video-assisted thoracic surgery versus thoracotomy. *Ann Thorac Surg* 1993;56:1285-9.
7. Gómez JA, Ludwig SC. Minimally invasive techniques for thoracolumbar spine trauma. *Contemp Spine Surg* 2012;13:1-7.
8. Camacho JE, Usmani MF, Strickland AR, Banagan KE, Ludwig SC. The use of minimally invasive surgery in spine trauma: A review of concepts. *J Spine Surg* 2019;5:S91-100.
9. Kaul R, Chhabra HS, Vaccaro AR, Abel R, Tuli S, Shetty AP, *et al.* Reliability assessment of AOSpine thoracolumbar spine injury classification system and Thoracolumbar Injury Classification and Severity Score (TLICS) for thoracolumbar spine injuries: Results of a multicentre study. *Eur Spine J* 2017;26:1470-6.
10. Farcy JP, Weidenbaum M, Glassman SD. Sagittal index in management of thoracolumbar burst fractures. *Spine (Phila Pa 1976)* 1990;15:958-65.
11. ASIA and ISCoS International Standards Committee. The 2019 revision of the International Standards for Neurological Classification of Spinal Cord Injury (ISNCSCI) – What's new? *Spinal Cord* 2019;57:815-7.
12. Schnake KJ, Schroeder GD, Vaccaro AR, Oner C. AOSpine Classification Systems (Subaxial, Thoracolumbar). *J Orthop Trauma* 2017;31 Suppl 4:S14-23.
13. Wood KB, Li W, Lebl DR, Ploumis A. Management of thoracolumbar spine fractures. *Spine J* 2014;14:145-64.
14. Walker CT, Xu DS, Godzik J, Turner JD, Uribe JS, Smith WD. Minimally invasive surgery for thoracolumbar spinal trauma. *Ann Transl Med* 2018;6:102.
15. Byvaltsev VA, Kalinin AA, Kononov NA. Minimal'no invazivnaia khirurgiia pozvonochnika: Étapy razvitiia [Minimally invasive spinal surgery: Stages of development]. *Zh Vopr Neirokhir Im N N Burdenko* 2019;83:92-100.
16. Le H, Barber J, Phan E, Hurley RK Jr, Javidan Y. Minimally invasive lateral corpectomy of the thoracolumbar spine: A case series of 20 patients. *Global Spine J* 2020;???:2192568220945291. [Epub ahead of print].
17. Korekij T, Park DK, Fischgrund J. Minimally invasive spine surgery in the treatment of thoracolumbar and lumbar spine trauma. *Neurosurg Focus* 2014;37:E11.
18. Pneumáticos SG, Triantafyllopoulos GK, Giannoudis PV. Advances made in the treatment of thoracolumbar fractures: Current trends and future directions. *Injury* 2013;44:703-12.
19. Kallemeier PM, Beaubien BP, Buttermann GR, Polga DJ, Wood KB. *In vitro* analysis of anterior and posterior fixation in an experimental unstable burst fracture model. *J Spinal Disord Tech* 2008;21:216-24.
20. Panchal RR, Matheis EA, Gudipally M, Hussain MM, Kim KD, Bucklen BS. Is lateral stabilization enough in thoracolumbar burst fracture reconstruction? A biomechanical investigation. *Spine J* 2015;15:2247-53.
21. Eck JC. Minimally invasive corpectomy and posterior stabilization for lumbar burst fracture. *Spine J* 2011;11:904-8.
22. Smith WD, Dakwar E, Le TV, Christian G, Serrano S, Uribe JS. Minimally invasive surgery for traumatic spinal pathologies: A mini-open, lateral approach in the thoracic and lumbar spine. *Spine (Phila Pa 1976)* 2010;35:S338-46.
23. Banagan K, Ludwig SC. Thoracolumbar spine trauma: When damage control minimally invasive spine surgery is an option. *Semin Spine Surg*

- 2012;24:221-5.
24. Kim SJ, Sohn MJ, Ryoo JY, Kim YS, Whang CJ. Clinical analysis of video-assisted thoracoscopic spinal surgery in the thoracic or thoracolumbar spinal pathologies. *J Korean Neurosurg Soc* 2007;42:293-9.
  25. Rampersaud YR, Annand N, Dekutoski MB. Use of minimally invasive surgical techniques in the management of thoracolumbar trauma: Current concepts. *Spine (Phila Pa 1976)* 2006;31:S96-102.
  26. Khoo LT, Beisse R, Potulski M. Thoracoscopic-assisted treatment of thoracic and lumbar fractures: A series of 371 consecutive cases. *Neurosurgery* 2002;51:S104-17.
  27. Gandhoke GS, Tempel ZJ, Bonfield CM, Madhok R, Okonkwo DO, Kanter AS. Technical nuances of the minimally invasive extreme lateral approach to treat thoracolumbar burst fractures. *Eur Spine J* 2015;24 Suppl 3:353-60.
  28. Lu DC, Lau D, Lee JG, Chou D. The transpedicular approach compared with the anterior approach: An analysis of 80 thoracolumbar corpectomies. *J Neurosurg Spine* 2010;12:583-91.
  29. Shin SR, Lee SS, Kim JH, Jung JH, Lee SK, Lee GJ, *et al.* Thoracolumbar burst fractures in patients with neurological deficit: Anterior approach versus posterior percutaneous fixation with laminotomy. *J Clin Neurosci* 2020;75:11-8.
  30. Theologis AA, Tabaraee E, Toogood P, Kennedy A, Birk H, McClellan RT, *et al.* Anterior corpectomy via the mini-open, extreme lateral, transpoas approach combined with short-segment posterior fixation for single-level traumatic lumbar burst fractures: Analysis of health-related quality of life outcomes and patient satisfaction. *J Neurosurg Spine* 2016;24:60-8.
  31. Reinhold M, Knop C, Beisse R, Audigé L, Kandziora F, Pizanis A, *et al.* Operative treatment of 733 patients with acute thoracolumbar spinal injuries: Comprehensive results from the second, prospective, Internet-based multicenter study of the Spine Study Group of the German Association of Trauma Surgery. *Eur Spine J* 2010;19:1657-76.
  32. Tabaraee E, Ahn J, Aboushaala K, Singh K. A comparison of surgical outcomes between minimally invasive and open thoracolumbar corpectomy. *Int J Spine Surg* 2020;14:736-44.
  33. Huangxs S, Christiansen PA, Tan H, Smith JS, Shaffrey ME, Uribe JS, *et al.* Mini-Open lateral corpectomy for thoracolumbar junction lesions. *Oper Neurosurg (Hagerstown)* 2020;18:640-7.
  34. Payer M, Sottas C. Mini-open anterior approach for corpectomy in the thoracolumbar spine. *Surg Neurol* 2008;69:25-31.