

CASE REPORT

Three cases of brain hydatidosis in North Khorasan, Iran

Reza Shafiei¹ | Saber Raeghi² | Fatemeh Jafarzadeh¹ | Mohsen Najjari³ |
Mohammad Amin Ghatee⁴ | Azar Shokri¹ 

¹Vector-borne Diseases Research Center, North Khorasan University of Medical Sciences, Bojnurd, Iran

²Department of Laboratory Sciences, Maragheh University of Medical Sciences, Maragheh, Iran

³Department of Parasitology and Mycology, School of Medicine, Mashhad University of Medical Sciences, Mashhad, Iran

⁴Cellular and Molecular Research Center, Medical Microbiology Department, School of Medicine, Yasuj University of Medical Sciences, Yasuj, Iran

Correspondence

Azar Shokri, Vector-Borne Diseases Research Center, North Khorasan University of Medical Sciences, Shahriar Street, Bojnurd 9414974877, Iran.
Email: azar_sh1969@yahoo.com

Abstract

Cystic hydatidosis is a serious public health problem in Iran. Although cysts can develop in almost all organs and the brain cysts are very rare. Here, we present 3 confirmed cases of brain hydatidosis and the patients who underwent successful surgery. Pathological examinations demonstrated the presence of cystic hydatidosis.

KEYWORDS

brain, cystic hydatidosis, *Echinococcus granulosus*, Iran

1 | INTRODUCTION

Cystic Echinococcosis (CE) or hydatid cyst is one of the most important and common zoonotic diseases in the world. The disease is caused by the larval stage of tapeworms *Echinococcus granulosus* (*E. granulosus*). The adult worms are inhabitants in the intestine of dogs and other canid families as the final hosts.^{1–4}

Dogs are infected by eating contaminated viscera and after a few months, they excrete the eggs with feces.^{2,5} The eggs can contaminate foods and water sources and mammalian (including human) infections occur through consumption of contaminated food/water.

Cystic hydatidosis is a worldwide disease with the highest rate of infection in the Mediterranean southern and central parts of Russia, the Middle East, South America,

Central Asia, Australia, China, and North and East Africa. The World Health Organization (WHO) has classified it as the most prevalent global food-borne disease.^{6,7} According to the WHO, Iran is considered one of the hyperendemic areas of the disease due to the high rate of dogs' exposure to livestock (3,4). The prevalence of hydatid cysts in the intermediate host was reported at 11.5%–34.6% and the incidence of 5% in human have been reported from different parts of Iran.⁵

The clinical symptoms and the incubation period of the disease vary depending on the involved organs, the size of the cyst, and/or the genotype of the parasite.^{2,8} Most of the organs of the body, including the liver, lungs, brain, spleen, and bones can be involved with hydatid cysts which would be led to serious risks and distress in the absence of a timely diagnosis and treatment.^{2,9} Rare

This is an open access article under the terms of the [Creative Commons Attribution-NonCommercial-NoDerivs](https://creativecommons.org/licenses/by-nc-nd/4.0/) License, which permits use and distribution in any medium, provided the original work is properly cited, the use is non-commercial and no modifications or adaptations are made.

© 2022 The Authors. *Clinical Case Reports* published by John Wiley & Sons Ltd.

cases of hydatidosis have been reported in soft tissue, pancreas, and musculoskeletal tissue.¹⁰

The most common sites are the liver (75%) and lungs (15%) followed by the spleen, kidney, heart, bones, and brain (10%).^{11,12,16}

In this study patients who had been surgically treated with cerebral cysts were examined.

There are many studies on the clinical manifestations and surgical procedures of patients with hydatid cysts^{13–15} but the author's attention was on the existence of cysts in the brain.

2 | METHODS

Three cases of brain hydatid cysts were treated from 2006 to 2014 in the surgical department at the Emam Ali hospital of North Khorasan University of Medical Sciences, placed in Northeast of Iran, Bojnurd (Figure 1). North Khorasan is a province of Iran that is located in northeastern the country and Bojnurd is the capital of the province. North Khorasan covers an area of 28,434 km² and has a population of 850,000. The geographical coordinates of the province are 37°28'34"N and 57°19'54"E. The counties of North Khorasan Province are Shirvan County, Esfarayen County, Maneh and Samalqan County, Raz and Jargalan County, Jajarm County, Faruj County, and Garmeh County. The climate in North Khorasan is referred to as a local steppe climate. There is not much rainfall in North Khorasan all year long.

The recorded information of mentioned patients was retrospectively reviewed. The demographic characteristics (including age, gender, geographic origin), their symptoms, results of laboratory tests, radiologic findings (CT scan/MRI), surgical methods, postoperative complications, and disease recurrence were recorded. On CT scan, cysts were recognizable, and considering serologic tests, the surgeon decided on the operation. Operations were performed by the protection of adjacent organs with large compresses impregnated with hypertonic saline solution (as scolicide) and through careful removing the cyst without leakage of their content. Washing of the cavity with hypertonic saline solution and external drainage of the cavity was performed for the prevention of generating new cysts. The diagnosis of brain hydatid cyst was confirmed in all cases by histopathological examination of resected specimens. Antibiotic and albendazole were administered to patients after surgery and they were followed up for 12 months fortunately, no recurrence was observed in our patients except in one of them who underwent a second surgery.

3 | CASE PRESENTATION

3.1 | Case 1

A 3-year-old boy from Ghasre Ghajar rural area of Badranlo around Bojnurd city. He was referred to the hospital with symptoms of headache. In the preliminary examination, brain CT was performed on the patient and

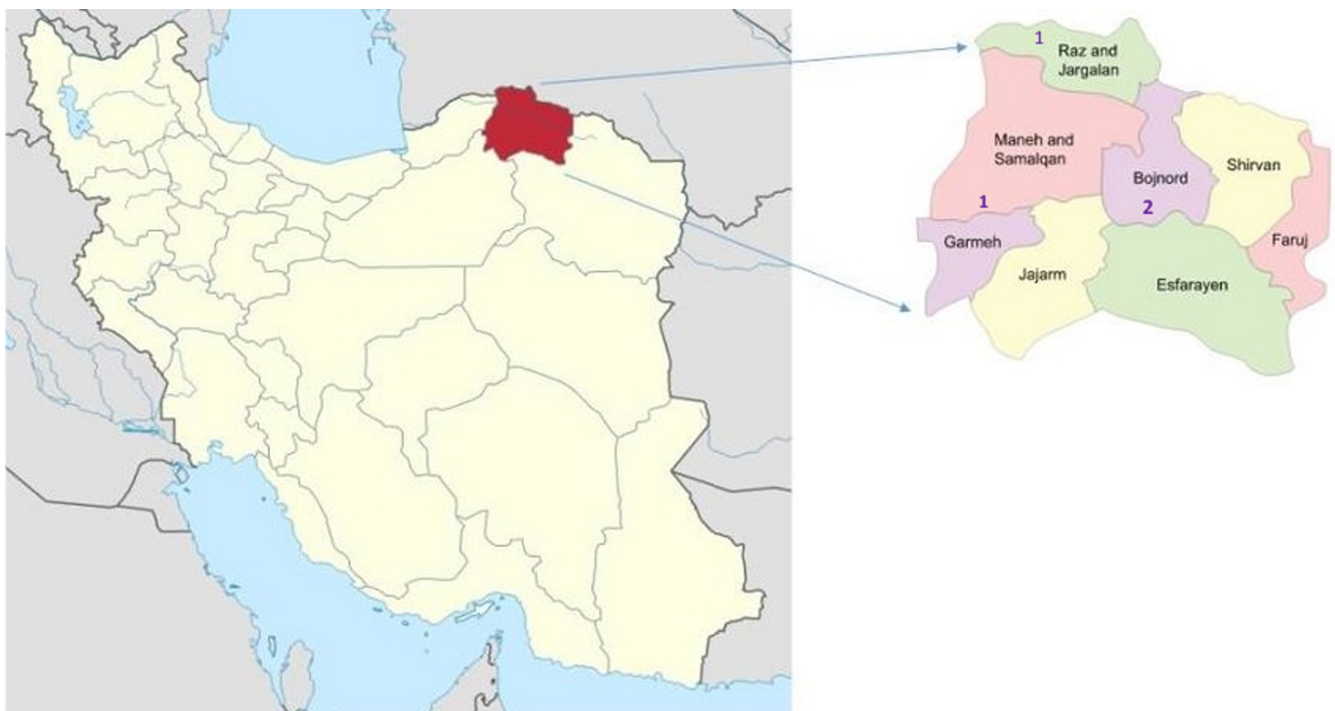


FIGURE 1 The location of study in Iran. Cases are shown in geographical area

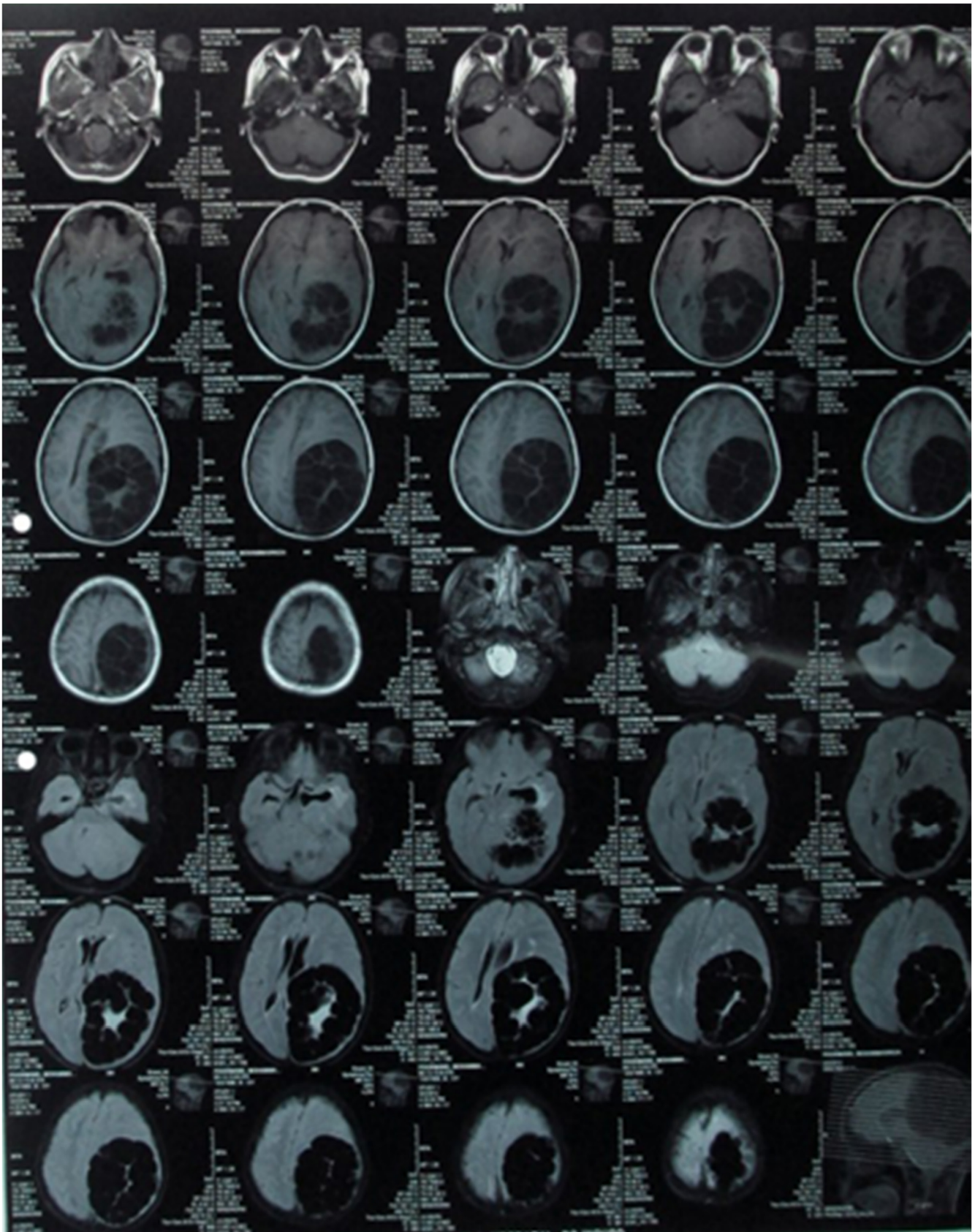


FIGURE 2 Magnetic resonance imaging showing hydatid cyst in Case 1

a mass of circle cyst in the left temporoparietal measured 8.5*4 cm with impression effect was seen in the brain. In the laboratory investigation, hemoglobin was 12g/dl, white blood cell was 6500 / μ l of which 55% was neutrophil, 39% lymphocyte, 6% monocyte. For treatment of hydatid cyst, the patient was subjected to surgery with the craniotomy method. Also, cyst resection and left graft dorsal were performed (Figures 2 and 3). Treatment with albendazole was started after the operation to prevent further echinococcosis, and also, received Dilantin (phenytoin sodium) (5 mg/kg/d in divided doses) for prevention of seizure. Post-operation MRI and CT scan images revealed no sign of relapse.

3.2 | Case 2

A 59-year-old housewife from Chakhmaghlo in Mane and Samalghan city. She was referred to the hospital

with symptoms of fever and headache. The patient has had involuntary movements and five senses reduced. In the preliminary examination, brain CT was performed on the patient and a cyst was seen in the right parietal-occipital measured 9*8 cm. In the laboratory investigation, hemoglobin was 11.9 g/dl, white blood cell was 10,800 / μ l with 91% neutrophil, 5.5% lymphocyte, and 3.5% monocyte.

This patient had a history of liver cysts. Craniotomy with dysplastic cyst and keratoplasty was performed. A single cyst of 9*8*2 cm with a germinal layer of cysts isolated (Figure 4). The patient had a sister who had undergone surgery for hydatidosis (Figure 5). Treatment with albendazole was started when the patient was discharged from the hospital to prevent further echinococcosis, and also, Dilantin (phenytoin sodium) (5 mg/kg/d in divided doses) was prescribed for the prevention of seizures. MRI and CT scan images were taken after surgery and no mass was seen.

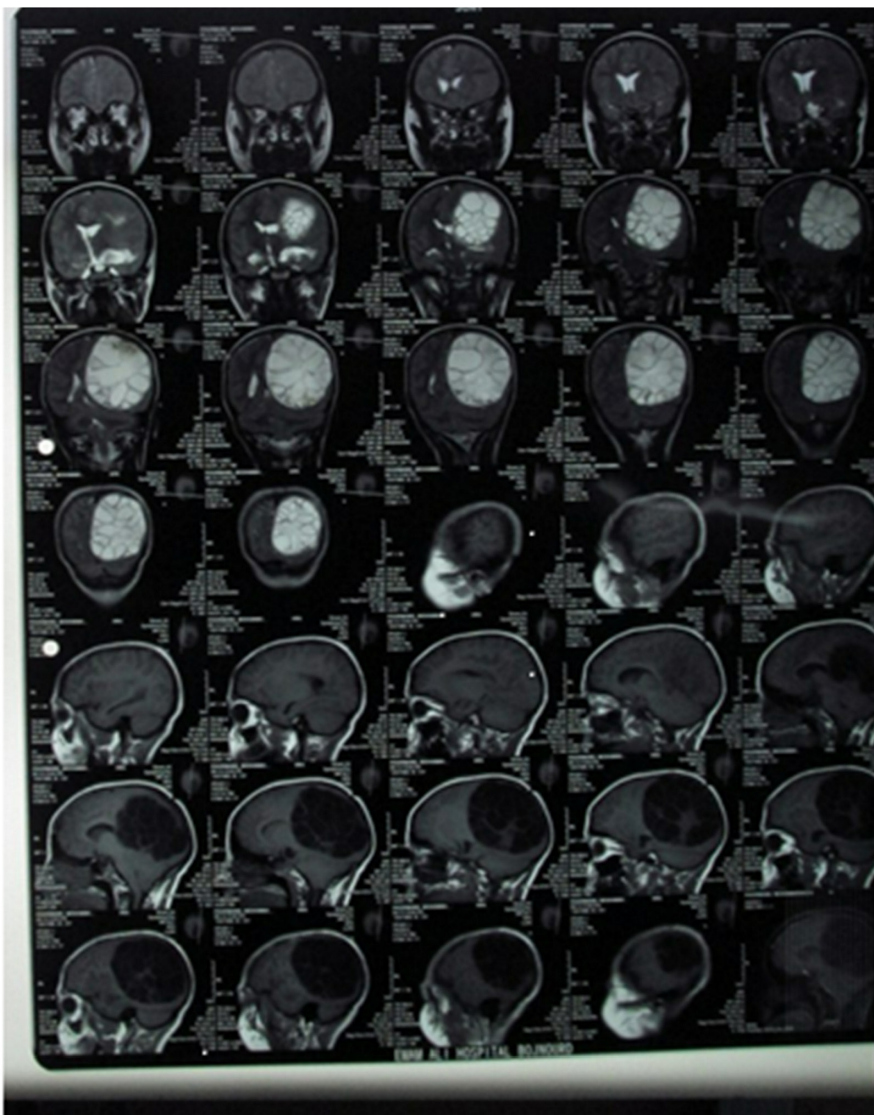


FIGURE 3 Magnetic resonance imaging showing cystic lesion in Case 1

FIGURE 4 Magnetic resonance imaging showing cystic lesion in Case 3

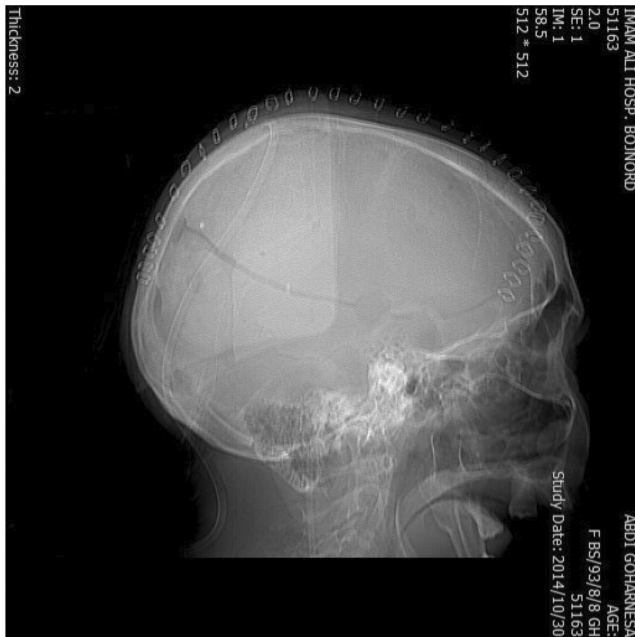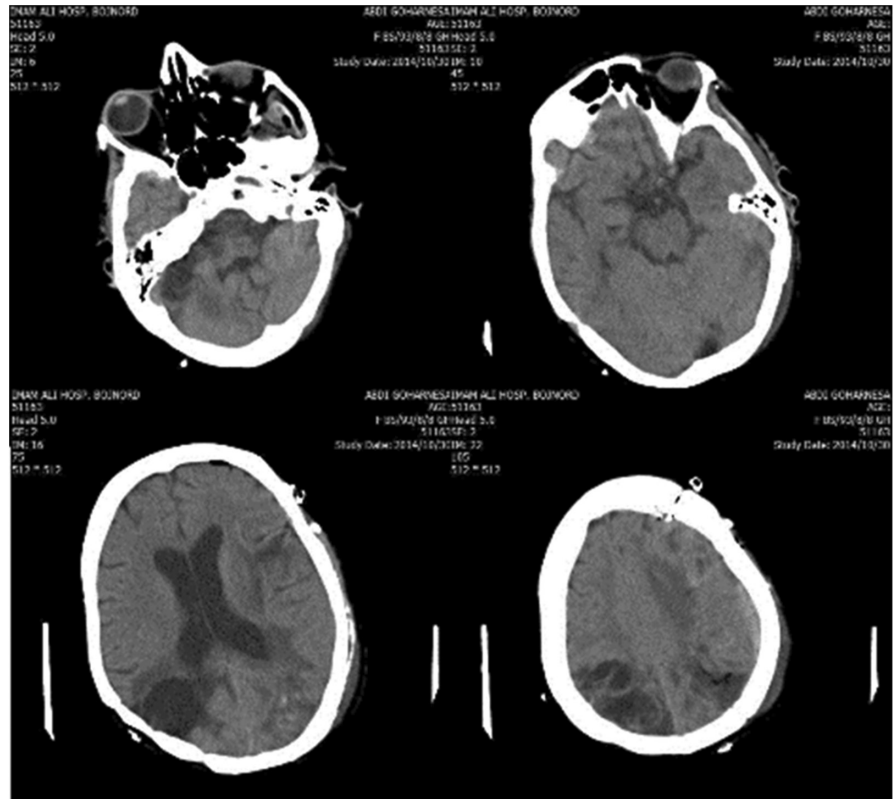


FIGURE 5 Skull radiography post-operation Case 3

3.3 | Case 3

A 53-year-old housewife from Bojnurd city was referred to the hospital with angiopathy, nausea, and vomiting. In the preliminary investigation, a brain CT was performed and the presence of a cyst with dimensions 6*4 cm was demonstrated. The complete blood investigation was performed with the following results: hemoglobin was 11 g/

dl, white blood cell 8000 / μ l, neutrophil 60%, lymphocyte 32%, monocyte 4%, and eosinophil 4%. The patient underwent surgery. The first operation of frontal and left occipital craniotomy was performed with cyst discharge. In the second operation, the frontal and occipital repair was performed after discharging multiple brain cysts. Treatment with albendazole was started post-operation to prevent further echinococcosis. Necessary medication for seizures prevention was used. Post-operation MRI and CT scan images were taken during the follow-up process and no sign of a cyst was seen.

4 | DISCUSSION

Hydatidosis is an endemic disease in Iran, particularly in rural areas where sheep raising is popular.¹⁶ Although the soft tissues are more likely to be infected with the parasite the brain cysts are unusual and rare.¹¹ The disease imposes the cost of US\$1539 for the surgery of each human hydatidosis case.¹⁷ Here, we explained four cases of brain hydatid cysts with complications and surgical treatments. Of our four cases, two were housewives. Brain hydatid cyst also is classified as primary (single) or secondary (multiple). The primary cysts are formed as a result of direct infection of the brain without the involvement of other organs and the secondary multiple cysts result from spontaneous, traumatic, or surgical rupture of a solitary cranial cyst.¹¹ Hydatid cysts can be established anywhere

in the brain and are mostly located supratentorial, in the middle cerebral artery territory.¹⁸ Vomiting and seizure due to raised intracranial pressure and brain compression are present in intracranial hydatid cysts. Papilledema and neurological deficit may be presented in physical examination.¹⁹ Although diagnosis is based on medical history and some characteristics such as family history, occupation, and place of residence but the concise diagnosis is unlikely without a high degree of suspicion of hydatid cysts and radiological findings, and therefore, needs histopathological confirmation.^{20,21}

Serological tests such as Casoni's intradermal test, complement fixation test, and ELISA may also be helpful for the diagnosis of hydatid disease but are not very reliable. Clinically, the disease is usually asymptomatic, and the clinical symptoms differ depending on the location and pressure effect of the cyst. Brain hydatidosis is an important clinical situation in the pediatric age group and may misdiagnose as an intracranial cyst, so in the differential diagnosis of intracranial cyst especially in endemic areas, the age of patients should be considered.²² Although in small or inoperable brain cysts, medical therapy has shown promising effects surgery remains the golden treatment by which cysts can be removed without rupture and results in a complete cure. Chemotherapy with two benzimidazoles (ABZ or MBZ) is indicated for inoperable patients with brain hydatidosis and for the prevention of secondary hydatid disease.¹¹ In our cases, surgery along with chemotherapy resulted in the complete cure.

5 | CONCLUSIONS

Hydatidosis should be considered a differential diagnosis of any cyst in the brain, particularly in endemic regions.

AUTHOR'S CONTRIBUTIONS

All of the authors had equal roles in study concept and design, acquisition of data, drafting of the manuscript, critical revision of the manuscript, and practical work

ACKNOWLEDGMENTS

The authors are thankful to the clinical research development center of Imam Ali Hospital, the North Khorasan University of Medical Science for their contributions and assistance.

FUNDING INFORMATION

No funding.

CONFLICT OF INTEREST

None declared.

ETHICAL APPROVAL

Applicable.

DATA AVAILABILITY STATEMENT

All the data are available without restriction.

CONSENT

Written informed consent was obtained from the patient for publication of this case report and any accompanying images. A copy of the written consent is available for review by the Editor of this journal.

ORCID

Azar Shokri  <https://orcid.org/0000-0002-0593-8853>

REFERENCES

1. Possenti A, Manzano-Román R, Sánchez-Ovejero C, et al. Potential risk factors associated with human cystic echinococcosis: systematic review and meta-analysis. *PLoS Negl Trop Dis*. 2016;10(11):e0005114.
2. Shafiei R, Ghatee MA, Jafarzadeh F, Javanshir Z, Karamian M. Genotyping and phylogenetic analysis of unusually located hydatid cysts isolated from humans in north-east Iran. *J Helminthol*. 2019;94:e64.
3. Ghatee MA, Nikaein K, Taylor WR, et al. Environmental, climatic and host population risk factors of human cystic echinococcosis in the southwest of Iran. *BMC Public Health*. 2020;20(1):1-13.
4. Jamshidi A, Haniloo A, Fazaeli A, Ghatee MA. Effects of geographical and climatic factors on cystic echinococcosis in south-western Iran. *J Helminthol*. 2020;94:e175.
5. Khazaei S, Rezaeian S, Khazaei Z, et al. Epidemiological and clinical characteristics of patients with hydatid cysts in Khorasan Razavi Province, from 2011 to 2014. *Iran J Parasitol*. 2016;11(3):364-370.
6. Abdelraouf A, El-Aal AAA, Shoeib EY, et al. Clinical and serological outcomes with different surgical approaches for human hepatic hydatidosis. *Rev Soc Bras Med Trop*. 2015;48:587-593.
7. Budke CM, Carabin H, Ndimubanzi PC, et al. A systematic review of the literature on cystic echinococcosis frequency worldwide and its associated clinical manifestations. *Am J Trop Med Hyg*. 2013;88:1011-1027.
8. Aliabadi ZA, Berenji F, Abdolmajid F, Jarahi L. Human hydatidosis/echinococcosis in north eastern Iran from 2003–2012. *Iran J Parasitol*. 2015;10(4):658.
9. Singal R, Sandhu KS, Mittal A, Gupta S, Jindal G. A giant splenic hydatid cyst. *Proceedings (Baylor University Medical Center)*. 2016;29(1):55-57.
10. Madeo J, Zheng X, Ahmed S, De Oleo RR. Primary cerebral echinococcosis presenting as long-standing generalized weakness. *Germs*. 2013;3(2):63-66.
11. Ganjeifar B, Ghafouri M, Shokri A, Rahbarian Yazdi F, Hashemi SA. Giant cerebral hydatid cyst: a rare case report. *Clin Case Rep*. 2020;9(3):1-5.
12. Ghafouri M, Yeganeh Khorasani E, Shokri A. Primary pelvic hydatid cyst in an infertile female, a case report. *Clin Case Rep*. 2020;8(9):1769-1773.

13. Basarslan SK, Gocmez C, Kamasak K, Ceviz A. The Gigant primary cerebral hydatid cyst with no marked manifestation: a case report and review of literature. *Eur Rev Med Pharmacol Sci.* 2015;19(8):1327-1329.
14. Ijaz L, Mirza B, Nadeem MM, Saleem M. Simultaneous giant hydatid cysts of brain and liver. *J Coll Physicians Surg Pak.* 2015;25(Suppl 1):S53-S55.
15. Eser I, Karabag H, Gunay S, et al. Surgical approach for patients with unusually located hydatid cyst. *Ann Ital Chir.* 2014;85(1):50-55.
16. Rokni MB. Echinococcosis/hydatidosis in Iran. *Iranian J Parasitol.* 2009;4(2):1-16.
17. Mahmoudi S, Mamishi S, Banar M, Pourakbari B, Keshavarz H. Epidemiology of echinococcosis in Iran: a systematic review and meta-analysis. *BMC Infect Dis.* 2019;19:929.
18. Binesh F, Mehrabani M, Navabii H. Primary brain hydatidosis. *BMJ Case Rep.* 2011;2011:bcr0620103099. doi:10.1136/bcr.06.2010.3099
19. Moldovan R, Neghina AM, Calma CL, Marincu I, Neghina R. Human cystic echinococcosis in two south-western and central-western Romanian counties: a 7-year epidemiological and clinical overview. *Acta Trop.* 2012;121(1):26-29.
20. Katilmis H, Ozturkcan S, Ozdemir I, Guvenc IA, Ozturan S. Primary hydatid cyst of the neck. *Am J Otolaryngol.* 2007;28:205-207.
21. Sahin B, Comoglu S, Polat B, Deger K. Hydatid cyst in an unusual location: pterygopalatine fossa—infratemporal fossa. *Auris Nasus Larynx.* 2016;43(4):464-467.
22. Shafiei R, Taghasi F, Hashemi SA, et al. Seroprevalence of cystic echinococcosis using recombinant antigen B-ELISA in North Khorasan Province, northeast of Iran. *Iran J Public Health.* 2021;50(3):592-597. doi:10.18502/ijph.v50i3.5605

How to cite this article: Shafiei R, Raeghi S, Jafarzadeh F, Najjari M, Ghatee MA, Shokri A. Three cases of brain hydatidosis in North Khorasan, Iran. *Clin Case Rep.* 2022;10:e06095. doi: [10.1002/ccr3.6095](https://doi.org/10.1002/ccr3.6095)