



Contents lists available at ScienceDirect

International Journal of Surgery Case Reports

journal homepage: www.casereports.com

Orthognathic surgery during breast cancer treatment—A case report



Tsuyoshi Shimo^{a,*}, Norie Yoshioka^a, Masahiro Nakamura^b, Soichiro Ibaragi^a,
Tatsuo Okui^a, Yuki Kunisada^a, Masanori Masui^a, Mayumi Yao^a, Koji Kishimoto^a,
Shoko Yoshida^a, Akiyoshi Nishiyama^a, Hiroshi Kamioka^b, Akira Sasaki^a

^a Department of Oral and Maxillofacial Surgery, Okayama University Graduate School of Medicine, Dentistry and Pharmaceutical Sciences, Okayama 700-8525, Japan

^b Department of Orthodontics, Okayama University Graduate School of Medicine, Dentistry and Pharmaceutical Sciences, Okayama 700-8525, Japan

ARTICLE INFO

Article history:

Received 24 July 2016

Received in revised form

23 December 2016

Accepted 24 December 2016

Available online 3 January 2017

Keywords:

Orthognathic surgery

Breast cancer

Tamoxifen

ABSTRACT

INTRODUCTION: In recent years, patients with orthognathic surgery in middle-aged and elderly people have come to be a more frequent occurrence. Breast cancer is the most frequently diagnosed cancer in woman worldwide, and its prevalence rate is steadily increasing.

PRESENTATION OF CASE: We report a case of a 47-year-old Japanese woman in whom left-side breast cancer (Stage 1) was unexpectedly found just before orthognathic surgery in April 2012. Breast-conserving surgery was performed (estrogen receptor+, progesterone receptor+, HER2 -, surgical margin+, sentinel lymph node +) that May. From June to August docetaxel (75 mg/m²) and cyclophosphamide (600 mg/m²) were administered four times every 21 days and thereafter radiotherapy (total 60 Gy) was completed. The cancer surgeon declared the prognosis good and the patient had a strong desire to undergo orthognathic surgery, so in November we performed a bimaxillary osteotomy, and administration of tamoxifen began 6 weeks after the osteotomy.

DISCUSSION: There are breast cancer cases in which the prognosis is sufficiently good for a planned orthognathic surgery to proceed. Good communication among surgeons and the patient is important.

CONCLUSION: We experienced a case in which breast cancer was found just before the orthognathic surgery; we performed a bimaxillary osteotomy, including follow-up tamoxifen administration, during breast cancer treatment.

© 2017 The Authors. Published by Elsevier Ltd on behalf of IJS Publishing Group Ltd. This is an open access article under the CC BY-NC-ND license (<http://creativecommons.org/licenses/by-nc-nd/4.0/>).

1. Introduction

In recent years, interest in oral health and aesthetics has increased, and more patients are undergoing orthognathic surgery in middle age or later. Treatment of skeletal Class III malocclusion in adults requires a combination of orthodontic and surgical procedures to achieve normal occlusion and improve facial aesthetics [1]. Normal jawbone healing becomes an important factor for the stability of the postoperative occlusion.

Breast cancer is the most frequently diagnosed cancer in women worldwide [2]. The incidence rate begins to increase after 20 years of age in both the Japanese and US populations, continuing to increase similarly until 45–49 years [3]. Improvements in surgery, chemotherapy, lymph node evaluation and hormone receptor blocking therapy have increased the survival of breast can-

cer patients [4]. Different molecular subtypes of breast cancer have various prognoses and responses to therapy [5].

Here we present a case in which breast cancer was unexpectedly found just before orthognathic surgery, and bimaxillary osteotomy was performed during the course of breast cancer treatment.

2. Presentation of case

A 45-year-old female sought orthognathic treatment at Okayama University hospital. Her main complaint was occlusal imperfection and mandibular protrusion. She had a mandibular protrusion, a concave facial profile and facial asymmetry (Fig. 1). Intraoral examination revealed a Class III malocclusion with an excessive negative overbite (–1 mm) and overjet (–4 mm). Representative initial cephalometric values were as follows (Table 1): SNA, 78.5°; SNB, 78.5°; ANB, 0.0°; Mp-FH, 40.5°; Gonial angle, 136.0°; U1-SN, 102.5°; L1-Mp, 84.0°; IIA, 127.0°; Occ P, 25.5°; N-Me, 142.5 mm; N/NF, 61.0 mm; Me/NF, 81.5 mm; Go-Me, 78.0 mm; Ar-Go, 51.0 mm; Ar-Me, 121.0 mm; U6/NF, 26.9 mm; U1/NF, 34.1 mm, L6/Mp, 36.5 mm; and L1/Mp, 46.5 mm. The patient was diagnosed as having an Angle Class III malocclusion with a skeletal Class III jaw base relationship and skeletal open bite.

* Corresponding author at: Department of Oral and Maxillofacial Surgery, Okayama University Graduate School of Medicine, Dentistry and Pharmaceutical Sciences, 2-5-1 Shikata-cho, Kita-ku, Okayama 700-8525, Japan.

E-mail address: shimotsu@md.okayama-u.ac.jp (T. Shimo).

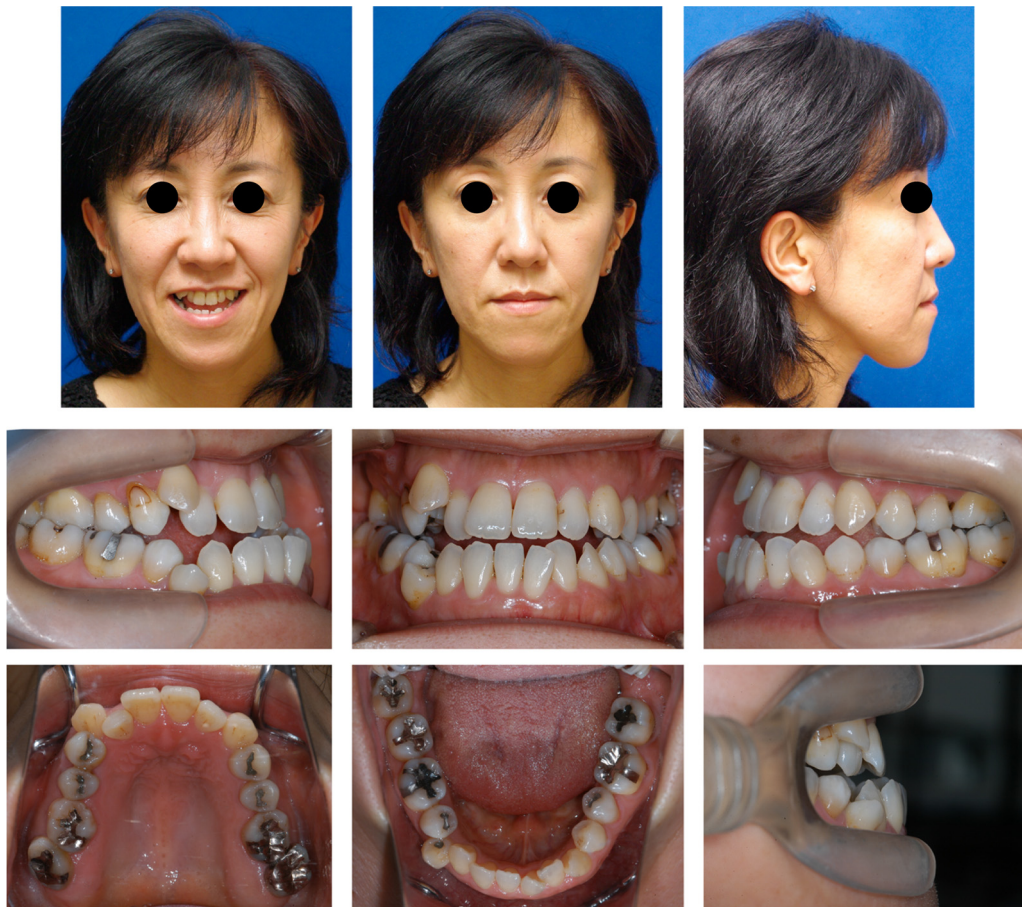

Fig. 1. Facial and oral photographs in pretreatment.

Table 1
Cephalometric measurements.

	Mean	SD	Initial 45y 3mo	Posttreatment 49y 3mo
Angular analysis (°)				
SNA	80.8	3.6	78.5	80.5
SNB	77.9	4.5	78.5	76.0
ANB	2.8	2.4	0.0	4.5
Mp-FH	30.5	3.6	40.5	41.5
Gonial angle	122.1	5.3	136.0	139.5
U1-SN	105.9	8.8	102.5	98.0
L1-Mp	93.4	6.8	84.0	88.0
IIA	123.6	10.6	127.0	126.5
Occ p	16.9	4.4	25.5	25.0
Linear analysis (mm)				
N-Me	125.8	3.7	142.5	137.5
N/NF	56.0	2.5	61.0	61.0
Me/NF	68.6	3.7	81.5	76.5
Go-Me	71.4	4.1	78.0	69.5
Ar-Go	47.3	3.3	51.0	51.5
Ar-Me	106.6	5.7	121.0	114.0
U6/NF	24.6	2.0	26.9	26.5
U1/NF	31.0	2.3	34.1	33.0
L6/Mp	32.9	2.5	36.5	34.0
L1/Mp	44.2	2.7	46.5	47.0
Overjet	3.1	1.1	-4.0	2.0
Overbite	3.3	1.9	-1.0	2.0

Mean, average values of Japanese women; SD, standard deviation; S, sella; N, nasion; A, A-point; B, B-point; SN, sella-nasion plane; Mp-FH, angle between mandibular plane and Frankfort (FH) plane; Gonial angle, angle between ramus plane and mandibular plane; U1-SN, upper incisor axis to SN; L1-Mp, angle between axial inclination of mandibular central incisor and mandibular plane; IIA, angle between upper incisor axis and lower incisor axis; Occ P, angle between SN and occlusal plane; N-Me, distance between nasion and menton; N/NF, perpendicular distance of nasion to nasal floor; Me/NF, perpendicular distance of menton to nasal floor; Go-Me, distance between gonion and menton; Ar-Go, distance between articulare and gonion; Ar-Me, distance between articulare and menton; U6/NF, perpendicular distance from the maxillary first molar to the nasal floor; U1/NF, perpendicular distance from the maxillary central incisor to the nasal floor; L6-MP, perpendicular distance from the mandibular first molar to the nasal floor; L1-MP, perpendicular distance of the mandibular incisor to the nasal floor.

After pre-surgical orthodontic treatment, orthognathic surgery was planned in 2012, but in April of that year the patient first underwent a medical examination at Okayama University hospital under suspicion of cancer in the left breast. She was diagnosed with breast cancer (stage 1), and left breast-conserving surgery and sentinel lymph node biopsy were performed in May 2012 (Estrogen receptor >50%, progesterone receptor >50%, HER2 negative, surgical margin positive, sentinel lymph node metastasis positive). Post-operative chemotherapy (docetaxel 75 mg/m² + cycloheximide 600 mg/m² × 4) was performed from June to August, then radiotherapy (total 60 Gy) was performed from September to November. As the breast cancer surgeon provided confirmation of a good prognosis and the patient still wanted to undergo orthognathic surgery, we went ahead and scheduled the bimaxillary osteotomy. In November, a maxillary segmental Le Fort I osteotomy (mx1 impaction, 2 mm; mx6 expansion, 5 mm; mx6 advancement, right 6 mm, left 4 mm; mx1 segmental area, bone augmentation) and mandibular bilateral intraoral vertical ramus osteotomy (IVRO, right M6, 6 mm and left M6, 4 mm, setback) was performed. Fig. 2 shows a panoramic X-ray view after the segmental Le Fort I osteotomy and IVRO. During the jawbone-healing period, administration of tamoxifen began 6 weeks after the orthognathic surgery. Occlusal stabilization was obtained followed by the completion of the postsurgical orthodontic treatment 10 months after the surgery. Fig. 3 shows the extraoral and intraoral views at debonding 10 months after orthognathic surgery. The cephalometric evaluation showed a skeletal Class I jaw relationship (Table 1). In order to examine the stability of the position of the anterior-posterior position of the bimaxillary after the osteotomy, we compared the lateral cephalograms at 3 months and 10 months (debonding) by super-

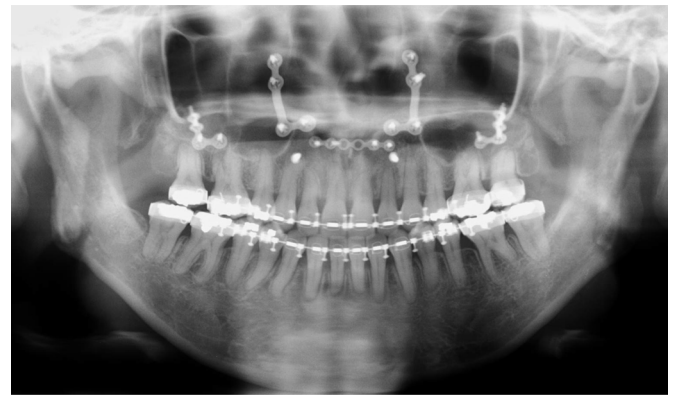

Fig. 2. Panoramic X-ray after the segmental Le Fort I osteotomy and IVRO.

imposition. From the post-operative bimaxillary stability shown in Fig. 4, it appeared that regeneration of the normal jawbone had occurred. It was also confirmed that the bone joining was performed normally even at the maxillary posterior part and the overlapping part of bone of the mandible IVRO (Fig. 5, arrows).

Four years after surgery, the stability of the occlusion has been maintained and there has been no recurrence of breast cancer.

3. Discussion

The treatment protocol produced satisfactory occlusal and aesthetic results. Maxillary advancement provided good support for the upper lip, and the maxillary segmental expansion also pro-

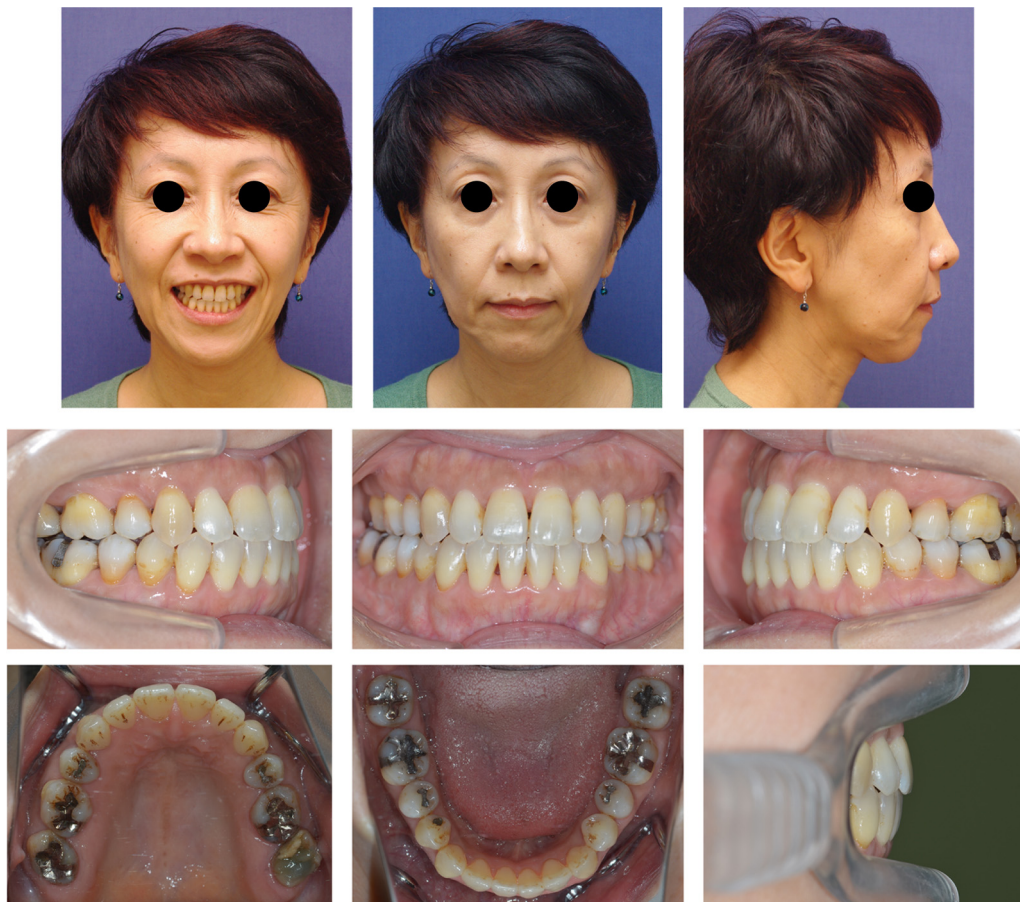

Fig. 3. Facial and oral photographs at debonding.

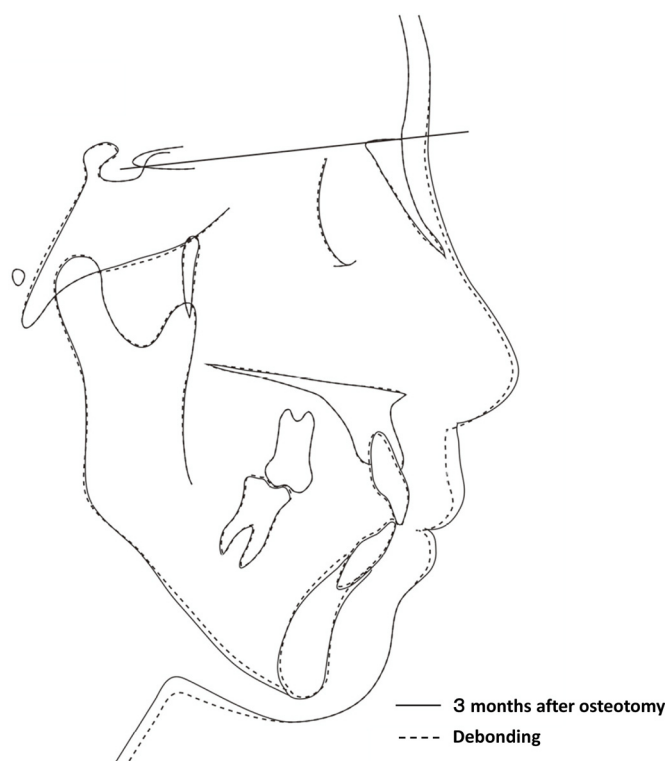


Fig. 4. Superimposition of the lateral cephalograms. Solid line: 3 months after orthognathic surgery, dotted line: debonding after 10 months after orthognathic surgery.

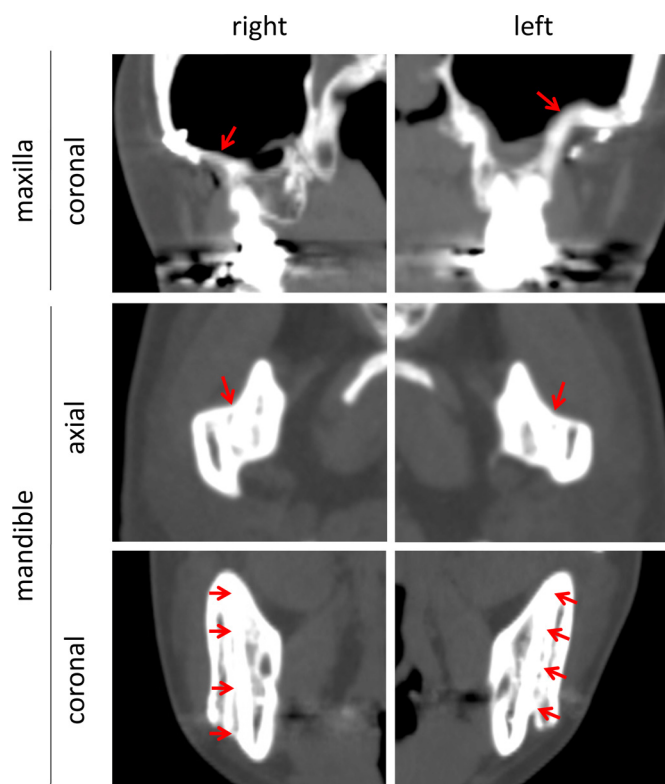


Fig. 5. CT images of the osteotomy line of maxilla and mandible 12 months after orthognathic surgery. arrows: osteotomy site with bone regeneration.

vided a satisfactory width relationship with the mandible. Bilateral IVRO also improved the functional mandibular deviation and the anterior-posterior relationship.

The normal healing processes of bone osteotomy are important factors for the stability of postoperative occlusion. Following Le Fort I osteotomies, the maxillary bone heals by intramembranous fracture healing using rigidly stable fixation. On the other hand, in mandible IVRO, non-stable healing conditions cause endochondral bone formation. This involves an acute inflammatory response including the production and release of several important molecules, and the recruitment of mesenchymal stem cells in order to generate a primary cartilaginous callus, with final remodeling that fully restores the normal bone structure [6].

Estrogen receptor α plays essential roles in the accumulation and maintenance of bone mass via cell-autonomous actions in both osteoblast progenitors and osteoclasts [7]. Estrogen deficiency results in loss of maxillary bone [8,9], and estrogen receptor α is required to maintain the microarchitecture of the maxillary alveolar bone [10]. Estrogen is also reported to be an important regulator of cartilage homeostasis, growth and maturation [11], and controls the growth and closure of the epiphyseal plate [12]. Estrogen could be involved in future advancements of fracture treatment [13] and seems to be an important factor in all stages of fracture healing [14]. These findings suggest that estrogen affects the Le Fort I osteotomy and IVRO healing process.

Tamoxifen treatment is associated with a decreased rate of growth [13], and causes a narrowing of the growth plate [14]. Tamoxifen acutely inhibits longitudinal bone growth in young male rats, an effect associated with an uptick in chondrocyte apoptosis and narrowing of the tibial growth plate [15,16]. Exposure to tamoxifen results in persistent reduction of cortical bone size as a result of the endosteal growth of the cortical bone [16]. These data suggest that tamoxifen might potentially reduce the incidence of premature fusion in endochondral ossification and reduce the cortical bone size in the jaw-healing processes after IVRO and Le Fort I osteotomy.

In women who have been through menopause, tamoxifen can help preserve bone strength, whereas in younger woman who have not reached menopause, tamoxifen causes a small amount of bone loss [17]. The effects of tamoxifen are one of clinical importance when we consider orthognathic surgery in breast cancer patients. In this case, there was no clinically reported delay of bone healing, but we consulted with her doctor and started tamoxifen 6 weeks after the orthognathic surgery. Mandible bone healing after IVRO could be associated with normal bone development, including not only cartilage and bone formation, but also endochondral resorption and bone remodeling. According to a previous *in vitro* study, chondrocytes are remodeled and bone remodeling is started 6 weeks after fracture [18,19]. The effect of the estrogen inhibitor tamoxifen should be further explored in clinical studies.

In response to the increased prevalence of orthognathic surgery in middle-age and older patients, it is expected that opportunities to encounter malignant tumor patients including patients with breast cancer will increase. In cases in which prognosis is sufficiently good to proceed, it is important to closely cooperate with the cancer surgeon and listen to the patient throughout the treatment process.

Conflict of interest

None.

Funding

None.

Ethical approval

None.

Consent

Informed consent was taken.

Author contributions

All authors have contributed equally in the treatment, data collection, data analysis or interpretation and writing this paper.

Guarantor

None.

References

- [1] M. Janson, G. Janson, E. Santana, R.C. de Castro, M.R. de Freitas, Orthodontic-surgical treatment of Class III malocclusion with extraction of an impacted canine and multi-segmented maxillary surgery, *Am. J. Orthod. Dentofac. Orthop.* 137 (2010) 840–849.
- [2] B. Lauby-Secretan, D. Loomis, K. Straif, Breast-cancer screening-viewpoint of the IARC Working Group, *N. Engl. J. Med.* 373 (2015) 1479.
- [3] K. Saika, T. Sobue, Epidemiology of breast cancer in Japan and the US, *Jpn. Med. Assoc. J.* 52 (2009) 39–44.
- [4] N. Harbeck, M. Gnant, Breast cancer, *Lancet* (2016), [http://dx.doi.org/10.1016/s0140-6736\(16\)31891-8](http://dx.doi.org/10.1016/s0140-6736(16)31891-8).
- [5] L.J. van't Veer, H. Dai, M.J. van de Vijver, Y.D. He, A.A. Hart, M. Mao, et al., Gene expression profiling predicts clinical outcome of breast cancer, *Nature* 415 (2002) 530–536.
- [6] R. Marsell, T.A. Einhorn, The biology of fracture healing, *Injury* 42 (2011) 551–555.
- [7] M. Almeida, S. Iyer, M. Martin-Millan, S.M. Bartell, L. Han, E. Ambrogini, et al., Estrogen receptor- α signaling in osteoblast progenitors stimulates cortical bone accrual, *J. Clin. Invest.* 123 (2013) 394–404.
- [8] J.P. Bezerra, A. de Siqueira, A.G. Pires, M.R. Marques, P.M. Duarte, M.F. Bastos, Effects of estrogen deficiency and/or caffeine intake on alveolar bone loss, density, and healing: a study in rats, *J. Periodontol.* 84 (2013) 839–849.
- [9] A.M. Marchini, C.P. Deco, K.B. Lodi, L. Marchini, A.M. Santo, R.F. Rocha, Influence of chronic alcoholism and oestrogen deficiency on the variation of stoichiometry of hydroxyapatite within alveolar bone crest of rats, *Arch. Oral Biol.* 57 (2012) 1385–1394.
- [10] S. Macari, L. Ajay Sharma, A. Wyatt, P. Knowles, R.E. Szawka, G.P. Garlet, et al., Osteoprotective effects of estrogen in the maxillary bone depend on ER α , *J. Dent. Res.* 95 (2016) 689–696.
- [11] H. Hatano, H.J. Siegel, H. Yamagiwa, J.T. Bronk, R.T. Turner, M.E. Bolander, et al., Identification of estrogen-regulated genes during fracture healing, using DNA microarray, *J. Bone Miner. Metab.* 22 (2004) 224–235.
- [12] M.M. Grumbach, Estrogen, bone, growth and sex: a sea change in conventional wisdom, *J. Pediatr. Endocrinol. Metab.* 13 (Suppl. (6)) (2000) 1439–1455.
- [13] E.A. Eugster, S.D. Rubin, E.O. Reiter, P. Plourde, H.C. Jou, O.H. Pescovitz, Tamoxifen treatment for precocious puberty in McCune-Albright syndrome: a multicenter trial, *J. Pediatr.* 143 (2003) 60–66.
- [14] J.M. Fitts, R.M. Klein, C.A. Powers, Comparison of tamoxifen and testosterone propionate in male rats: differential prevention of orchidectomy effects on sex organs, bone mass, growth, and the growth hormone-IGF-I axis, *J. Androl.* 25 (2004) 523–534.
- [15] A.S. Chagin, E. Karimian, F. Zaman, M. Takigawa, D. Chrysis, L. Savendahl, Tamoxifen induces permanent growth arrest through selective induction of apoptosis in growth plate chondrocytes in cultured rat metatarsal bones, *Bone* 40 (2007) 1415–1424.
- [16] E. Karimian, A.S. Chagin, J. Gjerde, T. Heino, E.A. Lien, C. Ohlsson, et al., Tamoxifen impairs both longitudinal and cortical bone growth in young male rats, *J. Bone Miner. Res.* 23 (2008) 1267–1277.
- [17] J.J. Body, Prevention and treatment of side-effects of systemic treatment: bone loss, *Ann. Oncol.* 21 (Suppl. (7)) (2010) vii180–vii185.
- [18] Y. Horikiri, T. Shimo, N. Kurio, T. Okui, K. Matsumoto, M. Iwamoto, et al., Sonic hedgehog regulates osteoblast function by focal adhesion kinase signaling in the process of fracture healing, *PLoS One* 8 (2013) e76785.
- [19] K. Matsumoto, T. Shimo, N. Kurio, T. Okui, K. Obata, M. Masui, et al., Expression and role of sonic hedgehog in the process of fracture healing with aging, *In Vivo* 30 (2016) 99–105.

Open Access

This article is published Open Access at sciedirect.com. It is distributed under the [IJSCR Supplemental terms and conditions](#), which permits unrestricted non commercial use, distribution, and reproduction in any medium, provided the original authors and source are credited.