

Clinical effectiveness of orthodontic treatment on smile esthetics: a systematic review

This article was published in the following Dove Press journal:
Clinical, Cosmetic and Investigational Dentistry

Terpsithea Christou¹
Anna Betlej¹
Najd Aswad¹
Dorothy Ogdon²
Chung How Kau¹

¹School of Dentistry, Department of Orthodontics, University of Alabama at Birmingham (UAB), Birmingham, AL, USA; ²School of Dentistry, University of Alabama at Birmingham (UAB), Birmingham, AL, USA

Objectives: The aim of this systematic review is to identify how different types of orthodontic interventions affect the esthetics of the smile, any time after orthodontic treatment.

Materials and methods: A systematic search of the literature was carried out using 5 electronic databases (PubMed, Embase, The Cochrane Library, Scopus, Dentistry and Oral Sciences Source) that included articles until October 2017. Randomized and non-randomized controlled clinical trials, case-control observational studies, and cohort and cross-sectional studies with validated data collection and/or follow-up periods reporting on orthodontic interventions that changed the smile any time after orthodontic treatment were part of the study protocol. Only studies that were published in the English language and those that had human patients of any age and gender who underwent orthodontic treatment were included.

Results: A total of 814 articles were found and 9 of them were included (7 cohort and 2 cross-sectional studies). Among the selected articles, 8 stated the type of orthodontic intervention used during treatment and 1 did not specify the intervention. Eight articles were judged of moderate risk and 1 had high risk of bias.

Conclusion: Orthodontic treatment affects the esthetics of the smile in three dimensions. There was slight evidence that extractions do not affect the smile width and buccal corridors area. Evidence on palatal expansion was controversial. The remaining existing data evidence that investigated smile esthetics after orthodontic treatment was uncertain. Therefore, more validated, evidence-based studies are needed.

Keywords: smile esthetics, smile design, orthodontics, biomechanics, interventions

Introduction

Improving the appearance of the smile is one of the main reasons patients seek orthodontic treatment. Understanding the components of an esthetically attractive smile is essential to achieving patient satisfaction as well as successful treatment results. In the 20th century, Edward Angle addressed this problem through an emphasis on achieving optimal occlusion, which was thought to coincide with appealing smile esthetics.¹ This approach remains a central idea in orthodontics, and orthodontists and other dental practitioners have focused research efforts on developing and providing guidelines for achieving optimal occlusion through orthodontic treatment. In the past, diagnosis was based on cephalometric analysis combined with photographs of a patient's profile. Analysis and intentional design of the smile were generally underemphasized during treatment planning. As the field and available technologies have continued to evolve, a gradual shift toward an increased emphasis on dental esthetics in treatment planning has occurred, and now

Correspondence: Terpsithea Christou
School of Dentistry, Department of
Orthodontics, University of Alabama at
Birmingham (UAB), 1919 7th Avenue
South SDB 305, Birmingham, AL 35294,
USA
Tel +1 205 934 4547
Fax +1 205 975 7580
Email tetich@uab.edu

an esthetically pleasing smile is a key desired outcome of orthodontic treatment. Moore et al² noted that the specific components of the smile that are valued for esthetics have changed in the last 50 years. Correctly identifying the factors that contribute to the creation of an esthetically pleasing smile by contemporary standards is critical to supporting professionals who aim to include intentional smile design in orthodontic treatment planning. The orthodontic and dental literature include a range of information on both soft and hard tissue structures that are components of an esthetic smile. In this article, we have categorized information from previous literature searches in three major divisions of the balanced smile. These divisions are the lip line, smile line, and dental components. The first division we describe is the lip line. This includes lip thickness, upper lip length, height of smile (overall or posteriorly), gingival display at smiling, inter-labial gap, and upper lip curvature/shape. The second division we describe, the smile line, includes smile arc, buccal corridors, cant of occlusal plane, upper incisor inclination, last posterior tooth visible, smile width/index ratio, smile symmetry, vertical maxillary height, and facial/dental midline. The third division includes micro-esthetics of dental components of the smile, upper incisor ratio/size/symmetry, upper incisor inclination, upper incisor angulation, upper incisor vertical position, tooth color, and incisal embrasures.³⁻⁸ To date, not many studies in the literature have been systematically reviewed in such a manner.

The aim of this systematic review was to identify studies that report the biomechanical effects of orthodontic treatment on the esthetics of the smile and determine how the smile is affected in the three planes of space: vertical, transverse, and sagittal.

Materials and methods

This carefully designed systematic review was created and the results reported according to guidance provided by the Preferred Reporting Items for Systematic Reviews and Meta-Analysis (PRISMA) guidelines and the *Cochrane Handbook for Systematic Reviews of Interventions*.⁹⁻¹² The protocol and research question of this narrative review was created based on the Problem, Intervention, Comparison, Outcome (PICO) format.¹³

The eligibility criteria for study inclusion were pre-determined and are summarized in Table 1. A study was considered eligible when it reported the outcomes of at least one orthodontic intervention known to affect the appearance of the smile or at least one treatment

Table 1 Summarized criteria that were applied for this current review

Inclusion criteria	Exclusion criteria
Randomized and non-randomized clinical trials studying the effect of orthodontic treatment on smile esthetics Studies written in English	Patients with craniofacial discrepancies, cleft lip and/or palate, or any syndrome affecting the face Orthognathic cases or Invisalign cases
Patients who underwent orthodontic treatment with any type of orthodontic appliance or orthodontic treatment method Observational studies	Studies investigating perception of laypeople or specialists about smile esthetics Studies investigating smile esthetics from the lateral aspect rather than the frontal aspect Editorials Letters Case reports

component known to contribute to the creation of a balanced smile. Our aim in writing this review was to gather information on smile design related to orthodontic treatment only. Because the focus of our question was solely outcomes following orthodontic treatment alone, studies that reported data concerning treatment strategies that included implants or treatment systems that are not considered conventional orthodontic methods (such as the Invisalign system) were not included. Studies that included data on outcomes of orthognathic surgery were also excluded because orthognathic surgery in conjunction with orthodontic treatment may alter smile outcomes in ways that are not similar to the effects on smile appearance following orthodontic treatment alone.

Studies to be considered for review were identified by thorough searches of electronic databases as well as hand-searching reference lists and consultations with experts in the field of orthodontics. Our group developed a search strategy for use in PubMed that was adapted for use in Embase, The Cochrane Library, Scopus, and Dentistry and Oral Sciences Source. The initial search was developed in June 2017, and the final search update for this project in each selected database was carried out on October 9th, 2017. The searches were not limited by date. The search strategies used in PubMed are reported in Table 2. The initial development of search strategies and database selection for this review were completed in collaboration with Dorothy Ogdon, Assistant Professor and Reference Librarian. Once database searching was complete,

Table 2 Search strategies from selected databases

Database	Key words	Search strategy	Result with duplicates	Result without duplicates
PubMed	1) "Smiling"[Mesh] OR "Orthodontics"[Mesh]; 2) smile AND orthodontic AND esthetic; 3) Randomized Controlled Trial OR RCT OR Clinical Trial OR clinical trial OR Review; 4) smile AND orthodontic AND aesthetic; 5) smile AND orthodontic AND improvement; 6) smile AND orthodontic AND enhancement; 7) smile AND orthodontic AND attractive.	A- 1 and 2 and 3. B- 1 and 4 and 3. C- 1 and 5 and 3. D- 1 and 6 and 3. E- 1 and 7 and 3.	97	69
Embase	1) smile; 2) orthodontics; 3) aesthetic; 4) esthetic; 5) improvement; 6) enhancement; 7) attractive.	A- 1 and 2 and 3. B- 1 and 2 and 4. C- 1 and 2 and 5. D- 1 and 2 and 6. E- 1 and 2 and 7.	391	144
The Cochrane Library	1) smile; 2) orthodontics; 3) esthetic; 4) aesthetic; 5) improvement; 6) enhancement; 7) attractive.	A- 1 and 2 and 3. B- 1 and 2 and 4. C- 1 and 2 and 5. D- 1 and 2 and 6. E- 1 and 2 and 7.	50	32
Scopus	1) smile AND orthodontics AND esthetic; 2) clinical trial OR randomized trial OR randomized controlled trial; 3) smile AND orthodontics AND aesthetic; 4) smile AND orthodontics AND improvement; 5) smile AND orthodontics AND enhancement; 6) smile AND orthodontics AND attractive.	A- 1 and 2. B- 3 and 2. C- 4 and 2. D- 5 and 2. E- 6 and 2.	272	96
Dentistry and Oral Sciences Source	1) orthodontics; 2) smile; 3) orthodontic; 4) esthetic; 5) randomized controlled trial OR clinical trial; 6) aesthetic; 7) improvement; 8) enhancement; 9) attractive.	A- 1 and 2 and 3 and 4 and 5. B- 1 and 2 and 3 and 6 and 5. C- 1 and 2 and 3 and 7 and 5. D- 1 and 2 and 3 and 8 and 5. E- 1 and 2 and 3 and 9 and 5.	4	2

deduplication was carried out using tools available through EndNote citation management software. Following deduplication, three investigators independently evaluated the titles and abstracts of retrieved studies for relevance based on the eligibility criteria reported in Table 1. Following title and abstract screening, the remaining articles were further reviewed for relevance to the research topic. Any disagreements on whether a study met the inclusion criteria were resolved by discussion amongst all three investigators.

To facilitate detailed investigation of the effects of orthodontic treatment on smile esthetics, data for different types of orthodontic interventions (eg, extractions, self-ligating brackets, rapid palatal expander, biteplane, intrusion arch) were categorized according to the primary focus of correction. The categories included as possible options for the primary focus of correction are: vertical correction (eg, with a biteplane or intrusion arch), transverse correction (eg, with a rapid palatal expander), or sagittal correction (eg, with extractions). Changes in the smile as the primary outcome following orthodontic treatment were based on measurement results on variables that constitute a balanced smile. The variables included in this article were summarized according to smile line, lip line, and micro-esthetics (Table 4).

To facilitate efficient collection of data on both types of orthodontic interventions, the primary focus of correction, and measurement results, original data extraction and collection forms were developed and used by two reviewers to independently collect data from each study selected for inclusion. Two reviewers extracted and recorded data from studies selected for inclusion; the third reviewer checked information reported on the data extraction forms and refined reported information as needed.

The first form was used to collect the following information: 1) author and year of publication; 2) study design; 3) participants (sample size, ages before treatment, sex); 4) intervention; 5) method (tools used for data acquisition); 6) author's conclusion; and 7) risk of bias. The second form was used to collect information on esthetic elements of the smile, including: 1) author and year of publication; 2) orthodontic treatment; and 3) parameters, divided into the subsections a) smile line parameters (1, buccal corridors; 2, smile arc; 3, occlusal cant; 4, smile width/index; 5, last tooth visible; 6, maxillary height; 7, smile symmetry; 8, facial/dental midline), b) lip line parameters (1, upper lip length/thickness; 2, height of smile; 3, gingival/incisor display; 4, interlabial gap; 5, lip curve/shape), and c) micro-esthetic parameters of the smile (1, upper incisor ratio; 2, incisor

inclination; 3, incisor angulation; 4, incisor vertical position; 5, tooth color; 6, incisal embrasures). Examples of the forms are provided in Tables 3 and 4. In the case of unreported or unclear information referring to the included studies, the authors were contacted via email for clarification. To assess the quality of the studies selected for inclusion, the authors reviewed each selected study independently, and any disagreements were resolved through group consensus. There are many validated methods available in the literature that can be used to assess the overall quality and risk of bias in individual studies.^{10,11} For the purposes of this review, if randomized controlled trials were identified for inclusion, the Cochrane Collaboration's risk of bias tool was used to assess risk of bias;¹⁰ the Newcastle-Ottawa scale was used¹¹ to assess the risk of bias in non-randomized studies. The Newcastle-Ottawa scale was designed to be used to assess risk of bias in case-control and cohort studies and includes criteria referring to the selection, comparability, and exposures of the study or criteria referring to the selection, comparability, and outcome measures, respectively. For the cross-sectional studies, a modified version of this scale was used to assess risk of bias. Regardless of which scale was used to evaluate a study, the criteria for rating the bias of publication were organized into 8 parameters. A star system was used to assign a rating; each parameter was awarded 1 star or a maximum 2 stars for comparability questions. Studies that received 8, 7, or 6 stars using this rating system were considered to have moderate risk of bias, whereas studies that received 5 or fewer stars were considered to have a high risk of bias. Studies that received the maximum allowed amount of 9 stars were considered to have a low risk of bias.

Due to a wide variability in reported outcomes across studies selected for inclusion the information from selected studies could not be compared statistically, and the group was not able to perform a meta-analysis.

Results

Study characteristics

After the initial search, 814 articles were retrieved. Further searches returned 343 articles after duplicate articles were removed. An additional 8 articles were identified by contacting authors for relevant studies and by handsearching. Titles and abstracts were reviewed for 351 articles and 17 articles were retrieved for full text assessment. After detailed assessment of the quality, 8 articles complied with the eligibility criteria and therefore were included for final study in this review.²¹⁻¹⁸ Figure 1 shows a flow

Table 3 Characteristics of included studies

Author (year)	Study design	Participants	Intervention	Method	Authors' conclusion	Risk of bias
Alkhalcin et al (2017) ¹⁴	Cohort	53 subjects (19 males, 34 females); 28 extraction, 25 non-extraction	Extractions	At T1=pre treatment, T2=4 years+2 months, T3=17 years+8 months, study model analysis; smile analysis on digital pictures	1. Premolar extractions did not have any adverse effects on the transverse dimension of the maxillary dentition 2. Buccal corridor ratios were not negatively affected by extraction treatment as compared to non-extraction treatment 3. Long-term changes in buccal corridor ratios were comparable in both groups Post-treatment arch width increase is likely to be seen in patients treated by either conventional or Damon self-ligating brackets. It is highly unlikely that there is any significant difference in buccal corridor width between patients treated with either system	Moderate
Shook et al (2016) ¹⁵	Cohort	84 patients: - Conventional brackets N=45, (male 22, female 23); - Damon self-ligating N=39, (male 19, female 20); mean age=15.13 years	Self-ligating brackets	At T1=pre treatment and T2=post treatment. Treatment time duration: self-ligating: mean=21.8–23.95 months and conventional: mean=22.85–26.43 months; photographs and digital model measurements; pre-treatment cephalograms were digitized to determine the vertical facial pattern		Moderate
Mah et al (2013) ¹⁶	Cohort	46 subjects (18 males, 28 females); mean age 16.6±4.2 years; Class II Division I	Extractions	Cephalograms; digital study models pre and post orthodontic treatment	1. The change in the curvature of the smiling was found to be related more significantly to the magnitude of difference in the inclination between the pre-treatment anterior occlusal plane and the functional occlusal plane than to the change in the inclination of the maxillary incisors 2. The change in the maxillary intercanine width did not influence the curvature significantly RME was beneficial for the smile esthetics and resulted in an increase of the transverse smile dimension and exposure of maxillary central and lateral incisors. However, lip thickness and buccal corridors remained unchanged Golden proportions were improved after orthodontic treatment There was a significant difference between the post-treatment micro-esthetic values between non-extraction and extraction groups. The non-extraction group was found to be closer to these proposed norms	Moderate
Carvalho et al (2012) ¹⁷	Cohort	27 subjects (15 females, 12 males); mean age 10 years+3 months	RME palatal expander	81 extraoral photographs of maximum smile before expansion and 3–6 months after fixation of the expanding screw		Moderate
Tauheed et al (2012) ¹⁸	Cohort	57 subjects (45 males, 12 females); 31 non-extraction, 26 extraction; age 12–30 years	Extractions	Study model analysis; digital pictures analysis pre and post orthodontic treatment		High

(Continued)

Table 3 (Continued).

Author (year)	Study design	Participants	Intervention	Method	Authors' conclusion	Risk of bias
Yang et al (2008) ¹⁹	Cross-sectional	92 subjects (19 males, 73 females); 36 non-extraction, 56 extraction	Extractions	Cephalometric analysis; study models analysis; digital pictures analysis	Extraction and non-extraction treatment did not affect the buccal corridor area	Moderate
Maulik and Nanda (2007) ²⁰	Cross-sectional	230 subjects; 73 non-orthodontic treatment (tx); 70 orthodontic tx with RME; 87 orthodontic tx without RME; age 14–35 years	RME palatal expansion	Videos taken while smiling	1. The orthodontically treated group demonstrated significantly more parallel smile arcs compared with the untreated group 2. The RME group showed significantly less buccal corridor on smiling 3. The RME group had significantly fewer posterior maxillary teeth visible on smile compared to the non-expanded group 4. The coincidence of high posterior smile height and reverse smile arc is statistically significant	Moderate
Lindauer et al (2005) ²¹	Cohort	20 subjects: -10 intrusion arch -10 bite plate	Bite plate and intrusion arch	Cephalometric analysis; study models analysis; pictures analysis at T1=pre treatment and T2=post overbite procedure correction: Bite plate mean duration=3.7±1.2 months and intrusion arch duration =4.6±1.5 months	About half of the patients in both the intrusion arch and the bite plate groups experienced flattening of the smile arc during the overbite correction phase of treatment	Moderate

Table 4

Author (year)	Orthodontic treatment	Smile line parameter					Maxillary height
		Buccal corridors	Smile arc	Occlusal cant	Smile width/index	Last tooth visible	
Akyalcin et al (2017) ¹⁴	X	X			X		
Shook et al (2016) ¹⁵	X	X			X		
Mah et al (2013) ¹⁶	X		X				
Carvalho et al (2012) ¹⁷	X	X	X		X		
Tauheed et al (2012) ¹⁸	X						
Yang et al (2008) ¹⁹	X	X					
Maulik and Nanda (2007) ²⁰	X	X	X		X		
Lindauer et al (2005) ²¹	X	X	X				
Author (year)	Orthodontic treatment	Smile symmetry			Facial/dental midline		
Akyalcin et al (2017) ¹⁴	X						
Shook et al (2016) ¹⁵	X						
Mah et al (2013) ¹⁶	X						
Carvalho et al (2012) ¹⁷	X						
Tauheed et al (2012) ¹⁸	X						
Yang et al (2008) ¹⁹	X						
Maulik and Nanda (2007) ²⁰	X						
Lindauer et al (2005) ²¹	X						
Author (year)	Orthodontic treatment	Lip line parameter					Lip curve/shape
		Upper lip length/thickness	Height of smile	Gingival/incisor display	Interlabial gap	Vertical maxillary height	
Akyalcin et al (2017) ¹⁴	X						
Shook et al (2016) ¹⁵	X						
Mah et al (2013) ¹⁶	X						
Carvalho et al (2012) ¹⁷	X	X		X			
Tauheed et al (2012) ¹⁸	X						
Yang et al (2008) ¹⁹	X						
Maulik and Nanda (2007) ²⁰	X						
Lindauer et al (2005) ²¹	X						
Author (year)	Orthodontic treatment	Micro-esthetic parameter of smile					Incisal embrasures
		Upper incisor ratio	Incisor inclination	Incisor angulation	Incisor vertical position	Tooth color	
Akyalcin et al (2017) ¹⁴	X						
Shook et al (2016) ¹⁵	X						
Mah et al (2013) ¹⁶	X						
Carvalho et al (2012) ¹⁷	X						
Tauheed et al (2012) ¹⁸	X	X					
Yang et al (2008) ¹⁹	X						
Maulik and Nanda (2007) ²⁰	X						
Lindauer et al (2005) ²¹	X				X		

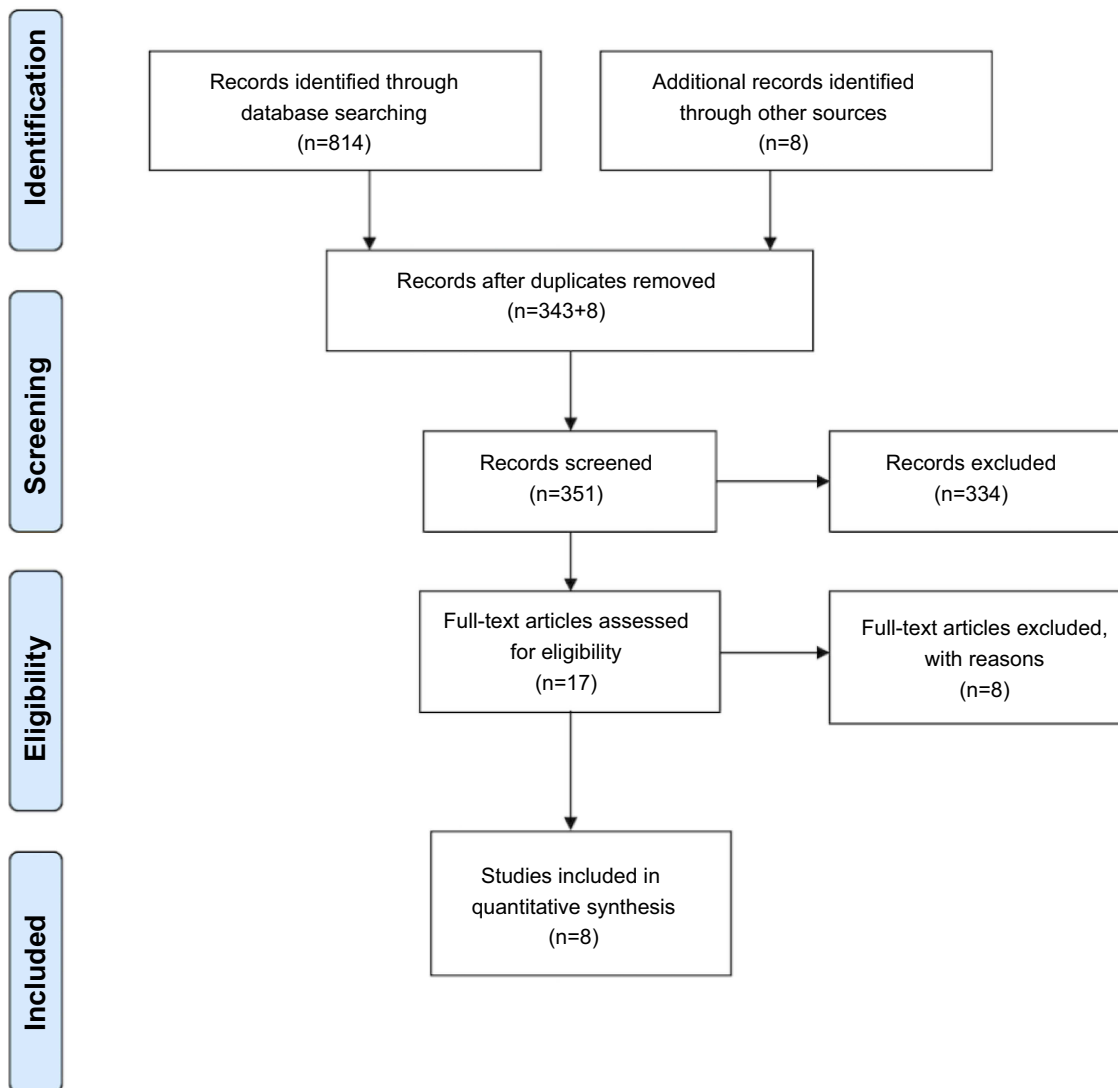


Figure 1 Preferred Reporting Items for Systematic Reviews and Meta-Analysis (PRISMA) flow diagram showing a graphical representation of the flow of citations reviewed in the course of this current review.

Note: Moher D, Liberati A, Tetzlaff J, Altman DG, The PRISMA Group (2009) Preferred Reporting Items for Systematic Reviews and Meta-Analyses: The PRISMA Statement. *PLoS Med* 6(7): e1000097. 2009 Moher et al. This is an open-access article distributed under the terms of the Creative Commons Attribution License. 37

chart of this study, according to the PRISMA statement, with the number of articles found at the initial retrieval, screening, and final selection for this review. Tables 3 and 4 summarize the characteristics of the included studies. No randomized controlled trials or case-control studies were found to be eligible for this review. The study designs for 8 publications that met the inclusion criteria were 2 cross-sectional studies and 6 cohort studies. After evaluation of the quality of the studies, 8 of the studies were judged to have moderate risk of bias and 1 was judged to have high risk of bias. None of the studies were considered to have low risk of bias. Most of the studies failed to show follow-up outcomes or failed to adequately explain the analysis of

their study design when compared to study controls for the factor that was being investigated. All studies in this review used orthodontics and assessed how the mechanics of orthodontic intervention influenced the appearance of the smile and its parameters. All 8 studies described the treatment protocol and orthodontic intervention.

Outcomes

The study parameters for the systematic review are present in three broad categories: vertical, transverse, or sagittal foci of correction representing changes to the smile in the respective dimensions of space.

The studies selected for inclusion in this review are summarized as follows:

1. One article described an orthodontic treatment to correct a vertical problem.
2. Five articles described correction of a transverse discrepancy.
3. Two articles addressed sagittal problems.
4. Five studies that described the correction of a transverse discrepancy reported outcomes on the use of rapid palatal expanders, self-ligating brackets, and extractions.
5. Finally, two studies that described corrections of sagittal problems reported outcomes on the use of extractions to correct Class II malocclusion or crowding.

Smile esthetics after orthodontic intervention with primary focus on correcting vertical orthodontic problems

Lindauer et al²¹ investigated how intrusion arch vs bite plate can correct a deep overbite and explained the different mechanics that there are used in each case. They found that both accomplish satisfying correction of the overbite, but both are likely to cause some degree of flattening of the smile arc during treatment. The intrusion arch, however, will decrease the maxillary incisor exposure due to the intruding mechanism and can lead to significant flattening of the smile arc. The authors suggested that the flat smile arc could be corrected to some degree using flat continuous arch wires in the later stages of orthodontic treatment. This action will bring the maxillary incisors closer to their initial vertical position and therefore create a more parallel smile arc.

Smile esthetics after orthodontic intervention with primary focus on correcting transverse orthodontic problems

In this group, 2 studies assessed how the smile changes after rapid maxillary expansion (RME). Maulik and Nanda²⁰ evaluated the smile of 230 subjects divided into 3 groups: a) non-treated; b) orthodontically treated without RME; and c) orthodontically treated with RME. It was found that the orthodontically treated group appeared to have more parallel smile arcs with the lower lip, compared to the untreated group. The authors also showed that rapid palatal expansion decreases the exposure of buccal corridors after treatment.

On the contrary, Carvalho et al¹⁷ showed that buccal corridors remain unchanged after rapid palatal expansion. The authors evaluated 27 patients in 3 different time frames: T1, before expansion; T2, 3 months after expansion; and T3, 6 months after expansion. Buccal corridors were shown to decrease on the right side and remain unchanged on the left side. In the conclusion it was claimed that buccal corridors did not show any clinically significant difference before and after treatment. They stated that rapid palatal expansion does not affect buccal corridors when compared before and after orthodontic expansion.

Another study in this category¹⁵ evaluated how self-ligating brackets affect the smile and its parameters compared to conventional brackets. The results showed that there is not significant difference for the smile esthetic outcome whether Damon self-ligating or conventional brackets are used. Both increase the arch width and decrease buccal corridors. The authors concluded that it is highly unlikely to have any significant difference in buccal corridor widths between patients treated with Damon self-ligating or conventional brackets.

Akyalcin et al³⁸ compared long term changes (up to 17 years) between extraction vs non-extraction groups before and after orthodontic treatment. This study included 53 patients, 28 had premolar extractions and 25 had non-extraction treatment. The authors concluded that extractions do not affect the transverse maxillary arch width or the buccal corridors. Furthermore, long term results (at 4 and 17 years post treatment) showed similar outcomes between the 2 study groups. Another study by Yang et al¹⁹ evaluated differences of buccal corridor areas in extraction vs non-extraction orthodontic treatment. The authors referenced literature that suggests buccal corridors are controlled by the vertical skeletal pattern of the face, the amount of upper incisor exposure, and the sum of the tooth material. The results supported the fact that the more hyper-divergent vertical skeletal pattern present in a patient, the less buccal corridor exposure was present. In addition, the narrower the inter-molar distance, the larger buccal corridors. Finally, there was no statistically significant correlation between extractions and buccal corridors area exposure.

Smile esthetics after orthodontic intervention with primary focus on correcting sagittal orthodontic problems

Mah et al¹⁶ investigated how orthodontic correction of 46 Class II Division I cases who were treated with maxillary first premolar extractions will affect the patients' smile arc in regard to the lower lip. The authors examined their

results based on differences in the occlusal plane, maxillary incisor inclination, and inter-canine distance, before and after treatment. This study showed that extraction of upper premolars to correct a maxillary sagittal discrepancy results in deepening of smile line curvature. This occurs due to clockwise rotation of the anterior occlusal plane and reduction of proclination of maxillary incisors. However, the authors did not find any clinically significant difference of the smile arc due to an increase of the inter-canine distance during Class II Division I correction.

In another study, Tauheed et al¹⁸ evaluated a total of 53 patients and attempted to assess whether the ratio of the teeth affects smile attractiveness. They concluded that it was very challenging to achieve ideal teeth ratios in every case and that orthodontic treatment improves micro-esthetics such as maxillary central incisor crown width–height ratio, connectors between maxillary anterior sextant, gingival zenith level of the maxillary lateral incisor, and golden percentage²² of the anterior teeth, regardless of whether extractions were performed or not. However, these micro-esthetic parameters showed greater deviation from the golden proportion ratio values in extraction cases compared to non-extraction ones.

Discussion

This review aimed to identify studies that report the effects of orthodontic treatment alone on the esthetics of the smile at any time following the completion of therapy and determine which components of smile attractiveness have been systematically evaluated in previous clinical studies.

This current review highlights the fact that different orthodontic interventions appear to correlate significantly with the smile esthetic result. Orthodontic treatment may influence one or more parameters that affect smile esthetics. Extraction biomechanics seem to be of the most important concern for researchers regarding their influence on smile esthetics.^{38–18} Palatal expanders also have been connected to have an effect on the smile,^{20,17} followed by self-ligating brackets¹⁵ and intrusion devices.²¹

Even though similar studies have been done, these have been from information on smile esthetics from the layperson's point of view.^{23,24} A study by Akyalcin et al¹⁴ used a sample size of 462 patients who were, according to ABO clinical examination, successfully treated. Subjects were rated by 30 panel members for their smile attractiveness. The results showed a harmonious smile arc and less gingival display to be key factors for an attractive smile. A similar study used records of 48 orthodontically treated patients. Twenty-five orthodontists and 20 laypeople were

asked to rate patients' smiles.²⁵ The result showed either very weak relationships or no correlation between the ABO Objective Grading System factors and smile esthetics.

There have also been proposals^{38,19} that extraction treatment have no effect on the smile width and buccal corridors. In addition, Yang et al¹⁹ suggested that the initial facial pattern, maxillary inter-molar distance, and sum of teeth material are the factors that will determine the buccal corridor exposure, not the extraction component. It is worth underlying that the authors of these 2 studies used different definitions of buccal corridors. In the first study, buccal corridors refer to the linear definition of the term which is described as the space between the corners of the lips at smiling and the last visible posterior teeth. In the second study, buccal corridors are defined as the area distal to the lateral incisors up to the corners of the mouth. A meta-analysis²⁶ that was published in 2015 investigating the effectiveness of tooth extraction and non-extraction treatment on smile esthetics could not conclude that an extraction treatment will affect the esthetics of the smile. Therefore, their conclusions are in agreement with our findings in this review. In addition, Meyer et al²⁷ conducted a retrospective study and evaluated arch width and buccal corridor changes before and after orthodontic treatment. The final sample size in that study consisted of 57 patients (30 had 4 premolar extractions and 27 had no premolar extractions). Among other intra-oral measurements (inter-canine and inter-molar maxillary distance), Meyer et al also measured buccal corridors between the extraction and non-extraction groups. They did not find any significant differences before and after orthodontic treatment for these two groups. These results are in agreement with Akyalcin et al's³⁸ and Yang et al's¹⁹ studies as well.

Tauheed et al¹⁸ focused on the proportions of the smile and found that teeth ratios after extraction treatment of maxillary premolars will deviate more from the golden proportion ratios than in non-extraction cases. Hence, to them, it is of great importance to preserve the micro-esthetics in the finishing stages when extraction mechanics are used in orthodontic treatment. Mah et al,¹⁶ on the other hand, focused on the smile arc changes after maxillary premolar extractions. According to Sarver,³ a harmonious smile should have the smiling line curvature created by the incisal edges of the upper teeth or else the smile arc to be parallel with the lower lip. Mah et al highlighted the fact that the smile arc can be affected by three factors: the difference between the inclination of the anterior occlusal plane and functional occlusal plane, the maxillary incisor

inclination, and the inter-canine width. According to the results of his Class II Division I study group, the smile arc is expected to increase after space closure in maxillary premolar extraction cases. According to this study, it is important that cephalometric data are incorporated in the treatment plan to improve or maintain the curvature of the smile arc. Mah et al's findings are referring to the increase of the smile arc after clockwise rotation of the anterior occlusal plane, in accordance with previous studies by Ackerman and Ackerman⁸ and by Lombardi.^{28,29} Several authors have mentioned that the effect of maxillary incisor inclination is in regard to the smile arc.^{8,28,29} Their studies show that over-proclination of the maxillary incisors will have a negative effect on the smile esthetic due to flattening of the smile arc. This concept is found to be in agreement with Mah et al's study. On the contrary, Mah et al did not find a significant change of the smile arc due to an increase of the inter-canine distance, whereas Sarver and Ackerman³⁰ suggested that the smile arc is also expected to flatten after an increase of the inter-canine distance.

Maulik and Nanda²⁰ studied the connection between expansion of the upper arch using a palatal expander and buccal corridor/smile esthetics. The authors used the percentage of represented buccal corridors in the total smile width as an indicator of a narrow smile. This description was initially introduced by Moore et al in their article "Buccal corridors and smile esthetics"² In this study, Moore et al defined ranges of buccal corridors as follows: 28% of buccal corridors would represent a medium-narrow smile, 15% a narrow smile, 10% a medium-broad smile, and 2% a broad smile fullness. Maulik and Nanda found buccal corridor results to be significantly different between the expanded (9.6%) and non-expanded (11%) groups. The group that underwent orthodontic treatment with a palatal expander showed significantly less buccal corridors on smiling. Carvalho et al¹⁷ also tested how palatal expanders affect the smile esthetics. The authors found that expanders seemed to increase the smile width and exposure of the maxillary central and lateral incisors but lip thickness remain unchanged. These researchers did not find a statistically significant decrease for buccal corridors. They used the linear definition of buccal corridor for their measurements. Results for the buccal corridors in the last 2 studies contradict each other. Comparing these two studies, Maulik and Nanda's study was a cross-sectional study with a sample size of 230 subjects and used videos to evaluate their results. The age of the participants was between 14 and 35 years. On the other hand,

Carvalho et al's study was a cohort. They used a smaller sample size of 27 people but evaluated results in three different time frames: T1, before expansion; T2, 3 months after expansion; and T3, 6 months after expansion. The mean age of this group was 10 years and 3 months. In addition, only for this study do we have information on the patient's initial severity of the transverse dimension. All patients included in Carvalho et al's study presented with initial unilateral or bilateral cross-bite. As we can notice, these 2 studies used different research design and inclusion criteria, and this is one of the limitations when it comes to comparing their results. Therefore, it is of great importance that more studies become available and more evidence exists in relation to the effect of the palatal expander on the smile and more specifically on buccal corridors. A systematic review published in 2011 evaluated the buccal corridors and smile. Two articles concluded no correlation between buccal corridors and smile attractiveness. Eight articles concluded that less attractive smiles will result from large buccal corridors.³¹

Further investigation into the effect of intrusion devices on the smile and its parameters is required. In this study, only 1 study was found to qualify for this review. Both the intrusion arch and bite plane cause some degree of flattening of the smile arc, with the first leading to more severe results due to the possible significant intrusion of the maxillary incisors as a consequence of the biomechanical effect of the intrusion arch.²¹ Due to lack of information from other studies it is difficult to have a clear judgment regarding the exact side effects on the smile of intrusion arch, bite plate, and a variety of other intrusion devices that are used in orthodontics on a daily basis. Studies^{3,8,32} agree that maxillary incisor intrusion might possibly cause flattening on the smile arc with negative effect on the final orthodontic outcome. Therefore, these devices seem to have a significant impact on smile and further studies are needed to provide evidence-based data.

Finally, the analysis of the use of different bracket systems on smile esthetics found only 1 eligible study. Following the introduction of self-ligating brackets, supporters of this system claimed that improved smile esthetics can be achieved. Furthermore, statements have been made that self-ligating brackets can increase the smile width and decrease the buccal corridors and produce fuller, broader smiles. This concept was not proven because the authors¹⁵ tested the hypothesis of whether the Damon self-ligating bracket system had a different effect on buccal corridors compared to traditional brackets

after orthodontic treatment. The results showed no difference between the two systems. Both systems increase the smile width and decrease the buccal corridor area. A systematic review by Chen et al³³ compared the effectiveness, efficiency, and stability of treatment with self-ligating brackets vs conventional brackets. Out of the 16 included studies, 3 mentioned that a Damon self-ligating bracket system produces increased inter-molar width after treatment compared to conventional brackets.^{34,36} These studies did not analyze whether the increased inter-molar width showed further effect on any of the smile parameters.

Conclusion

The findings from this systematic review are the following:

1. Whether certain types of orthodontic appliance systems had a positive or negative impact on the smile arch was inconclusive.
2. Intrusion arches and flat bite planes could flatten the smile.
3. There was slight evidence that extractions do not to affect the smile width and buccal corridors.
4. In addition, evidence on palatal expansion is controversial about whether smile esthetics are compromised.

However, due to heterogeneity of the research design, the clinical relevance of the included studies, and the lack of adequate comparable studies, the applications of the current study's results should be considered with caution. On the basis of this study, there is a need for more evidence-based research in the area of smile esthetics and orthodontic treatment.

Disclosure

The authors report no conflicts of interest in this work.

References

1. Mattick CR, Gordon PH, Gillgrass TJ. Smile aesthetics and malocclusion in UK teenage magazines assessed using the Index of Orthodontic Treatment Need (IOTN). *Br Dent J*. 2004;197:245. doi:10.1038/sj.bdj.4811614
2. Moore T, Southard KA, Casco JS, Qian F, Southard TE. Buccal corridors and smile esthetics. *Am J Orthod Dentofacial Orthop*. 2005;127:208–213 quiz 261. doi:10.1016/j.ajodo.2003.11.027.
3. Sarver DM. The importance of the incisor positioning in the esthetic smile: the smile arc. *Am J Orthod Dentofacial Orthop*. 2001;120:98–111. doi:10.1067/mod.2001.114301
4. Sabri R. The eight components of a balanced smile. *J Clin Orthod*. 2005;39:155–167.quiz 154.
5. Machado AW. 10 commandments of smile esthetics. *Dental Press J Orthod*. 2014;19:136–157.
6. Sharma PK, Sharma P. Dental smile esthetics: the assessment and creation of the ideal smile. *Semin Orthod*. 2012;18:193–201. doi:10.1053/j.sodo.2012.04.004
7. Seixas MR, Costa-Pinto RA, de Araújo TM. Checklist of aesthetic features to consider in diagnosing and treating excessive gingival display (gummy smile). *Dental Press J Orthod*. 2011;16(2):131–157. doi:10.1590/S2176-94512011000200016
8. Ackerman MB, Ackerman JL. Smile analysis and design in the digital era. *J Clin Orthod*. 2002;36:221–236.
9. Sanderson S, Tatt ID, Higgins JP. Tools for assessing quality and susceptibility to bias in observational studies in epidemiology: a systematic review and annotated bibliography. *Int J Epidemiol*. 2007;36:666–676. doi:10.1093/ije/dym018
10. Higgins JPT, Altman DG, Sterne JAC. The cochrane collaboration's tool for assessing risk of bias in randomized trials. *BMJ*. 2011;343:d5928. doi:10.1136/bmj.d5928
11. Moher D, Liberati A, Tetzlaff J, Altman DG, Group P. Preferred reporting items for systematic reviews and meta-analyses: the PRISMA statement. *J Clin Epidemiol*. 2009;62:1006–1012. doi:10.1016/j.jclinepi.2009.06.005
12. Moher D, Jadad AR, Tugwell P. Assessing the quality of randomized controlled trials. Current issues and future directions. *Int J Technol Assess Health Care*. 1996;12:195–208.
13. Da Costa Santos CM, De Mattos Pimenta CA, Nobre MRC. The PICO strategy for the research question construction and evidence search. *Rev Latino-Am Enfermagem*. 2007;15(3):508–511. doi:10.1590/S0104-11692007000300023
14. Akyalcin S, Frels LK, English JD, Laman S. Analysis of smile esthetics in American Board of Orthodontic patients. *Angle Orthod*. 2014;84:486–491. doi:10.2319/072813-562.1
15. Shook C, Kim SM, Burnheimer J. Maxillary arch width and buccal corridor changes with Damon and conventional brackets: A retrospective analysis. *Angle Orthod*. 2016;86:655–660. doi:10.2319/050515-304.1
16. Mah M, Tan WC, Ong SH, Chan YH, Foong K. Three-dimensional analysis of the change in the curvature of the smiling line following orthodontic treatment in incisor class II division 1 malocclusion. *Eur J Orthod*. 2013;36(6):657–664.
17. Carvalho APMC, Goldenberg FC, Angelieri F, Siqueira DF, Bommarito S, Scanavini MA. Assessment of changes in smile after rapid maxillary expansion. *Dental Press J Orthod*. 2012;17:94–101. doi:10.1590/S2176-94512012000500014
18. Tauheed S, Shaikh A, Fida M. Microesthetics of The Smile: Extraction vs. Non-extraction. *J Coll Physicians Surg Pak*. 2012;22(4):230–234.
19. Yang IH, Nahm DS, Baek SH. Which hard and soft tissue factors relate with the amount of buccal corridor space during smiling? *Angle Orthod*. 2008;78:5–11. doi:10.2319/120906-502.1
20. Maulik C, Nanda R. Dynamic smile analysis in young adults. *Am J Orthod Dentofacial Orthop*. 2007;132:307–315. doi:10.1016/j.ajodo.2005.11.037
21. Lindauer SJ, Lewis SM, Shroff B. Overbite correction and smile Aesthetics. *Semin Orthod*. 2005;11:62–66. doi:10.1053/j.sodo.2005.02.003
22. Snow SR. Esthetic smile analysis of maxillary anterior tooth width: the golden percentage. *J Esthetic Restorat Dentis*. 1999;11:177–184. doi:10.1111/jerd.1999.11.issue-4
23. Saha MK, Khatri M, Saha SG, Dubey S, Saxena D, Vijaywargiya N. Perception of acceptable range of smiles by specialists, general dentists and lay persons and evaluation of different aesthetic paradigms. *J Clin Diagn Res*. 2017;11:Zc25–zc28. doi:10.7860/JCDR/2017/23359.9274
24. Parrini S, Rossini G, Castroflorio T, Fortini A, Deregisus A, Debernardi C. Laypeople's perceptions of frontal smile esthetics: A systematic review. *Am J Orthod Dentofacial Orthop*. 2016;150:740–750. doi:10.1016/j.ajodo.2016.06.022

25. Schabel BJ, McNamara JA, Baccetti T, Franchi L, Jamieson SA. The relationship between posttreatment smile esthetics and the ABO Objective Grading System. *Angle Orthod.* 2008;78:579–584. doi:10.2319/0003-3219(2008)078[0579:TRBPSE]2.0.CO;2
26. Dai ML, Xiao M, Yu Z, Dx L. Effect of extraction and non-extraction treatment on frontal smiling esthetics: a meta-analysis. *Shanghai J Stomatol.* 2015;24(4):499–504.
27. Meyer AH, Woods MG, Manton DJ. Maxillary arch width and buccal corridor changes with orthodontic treatment. Part 1: differences between premolar extraction and nonextraction treatment outcomes. *Am J Orthod Dentofacial Orthop.* 2014;145:207–216. doi:10.1016/j.ajodo.2013.10.017
28. Lombardi RE. The principles of visual perception and their clinical application to denture esthetics. *J Prosthet Dent.* 1973;29:358–382.
29. Isiksal E, Hazar S, Akyalcin S. Smile esthetics: perception and comparison of treated and untreated smiles. *Am J Orthod Dentofacial Orthop.* 2006;129:8–16. doi:10.1016/j.ajodo.2005.07.004
30. Sarver DM, Ackerman MB. Dynamic smile visualization and quantification: part 1. Evolution of the concept and dynamic records for smile capture. *Am J Orthod Dentofacial Orthop.* 2003;124:4–12. doi:10.1016/S0889540603003068
31. Janson G, Branco NC, Freire Fernandes TM, Sathler R, Garib D, Pereira Lauris JR. Influence of orthodontic treatment, midline position, buccal corridor and smile arc on smile attractiveness. *Angle Orthod.* 2011;81:153–161. doi:10.2319/040710-195.1
32. Zachrisson BU. Esthetic factors involved in anterior tooth display and the smile: vertical dimension. *J Clin Orthod.* 1998;32:432–445.
33. Chen SS, Greenlee GM, Kim JE, Smith CL, Huang GJ. Systematic review of self-ligating brackets. *Am J Orthod Dentofacial Orthop.* 2010;137(6):726.e1–726.e18; discussion 726–7. doi:10.1016/j.ajodo.2009.11.009
34. Pandis N, Polychronopoulou A, Eliades T. Self-ligating vs conventional brackets in the treatment of mandibular crowding: a prospective clinical trial of treatment duration and dental effects. *Am J Orthod Dentofacial Orthop.* 2007;132:208–215. doi:10.1016/j.ajodo.2006.01.030
35. Pandis N, Polychronopoulou A, Makou M, Eliades T. Mandibular dental arch changes associated with treatment of crowding using self-ligating and conventional brackets. *Eur J Orthod.* 2010;32:248–253. doi:10.1093/ejo/cjp123
36. Jiang RP, Fu MK. [Non-extraction treatment with self-ligating and conventional brackets]. *Chinese J Stomatol.* 2008;43:459–463.
37. Moher D, Liberati A, Tetzlaff J, Altman DG; The PRISMA Group. Preferred Reporting items for Systematic Reviews and Meta-Analyses: The PRISMA Statement. *PLoS Med* 2009;6(7): e1000097. doi:10.1371/journal.pmed1000097
38. Akyalcin S, Misner K, English JD, Alexander WG, Alexander JM, Gallerano R. Smile esthetics: evaluation of long-term changes in the transverse dimension. *Korean J Orthod.* 2017;47:100–107. doi:10.4041/kjod.2017.47.2.100

Clinical, Cosmetic and Investigational Dentistry

Dovepress

Publish your work in this journal

Clinical, Cosmetic and Investigational Dentistry is an international, peer-reviewed, open access, online journal focusing on the latest clinical and experimental research in dentistry with specific emphasis on cosmetic interventions. Innovative developments in dental materials, techniques and devices that improve outcomes and patient

satisfaction and preference will be highlighted. The manuscript management system is completely online and includes a very quick and fair peer-review system, which is all easy to use. Visit <http://www.dovepress.com/testimonials.php> to read real quotes from published authors.

Submit your manuscript here: <https://www.dovepress.com/clinical-cosmetic-and-investigational-dentistry-journal>