

A single-operator technique in ultrasound-guided regional anesthesia

Shuai Tang¹, Jin-Lei Li², Yu-Guan Zhang¹, Yu-Guang Huang¹

¹Department of Anesthesiology, Peking Union Medical College Hospital, Chinese Academy of Medical Sciences, Beijing 100730, China;

²Department of Anesthesiology, Yale University, New Haven, CT, USA.

During ultrasound-guided regional anesthesia, the operator typically holds the probe in one hand and the needle in the other hand. Meanwhile, another person is frequently needed to control the syringe. However, the availability of a second-pair-of-hands could be challenging under many circumstances, such as operating room rush hours and off hours. In addition, an assistant, who is unfamiliar with the operator or the procedure, can make a seemingly short procedure a lengthy one, leading to delays or even adverse events due to miscommunication. There have been specialists come up with different solutions to solve this problem.^[1-4] We developed a technique which allows a single operator to perform ultrasound-guided regional anesthesia.

In this technique the operator holds the probe in one hand and, the syringe and needle in the other. The needle is held between the thumb and index finger, and the syringe can be either in the palm with the barrel edge clamped between the index and middle fingers [Figure 1A] or be put down in the sterile field. When the needle tip reaches the target, the operator releases the needle and then uses the thumb to push the plunger backward to perform an aspiration [Figure 1B] followed by a forward pushing on the plunger with the thumb to inject local anesthetics [Figure 1C]. The spread of the local anesthetics should be continuously observed. One can stabilize or adjust the needle tip as needed throughout the procedure by temporarily holding the needle between the ring and little fingers. Another point of this technique is that the palm should be facing the operator which enables directly observing the injected volume (Supplemental Digital Content: video [Video 1 This video is a demonstration of the application of Tang maneuver in the simulation and clinical settings, <http://links.lww.com/CM9/A368>]).

We made two additional modifications. When injecting more than 20 mL of local anesthetic is planned, we

modified this technique to add a three-way stopcock between two 20 mL syringes. In this case, one operator can inject up to 40 mL of local anesthetics. Second, we now preferentially use transducers with control buttons, which allow the operator to optimize the image quality and save them.

With the original design and subsequent modifications, this technique (what we call the Tang maneuver) allows one operator to perform ultrasound-guided regional anesthesia without sacrificing either safety (by maintaining aspiration and injection pressure monitor) or quality of images (by simultaneously adjusting ultrasound setting and saving images).

There are several pre-requisites needed for this technique as follows: (1) a seasoned proceduralist; (2) all supplies available in a sterile field; (3) ideally, an ultrasound with control buttons on the probe, alternatively, a sterile cover for the ultrasound control pad can be used.

The advantages of this technique are multi-fold. First, the whole process of regional anesthesia can be performed comfortably by a single operator without assistance, hence saving workforce. Human resources of medical workers can be extremely scarce, as in the current pandemic situation. Second, by holding the needle between the ring and little fingers, this technique offers the operator the ability to inject local anesthetic while manipulating the needle, which is very useful in clinical practice. Thirdly, the operator can feel the injection pressure (which helps with intraneural injection identification) and observe needle position and local anesthetic spread in real time.

Tang maneuver filled several gaps in existing single-operator ultrasound-guided nerve block techniques. The syringe barrel edge is clamped between the index and middle fingers therefore provides better stability of the

Access this article online

Quick Response Code:



Website:

www.cmj.org

DOI:

10.1097/CM9.0000000000001186

Correspondence to: Yu-Guang Huang, Department of Anesthesiology, Peking Union Medical College Hospital, CAMS&PUMC, No.1 Wangfujing, Dongcheng District, Beijing 100730, China
E-Mail: garypumch@163.com

Copyright © 2020 The Chinese Medical Association, produced by Wolters Kluwer, Inc. under the CC-BY-NC-ND license. This is an open access article distributed under the terms of the Creative Commons Attribution-Non Commercial-No Derivatives License 4.0 (CCBY-NC-ND), where it is permissible to download and share the work provided it is properly cited. The work cannot be changed in any way or used commercially without permission from the journal.

Chinese Medical Journal 2021;134(6)

Received: 24-11-2020 Edited by: Yan-Jie Yin and Xiu-Yuan Hao

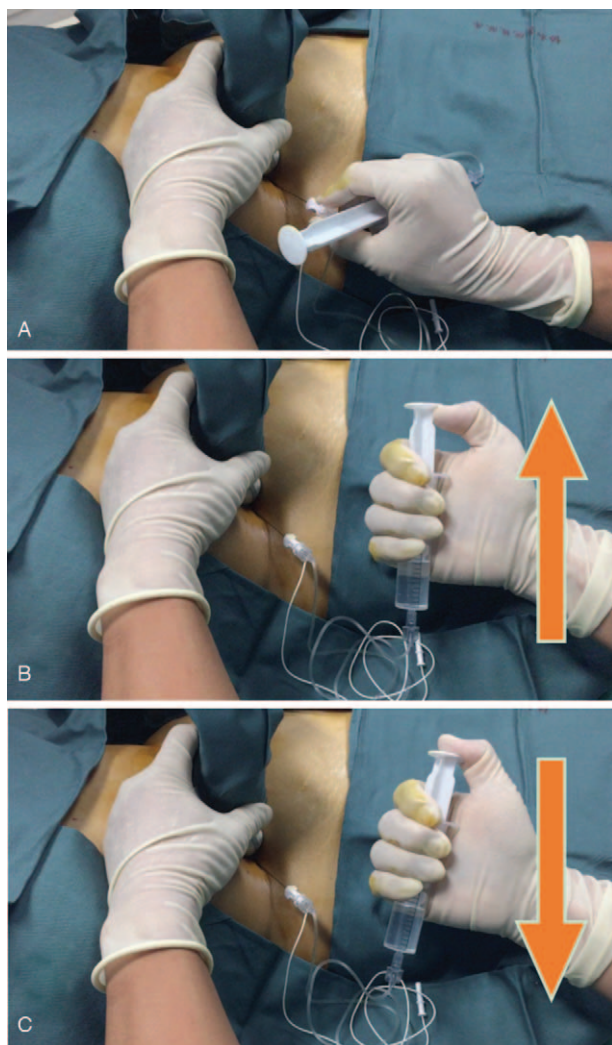


Figure 1: Steps of the single operator technique. (A) The operator holds the probe in the left hand and the syringe and needle in the right hand. The needle is held between the thumb and the index finger and the syringe in palm. (B) The operator uses the thumb to push the plunger backwards to perform an aspiration. The upward arrow refers to aspiration with the thumb while pushing the plunger backward. (C) The operator uses the thumb to push the plunger forward to perform an injection. The downward arrow refers to injection with the thumb while pushing the plunger forward.

syringe than the Jedi Grip^[1] during aspiration and injection of local anesthetics. In addition, in the “on lock” grip^[3] the operator holds the ultrasound probe between the ring and little fingers and the syringe between the index and middle fingers. This could very well be a source of probe instability and inability to intermittently aspirate during injection. On the other hand, in Tang maneuver we are able to free one dedicated hand to hold only the probe and nothing else. After careful evaluation and combining with our practical experience, we feel Tang maneuver offers a good balance of stability, controllability, operator comfort, and syringe feedback [Table 1].

Table 1: Comparison of the three single-operator ultrasound-guided regional anesthesia techniques.

Evaluation index	Jedi grip	On lock grip	Tang maneuver
Stability	+++	+	+++
Controllability	++	++	+++
Operator comfort	++	+	+++
Syringe feedback on injection pressure	++	+	+++

+: Weak; ++: Intermediate; +++: Strong.

The limitations of this technique include the following: (1) the needle may be unstable or may slip away from the target during injection; (2) it takes time for an operator to get used to holding needles while having the syringe in palm; (3) repetitive practice is required for operators to get used to this technique; (4) it is difficult for most practitioners to operate syringes larger than 20 mL while maintaining stability with one hand, thus limiting the total volume that can be injected, some operators with small hands may feel more comfortable with 10 mL syringes instead. As a newly developed technique, clinical or simulative trials are needed to validate the practical relevance of the Tang maneuver.

Funding

This work was supported by the Fundamental Research Funds for the Central Universities (No. 3331019031) and B. Braun Anesthesia Scientific Research Fund (No. BBDF-2018-008).

Conflicts of interest

None.

References

1. Pappin D, Christie I. The Jedi Grip: a novel technique for administering local anaesthetic in ultrasound-guided regional anaesthesia. *Anaesthesia* 2011;66:845. doi: 10.1111/j.1365-2044.2011.06845.x.
2. Bedforth N, Townsley P, Maybin J, Eisenberg E. Single-handed ultrasound-guided regional anaesthesia. *Anaesthesia* 2011;66:846. doi: 10.1111/j.1365-2044.2011.06864.x.
3. Gupta P, Berrill A. ‘On lock’ - a further single-operator ultrasound-guided regional anaesthesia grip. *Anaesthesia* 2017;72:1289. doi: 10.1111/anae.14050.
4. Johnson B, Herring A, Stone M, Nagdev A. Performance accuracy of hand-on-needle versus hand-on-syringe technique for ultrasound-guided regional anaesthesia simulation for emergency medicine residents. *West J Emerg Med* 2014;15:641-646. doi: 10.5811/westjem.2014.7.21717.

How to cite this article: Tang S, Li JL, Zhang YG, Huang YG. A single-operator technique in ultrasound-guided regional anaesthesia. *Chin Med J* 2021;134:734-735. doi: 10.1097/CM9.0000000000001186