

Case Report

In Situ Graft Replacement for a Ruptured Abdominal Aortic Aneurysm Infected with *Listeria monocytogenes* after Endovascular Aneurysm Repair

Tsune-hisa Yamamoto, MD, Katsuhiko Oka, MD, Keiichi Kanda, MD, PhD, Osamu Sakai, MD, PhD, Taiji Watanabe, MD, PhD, and Hitoshi Yaku, MD, PhD

Listeria monocytogenes infection and rupture of the aneurysm sac, after endovascular aneurysm repair (EVAR), are both rare. We report the case of an 82-year-old man who presented with a ruptured aneurysm by infection with *L. monocytogenes* after EVAR. We successfully treated him by in situ reconstruction with a bifurcated expanded polytetrafluoroethylene (ePTFE) graft, with partial removal of the infected stent graft. At 30 months from the reoperation, the patient was in good health at home, with no symptoms of infection, and the gallium-67-citrate single-photon emission computed tomography/computed tomography (SPECT/CT) fusion images confirmed no fluid accumulation.

Keywords: EVAR, infection, *Listeria monocytogenes*


Introduction

Stent-graft infection remains very rare, despite the high mortality and significant morbidity associated with aortic aneurysms. Here we report the first known case of a ruptured aneurysm by infection with *Listeria monocytogenes* after endovascular aneurysm repair (EVAR) treated by

Department of Cardiovascular Surgery, Graduate School of Medical Science, Kyoto Prefectural University of Medicine, Kyoto, Japan

Received: May 26, 2018; Accepted: June 5, 2018

Corresponding author: Hitoshi Yaku, MD, PhD. Department of Cardiovascular Surgery, Graduate School of Medical Science, Kyoto Prefectural University of Medicine, 465 Kajii-cho, Kawaramachi-Hirokoji, Kamigyo-ku, Kyoto 602-8566, Japan
Tel: +81-75-251-5752, Fax: +81-75-257-5910
E-mail: yakuh@koto.kpu-m.ac.jp

 ©2018 The Editorial Committee of Annals of Vascular Diseases. This article is distributed under the terms of the Creative Commons Attribution License, which permits use, distribution, and reproduction in any medium, provided the credit of the original work, a link to the license, and indication of any change are properly given, and the original work is not used for commercial purposes. Remixed or transformed contributions must be distributed under the same license as the original.

surgical removal of the infected stent graft and in situ reconstruction with a new expanded polytetrafluoroethylene (ePTFE) graft. The patient provided consent for the publication of his data.

Case Report

An 82-year-old man presented with an asymptomatic 63 mm abdominal aortic aneurysm (AAA) and a 43 mm right common iliac arterial aneurysm.

He underwent elective EVAR under general anesthesia. After right internal iliac artery embolization with coils, an Endurant stent graft (Medtronic Cardiovascular, Santa Rosa, CA, USA) was implanted below the left renal artery. The distal limbs landed at the right external iliac and the left common iliac arteries. During hospitalization, the patient displayed no symptoms of infection and was discharged uneventfully. Postoperative computed tomographic (CT) scans confirmed proper positioning of stent grafts. No indications of graft migration, endoleak formation, infection, or enlargement of the AAA sac were observed until 12 months after EVAR.

However, 13 months after EVAR, the patient visited another clinic because of high fever and diffuse abdominal pain. Blood samples showed a leukocyte count of 15,800 cells/ μ L and a C-reactive protein (CRP) level of 27.0 mg/dL. He was given ceftriaxone after the diagnosis of cholecystitis for gallbladder wall thickening. Although the symptoms soon improved, markers of severe inflammation were detectable four weeks thereafter.

When the patient visited our hospital 14 months after EVAR, he had no symptoms of infection and had a normal body temperature. Subsequent CT scans showed neither endoleaks nor any increase in the diameter of the aneurysm. However, a new 18 mm saccular protrusion was observed toward the left lateral wall of the aneurysm. This irregular and disrupted protrusion was intense, indicating infection and containment of the rupture (Figs. 1A and

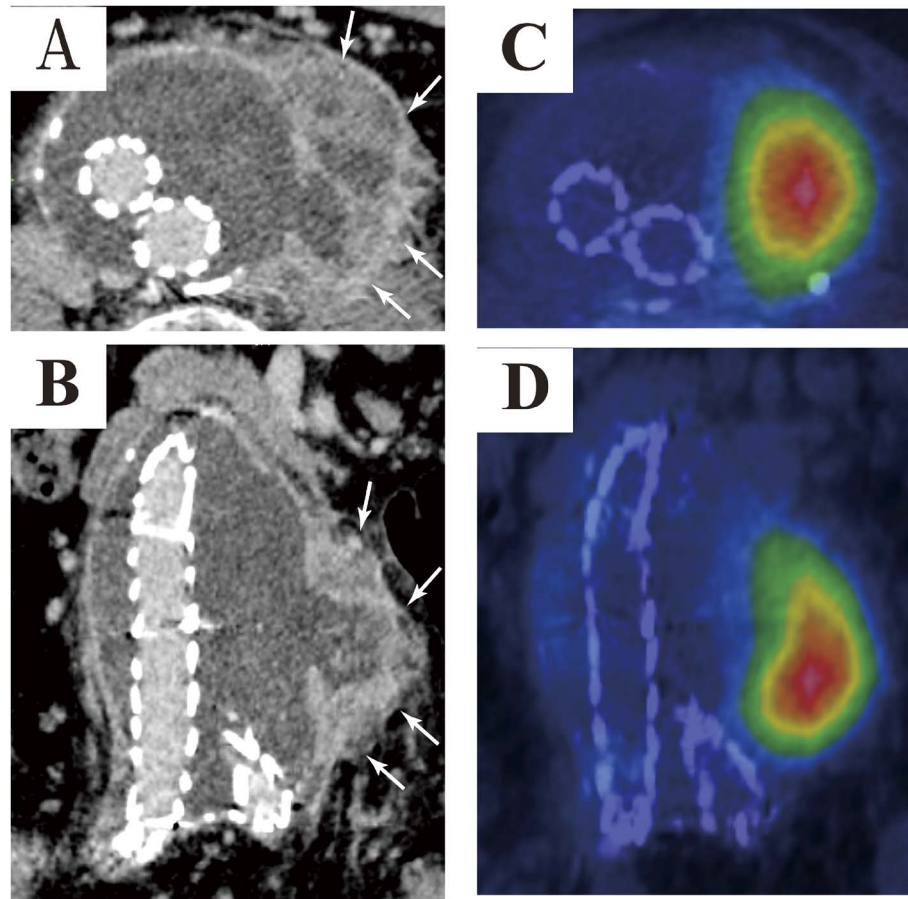


Fig. 1 (A, B) Abdominal computed tomographic (CT) scan at 14 months, exhibiting thickening of the aneurysm sac wall (white arrows). No evidence of endoleak formation or stent-graft migration was observed. (C, D) Ga-67-citrate single-photon emission computed tomography (SPECT)/CT fusion images at 15 months demonstrating localized fluid accumulation at the left side of the abdominal aortic aneurysm (AAA) sac. These images show a high level of integration as indicated by the encroachment of the warm colors.

1B). A second blood culture was negative for pathogens.

We attempted conservative treatment with antibiotics (2.0g ceftriaxone per day) for four weeks because of his morbidity and overall condition. However, despite the reduced expression of inflammatory markers (white blood cell count: 7,100 cells/ μ L; CRP: 0.46mg/dL), the length of the protrusion enlarged to 30 mm. Ga-67-citrate single-photon emission computed tomography (SPECT)/CT fusion images demonstrated localized fluid accumulation at the protrusion site (Figs. 1C and 1D). Finally, we performed a second surgery 18 months after EVAR. A small volume of serous ascites was collected by laparotomy, and thickening, paleness, and friability of the sac wall were observed. Adventitia of the sac was severely adhered to the intestinal tract. The abdominal aorta below the renal arteries was clamped, which included the main body of the stent graft, followed by distal clamping of the bilateral external iliac arteries. The aneurysm sac was opened

and washed with a large volume of saline (Fig. 2). No endoleaks were observed. Before cutting the stent graft, the bilateral legs were temporarily clamped. Both the abdominal aorta and the Endurant main body were interrupted 1 cm below the proximal clamp. The distal part of the main body and the limbs were removed. The infected aortic wall was resected as much as possible. Anatomical reconstruction with a 20 \times 10 mm bifurcated ePTFE graft (GORE-TEX Vascular Grafts, W. L. Gore & Associates, Inc., Flagstaff, AZ, USA) was performed from the infrarenal abdominal aorta to the bilateral external iliac arteries. Both the proximal aortic stump and the remaining Endurant main body wall were anastomosed to the new graft. The left internal iliac artery was ligated, and the omentum was tacked around the bifurcated graft.

Microbacterial cultures of the contents of the yellow discharge, sac wall, and stent graft later grew *L. monocytogenes*. The histopathology of the resected aorta revealed

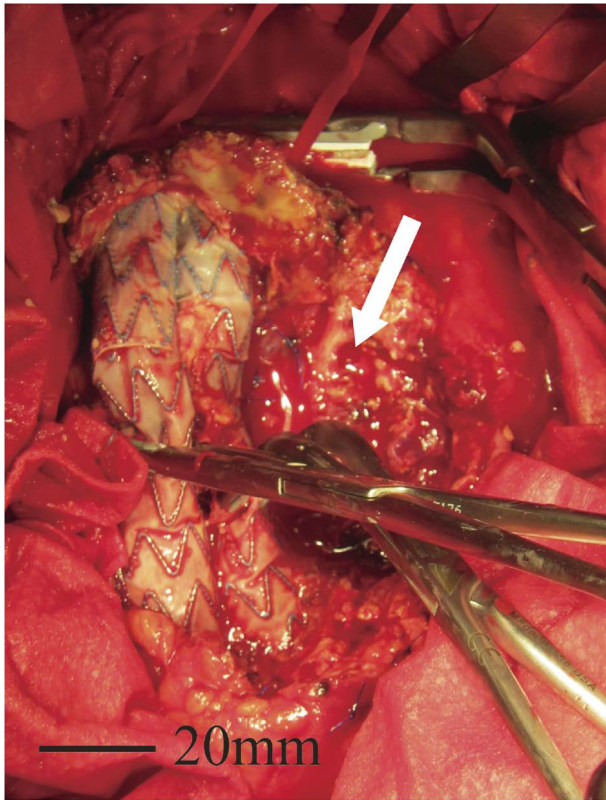


Fig. 2 Intraoperative photograph. The aneurysm sac wall was severely damaged with intramural thrombus (white arrow). There was no evidence of endoleak formation.

inflamed and granulated tissue with foreign body granuloma and necrosis. Thus, intravenous antibiotics were administered (2.0g vancomycin and meropenem per day). His postoperative course was uncomplicated, and he was discharged 26 days after surgery with a prescription for amoxicillin (3,000mg every 6h). Blood samples showed a leukocyte count of 7,500 cells/ μ L and a CRP level of 0.27mg/dL. A CT scan at the eight-month follow-up confirmed the resolution of the abnormal fluid pooling. The ePTFE graft was anastomosed to the native aorta and the left Endurant main body (Fig. 3A). The Ga-67-citrate SPECT/CT fusion images confirmed no fluid accumulation (Fig. 3B). At 30 months after reoperation, he exhibited no symptoms of infection. We are currently planning to perform permanent oral antibiotic administration in the future.

Discussion

Following EVAR, aortic stent-graft infections are rare. A literature review revealed a rate of stent-graft infection of only 0.4–0.63%, with studies reporting a high overall incidence of stent-graft infection characterized by a first-line treatment of stent-graft removal and intravenous administration of antibiotics.^{1,2)}

Only three other cases were reported to have stent-graft infections, leading to the rupture of the aneurysm sac.^{3–5)}

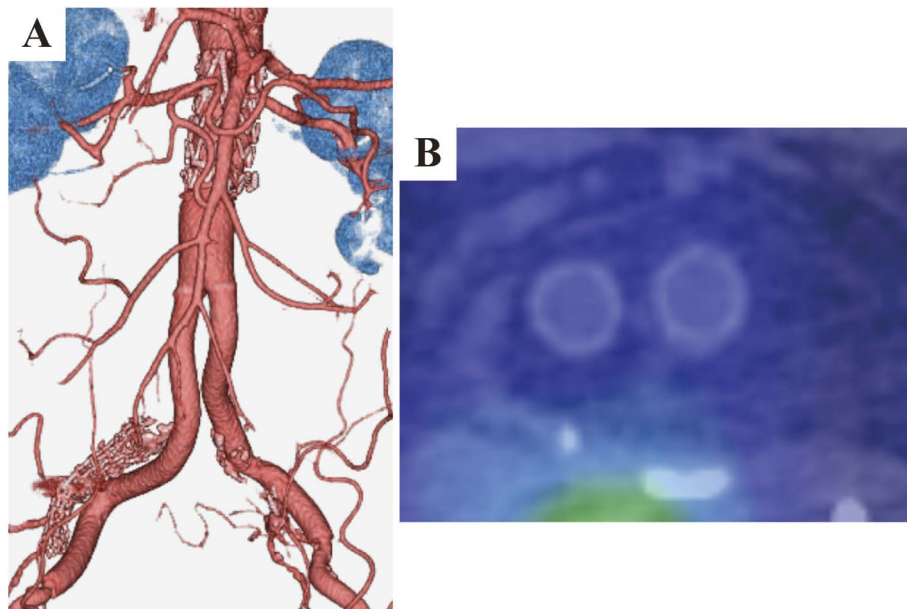


Fig. 3 Imaging after surgical removal of the stent graft and in situ revascularization. **(A)** A three-dimensional computed tomography (CT) image. The expanded polytetrafluoroethylene (ePTFE) graft was anastomosed to the native aorta and the remaining part of the Endurant main body. **(B)** A Ga-67-citrate single-photon emission computed tomography (SPECT)/CT fusion image. There was no sign of fluid accumulation around the ePTFE graft.

In all three cases, the infected stent grafts were removed and highly sensitive antibiotics were administered, followed by an extra-anatomical bypass surgery.

Here, because of the relatively high surgical risk, we initially selected a conservative treatment strategy with antibiotics, despite the predictable high mortality rate.^{1,6)} However, the protrusion of the aneurysm sac expanded with time. Therefore, we decided to perform anatomical revascularization. Cryopreserved homografts are difficult to obtain in Japan. We selected in situ ePTFE grafting rather than extra-anatomical bypass grafting because of its lower mortality rate and higher patency rate.

Because the suprarenal barbs were rigidly fixed to the abdominal aortic wall at the superior mesenteric and renal artery levels, complete removal of the stent graft required the aortic clamp above them. Moreover, removal of the main body of the stent graft with the suprarenal barbs could cause severe damage to the aortic wall, which requires reconstruction of the visceral arteries. Due to the fact that the infection was localized to the left lateral aneurysm sac, we left part of the main body that was anastomosed to the ePTFE graft, including the native aortic wall. Marone et al.⁷⁾ recommended resection of the stent graft at the fabric level to avoid cutting the stent struts, which could eventually damage the new graft or suture line.

L. monocytogenes, an aerobic Gram-positive bacillus commonly found in the soil, is widespread in the environment and is part of the human fecal flora in approximately 5% of healthy adults. Although adult human infections are rare, *Listeria* infections are more common and cause sepsis, meningoenzephalitis, or gastroenteritis in neonates, pregnant women, the elderly, and immunocompromised hosts.⁸⁾

Only a few reports on *L. monocytogenes* infection after EVAR exist in the literature.^{1,2,6,9)} The mechanism of *L. monocytogenes* infection in an aortic aneurysm or stent graft is that the bacteria cross the mucosal barrier of the human intestine, aided by endocytosis of endothelial cells, and enter the bloodstream. They then spread throughout the body and adhere to the aortic wall or aortic stent graft.¹⁰⁾ Here, the delay in the onset of infection 13 months after implantation and the history of cholecystitis suggest hematogenic seeding of the aneurysm sac and stent graft as an etiology for infection and eventual rupture. Focal infection to the aneurysm sac caused the protrusion and rupture of the aneurysm sac.

Conclusion

To the best of our knowledge, this is the first report on

the rupture of AAA infected with *L. monocytogenes* after EVAR, treated by partial removal of stent grafts and in situ reconstruction. The method presented is safe and useful for aortic aneurysm repair.

Disclosure Statement

Katsuhiko Oka and Osamu Sakai have received research fund from W. L. Gore & Associates Co. Ltd.

Author Contributions

Study conception: TY, KO, KK

Analysis: all authors

Data collection: TY

Writing: TY

Critical review and revision: all authors

Final approval of the article: all authors

Accountability for all aspects of the work: all authors

References

- 1) Fiorani P, Speziale F, Calisti A, et al. Endovascular graft infection: preliminary results of an international enquiry. *J Endovasc Ther* 2003; **10**: 919-27.
- 2) Cernohorsky P, Reijnen MPJ, Tielliu IFJ, et al. The relevance of aortic endograft prosthetic infection. *J Vasc Surg* 2011; **54**: 327-33.
- 3) Parra JR, Lee C, Hodgson KJ, et al. Endograft infection leading to rupture of aortic aneurysm. *J Vasc Surg* 2004; **39**: 676-8.
- 4) Berchiolli R, Adami D, Sardella SG, et al. Rupture of abdominal aortic aneurysm due to endograft infection after endovascular aneurysm repair (EVAR). *European Journal of Vascular and Endovascular Surgery Extra* 2005; **10**: 110-3.
- 5) Starr J, Walker G, Vaccaro P. Endograft infection presenting as a ruptured aortic aneurysm. *Ann Vasc Surg* 2009; **23**: 787.e7-e9.
- 6) Saleem BR, Berger P, Zeebregts CJ, et al. Periaortic endograft infection due to *Listeria monocytogenes* treated with graft preservation. *J Vasc Surg* 2008; **47**: 635-7.
- 7) Marone EM, Mascia D, Coppi G, et al. Delayed open conversion after endovascular abdominal aortic aneurysm: device-specific surgical approach. *Eur J Vasc Endovasc Surg* 2013; **45**: 457-64.
- 8) Lorber B. Listeriosis. *Clin Infect Dis* 1997; **24**: 1-11.
- 9) Heikkinen L, Valtonen M, Lepantalo M, et al. Infrarenal endoluminal bifurcated stent graft infected with *Listeria monocytogenes*. *J Vasc Surg* 1999; **29**: 554-6.
- 10) Zdanowski Z, Ribbe E, Schalen C. Bacterial adherence to synthetic vascular prostheses and influence of human plasma. An in vitro study. *Eur J Vasc Surg* 1993; **7**: 277-82.