

Available online at [www.sciencedirect.com](http://www.sciencedirect.com)

ScienceDirect

journal homepage: [www.elsevier.com/locate/radcr](http://www.elsevier.com/locate/radcr)

## Case Report

# Successful endovascular management with a covered stent of an external iliac pseudoaneurysm following allograft nephrectomy using CO<sub>2</sub> as contrast medium: a case report ☆☆☆★

Federico Fontana, MD<sup>a,b</sup>, Filippo Piacentino, MD<sup>a</sup>, Christian Ossola, MD<sup>b,\*</sup>, Marco Curti, MD<sup>b</sup>, Andrea Coppola, MD<sup>a</sup>, Giulio Carcano, MD<sup>b,c</sup>, Gabriele Piffaretti, PhD<sup>b,d</sup>, Matteo Tozzi, MD<sup>b,d</sup>, Massimo Venturini, MD<sup>a,b</sup>

<sup>a</sup>Diagnostic and Interventional Radiology Department, Ospedale di Circolo, ASST dei Sette Laghi, 21100 Varese, Italy.

<sup>b</sup>School of Medicine and Surgery, Università degli Studi dell'Insubria, 21100 Varese, Italy

<sup>c</sup>Surgery Department, Ospedale di Circolo, ASST dei Sette Laghi, 21100 Varese, Italy

<sup>d</sup>Vascular Surgery Department, Ospedale di Circolo, ASST dei Sette Laghi, 21100 Varese, Italy

## ARTICLE INFO

## Article history:

Received 25 August 2021

Accepted 30 August 2021

## Keywords:

CO<sub>2</sub>CO<sub>2</sub> arteriography

Iliac pseudoaneurysm

Endovascular stenting

CKD

## ABSTRACT

Iodinated contrast agents for angiography in chronic kidney disease (CKD) patients could further deteriorate their renal function leading to adverse sequelae. The use of carbon dioxide (CO<sub>2</sub>) is reported in the literature and has been safely used for a variety of angiographic procedures, particularly to guide aortic and renal interventions. We report the case of the successful endovascular treatment with a covered stent of a right external iliac artery pseudoaneurysm following graft nephrectomy in a CKD patient, using CO<sub>2</sub> as contrast medium.

© 2021 The Authors. Published by Elsevier Inc. on behalf of University of Washington.

This is an open access article under the CC BY-NC-ND license

(<http://creativecommons.org/licenses/by-nc-nd/4.0/>)

## Background

In patients with chronic kidney disease (CKD), carbon dioxide (CO<sub>2</sub>) is a valid alternative as a contrast medium for dig-

ital subtraction angiography, given the lack of nephrotoxicity [1].

Kidney transplantation is the gold standard for most patients with CKD because it improves both survival and quality of life, although it can be burdened by several complications.

Abbreviations: CKD, chronic kidney disease; CO<sub>2</sub>, carbon dioxide; EIAP, external iliac artery pseudoaneurysm; DSA, digital subtraction arteriography.

☆ Acknowledgements: No grant or fundings were received for this study.

☆☆ Competing interests: The authors declare that they have no conflict of interest.

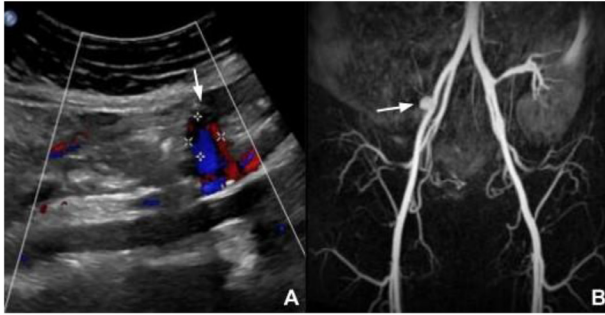
\* Informed consent: Informed consent was obtained from all individual participants included in the study.

\* Corresponding author.

E-mail address: [c.ossola7@gmail.com](mailto:c.ossola7@gmail.com) (C. Ossola).

<https://doi.org/10.1016/j.radcr.2021.08.077>

1930-0433/© 2021 The Authors. Published by Elsevier Inc. on behalf of University of Washington. This is an open access article under the CC BY-NC-ND license (<http://creativecommons.org/licenses/by-nc-nd/4.0/>)



**Fig. 1 – Color Doppler Ultrasound (A) and a paracoronaral contrast enhanced magnetic resonance angiography (B) demonstrating the presence of a 15 mm right external iliac artery perianastomotic pseudoaneurysm (white arrow)**

Pseudoaneurysm of the anastomosis is a rare vascular complication of renal transplant and explant, in around 0,3 % of the transplant population [2].

We present a case of right external iliac artery pseudoaneurysm (EIAP) after allograft nephrectomy, successfully treated with a covered stent using CO<sub>2</sub> as contrast medium.

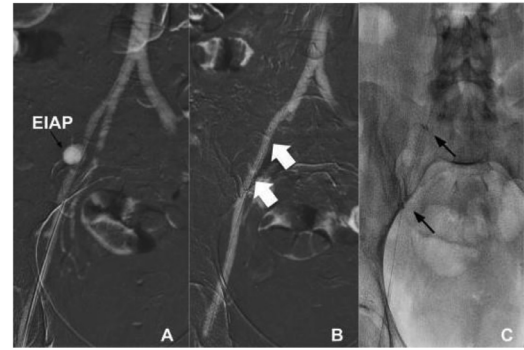
## Case presentation

In 1998, a 12-year-old girl with Henoch-Schonlein nephritis underwent cadaveric renal transplantation in right iliac fossa; the graft artery was joined with the right iliac artery. Fourteen years after, the patient underwent graft nephrectomy due to a progressive renal failure secondary to pyelonephritis.

One year later, she received a living-related kidney in right iliac fossa; the graft artery was joined with the right external iliac artery. The graft was removed after 3 years due to IgA nephropathy. In third post-explantation day, the patient developed abdominal pain at the surgical wound site. Contrast enhanced CT scan revealed the presence of free fluid material in the right iliac fossa with arterial bleeding from ipsilateral psoas muscle. Immediate surgical exploration was performed with the evacuation of the hematoma and hemostasis. Five months later, in February 2020, the patient underwent a third renal transplant from a cadaveric donor in left iliac fossa; the graft artery was joined with the left external iliac artery. In the twentieth postoperative day, a standard follow-up color-Doppler ultrasound (US) examination showed a perianastomotic right EIAP. A contrast enhanced magnetic resonance angiography (Fig. 1) confirmed the US findings.

An endovascular treatment with covered stent was planned; in consideration of the poor kidney function (creatinine 2.52 mg/dl), CO<sub>2</sub> was used as contrast medium to avoid nephrotoxicity.

The procedure was performed in an angiographic room (Al-lura Xper FD20 with flat detector, Philips Medical Systems, Best, The Netherlands), using an ipsilateral femoral artery approach; a preliminary diagnostic digital subtraction arteriography (DSA) was performed using CO<sub>2</sub> administered by a dedicated automatic injection system (Angiodroid Srl, San



**Fig. 2 – Carbon dioxide digital subtraction angiography of a right external iliac artery pseudoaneurysm (EIAP) before (A) and after (B) the deployment of covered stent (white arrows) with complete exclusion of the pseudoaneurysm. Single shot fluoroscopy (C) confirms the proper expansion of the stent (black arrows)**

Lazzaro, Bologna, Italy), connected to a right femoral 6-French vascular introducer (Terumo, Tokyo, Japan).

A 6 mm x 50 mm covered stent (Viabahn, Gore, Newark, Delaware, US) was released. A second CO<sub>2</sub> DSA demonstrated total EIAP exclusion, good stent expansion and regular patency of the iliac arterial axis (Fig. 2). After the procedure, creatinine remained stable at 1.97 mg/dL. Additionally, serial hemoglobin and vital signs remained stable.

For each injection, CO<sub>2</sub> volume and pressure were 40 mL and 250 mmHg, respectively. To avoid gas fragmentation, the catheter was purged before each injection.

A 3-months follow-up color-Doppler ultrasound confirmed stent patency with the complete exclusion of the pseudoaneurysm.

## Discussion

Iodinated contrast-induced nephropathy accounts for 11% of hospital-acquired renal insufficiency. The use of CO<sub>2</sub> as contrast medium has some advantages along with the absence of nephrotoxicity, the low viscosity and the lower costs, if compared to iodinated CM contrast medium [1].

CO<sub>2</sub> DSA was first illustrated by Hawkins and colleagues [3] in 1982. Despite image quality of CO<sub>2</sub> DSA is diluted if compared to iodine DSA, modern angiographic equipment are capable of high resolution and image summation by incorporating software packages with an upgraded contrast resolution [4].

CO<sub>2</sub> DSA images are obtained by replacing the intraluminal blood volume with the gas; on the other hand, iodine DSA images are achieved through the amalgamation of the contrast medium with the blood [5].

The use of CO<sub>2</sub> as contrast medium is not free from possible complications, primarily related to the amount of gas injection and its neurotoxicity in cerebral angiography. Other complications are represented by ischemic colitis subsequent to the accumulation of CO<sub>2</sub> into the mesenteric arteries, this

is defined as “vapor lock phenomenon”. Respiratory or renal failure occurs quite rarely [6]. Nevertheless, CO<sub>2</sub> use has been safely reported in literature for a variety of angiographic procedures, particularly to guide aortic and renal interventions [5].

Said *et al.* [4] described the CO<sub>2</sub> use for the diagnosis and embolization of a renal artery pseudoaneurysm secondary to a nephrectomy in a CKD patient.

Chacko *et al.* [1] demonstrated that renal interventions management could be successfully and securely accomplished through CO<sub>2</sub> angiography in patients with Takayasu arteritis and renal insufficiency.

In 2016, Adachi *et al.* [7] presented a case report suggesting that the combination of CO<sub>2</sub> and small quantities of iodinated contrast medium could be a valid alternative to better evaluate renal artery ostial stenosis, to prevent both high volume CO<sub>2</sub> complications and nephrotoxicity [7].

EIAP is a rare complication of renal transplantation, and in the majority of cases are subsequent to graft nephrectomy [8]. Diagnosis is very challenging because clinical manifestations are often non-specific. EIAP must be suspected in the postoperative period if hemorrhagic shock secondary to acute rupture occurs, but in the majority of cases EIAPs are asymptomatic and only incidentally discovered [8], as in this case report.

The pseudoaneurysm repair strategy can include surgery, endovascular treatment (embolization or covered stent), or ultrasound-guided percutaneous thrombin injection [9].

Covered stent is a more conservative endovascular treatment than embolization and in the past the Viabahn stent-graft was successfully used in visceral or peripheral aneurysms (and pseudoaneurysms) management [10].

Herein, we described a case of a patient with CKD who developed a right EIAP following graft nephrectomy, effectively endovascular managed using CO<sub>2</sub> as contrast medium.

In the endovascular literature, reports for the CO<sub>2</sub> contrast medium use in the treatment of pseudoaneurysm is quite scanty; however, as in this case, the CO<sub>2</sub> use can be a good option to reduce the use of iodinated contrast medium in CKD patients.

---

## Conclusion

CO<sub>2</sub> is a secure, non-nephrotoxic contrast agent that may be useful in the endovascular management as complementary to the standard iodinated contrast medium, with significant benefits in CKD patients also in case of covered stent implantation.

---

## Ethical statement

All procedures performed in studies involving human participants were in accordance with the ethical standards of the in-

stitutional and/or national research committee and with the 1964 Helsinki Declaration and its later amendments or comparable ethical standards.

---

## Human and animal rights

This article does not contain any studies with animals performed by any of the authors.

---

## REFERENCES

- [1] Chacko S, Joseph G, Thomson V, George P, George O, Danda D. Carbon dioxide Angiography-Guided Renal-Related Interventions in Patients with Takayasu Arteritis and Renal Insufficiency. *Cardiovasc Intervent Radiol* 2018;41:998–1007.
- [2] Sharma N, Bidnur S, Caldas M, McNally D, Murray A, Turnbull R, et al. Renal transplant anastomotic pseudoaneurysms: Case report of open repair and endovascular management. *IJU Case Rep* 2019;12:86–9.
- [3] Hawkins IF. Carbon dioxide digital subtraction arteriography. *Journal of Roentgenology* 1982;139:19–24.
- [4] Said MA, McGuire BB, Liu JS, Resnik SA, Nadler RB. Novel use of carbon dioxide arteriography in renal artery pseudoaneurysm in patients with poor renal function. *BMJ Case Rep* 2014;2014:1–2. pii: bcr2014206915.
- [5] Moos JM, Ham SW, Han SM, Lew WK, Hua HT, Hood DB, et al. Safety of carbon dioxide digital subtraction angiography. *Arch Surg* 2011;146:1428–32.
- [6] Shaw DR, Kessel DO. The current status of the use of carbon dioxide in diagnostic and interventional angiographic procedures. *Cardiovasc Intervent Radiol* 2006;9:323–31.
- [7] Adachi Y, Endo A, Nakashima R, Sugamori T, Takahashi N, Kinoshita Y, et al. Renal artery stenting using CO<sub>2</sub> gas angiography in combination with iodinated contrast angiography. *Intern Med* 2016;55:2419–22.
- [8] Kobayashi K, Censullo ML, Rossman LL, Kyriakides PN, Kahan BD, Cohen AM. Interventional radiologic management of renal transplant dysfunction: indications, limitations, and technical considerations. *Radiographics* 2007;27:1109–30.
- [9] Bracale UM, Carbone F, del Guercio L, Viola D, D’Armiento FP, Maurea S, et al. External iliac artery pseudoaneurysm complicating renal transplantation. *Interact Cardiovasc Thorac Surg* 2009;8:654–60.
- [10] Venturini M, Marra P, Colombo M, Panzeri M, Gusmini S, Sallemi C, et al. Endovascular repair of 40 visceral artery aneurysms and pseudoaneurysms with the viabahn stent-graft: technical aspects, clinical outcome and mid-term patency. *Cardiovasc Intervent Radiol* 2018;41:385–97.