

## Epidermoid cyst of the cecum in an elderly man

Ali Uzunlar, Yasar Bukte

**E**pidermoid cyst of the cecum is extremely rare. There have been only five reports of epidermoid cysts of the cecum in the English literature. The lesion has been reported in other internal organs in the epididymis, testis, spleen, accessory spleen and liver.<sup>1-9</sup> I report the first case of epidermoid cyst of the cecum in the oldest patient reported thus far and discuss the origin of this entity.

### Case

A 75-year-old man presented to the primary care clinic with a 2-week history of intermittent nausea, vomiting, and abdominal pain. On physical examination, there were signs of acute abdomen such as abdominal tenderness, but no mass within the abdomen was palpable. Plain abdominal radiographs were normal. An abdominal ultrasound scan showed a cystic mass of approximately 5.3 cm in diameter and without connection to the intestine in the right lower quadrant. The radiologist reported a possible appendix mucocele (Figure 1). The patient was taken to the operating room for exploratory laparotomy and possible colonic resection. The exploration of the cecum showed a subserosal mass of  $4.5 \times 3 \times 2$  cm in dimension on the antimesenteric side (Figure 2). No abnormalities were detected on the peritoneal surface or in the small bowel. The terminal ileum, vermiform appendix and proximal right colon were dissected and removed.

On the pathological gross examination I saw a resected right colon, including the cecum and proximal ascending colon  $4.5 \times 3 \times 2$  cm with an attached segment of distal ileum and an intact vermiform appendix. There was a roughly spherical cyst, 4.5 cm in diameter, extending from and expanding the serosal surface of the cecum, just adjacent to the appendix and the distal ileum. The cyst had no connection to the cecum lumen and was filled with a pale yellow-gray soft material.

Histologically, the wall of the cyst was partially composed of the muscu-

*From the Department of Pathology,  
Dicle University, Diyarbakir, Turkey*

*Correspondence and reprint requests:*

*Ali Uzunlar, MD*

*Department of Pathology*

*Dicle University*

*Diyarbakir 21280, Turkey*

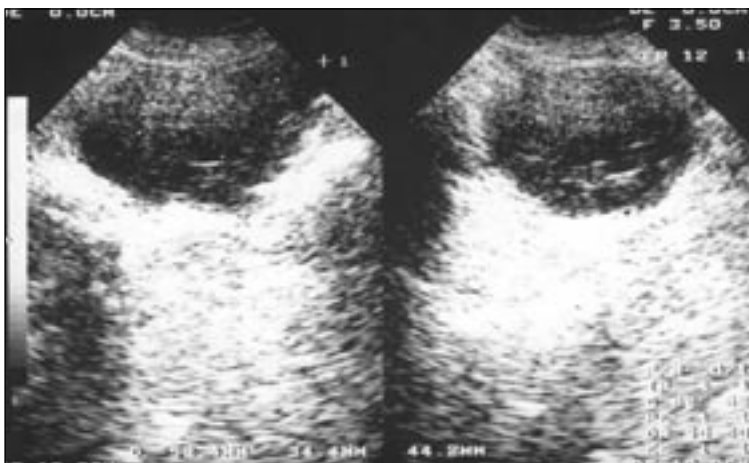*T: +90-412-248 8006*

*uzunlar@dicle.edu.tr*

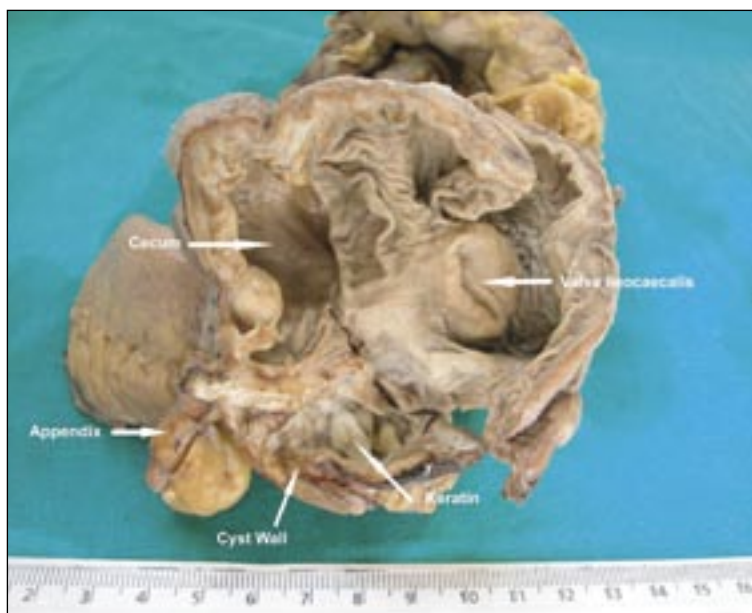
*Accepted for publication*

*January 2006*

*Ann Saudi Med 2006;26(6):477-479*



**Figure 1.** Abdominal ultrasound showing the cystic mass of approximately 5.3 cm in diameter at ileocaecal localization.



**Figure 2.** Gross photography of the surgical pathology specimen of resected cecum, terminal ileum and appendix. The cyst is located on the outer surface of the cecum and contains friable gray keratin.

laris propria of the cecum (Figure 3a). The muscularis propria was present between the normal cecal mucosa and the wall of the cyst. The inner lining of the cyst was composed of mature, keratinized, stratified squamous epithelium with a granular layer (Figure 3b). Skin adnexae were completely absent. There no other ectodermal, endodermal, or mesenchymal elements. The patient died of acute abdomen on the tenth day.

**Discussion**

Epidermoid cysts of the cecum are extremely rare; however, similar cysts of the internal organs have been reported involving the testis, epididymis, spleen, accessory spleen, appendix and liver.<sup>1-9</sup> The histogenesis of epidermoid cyst is unknown. These cysts are generally accepted to be sequestration cysts that may be either congenital or acquired.<sup>10</sup>

In my patient, the congenital epidermoid cyst of the cecum may have taken origin where the cecum re-enters the abdominal cavity as the last part of the gut in the process of intrauterine rotation.<sup>11</sup> Any inclusion or closure line of epidermal or dermal structures may result in the later development of these cysts. Also, the fact that most occur in a subserosal location in the cecum also supports this concept.<sup>9</sup>

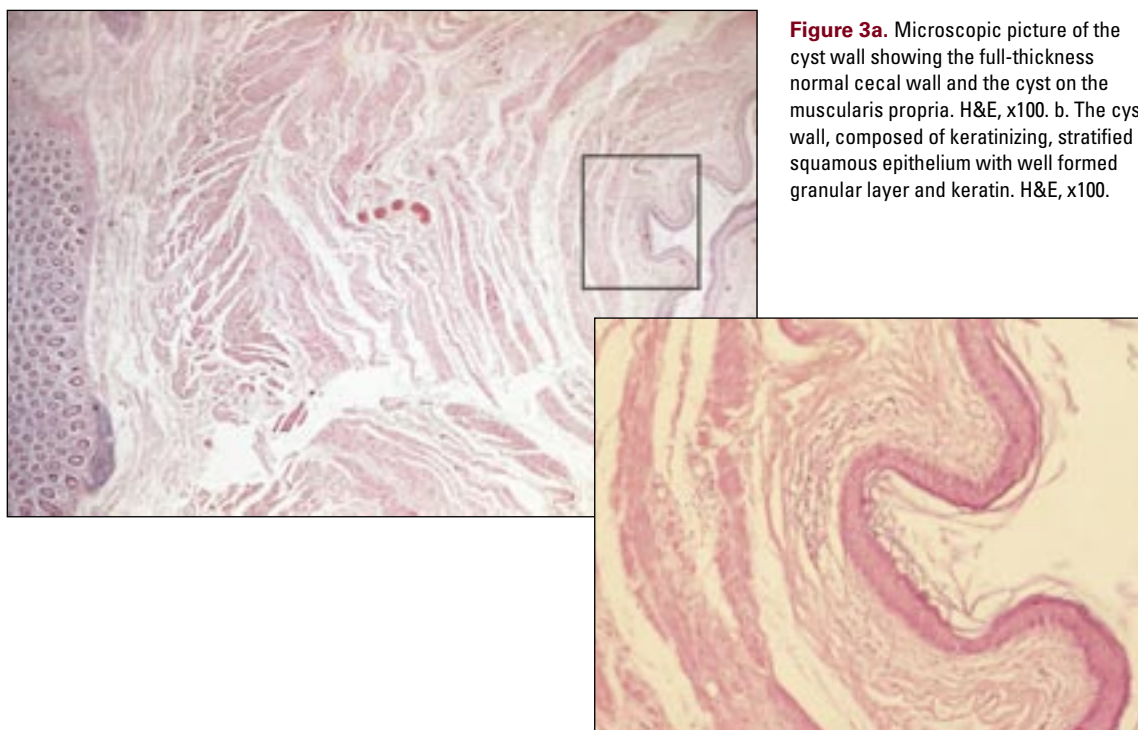
Acquired epidermoid cysts are either traumatic or iatrogenic and are caused by implantation of the epidermis in locations favorable to growth.<sup>9,12</sup> In a review of the literature, only five similar pure epidermoid cysts attached to the cecum were detected. Two cases described in the literature were attributed to iatrogenic implantations during an appendectomy of fragments of epidermis via scalpels, needles, or clamps at the time of the surgical procedure.<sup>12,13</sup> The third case was that of an 8-year-old girl,<sup>9</sup> the first a 67-year-old man<sup>14</sup> and the sixth a 27-year-old woman<sup>15</sup> with no previous iatrogenic etiology (Table 1). The interesting finding in my current case is the age of the patient (75-year-old man) with acute abdomen due to epidermoid cyst of the cecum. The patient had no history of appendectomy or any abdominal surgical procedures. The cyst shared muscular wall with the cecum.

The theories of metaplasia of the serosa caused by chronic inflammatory stimuli and heterotopic inclusion within the organ have not been enough to explain the occurrences of these cysts in the cecum yet.<sup>14,16</sup> However, Horibe et al<sup>7</sup> reported on an epidermoid cyst in an intrapancreatic accessory spleen. They consider that the cyst epithelium, considered to be the pancreatic duct epithelium, may have developed into squamous metaplasia due to chronic inflammatory stimuli. In my case the location and the absence of chronic inflammatory stimuli make this assumption impossible.

Another possibility in this case was an origin in an undescended testis, but this was excluded clinically and radiologically, as the patient’s scrotum contained two testes, and the cyst was located more lateral to the normal

**Table 1.** Reported cases of epidermoid cyst of the cecum until today.

Case no.	Age of patient (years)	Sex	History of surgical procedure	Year reported	Reference
1	67	M	No previous history	2002	14
2	8	F	No previous history	1999	9
3	71	M	Appendectomy16 years prior	1969	12
4	27	F	No previous history	1965	15
5	53	M	Appendectomy12 years prior	1961	13



**Figure 3a.** Microscopic picture of the cyst wall showing the full-thickness normal cecal wall and the cyst on the muscularis propria. H&E, x100. **b.** The cyst wall, composed of keratinizing, stratified squamous epithelium with well formed granular layer and keratin. H&E, x100.

expected paravertebral path of testicular descent.

The possibility of cecal duplication was highly unlikely because of the clear external location of the cyst in relation to the cecal muscular wall and its gross appearance. Mady et al<sup>14</sup> described an epidermoid cyst of the cecum of an elderly man. They reported that the most likely explanation for the presence and development of an epidermoid cyst in this location and its sharing the muscular wall of the cecum is the result of an aberrant embryonic

ectodermal implantation during embryogenesis.

As a result, the most probable explanation for the presence and development of an epidermoid cyst in the cecum is the result of an aberrant embryonic ectodermal implantation during embryogenesis. The possibility of the presence of epidermoid cysts in this area should be considered in the differential diagnosis of cysts within the abdomen and remembered as a reason for acute abdomen.

## References

1. Price EB. Epidermoid cysts of the testis: a clinical and pathologic analysis of 69 cases from the testicular tumor registry. *J Urol.* 1969;102:708-13.
2. Shah KH, Maxted WC, Chun B. Epidermoid cysts of the testis: a report of three cases and an analysis of 141 cases from the world literature. *Cancer* 1981;47:577-82.
3. Srigley JR, Hartwick RW. Tumors and cysts of the paratesticular region. *Pathol Annu.* 1990;25:51-108.
4. Blank E, Campbell JR. Epidermoid cysts of the spleen. *Pediatrics* 1973;51:75-84.
5. Sirinek KR, Evans WE. Nonparasitic splenic cysts: case report of epidermoid cyst with review of the literature. *Am J Surg.* 1973;126:8-13.
6. Tsakraklikes V, Hadley TW. Epidermoid cysts of the spleen: a report of five cases. *Arch Pathol Lab Med.* 1973;96:251-4.
7. Horibe Y, Murakami M, Yamao K, Imaeda Y, Tashiro K, Kasahara M. Epithelial inclusion cyst (epidermoid cyst) formation with epithelioid cell granuloma in an intrapancreatic accessory spleen. *Pathol Int.* 2001;51:50-4.
8. Schullinger JN, Wigger HJ, Price JB, Benson M, Harris RC. Epidermoid cysts of the liver. *J Pediatr Surg.* 1983;18:240-2.
9. Andiran F, Dayi S, Caydere M, Dilmen G, Dilmen U. Epidermoid cyst of the cecum. *J Pediatr Surg.* 1999;34:1567-9.
10. Pear BL. Epidermoid and dermoid sequestration cysts. *Am J Roentgenol Radium Ther Nucl Med.* 1970;110:148-55.
11. Williams PL, Warwick R. *Gray's Anatomy.* Edinburgh, Churchill Livingstone, 1980. p 201.
12. Pear BL, Wolff JN. Epidermoid cyst of the cecum. *JAMA* 1969;207:1516-7.
13. Pan A, Rogers AG, Klass AA. Epidermoid cyst of the cecum. *Can Med Assoc J.* 1961;84:1075.
14. Mady HH, Melhem MF. Epidermoid cyst of the cecum of an elderly man with no previous history of surgery: a case report and review of literature. *Int J Colorectal Dis.* 2002;17:280-3.
15. Chanddreviotis N. Epidermoid cyst of the cecum. *JAMA* 1965;192:425-6.
16. King ESJ. Metaplasia in tunica vaginalis. *Aust NZ J Surg.* 1954;24:131.