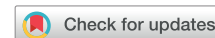

De novo subcutaneous implantable cardioverter-defibrillator in patient with left ventricular assist device



William Reichert, MD,* Emrie Tomaiko, BA,* Aneesh Kalya,[†] Sharon Kusne, NP,*
Carla Lockhart, DNP,* Wilber Su, MD, FHRS*[‡]

From the *Banner University Medical Center–Phoenix and University of Arizona, Phoenix, Arizona,
[†]Arizona State University, Tempe, Arizona, and [‡]Stanford University, Palo Alto, California.

Introduction

As the incidence of heart failure with reduced ejection fraction continues to increase, the prevalence of left ventricular assist devices (LVADs) for patients with end-stage heart failure continues to rise. The majority of these patients will also qualify for an implantable cardioverter-defibrillator (ICD) device for either primary or secondary prevention of sudden cardiac death. Despite their symbiotic potential, LVADs have been shown to create multiple issues with ICD arrhythmia and artifact recognition.^{1,2} In addition, the subcutaneous implantable cardioverter-defibrillator (S-ICD) has emerged as an alternative to transvenous ICD to avoid lead-related or infection-related complications.^{3,4} The use of S-ICD in patients with LVADs has been described in case reports with mixed levels of interference due to the electromagnetic interference (EMI) generated by the LVAD. This is mostly device related, with HeartMate II (Abbott, North Chicago, IL) having less reported interference than HeartWare HVAD (Medtronic, Miramar, FL) or HeartMate 3 (Abbott, North Chicago, IL).^{3–13} In most cases the S-ICD was implanted before the implant of the LVAD, but in certain circumstances the S-ICD was placed after LVAD implant, either electively or for another reason, such as infection. We present a case of S-ICD implant in a patient with HeartMate II LVAD, owing to infection concerns.

KEYWORDS Arrhythmia; Electromagnetic interference; HeartMate II; Left ventricular assist device; Subcutaneous implantable cardioverter-defibrillator

(Heart Rhythm Case Reports 2020;6:774–776)

This research did not receive any specific grant from funding agencies in the public, commercial, or not-for-profit sectors. Disclosures: Wilber Su has received significant research grants and speaker honoraria from both Abbott and Boston Scientific. There are no other conflicts of interest to disclose for other authors. **Address reprint requests and correspondence:** Dr William Reichert, Cardiology Department, Banner University Medical Center, 1111 E. McDowell Rd, Phoenix, AZ 85006. E-mail address: williambreichert@gmail.com.

KEY TEACHING POINTS

- Left ventricular assist devices (LVADs) have been shown to create multiple issues with implantable cardioverter-defibrillator (ICD) arrhythmia and artifact recognition.
- Subcutaneous implantable cardioverter-defibrillator (S-ICD) has emerged as an alternative to transvenous ICD to avoid lead-related or infection-related complications.
- The use of S-ICD in patients with LVADs has been described in case reports with mixed levels of interference due to the electromagnetic interference generated by the LVAD.
- We present a case of S-ICD implant in a patient with a HeartMate II LVAD (Abbott, North Chicago, IL), without subsequent electromagnetic interference.

Case report

A 77-year-old man with a HeartMate II LVAD presented to the heart failure clinic for a low flow alarm. The LVAD was initially implanted in India, without an ICD implant. The patient was admitted to the hospital and found to have pump thrombus. During surgery for pump replacement, the patient was noted to have a pocket infection, which was subsequently treated with irrigation and systemic antibiotics. During the recovery, the patient suffered ventricular fibrillation and hypotension requiring defibrillation, prompting evaluation for ICD placement.

The decision for S-ICD over traditional transvenous implant was made to minimize infection risk, as the patient did not require any other monitoring or pacemaker functions. The patient underwent standard S-ICD screening utilizing surface electrocardiogram in 3 vectors to anticipate any interference and create a template for primary, secondary, and alternate vectors post implant. An EMBLEM MRI S-

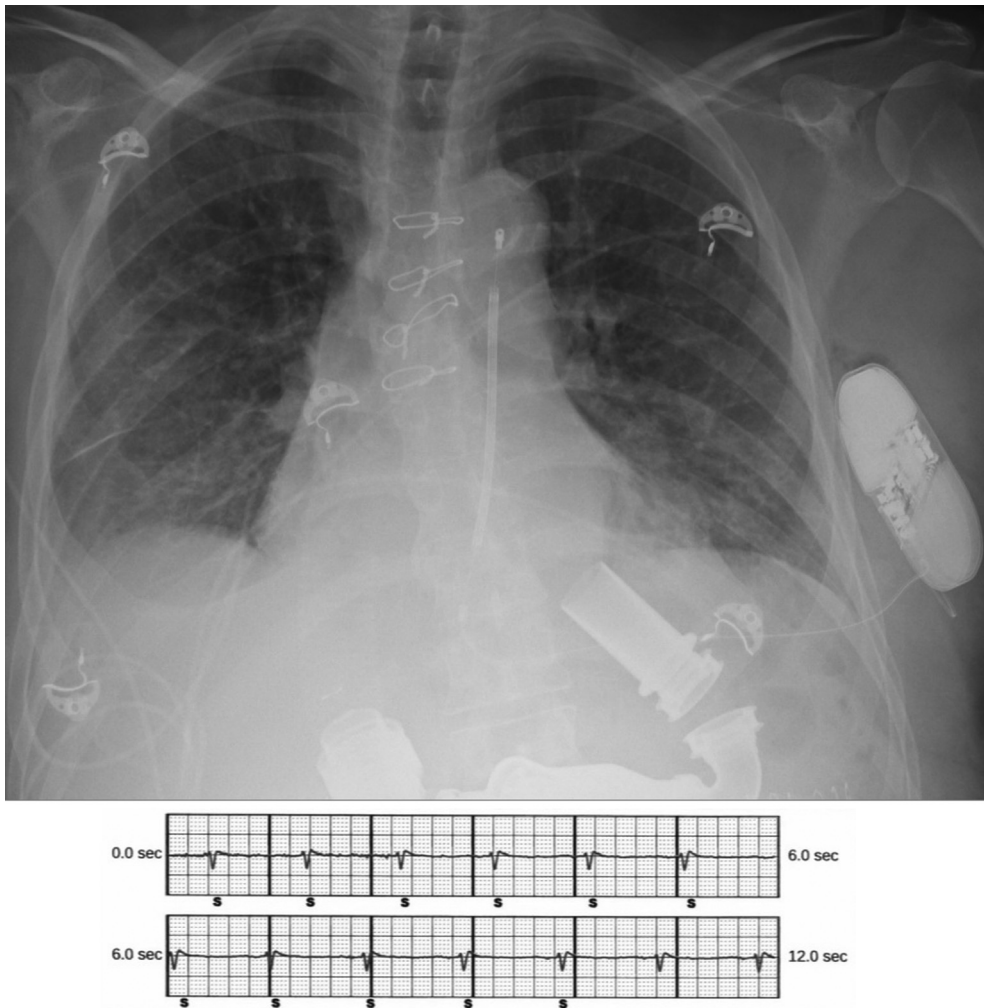


Figure 1 Chest radiograph showing implanted subcutaneous implantable cardioverter-defibrillator with HeartMate II (Abbott, North Chicago, IL) left ventricular assist device with associated alternate vector electrogram.

ICD (Boston Scientific) was implanted (Figure 1) with the VF/VT zone set to 200/250 beats per minute; no significant interference from the LVAD was noted at that time. Defibrillation threshold testing was performed as the implant was for secondary prevention to confirm efficacy and ensure no LVAD interference in a controlled setting. Defibrillation threshold testing was performed successfully at 65 J and 44 ohms with automatic programming in the alternate vector. Computed tomography shows the lateral device placement, providing 11 cm between the S-ICD and LVAD insertion in the apex (Figure 2). The device has not had any significant EMI in any vector and the patient has had no inappropriate shocks for more than 12 months.

Discussion

LVADs have been known to cause EMI with S-ICD, possibly resulting in inappropriate shocks or misidentification of lethal arrhythmias. After a thorough literature search, only 12 cases of S-ICD implant in HeartMate II LVAD have been reported, 1 with EMI causing inappropriate S-ICD shocks and 11 that did not report any interference.^{5–7,14} Our case showed

another instance of S-ICD with no EMI and no shocks on multiple device interrogations over a 12-month span in a patient with the HeartMate II LVAD.

The etiology of EMI has been discussed by multiple publications, some of which link varying pump speeds to EMI causing S-ICD malfunction.^{5,6,8,12} While different S-ICDs utilize varying filters, in general, physiologic frequencies between 3 and 40 Hz are utilized, with other frequencies filtered out in modern S-ICDs, including the EMBLEM MRI S-ICD. Thus, the HeartWare HVAD (standard operational frequencies of 40–53 Hz) would potentially cause EMI at lower frequencies, but the HeartMate 3 (standard operational frequencies 83–100 Hz) and the HeartMate II (standard operational frequencies 146–166 Hz) should be filtered, as their frequencies are greater than 40 Hz.¹¹ Thus, additional causes of EMI must be sought in cases when these filters are utilized.

Other potential causes of EMI implicated in transvenous ICDs include programmer frequency interference and battery pack interference, among other variables.^{14,15} Given this, it is clear there are numerous undiscovered causes of EMI. While

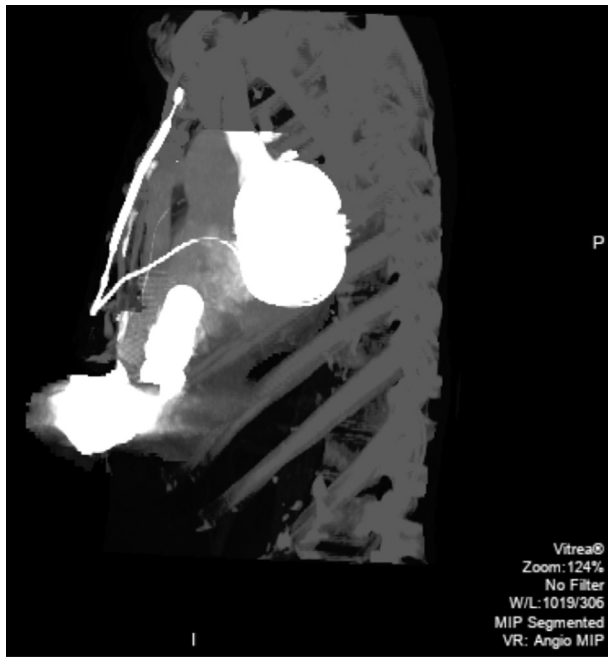


Figure 2 Lateral computed tomography showing implanted subcutaneous implantable cardioverter-defibrillator in relation to HeartMate II (Abbott, North Chicago, IL) left ventricular assist device.

these continue to be identified, implanters should minimize known causes. One example would be choosing the vector that gives the least interference. Along the same lines, it has been shown that the shorter distance between S-ICD and the LVAD is associated with EMI and possibly explains why alternate vectors have less EMI.¹¹ Though not thoroughly investigated with limited information included in manuscripts regarding the HeartMate II, the 1 publication showing EMI in a HeartMate II LVAD did include a chest radiograph that had a relatively short distance between S-ICD and LVAD compared to other available images, including ours.^{4–6} Thus, we hypothesize the HeartMate II LVAD's abdominal location intrinsically provides greater electrical isolation and distance from the S-ICD components, lowering incidence and amount of EMI compared to other LVADs.

Conclusions

It appears that utilizing an S-ICD in a patient is possible and, especially in the case of patients with a HeartMate II LVAD, seems to be safe, with relatively low incidence of EMI and inappropriate over- or undersensing of ventricular arrhythmias. Despite this possible compatibility with the HeartMate

II LVAD, the avoidance of S-ICD placement without strong indication (such as vascular incompatibility or infection concerns) should be practiced by clinicians until further research and S-ICD detection algorithms are investigated.

Acknowledgement

The authors thank Dan Hlavacek for his assistance with S-ICD background information.

References

- Oswald H, Klein G, Struber M, Gardiwal A. Implantable defibrillator with left ventricular assist device compatibility. *Interact Cardiovasc Thorac Surg* 2009; 8:579–580.
- Kuhne M, Sakumura M, Reich S, et al. Simultaneous use of implantable cardioverter-defibrillators and left ventricular assist devices in patients with severe heart failure. *Am J Cardiol* 2010;105:378–382.
- López-Gil M, Fontenla A, Delgado JF, Rodríguez-Muñoz D. Subcutaneous implantable cardioverter defibrillators in patients with left ventricular assist devices: case report and comprehensive review. *Eur Heart J Case Rep* 2019; 3:ytz057.
- Sehatbakhsh S, Kushnir A, Chait R, Ghumman W. Electromagnetic interference between subcutaneous ICD and HeartMate II LVAD. *J Card Fail* 2018;24:S12.
- Gupta A, Subzposh F, Hankins SR, Kutalek SP. Subcutaneous implantable cardioverter-defibrillator implantation in a patient with a left ventricular assist device already in place. *Tex Heart Inst J* 2015;42:140–143.
- Raman AS, Shabari FR, Kar B, Loyalka P, Hariharan R. No electromagnetic interference occurred in a patient with a HeartMate II left ventricular assist system and a subcutaneous implantable cardioverter-defibrillator. *Tex Heart Inst J* 2016; 43:183–185.
- Saini H, Saini A, Leffler J, Eddy S, Ellenbogen KA. Subcutaneous implantable cardioverter defibrillator (S-ICD) shocks in a patient with a left ventricular assist device. *Pacing Clin Electrophysiol* 2018;41:309–311.
- Ahmed AS, Patel PJ, Bagga S, et al. Troubleshooting electromagnetic interference in a patient with centrifugal flow left ventricular assist device and subcutaneous implantable cardioverter defibrillator. *J Cardiovasc Electrophysiol* 2018;29:477–481.
- Migliore F, Leoni L, Bottio T, et al. Subcutaneous implantable cardioverter-defibrillator and left ventricular assist device: a safe and effective approach for refractory heart failure. *JACC Clin Electrophysiol* 2016;2:246–247.
- Pfeffer TJ, König T, Duncker D, et al. Subcutaneous implantable cardioverter-defibrillator shocks after left ventricular assist device implantation. *Circ Arrhythm Electrophysiol* 2016;9:1–3.
- Black-Maier E, Lewis RK, Barnett AS, et al. Subcutaneous implantable cardioverter-defibrillator troubleshooting in patients with left ventricular assist devices: a case series and systematic review. *Heart Rhythm* 2020; S1547-5271(20):30351–30359.
- Saeed D, Albert A, Westenfeld R, et al. Left ventricular assist device in a patient with a concomitant subcutaneous implantable cardioverter defibrillator. *Circ Arrhythm Electrophysiol* 2013;6:e32–e33.
- Afzal MR, Ahmed A, Prutkin JM, et al. Multicenter experience of concomitant use of left ventricular assist devices and subcutaneous implantable cardioverter-defibrillators. *JACC Clin Electrophysiol* 2018;4:1261–1262.
- Boudghene-Stambouli F, Boule S, Goeminne C, et al. Clinical implications of left ventricular assist device implantation in patients with an implantable cardioverter-defibrillator. *J Interv Card Electrophysiol* 2013;39:177–184.
- Foo D, Walker BD, Kuchar DL, et al. Left ventricular mechanical assist devices and cardiac device interactions: an observational case series. *Pacing Clin Electrophysiol* 2009;32:879–887.