

# Full mouth rehabilitation on a bilateral condylar fractured patient using orthognathic surgery and dental implant

Jee-Youn Park<sup>1</sup>, DDS, Kang-Min Ahn<sup>2</sup>, DDS, MSD, PhD, Joo-Hee Lee<sup>1</sup>, DDS, MSD, PhD, Hyun-Suk Cha<sup>1\*</sup>, DDS, MSD, PhD

<sup>1</sup>Division of Prosthodontics, <sup>2</sup>Division of Oral and Maxillofacial Surgery, Department of Dentistry, College of Medicine, University of Ulsan, Asan Medical Center, Seoul, Korea

**BACKGROUND.** Mandibular displacement is a common complication of condylar fracture. In the mandibular displacement due to condylar fracture, it is difficult to restore both esthetics and function without using orthognathic surgery. **CASE DESCRIPTION.** This clinical report described a full mouth rehabilitation in the patient with bilateral condylar fractures and displaced mandible using bilateral sagittal split ramus osteotomy (BSSRO) and simultaneous dental implant surgery. Mandibular position was determined by model surgery through the diagnostic wax up and restoration of fractured teeth. The precise amount of the mandibular shift can be obtained from the ideal intercuspation of remaining teeth. **CLINICAL IMPLICATION.** Mandibular displacement by both condylar fractures can be successfully treated by orthognathic surgery. Determination of occlusal plane and visualization from diagnostic wax up are mandatory for mandibular repositioning of model surgery. Stable occlusion and regular recall check up are needed for long-term outcome. [J Adv Prosthodont 2011;3:51-5]

**KEY WORDS.** Condylar fracture, Orthognathic surgery, Dental Implant, Full mouth rehabilitation

## INTRODUCTION

Rehabilitation after multiple facial bone fracture is quite a complicated procedure involving reduction of fractured bone fragment, restoration of original occlusion and injured tooth rehabilitation. Especially, both mandibular condyle fracture and multiple teeth avulsion were happened, restoration of the original occlusion is quite difficult even in specialist. Mandibular displacement after a condylar fracture causes complications such as anterior open bite, discrepancy between the centric relation and maximal intercuspation, mandibular posterior displacement, a decrease in the posterior facial height, and an increase in the anterior facial height.<sup>1</sup> Especially, secondary displacement of the mandible occurred because the lateral pterygoid muscle pulls the fractured part.

To treat mandibular displacement, conservative methods, such as intermaxillary fixation, and prosthetic methods or surgical methods, such as condylectomy and mandibular osteotomy, have been introduced.<sup>2-4</sup> It was reported that routine open reduction and fixation of condylar fracture was not indicated in the prevention of posttraumatic malocclusion.<sup>5</sup> Malocclusion can

be well corrected with orthognathic surgery rather than by restoring the temporomandibular joint.

Cases have been reported of the recovery of both aesthetics and function in mandibular displacement after a condylar fracture using orthognathic surgery.<sup>5</sup> In general, the amount of the mandible shift can be obtained from the ideal occlusion position of an upper and lower dentition. However, if a patient does not have enough teeth for the intercuspation due to multiple tooth fractures from the trauma, it is difficult to decide the mandibular position for orthognathic surgery and to fabricate a precise surgical guide for dental implant. In this case, it is necessary to make a reference for the mandibular positioning. Before the orthognathic surgery, fractured teeth should be restored according to ideal diagnostic wax up, and then three-dimensional mandibular positioning was determined using them as a reference.

This clinical report describes a full mouth rehabilitation using orthognathic surgery and dental implant on a patient with a bilateral condylar fractures and the mandibular positioning problem that was encountered due to multiple fractures and loss of teeth.

Corresponding author: Hyun-Suk Cha  
Department of Dentistry, College of Medicine, University of Ulsan, Asan Medical Center  
#388-1, Pungnap 2-Dong, Songpa-Gu, Seoul, 138-736, Korea  
Tel. 82 2 3010 3850; e-mail, chahyunsuk@hanmail.net  
Received February 24, 2011 / Last Revision March 5, 2011 / Accepted March 11, 2011

© 2011 The Korean Academy of Prosthodontics  
This is an Open Access article distributed under the terms of the Creative Commons Attribution Non-Commercial License (<http://creativecommons.org/licenses/by-nc/3.0>) which permits unrestricted non-commercial use, distribution, and reproduction in any medium, provided the original work is properly cited.

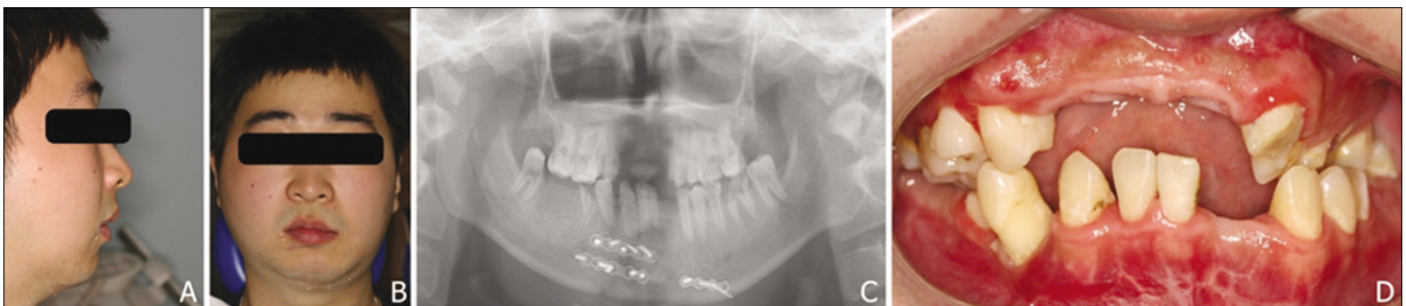
## CLINICAL REPORT

A 22-year-old male patient was referred to the Department of Oral Surgery and Prosthodontics of Asan Medical Center, 5 months after a fall accident. Before he referred to our department of prosthodontics, he underwent open reduction of mandibular fracture and closed reduction of bilateral condylar fracture, and hip joint surgery at the other hospital. He had been healthy before the accident and had not any special medical history.

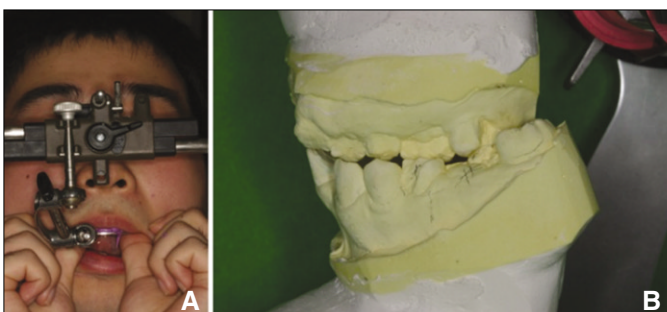
Through physical examination the pre-operation findings were as follows: there were missing #13,#12,#11,#21,#22,#31,#32,#46 teeth and fractured #15,#14,#23,#24,#25,#26,#27,#35,#36,#45,#47 teeth. Skeletal class II tendency was presented with posterior and left lateral displacement of mandible. There was a mouth opening limitation. Maximum mouth opening was 25 mm. Considering the posterior deviation of mandible, actual opening was just 15 mm. With the mouth opening movement there was left side deviation of mandible because of ankylosed his left condyle. There was no specific pain or symptom on his temporomandibular joint with spontaneous movement (Fig. 1).

Impressions of both arches were made using an irreversible hydrocolloid impression material (Aroma Fine DF III, GC, Tokyo, Japan) for diagnostic cast. Facebow transfer was performed to mount maxillary cast (Fig. 2). The first diagnostic wax up was performed at an ideal position of the maxillary and mandibular arch using an anatomic landmark and the adjacent natural teeth (Fig. 3). The lip support, which was checked intra-orally, was used to decide the position of the maxillary anterior teeth. A retromolar pad was used to establish the mandibular occlusal plane. Based on this wax up model, oral examination, radiographs, BSSRO surgery for the displaced mandible and extraction of the hopeless teeth (#14, #15, #36, #45, #47) were planned. Complete crowns of remaining fractured teeth (#23, #24, #25, #26, #27, #35) and dental implant for missing area were also planned. Full veneer restorations for the remaining fractured teeth should be performed prior to BSSRO surgery, to use them as a reference.

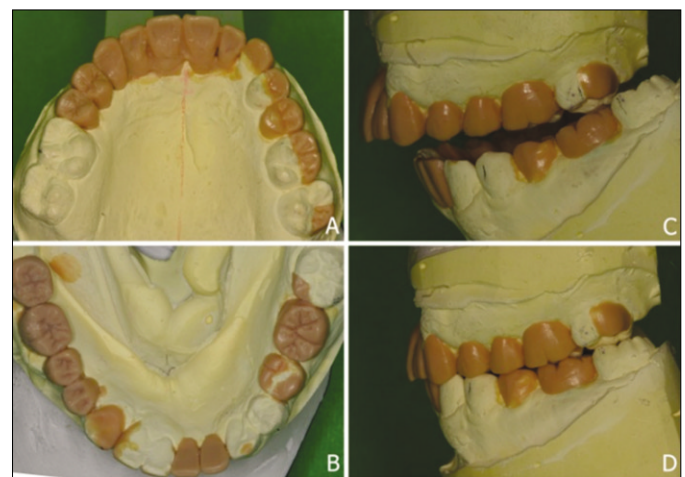The maxillary right premolar, the mandibular left first molar, and the mandibular right first molar and third molar were extracted under local anesthesia. Before the prosthodontic treatment, total periodontal treatment and oral hygiene instruction (OHI) were performed and during the total treatment, periodic



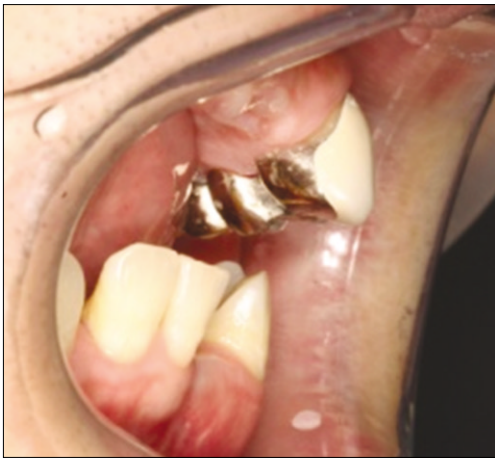**Fig. 1.** Initial facial photos and radiograph. A: Lateral facial profile, B: Frontal facial profile, C: Panoramic radiograph, D: Intraoral frontal view.



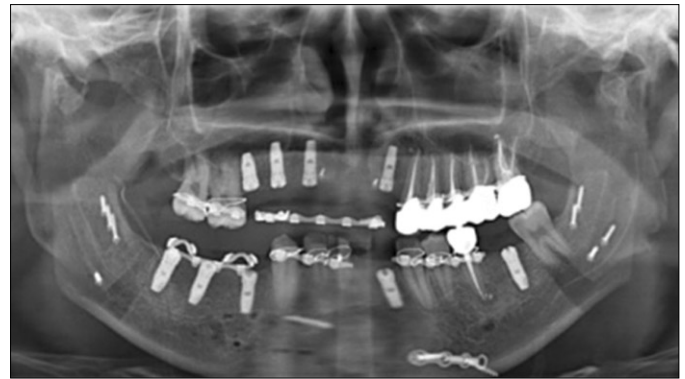
**Fig. 2.** Facebow transfer A and diagnostic model mounted on a semi-adjustable articulator B.



**Fig. 3.** Diagnostic wax up and model surgery. A: Occlusal view of Maxilla, B: Occlusal view of Mandible, C: Initial status of mounted model, D: Remounting of lower cast to simulate BSSRO.



**Fig. 4.** Initial overbite and overjet relationship with try in of final metal-ceramic crown.



**Fig. 5.** Panoramic radiograph after implant and BSSRO surgery.

scaling with three-month intervals was performed. Root canal treatments and clinical crown lengthening for the fractured teeth (#23, #24, #25, #26, #27, #35) were performed. After the endodontic treatment, the lost part of the teeth was restored with a post and a core (ParaPostXT, whaledent, New Jersey, USA / LuxaCore, DMG, Hamberg, Germany).

Then a definitive impression was made using polyvinylsiloxane impression material (Honigum, DMG, Hamberg, Germany). The upper and lower working cast for the complete crown were cross mounted on the articulator to the diagnostic wax up cast. Complete crowns were fabricated and intraoral try in procedure was performed (Fig. 4).

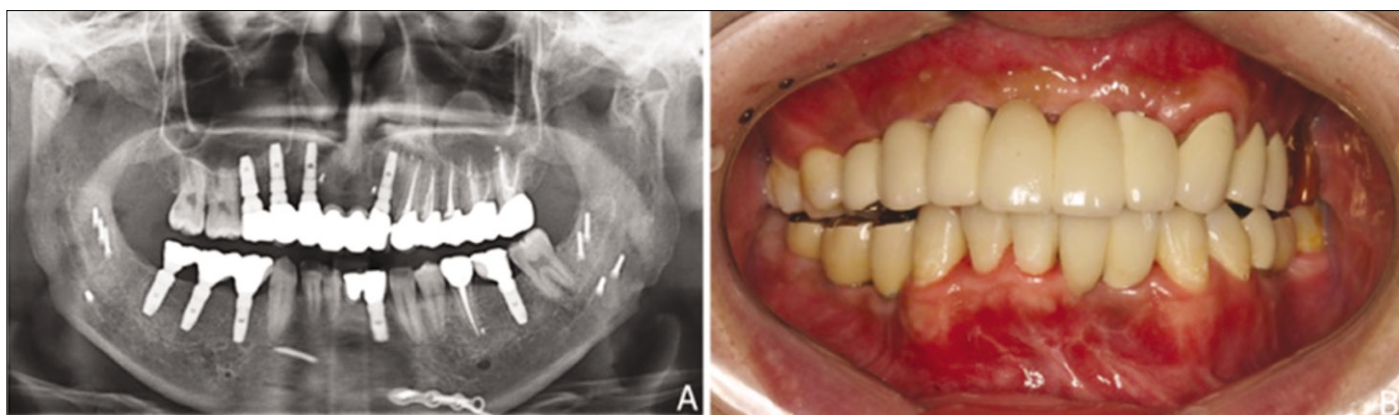
One day before the surgery, the ceramic metal restorations were cemented using glass ionomer cement (FujiCEM, GC, Tokyo, Japan), and impressions of both arches were made with irreversible hydrocolloid impression material (Aromafine, GC Corp., Tokyo, Japan). With the new casts, the second wax up model was made based on the first diagnostic wax up. Two surgical guides were required, because the implant and BSSRO surgeries were planned to be performed simultaneously. The first surgical guide was fabricated for the precise implant placement by duplicating the second wax up cast. Subsequently, the model surgery with the wax up casts was performed to determine the position of the mandible. The second surgical guide for the BSSRO surgery was fabricated on the mounted cast after the model surgery. For the fixation of right posterior region, arch bar was embedded in the lower right and upper anterior part of surgical guide.

Under general anesthesia, BSSRO was performed according to the prefabricated surgical stent and with guides of left posterior teeth occlusion. The amount of mandibular advancement was 6 mm on the right and 8 mm on the left. The mandible was fixed with four screws in each side. Right side of mandible was down positioned to gain interarch

space. Symphysis fixation plates and screws were removed. Nine dental implants (Implantium, Dentium, Seoul, Korea) were installed in the maxilla and mandible using surgical stent with block bone grafting procedure performed in the anterior maxilla simultaneously (Fig. 5). Intravenous antibiotics and analgesics were prescribed to the patient and patient controlled analgesia was connected to the main fluid to control postoperative pain. The patient was advised to have a soft diet with a tube for two weeks and to rinse his oral cavity with a 0.12% chlorhexidine gluconate solution several times a day. After 3 weeks, the maxillomandibular fixation was released and the patient healed well without particular complication. Provisional removable partial denture prosthesis was inserted 4 weeks after the surgery. The occlusion was checked every other week until the fixed dental prosthesis was delivered. The stability of the occlusion was confirmed using this process.

Four months later, second-stage surgery was performed and healing abutments were placed. And fixed type implant provisional restorations were delivered. In the provisional restoration, a group functioned occlusion was made using implants around the canine and bicuspid on the right side, and a canine protected occlusion was made using the remaining maxillary canine on the left side. Stable maintenance of the occlusal contact was confirmed during the follow up visits one and two months later. A provisional restoration model was mounted via facebow transfer. In addition, condylar guidance was set up by check bite on the provisional restoration. The customized anterior guide table was manufactured using the mounted provisional restoration model. Then the master cast of the maxilla and mandible were cross mounted, by which the final fixed implant prosthesis of the maxilla and mandible was manufactured. The lip support and midline of the provisional restoration were also reproduced.

The all implant abutment screws were tightened to 25 Ncm



**Fig. 6.** A: Panoramic radiograph after one year later from delivery of prosthesis, B: Frontal view of definitive fixed prosthesis at one year recall check up.

as manufacturer's recommendation. Then, cement type implant prosthesis were cemented using zinc phosphate cement (Elite cement, GC, Tokyo, Japan) except the left mandibular first molar. The left mandibular first molar was restored using a screw retained implant prosthesis and screw hole filled with stopping and composite resin. The final implant prosthesis of the maxilla and mandible was completed seven months after the implants were installed. A periodic recall check up was made to perform occlusal adjustments one, two, three, and six months after the installation of the final implant prosthesis. The patient has been followed for one year since the delivery of the final dental prosthesis with no remarkable complications and a fair occlusal relationship has been maintained. There was no observed open bite tendency. The current maximum mouth opening of the patient was 40 mm, and no abnormal symptoms of a temporomandibular joint as joint pain or clicking sounds were observed. The patient was satisfied with the current functional and esthetic aspects of his treatment (Fig. 6).

## DISCUSSION

Implants and a fixed dental prosthesis are necessary for the patient who lost majority of his teeth due to facial trauma. But, in case of the condylar fractured patient, sometimes stable occlusion can not be achieved only with the prosthodontic treatment because of posterior displaced mandible. Orthognathic surgery is mandatory for rehabilitation of function and esthetics.

In a situation where stable occlusion could not be obtained through the teeth, a first wax up was performed at each arch, as might be ideal with a reference to the anatomic landmark, and a model surgery was performed using it. After the surgery, the function and esthetics of the fixed dental prosthesis were found satisfactory. This means that the position of the placed implants and the amount of mandibular movement during the surgery were precise, as planned before the surgery.

With a shortage of sources for stable intermaxillary fixation, the following factors seem to make the stable intermaxillary fixation possible. First, before the surgery, the natural teeth that could be restored were treated using the final dental prosthesis. Therefore, the fixation was performed through at least the left remaining natural teeth after the surgery. Second, temporary dentures were fabricated as soon as possible and placed after the removal of the arch bar. In addition, the temporary dentures were continually monitored before the final implant of the dental prosthesis to stabilize the occlusion. Through this, it was confirmed that the recurrence of the pre-surgical intermaxillary relationship can be prevented, and the post-surgical intermaxillary relationship was identical to the relationship planned before the surgery. Third, the implants were simultaneously placed with the orthognathic surgery by determining the position of the implant on a diagnostic wax up prior to the orthognathic surgery. As a result, the total treatment period was shortened and the possibility of the recurrence of the pre-surgical intermaxillary relationship due to the delay in the prosthetic treatment was minimized. Consequently, the full mouth prosthetic restoration was completed thirteen months after the patient's visit to the hospital, and six months after the orthognathic and implant surgeries. It seems that if the restoration of the teeth and the implant placement were performed in this order after the orthognathic surgery, the treatment period would be longer and it might be more difficult to establish a stable occlusion relationship and prevention of the recurrence of the pre-surgical intermaxillary relationship.

Türp *et al.*<sup>6</sup> reported that the use of a conservative approach to treat condylar or subcondylar fractures will produce in most cases a favorable functional long-term outcome. In this study, the patient with a condylar fracture underwent closed reduction, followed by orthognathic surgery, to correct the location of his displaced due to the fractures mandible.<sup>7</sup> Becking *et al.* also reported that when 21 patients with a condylar frac-

ture coupled with malocclusion were monitored for one year after orthognathic surgery, they showed stable results clinically and radiographically.<sup>7</sup> More detailed data over a longer period are required, though. Therefore, continuous monitoring of this case is required. So far, one and a half years have passed since the conduct of the surgery, and the fair occlusal relationship has been maintained. This fair relationship is expected to be further maintained.

## CONCLUSION

The condyle fractured patient with a mandibular displacement can be successfully treated by orthognathic surgery. The precise amount of mandibular reposition was determined by model surgery through the diagnostic wax up of ideal occlusion and the intercuspation of remaining fractured teeth. Precise occlusion should be achieved to ensure predictable outcome and stable mandibular position.

## REFERENCES

1. Kazanjian VH, Converse JH. The surgical treatment of facial injuries. 3rd ed: Baltimore; Williams & Wilkins; 1974.
2. Spitzer WJ, Vanderborght G, Dumbach J. Surgical management of mandibular malposition after malunited condylar fractures in adults. *J Craniomaxillofac Surg* 1997;25:91-6.
3. Hinds EC, Parnes EI. Late management of condylar fractures by means of subcondylar osteotomy: reports of cases. *J Oral Surg* 1966;24:54-9.
4. Harper R, Weinberg S. Treatment of malunited, unusually displaced bilateral condylar fractures: report of case. *J Oral Surg* 1978;36:716-9.
5. Rubens BC, Stoelinga PJ, Weaver TJ, Blijdorp PA. Management of malunited mandibular condylar fractures. *Int J Oral Maxillofac Surg* 1990;19:22-5.
6. Türp JC, Stoll P, Schlotthauer U, Vach W, Strub JR. Computerized axiographic evaluation of condylar movements in cases with fractures of the condylar process: a follow up over 19 years. *J Craniomaxillofac Surg* 1996;24:46-52.
7. Becking AG, Zijdeveld SA, Tuinzing DB. Management of post-traumatic malocclusion caused by condylar process fractures. *J Oral Maxillofac Surg* 1998;56:1370-4.