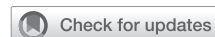

# Hybrid repair of acute type A aortic dissection with visceral malperfusion syndrome



Buqing Ni, MD, Jiayi Gu, MD, Minghui Li, MD, and Yongfeng Shao, MD, Nanjing, China

From the Department of Cardiovascular Surgery, The First Affiliated Hospital of Nanjing Medical University, Nanjing, China.

This work was funded by the Priority Academic Program Development of Jiangsu Higher Education Institutions (JX10231801).

Disclosures: The authors reported no conflicts of interest.

The *Journal* policy requires editors and reviewers to disclose conflicts of interest and to decline handling or reviewing manuscripts for which they may have a conflict of interest. The editors and reviewers of this article have no conflicts of interest.

Received for publication Nov 3, 2020; accepted for publication Nov 18, 2020; available ahead of print Nov 26, 2020.

Address for reprints: Yongfeng Shao, MD, Department of Cardiovascular Surgery, The First Affiliated Hospital of Nanjing Medical University, 300 Guangzhou Rd, Nanjing 210029, China (E-mail: [yongfengshao30@hotmail.com](mailto:yongfengshao30@hotmail.com)).

JTCVS Techniques 2021;7:22-4

2666-2507

Copyright © 2020 The Authors. Published by Elsevier Inc. on behalf of The American Association for Thoracic Surgery. This is an open access article under the CC BY-NC-ND license (<http://creativecommons.org/licenses/by-nc-nd/4.0/>).

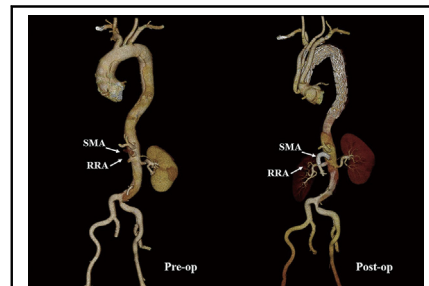
<https://doi.org/10.1016/j.jtc.2020.11.014>

Video clip is available online.

Acute type A aortic dissection (ATAAD) complicated by mesenteric malperfusion is the most life-threatening condition. According to the International Registry of Aortic Dissection database, in-hospital mortality is 63.2%.<sup>1</sup> Conventional open surgical repair can protect the patient from aortic rupture and resolve the dynamic malperfusion. However, if the end-organ damage occurs due to prolonged ischemia or static compression of the superior mesenteric artery (SMA), the mesenteric malperfusion is rarely relieved by open repair alone. For these reasons, some authors recommended interventional therapy first to alleviate the mesenteric malperfusion followed by delayed open surgical repair; however, this approach may also carry the risk of aortic rupture during the interim.<sup>2,3</sup> Here, we report a new repair procedure through one-stop hybrid approach (Video 1).

## CASE PRESENTATION

A 51-year-old man was admitted to our institution with chest and abdominal pain, as well as dyspnea for 12 hours. The patient had hypertension for 10 years and unregulated oral antipulse treatment. Results of a computed tomographic angiography (CTA) scan demonstrated type A aortic dissection associated with bilateral pulmonary edema, occluded right renal artery (RRA), and SMA (Figure 1, A-D). Physical examination revealed the disappearance of bowel sounds without tenderness. Arterial



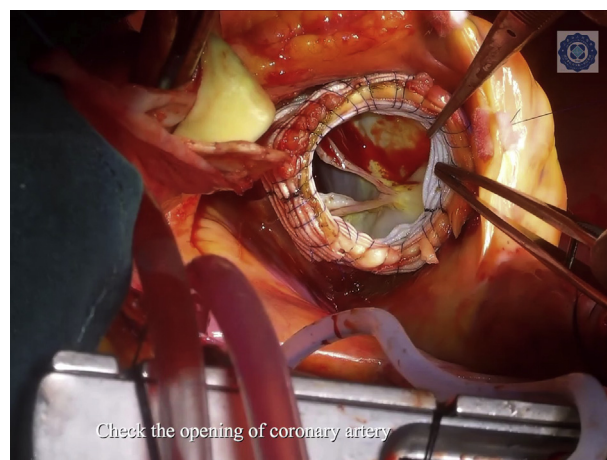
CTA shows before and after repair of aortic dissection with visceral malperfusion.

## CENTRAL MESSAGE

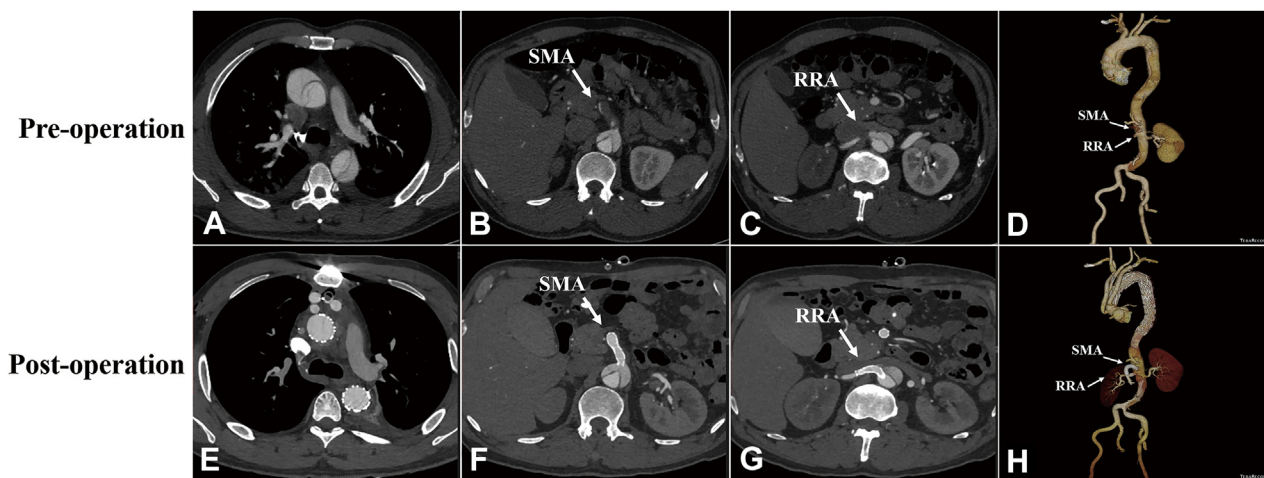
One-stop hybrid approach may address both of the issues of aortic rupture and malperfusion simultaneously, facilitating repair aortic dissection with visceral malperfusion syndrome.

See Commentaries on pages 25 and 27

blood gas analysis showed an arterial oxygen tension of 52 mm Hg and lactate of 3.5 mmol/L. Blood test showed renal dysfunction with  $K^+$  of 6.2 mmol/L and creatinine of 189  $\mu$ mol/L. Transesophageal echocardiography



VIDEO 1. One-stop hybrid repair of acute type A aortic dissection complicated with multiple visceral malperfusion. Video available at: [https://www.jtcvs.org/article/S2666-2507\(20\)30696-9/fulltext](https://www.jtcvs.org/article/S2666-2507(20)30696-9/fulltext).



**FIGURE 1.** Images of preoperation and postoperation. A, Preoperative CTA shows type A aortic dissection with intimal tear in ascending aorta. B, Thrombus in the false lumen of SMA with compression of true lumen. C, Thrombus in the RRA with malperfusion. D, 3-dimensional reconstruction of CTA shows type A aortic dissection with occluded SMA and RRA. E, Postoperative CTA reveals complete isolation of proximal dissection with enlarged true lumen and thrombus formation in false lumen. F, Patent stent with enlargement of true lumen of SMA. G, Patent stent with normal perfusion of RRA. H, 3-dimensional reconstruction of CTA shows complete isolation of proximal aortic dissection with patent supra arch and visceral artery branches. SMA, Superior mesenteric artery; RRA, right renal artery.

identified severe aortic insufficiency. Due to the fact that both SMA and RRA had static malperfusion, central aortic repair would not resolve this problem, so we decided to apply one-stop hybrid approach for repair. The patient provided informed consent for the publication of the study data.

### SURGICAL TECHNIQUE AND OUTCOMES

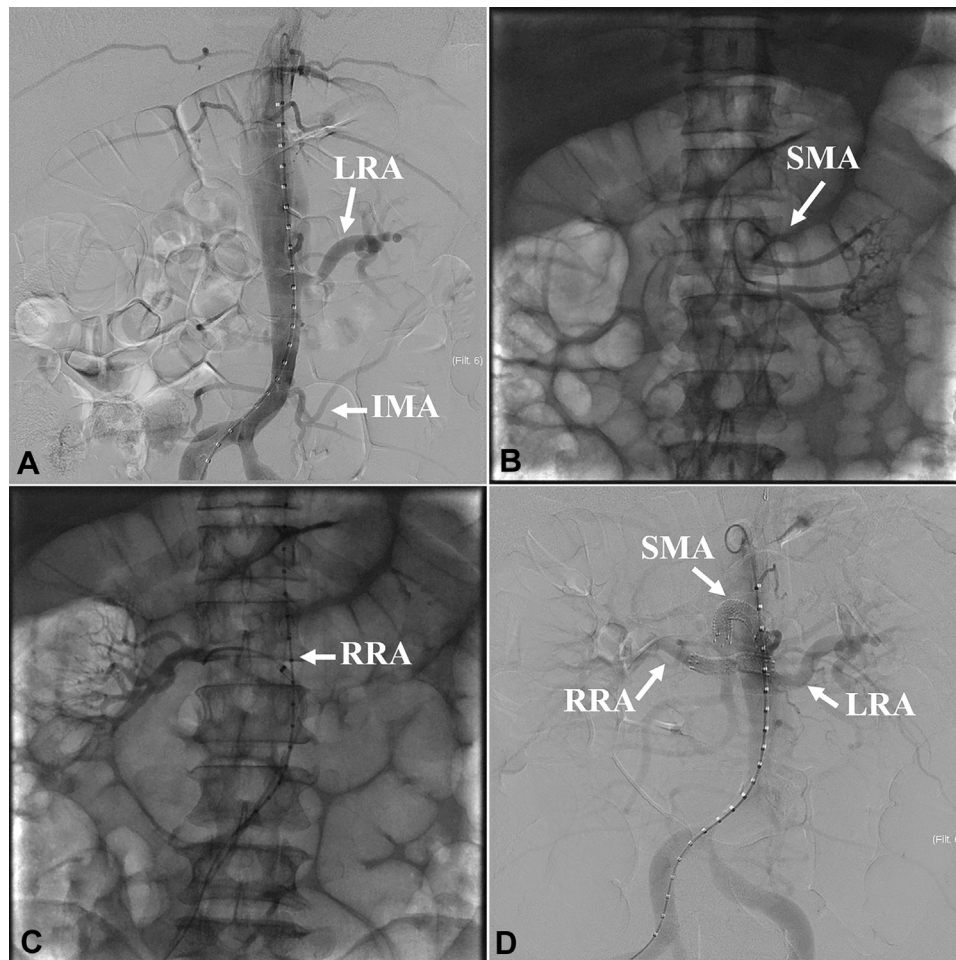
The surgery was conducted in a hybrid setting operation room. Under general anesthesia with single lumen endotracheal tube, the patient underwent median sternotomy, surgical exposure of right common femoral artery, and supra-aortic arch branches. After systemic heparinization to achieve an activated clotting time >480 seconds, abdominal aortography confirmed aortic dissection with occlusion of proximal SMA and RRA and dynamic compression of left iliac common artery (Figure 2, A). A 5-Fr Cobra catheter (Cordis Corporation, Miami Lakes, Fla) and 0.035-inch guidewire were introduced via right femoral approach for superselection of occluded SMA and RRA (Figure 2, B and C). Exchanging into a stiff guidewire, a 10 × 60-mm and an 8 × 40-mm Absolute self-expandable bare stent (Abbott Vascular, Temecula, Calif) were implanted into SMA and RRA, respectively, then followed with postdilation. Aortography revealed the SMA and RRA were patent (Figure 2, D). Cardiopulmonary bypass was established via cannulation of innominate artery, right common femoral artery, and right atrium. Systemic cooling was started to a nasopharyngeal temperature of 28°C. The ascending aorta was clamped and longitudinally incised. Myocardial protection was achieved with antegrade Del Nido cardioplegia

infusion. The ascending aorta was transected at the level of 1.5 to 2 cm above commissures. The aortic root was carefully mobilized and reconstructed with a modified sandwich technique using a vascular graft. After completion of aortic root repair, we clamped the proximal innominate artery followed by translocation of aortic crossclamp from ascending aorta to the interval between left common carotid artery and innominate artery. The distal ascending aorta was transected and anastomosed to the 4-branched graft with a reserved 3-cm length landing zone. Then, the proximal anastomosis was performed to the aortic root and followed by end-to-end anastomoses of branched graft to the arch vessels with sequential clamping. When cardiopulmonary bypass was weaned, a 32-24-200 mm and 30-26-160 mm Ankura Stent Graft (Lifetech Scientific Corp, Ltd, Shenzhen, China) were deployed via right femoral artery from proximal to distal sequentially.

The patient was extubated at postoperative 12 hours and discharged on postoperative day 9 without complications. The CTA scan on postoperative day 7 showed proximal dissection was isolated completely without endoleak and occluded visceral branches (Figure 1, E-H).

### DISCUSSION

Proximal aorta rupture and mesenteric ischemia are the 2 related lethal issues in patients with ATAAD and mesenteric malperfusion. Uncomprehensive consideration of these issues will most likely result in death. For end-stage malperfusion such as increasing lactate or pneumatosis in the wall of the intestine on computed tomography scan, staged watchful wait strategy is undoubtedly a wise choice,



**FIGURE 2.** Angiography of before and after endovascular intervention. A, Abdominal aortography shows double-lumen aorta with patent LRA and IMA and occlusion of SMA and RRA. B, Superselection of distal SMA. C, Superselection of distal RRA. D, After implantation of the bare stent, the aortography shows patent SMA and RRA. LRA, Left renal artery; IMA, inferior mesenteric artery; SMA, superior mesenteric artery; RRA, right renal artery.

avoiding futile central aortic repair. However, for the early stage of SMA malperfusion syndrome, we don't think the "natural selection" is the fate of these kinds of patients. To overcome this limitation, one-stop hybrid approach may address both of the issues of aortic rupture and malperfusion simultaneously.<sup>4</sup> In the hybrid operation room, we initiated with interventional technique to restore the blood flow of malperfused organs, then subsequently performed aortic root repair, debranching total arch replacement and retrograde stent graft implantation. The strength of this approach is the ability to relieve visceral malperfusion first and to prevent aortic rupture subsequently. Another point in this particular approach is that circulation arrest could have been avoided by the use of the arch hybrid debranching technique so that second-time visceral organ ischemia/reperfusion injury does not occur. In conclusion, a one-stop

hybrid approach is a reasonable treatment option in ATAAD presenting with an early stage of visceral malperfusion syndrome.

### References

1. Di Eusanio M, Trimarchi S, Patel HJ, Hutchison S, Suzuki T, Peterson MD, et al. Clinical presentation, management, and short-term outcome of patients with type A acute dissection complicated by mesenteric malperfusion: observations from the International Registry of Acute Aortic Dissection. *J Thorac Cardiovasc Surg.* 2013;145:385-90.
2. Leshnowar BG, Keeling WB, Duwayri YM, Jordan WD Jr, Chen EP. The "thoracic endovascular aortic repair-first" strategy for acute type A dissection with mesenteric malperfusion: initial results compared with conventional algorithms. *J Thorac Cardiovasc Surg.* 2019;158:1516-24.
3. Yang B, Norton EL, Rosati CM, Wu X, Kim KM, Khaja MS, et al. Managing patients with acute type A aortic dissection and mesenteric malperfusion syndrome: a 20-year experience. *J Thorac Cardiovasc Surg.* 2019;158:675-87.
4. Kim JB. Hybrid approach as the rescuer of malperfusion syndrome in acute type I aortic dissection: a new hope? *Semin Thorac Cardiovasc Surg.* 2019;31:749-50.