

Severe Agitation as an Unusual Presentation of Multisystem Inflammatory Syndrome in Children

Mohamed A. Ghamry¹, Korlos Salib², Shereen Henin³, Rehab Salah⁴, Monica Dobs⁵

Review began 07/25/2022

Review ended 07/31/2022

Published 08/02/2022

© Copyright 2022

Ghamry et al. This is an open access article distributed under the terms of the Creative Commons Attribution License CC-BY 4.0., which permits unrestricted use, distribution, and reproduction in any medium, provided the original author and source are credited.

1. Pediatrics, Al Salam Hospital, Ministry of Health, Port Said, EGY 2. General Practice, El-Demerdash Hospital, Cairo, EGY 3. Internal Medicine/Pediatrics, California Institute of Behavioral Neurosciences and Psychology, Fairfield, USA 4. Cardiology, Faculty of Medicine, Benha University, Benha, EGY 5. Pediatrics, University of Florida College of Medicine, Jacksonville, USA

Corresponding author: Mohamed A. Ghamry, 01123105555m@gmail.com

Abstract

Multisystem inflammatory syndrome in children (MIS-C) is a rare hyperinflammatory syndrome that mainly affects children after a primary infection with coronavirus disease 2019 (COVID-19), with the possibility of severe and lethal complications. We report a case of a unique presentation of MIS-C in a four-year-old boy who presented with severe agitation, muscle spasms, and two days of fever. Other findings consistent with MIS-C were revealed later, and he was managed with intravenous immunoglobulin (IVIG) and steroids. He showed a dramatic response of improvement and was discharged. This case report aimed to raise health professionals' awareness about the atypical presentations of MIS-C and the importance of early diagnosis, treatment, and follow-up MIS-C cases to avoid complications affecting children's lives.

Categories: Emergency Medicine, Neurology, Pediatrics

Keywords: covid-19, right coronary artery (rca), high fever, agitation, pediatric sepsis, pediatrics, post sars-cov-2 complication, altered mental state, multi-system inflammatory syndrome in children (mis-c)

Introduction

Infection with coronavirus disease 2019 (COVID-19) has demonstrated a broad spectrum of clinical manifestations, ranging from asymptomatic to severe acute respiratory distress syndrome and death [1]. Although children are susceptible to COVID-19 infection as adults, they have a much lower rate of symptomatic primary infection [1]. However, a small percentage of children can develop multisystem inflammatory syndrome in children (MIS-C), which has been defined by the Centers for Disease Control and Prevention (CDC) and the World Health Organization [1]. The MIS-C diagnosis can be challenging due to its polymorphous presentation, so it requires a high index of suspicion to diagnose this syndrome quickly [1].

Case Presentation

A four-year-old male child with no past medical, psychiatric, or hospitalization history was admitted to the pediatric emergency service with severe agitation and muscle spasms as can be seen in Video 1.

VIDEO 1: Severe agitation and muscle spasms shown in a case of child affected with "multisystem inflammatory syndrome in children" placed on unfit oxygen mask

View video here: <https://vimeo.com/728817399>

He was well two days ago when he developed a fever recorded up to 40°C, relieved with cold compresses and acetaminophen but returns every six hours. No history of recent illness, contact with a diseased person, or traveling. In the physical examination, he was alert, agitated, and febrile to 40°C with tachycardia and hypotension concerning shock. Laboratory studies are significant for low white blood cell count (2.9 k/ μ L) with low lymphocytes count (0.4 k/ μ L), high C-reactive protein (96 mg/dL), high creatinine (1.2 mg/dL), high blood urea nitrogen (30 mg/dL), elevated erythrocyte sedimentation rate (70 mm/h), raised ferritin (1330 ng/mL), high D-dimer (6 mg/L), and high CK-MB (137 IU/L). SARS-CoV-2 polymerase chain reaction testing was negative. Chest computed tomography (CT) showed bilateral lung opacities (Figure 1). He was placed on a non-rebreathing oxygen mask. He received fluid resuscitation, antipyretic, empiric antibiotics, and a pediatrics-neuropsychiatric consultation.

How to cite this article

Ghamry M A, Salib K, Henin S, et al. (August 02, 2022) Severe Agitation as an Unusual Presentation of Multisystem Inflammatory Syndrome in Children. *Cureus* 14(8): e27621. DOI 10.7759/cureus.27621

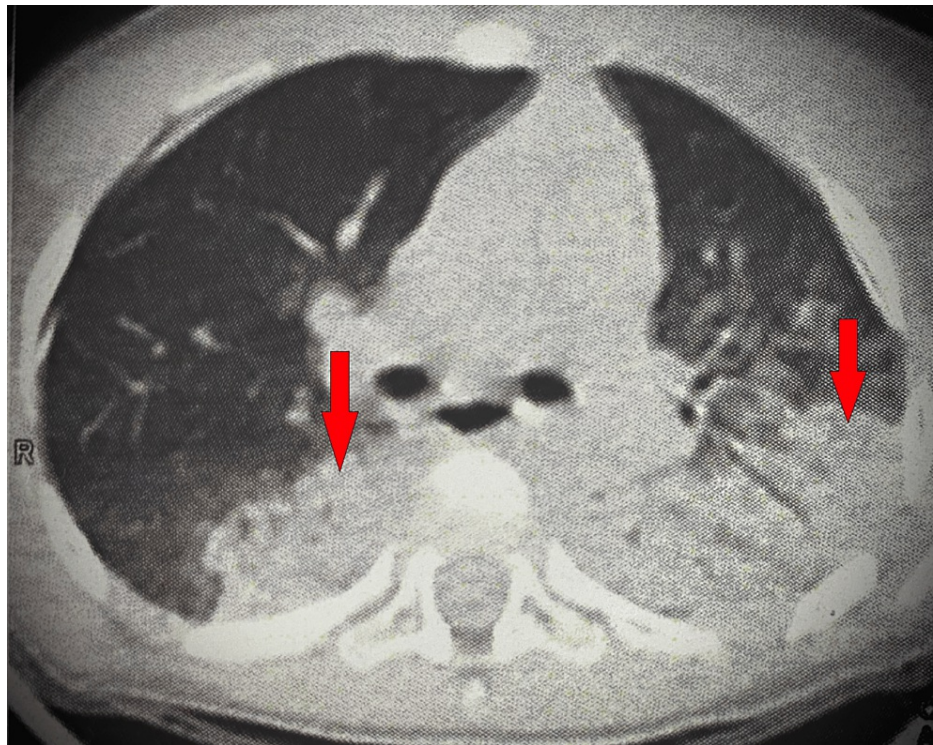


FIGURE 1: Chest CT showed bilateral lung opacities (arrows show examples of the opacities)

He was admitted to the pediatric intensive care unit, where he was placed on a high-flow nasal cannula and required initiation of norepinephrine to support falling blood pressure. After one hour, the patient develops attacks of muscle spasms and opisthotonos position with agitation and fluctuating level of consciousness. Soft wrist restraints were temporarily applied. Brain CT and magnetic resonance imaging showed no abnormalities. Upon thorough infection workup, the patient is confirmed to have COVID-19 immunoglobulin G (IgG)-positive, with the exclusion of other infections. Echocardiogram showed a left ventricular ejection fraction of 58% and mild right coronary artery (RCA) dilation (z-score < 2.5).

The patient met MIS-C CDC diagnostic criteria with clinical and laboratory findings. The patient was diagnosed with MIS-C, and treatment was started immediately. A single dose of intravenous immunoglobulin (IVIG) (2 g/kg), a five-day course of methylprednisolone (2 mg/kg/day), aspirin (4 mg/kg/day), and anticoagulation with low-molecular-weight heparin were started. Dramatic clinical response happened as the patient's fever, agitation, blood pressure, and level of consciousness improved to normal at the 12th hour after IVIG treatment, and norepinephrine was discontinued. In the follow-up, respiratory distress improved, inflammatory markers regressed, and RCA returned to normal in the echocardiogram. Antibiotherapy was discontinued on the eighth day of hospitalization, as no growth was detected in blood, cerebrospinal fluid, urine, and stool cultures. The patient was discharged at the end of the ninth day to continue aspirin therapy, and follow-up instructions were given.

Discussion

A new entity termed MIS-C associated with COVID-19 was described by CDC in the United States on 14th May 2020 [2]. CDC defines MIS-C as a clinically severe illness requiring hospitalization in an individual aged <21 years proved to have current or recent SARS-CoV-2 infection or exposed to suspected or confirmed COVID-19 case within four weeks who presented with fever (>38.0°C for ≥24 hours), inflammatory marker elevation, and multisystem (>2) organ dysfunction, and in the absence of an alternative likely explanation [2].

MIS-C presentation involving four organ systems or more occurred in >70% of patients, with >50% admitted to an intensive care unit during their hospital stay (Table 1) [3]. Most common symptoms and signs are fever > 38°C (100%), gastrointestinal symptoms (53-92%), mucocutaneous involvement (70-74%), and hypotension (49-51%) [3]. Cardiac involvement is reported in 80% of MIS-C, including ventricular dysfunction, coronary artery dilation and aneurysms, arrhythmia, and conduction abnormalities [3,4]. Neuropsychiatric presentations were also reported, including irritability, headache, and confusion [5]. Hutchison et al. reported agitation and fluctuating awareness levels during an adolescent boy's MIS-C disease course. However, Hutchison et al. suggested multiple explanations for these symptoms. They then

outweighed the probability that the effect of high-dose corticosteroid therapy may cause these symptoms because the neuropsychiatric symptoms had appeared after initiating it and disappeared after discontinuing it [5]. In this case report, we report agitation as an initial presentation of MIS-C with a fluctuating level of consciousness before corticosteroid therapy initiation, which excludes that it may be secondary to corticosteroid therapy. The effect of COVID-19 infection or MIS-C on the nervous system remains unclear, and the neurological manifestations may be primary, secondary, or both [5].

Presenting symptoms (N)	The median age in years	Total number of cases	Country	Reference
Fever (10), conjunctivitis (5), rash (5), cervical lymphadenopathy (7), mucosal changes (4), diarrhea (6)	7.5	10	Italy	Verdoni et al. [6]
Fever (3), cough (2), dyspnea (2), sore throat (2), vomiting (2), abdominal pain (2)	11	3	Switzerland	Dallan et al. [7]
Fever, rash, irritability, red lips	0.3	1	India	Acharya et al. [8]
Fever (21), Rash (15), lip changes (15), conjunctivitis (17), diarrhea (20), vomiting (20), abdominal pain (21), irritability (12), headache (6), confusion (6)	7.9	21	France	Toubiana et al. [9]
Fever (58), abdominal pain (31), diarrhea (30), rash (30), vomiting (26), conjunctivitis (26), headache (15), respiratory symptoms (12), lymphadenopathy (9), swollen hands and feet (9), sore throat (6), confusion (5)	9	58	United Kingdom	Whittaker et al. [10]
Fever (99), chest pain (11), abdominal pain (60), nausea or vomiting (57), diarrhea (49), rash (59), swollen hands or feet (9), conjunctivitis (55), mucosal changes (27), headache (29), confusion or altered mental status (2), musculoskeletal pain (20), sore throat (16), congestion (13), cough (31), dyspnea (19), wheezing (1)	0-20	99	United States of America	Dufort et al. [11]
Fever, agitation, muscle spasms, fluctuating level of consciousness	4	1	Egypt	This study

TABLE 1: Comparison between presenting clinical symptoms in children with MIS-C around the world

MIS-C: multisystem inflammatory syndrome in children

IVIg has been shown to be effective in treating MIS-C. Corticosteroids can be used based on the case and the followed guidelines. However, MIS-C management is multidisciplinary, and treatment should be individualized according to the system involved [12]. Long-term follow-up is essential, especially in children who have experienced complications [12]. The successful response for IVIg in treating MIS-C and Kawasaki disease suggests that antibodies likely have a role in the pathophysiology, but the exact role of antibodies is still unknown [13].

Conclusions

MIS-C is a serious complication of COVID-19 infection, and health care providers should have a high index of suspicion for MIS-C, especially if multiple systems are affected, history of infection or exposure to COVID-19, laboratory evidence of COVID-19 infection or antibodies, or unusual presentations in a feverish child. Neuropsychiatric manifestations can be the first presentation of this syndrome. Further studies about the pathogenesis of MIS-C will be beneficial in understanding the nature of the disease. As this is a new pediatric syndrome, further research and case reports are needed to assist other clinicians to early diagnose the disease and contribute to the most effective preventive and therapeutic strategies to save children's lives and keep them healthy.

Additional Information

Disclosures

Human subjects: Consent was obtained or waived by all participants in this study. **Conflicts of interest:** In compliance with the ICMJE uniform disclosure form, all authors declare the following: **Payment/services info:** All authors have declared that no financial support was received from any organization for the submitted work. **Financial relationships:** All authors have declared that they have no financial

relationships at present or within the previous three years with any organizations that might have an interest in the submitted work. **Other relationships:** All authors have declared that there are no other relationships or activities that could appear to have influenced the submitted work.

References

1. Mahajan N, Chang HT, Leeman R, Manalo R, Glaberson WR: Case of multisystem inflammatory syndrome in children presenting as fever and abdominal pain. *BMJ Case Rep.* 2020, 13: [10.1136/bcr-2020-237306](https://doi.org/10.1136/bcr-2020-237306)
2. Multisystem inflammatory syndrome in children (MIS-C) associated with coronavirus disease 2019 (COVID-19). (2020). Accessed: May 14, 2020: <https://emergency.cdc.gov/han/2020/han00432.asp>.
3. Giacalone M, Scheier E, Shavit I: Multisystem inflammatory syndrome in children (MIS-C): a mini-review . *Int J Emerg Med.* 2021, 14: [10.1186/s12245-021-00373-6](https://doi.org/10.1186/s12245-021-00373-6)
4. Alsaied T, Tremoulet AH, Burns JC, et al.: Review of cardiac involvement in multisystem inflammatory syndrome in children. *Circulation.* 2021, 143:78-88. [10.1161/CIRCULATIONAHA.120.049836](https://doi.org/10.1161/CIRCULATIONAHA.120.049836)
5. Hutchison L, Plichta AM, Lerea Y, Madora M, Ushay HM: Neuropsychiatric symptoms in an adolescent boy with multisystem inflammatory syndrome in children. *Psychosomatics.* 2020, 61:739-44. [10.1016/j.psych.2020.06.015](https://doi.org/10.1016/j.psych.2020.06.015)
6. Verdoni L, Mazza A, Gervasoni A, et al.: An outbreak of severe Kawasaki-like disease at the Italian epicentre of the SARS-CoV-2 epidemic: an observational cohort study. *Lancet.* 2020, 395:1771-8. [10.1016/S0140-6736\(20\)31103-X](https://doi.org/10.1016/S0140-6736(20)31103-X)
7. Dallan C, Romano F, Siebert J, Politi S, Lacroix L, Sahyoun C: Septic shock presentation in adolescents with COVID-19. *Lancet Child Adolesc Health.* 2020, 4:21-3. [10.1016/S2352-4642\(20\)30164-4](https://doi.org/10.1016/S2352-4642(20)30164-4)
8. Acharyya BC, Acharyya S, Das D: Novel coronavirus mimicking Kawasaki disease in an infant . *Indian Pediatr.* 2020, 57:753-4. [10.1007/s13312-020-1924-5](https://doi.org/10.1007/s13312-020-1924-5)
9. Toubiana J, Poirault C, Corsia A, et al.: Kawasaki-like multisystem inflammatory syndrome in children during the covid-19 pandemic in Paris, France: prospective observational study. *BMJ.* 2020, 369:[10.1136/bmj.m2094](https://doi.org/10.1136/bmj.m2094)
10. Whittaker E, Bamford A, Kenny J, et al.: Clinical characteristics of 58 children with a pediatric inflammatory multisystem syndrome temporally associated with SARS-CoV-2. *JAMA.* 2020, 324:259-69. [10.1001/jama.2020.10369](https://doi.org/10.1001/jama.2020.10369)
11. Dufort EM, Koumans EH, Chow EJ, et al.: Multisystem inflammatory syndrome in children in New York State. *N Engl J Med.* 2020, 383:347-58. [10.1056/NEJMoa2021756](https://doi.org/10.1056/NEJMoa2021756)
12. Alrefaey Y, Alharbi AF, Alzahrani YM, Albar RF: A case of multisystem inflammatory syndrome in a three-year-old boy. *Cureus.* 2022, 14:[10.7759/cureus.26315](https://doi.org/10.7759/cureus.26315)
13. Lindquist ME, Hicar MD: B cells and antibodies in Kawasaki disease . *Int J Mol Sci.* 2019, 20:[10.3390/ijms20081834](https://doi.org/10.3390/ijms20081834)