



Contents lists available at ScienceDirect

International Journal of Surgery Case Reports

journal homepage: www.casereports.com

A case report of laparoscopic duodenal atresia repair in a neonate using a novel miniature stapling device



Yoon Jung Boo^{a,b}, Jan Gödeke^a, Veronika Engel^a, Oliver J. Muensterer^{a,*}

^a Department of Pediatric Surgery, University Medicine Mainz, Mainz, Germany

^b Division of Pediatric Surgery, Department of Surgery, Korea University College of Medicine, Seoul, Republic of Korea

ARTICLE INFO

Article history:

Received 28 September 2016

Accepted 20 November 2016

Available online 22 November 2016

Keywords:

Duodenal atresia
Annular pancreas
Laparoscopic surgery
Surgical stapler
Anastomosis

ABSTRACT

INTRODUCTION: Laparoscopic duodenal atresia repair is an advanced procedure performed in select pediatric surgical centers. Recently, sub-6 mm endosurgical staplers have been introduced, facilitating and accelerating the creation of intracorporeal intestinal anastomoses.

PRESENTATION OF CASE: We performed a laparoscopic duodenojejunostomy in a one-day-old child with duodenal atresia due to annular pancreas using a novel 5.8 mm articulating endostapler with excellent outcome. The technical details are reported.

DISCUSSION: Laparoscopic duodenojejunostomy is a technically demanding procedure due to difficulty in hand-sewn anastomosis in a small and restricted space. With this novel 5.8 mm articulating endostapler, we were able to perform a quicker and easier anastomosis.

CONCLUSION: We report a case of laparoscopic duodenal atresia repair in a neonate using a novel miniature stapling device. This new technique is a safe, quick and easier way to perform laparoscopic duodenal atresia repair.

© 2016 The Author(s). Published by Elsevier Ltd on behalf of IJS Publishing Group Ltd. This is an open access article under the CC BY-NC-ND license (<http://creativecommons.org/licenses/by-nc-nd/4.0/>).

1. Introduction

Laparoscopic duodenal atresia repair in neonates is considered an advanced procedure that should be performed only in select pediatric surgical centers that have the necessary experience [1]. The challenges of the operation include identification of the small, postatretic portion of the intestine proximal to the ligament of Treitz, correct apposition of the proximal and distal bowel, as well as suturing a watertight, generous anastomosis in a very small space.

In adults, stapled small bowel anastomoses are constructed quicker and result in fewer complications than hand-sewn ones, including a lower rate of leaks and postoperative bowel obstructions [2].

Theoretically, laparoscopic side-to-side stapling of the duodeno-oduodenostomy or duodenojejunostomy could greatly facilitate and shorten congenital duodenal atresia correction. The 12 mm endosurgical stapling devices available to date, however, are simply too large to be employed in neonates, considering the tight intraabdominal space and the small intraluminal caliber of the distal duodenum.

Recently, sub-6 mm endosurgical stapling devices have been made commercially available. We performed a laparoscopic duodeno-oduodenostomy using a new articulating 5.8 mm endostapler (Fig. 1), reporting technical details and outcome. To our knowledge, this is the first such report using this type of device.

2. Presentation of case

A baby girl with prenatally diagnosed duodenal atresia was born at 40 weeks of gestation and a birth weight of 3070 g. The karyotype excluded Down syndrome. Postnatal radiography confirmed a double-bubble in the upper abdomen (Fig. 2). No other associated anomalies were detected, and the nasogastric output was clear and nonbilious.

The child was scheduled for laparoscopic duodeno-oduodenostomy on the second day of life. During surgery, 3 mm trocars were placed in the navel, as well as the left upper and right lower quadrants. The distended proximal duodenum was immediately visible. Upon further inspection, the underlying cause of the atresia was found to be annular pancreas. The distal, atretic portion of the duodenum was relatively fixed to the retroperitoneum due to the annular pancreas. Therefore, distal duodenum and a portion of jejunum was mobilized and brought close to the proximal portion using transabdominal percutaneous stitches. With both portions of the bowel apposed, enterotomies were performed using cold endoscopic scissors at the anterior aspect (Fig. 3). A 5.8 mm diameter articulating endostapler (MicroCutter 5/80, Dexter Surgical

* Corresponding author at: Department of Pediatric Surgery, University Medicine Mainz, Langenbeckstraße 1, Mainz, 55131, Germany.

E-mail addresses: oliver.muensterer@unimedizin-mainz.de, drboo@korea.ac.kr (O.J. Muensterer).

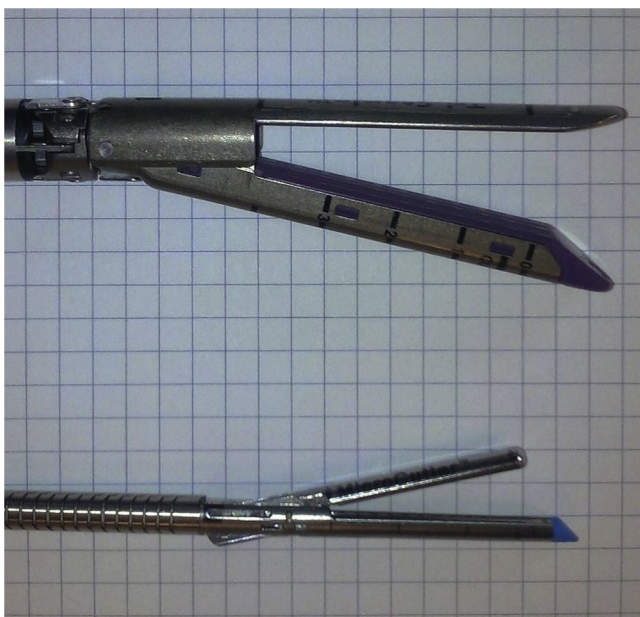


Fig. 1. Photograph of a conventional 12 mm stapler (upper) versus a 5.8 mm diameter articulating endostapler (MicroCutter 5/80, Dexter Surgical Inc., Redwood City, CA) (lower).

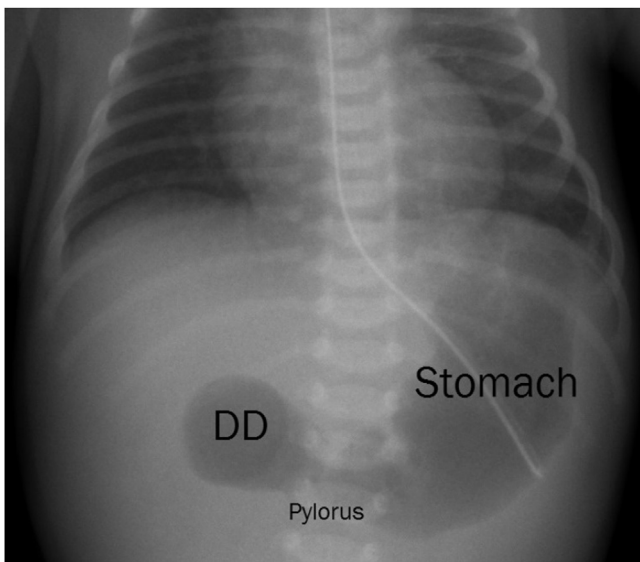


Fig. 2. Postnatal radiography showing a double-bubble in the upper abdomen. DD. Duodenum.

Inc., Redwood City, CA) was introduced through an additional skin incision in the right upper quadrant in trajectory of the aligned portions of duodenum (Fig. 4). Care was taken not to include the papilla in the anastomosis by gently pushing the stapler inferiorly, away from the liver. The stapling device was activated, creating a side-to-side anastomosis of both duodenal limbs. The combined enterotomy was closed using a running 4–0 Glycolactate suture. Total operative time was 75 min. The staple line was well visible on a postoperative radiograph (Fig. 5). Breastmilk was given on postop day one and the patient was discharged home on postop day 5. At a recent 5 months follow up visit, she was developing and thriving normally.

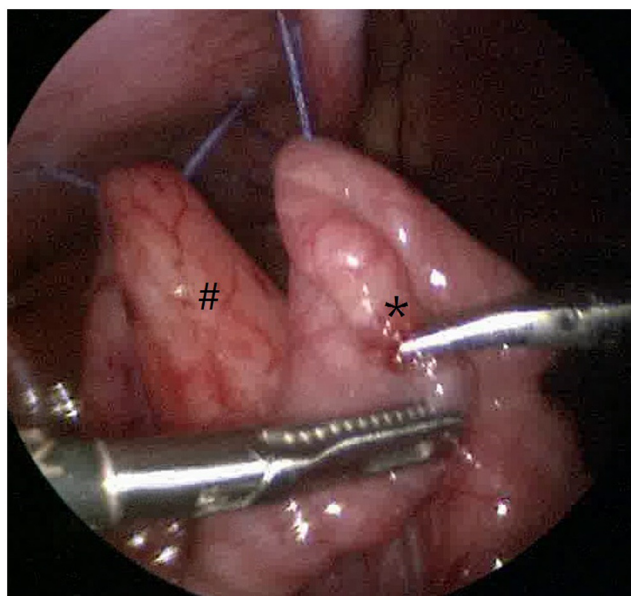


Fig. 3. Intraoperative view of showing the mobilized distal (*) and the proximal portion of duodenum (#) using transabdominal percutaneous stitches.

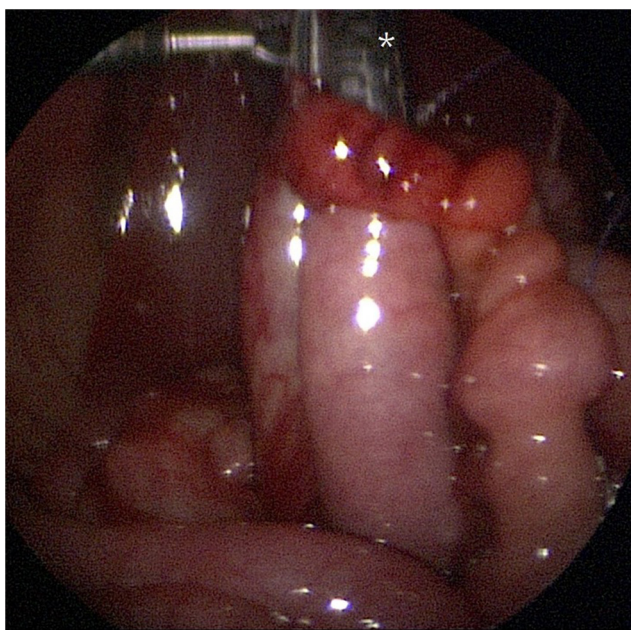


Fig. 4. The miniature stapler introduced from above (*) creating the side to side anastomosis of both duodenal limbs.

3. Discussion

Congenital obstruction of the duodenum may result from failure of the lumen to re-canalize during development, or by intrinsic compression due to annular pancreas. The initial management should include nasogastric decompression, which may produce bilious or nonbilious drainage. Once the patient has been stabilized, the diagnosis is confirmed, and potential associated anomalies have been addressed, a duodenoduodenostomy is performed.

In cases of annular pancreas, the distal portion of the duodenum may be fixed by the pancreatic ring, so that further downstream mobilization into the proximal jejunum may be required to perform a good anastomosis. This was the case in our patient, so that we performed a duodenojejunostomy.

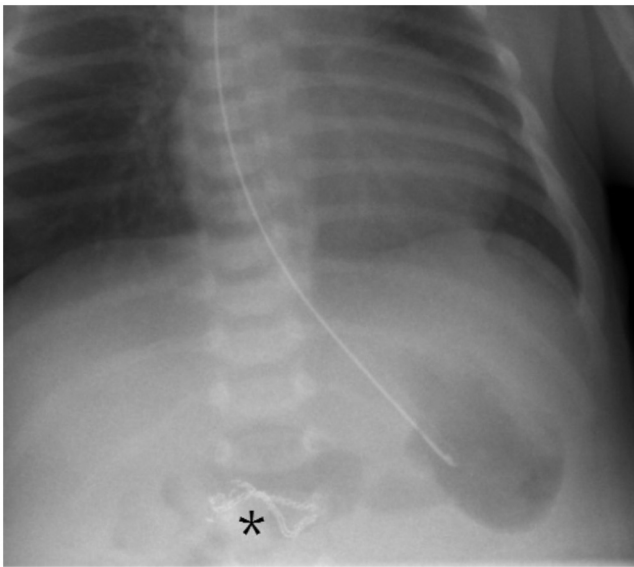


Fig. 5. Postoperative plain radiograph showing the staple line (*) in the duodenum.

Laparoscopic duodenal atresia repair was first described by Bax and colleagues in 2001 [3]. Due to the location of the duodenum and the general small working space, it is considered one of the more complex, advanced pediatric endosurgical procedure [1]. One of the potential problems is a relatively high anastomotic leak rate. In one series of 22 patients operated between 2000 and 2005, 4 interventions were converted to an open technique, and 5 of the patients suffered postoperative leakage [1]. This has prompted some to try alternative methods of anastomosis, such as vascular Nitinol U-clips [4], which are no longer commercially available. Therefore to date, the laparoscopic hand-sewn diamond-shaped anastomosis is still considered the standard approach.

However, laparoscopic repair of duodenal atresia still has benefits in terms of a quick recovery; most importantly, it has a better cosmetic result, not resulting in a disfiguring scar on the abdomen. One of the main reasons for the technical difficulties of laparoscopic duodenoduodenostomy and duodenojejunosomy is creating a watertight closure of the anastomosis, particularly on the posterior wall. This is generally considered the most demanding part of the procedure and failure to do so is related to the high leak rate.

Stapled anastomosis allows surgeon to perform anastomosis much easier than with a hand-sewn technique. With this novel 5.8 mm articulating endostapler, we hypothesized to be able to perform a quicker and easier anastomosis.

Although controversy remains between hand-sewn and stapled anastomoses, according to reports in adults, stapled anastomoses are generally considered to be more reliable and less prone to stricture than hand-sewn ones [2,5,6].

A recent report suggested improved efficacy of the stapled anastomoses in surgery on newborns based on the shorter time of operation [7]. Indeed, the operation time of our case was only 75 min. This was substantially shorter than the mean time of 90 min (range 80–150 min) reported in a recent study for conventional laparoscopic duodenoduodenostomy [8].

As far as we know, this is the first report of the application of a 5.8-mm stapler for newborn duodenal atresia repair. This new technique may shorten the learning curve for laparoscopic duoden-

oduodenostomy and may decrease the relatively high conversion and complications rate. In addition, the articulation feature of the device may allow us to perform the same operation using a single-incision laparoscopic approach in the future.

4. Conclusion

We first report a case of laparoscopic duodenal atresia repair in a neonate using a novel miniature stapling device. This new technique is a safe, quick and easy way to perform laparoscopic duodenal atresia repair.

Conflict of interest

The authors have no conflicts of interest.

Funding

This case report was funded internally by departmental funds.

Ethical approval

According to the stipulations of the ethics committee of the state of Rhineland-Palatinate, IRB approval is not required for this report. The device used in this patient is a licensed medical product in Germany.

Consent

Consent has been obtained from the patient's guardian.

Author contribution

Concept and design: OJM, JG, VE; Acquisition of data: OJM; Drafting and writing the article: OJM, YJB; Approved the final version of the manuscript on behalf of all authors: YJB, OJM, JG.

Guarantor

Oliver J. Muensterer: Department of Pediatric Surgery, University Medicine Mainz, Langenbeckstraße 1, 55131 Mainz, Germany. Tel: +49 06131 17-7111. Fax: +49 06131 17-6523. E-mail address: oliver.muensterer@unimedizin-mainz.de.

References

- [1] D.C. van der Zee, Laparoscopic repair of duodenal atresia: revisited, *World J. Surg.* 35 (8) (2011) 1781–1784.
- [2] T. Loffler, I. Rossion, K. Goossen, et al., Hand suture versus stapler for closure of loop ileostomy—a systematic review and meta-analysis of randomized controlled trials, *Langenbecks Arch. Surg.* 400 (2) (2015) 193–205.
- [3] N.M. Bax, B.M. Ure, D.C. van der Zee, I. van Tuijl, Laparoscopic duodenoduodenostomy for duodenal atresia, *Surg. Endosc.* 15 (2) (2001) 217.
- [4] P.A. Valusek, T.L. Spilde, K. Tsao, S.D. St Peter, G.W. Holcomb 3rd, D.J. Ostlie, Laparoscopic duodenal atresia repair using surgical U-clips: a novel technique, *Surg. Endosc.* 21 (6) (2007) 1023–1024.
- [5] C.B. Neutzling, S.A. Lustosa, I.M. Proenca, E.M. da Silva, D. Matos, Stapled versus handsewn methods for colorectal anastomosis surgery, *Cochrane Database Syst. Rev.* 2 (2012) CD003144.
- [6] P.Y. Choy, I.P. Bissett, J.G. Docherty, B.R. Parry, A. Merrie, A. Fitzgerald, Stapled versus handsewn methods for ileocolic anastomoses, *Cochrane Database Syst. Rev.* 9 (2011) CD004320.
- [7] Y. Kozlov, V. Novogilov, A. Podkamenev, I. Weber, Stapled bowel anastomoses in newborn surgery, *Eur. J. Pediatr. Surg.* 3 (1) (2013) 63–66.
- [8] B. Parmentier, M. Peycelon, C.O. Muller, A. El Ghoneimi, A. Bonnard, Laparoscopic management of congenital duodenal atresia or stenosis: A single-center early experience, *J. Pediatr. Surg.* 50 (11) (2015) 1833–1836.

Open Access

This article is published Open Access at sciedirect.com. It is distributed under the [IJSCR Supplemental terms and conditions](#), which permits unrestricted non commercial use, distribution, and reproduction in any medium, provided the original authors and source are credited.