



## Case report

# Inflammatory myofibroblastic tumour: case report of a rare form of bladder tumour

Balasingam Balagobi<sup>a</sup>, Sreekanthan Gobishangar<sup>a</sup>, Anusha Ginige<sup>b</sup>, Dayal Gamlaksha<sup>c</sup>, Jeyarajah Sanjeyan<sup>c</sup>, Loganathan Suvethini<sup>a,\*</sup>,<sup>1</sup>

<sup>a</sup> Professorial Surgical Department, Teaching Hospital Jaffna

<sup>b</sup> District General Hospital, Vavuniya, Sri Lanka

<sup>c</sup> Teaching Hospital Jaffna, Sri Lanka

## ARTICLE INFO

## Keywords:

Inflammatory myofibroblastic tumour  
Sarcomatoid variant  
Bladder tumour

## ABSTRACT

**Introduction and importance:** Inflammatory myofibroblastic tumour (IMT) is a rare tumour with malignant potential and has been described in many major organs with the most frequent site being the lungs. However, bladder is an extremely rare location. IMT presents a unique diagnostic challenge because of the characteristics it shares with malignant neoplasms.

**Case presentation:** Here we report the case of a 47-year-old male who presented with storage lower urinary tract symptoms associated with non-specific lower abdominal pain for one month duration. Contrast-enhanced computed tomography of abdomen and pelvis revealed a 6 cm tumour at the dome and left side anterior wall of the bladder. He underwent laparotomy and partial cystectomy. Histopathology results were consistent with an IMT.

**Clinical discussion:** Even though bladder IMT is indolent in course, typical IMTs can be locally aggressive. Due to the lack of specificity in clinical symptoms, it is not easy to arrive at a precise diagnosis before surgery. Hence, the final diagnosis depends on histomorphological features and the immune histochemical profile.

**Conclusion:** It can be challenging to distinguish IMT from malignant neoplasms both clinically and histologically. As such, local surgical resection with close follow-up remains the mainstay of treatment for urinary tract IMT.

## 1. Introduction

Inflammatory myofibroblastic tumour (IMT) is an extremely rare clinical and pathological disease entity that has been reported in multiple anatomic locations, with the most frequent site being the lungs. It can also be found in head and neck soft tissue, abdominal cavity, omentum, retroperitoneum and other tissues and organs. However, the IMT is rarely encountered in the urinary tract [1].

In 1994, the World Health Organization (WHO) defined IMT as an intermediate soft tissue tumour with a background proliferation of spindle cells associated with a variably dense polymorphic infiltrate of mononuclear inflammatory cells [2]. Children and young adults are affected very often, but IMTs may occur along with the entire age range, with a slight predominance for women is discussed in some studies [3], while others report a male predominance [4]. The aetiology of IMT is unknown; theories include an inflammatory reaction to an infection or

an underlying low-grade malignancy. However, immunohistochemical staining of IMT reveals the presence of IgG-predominant, polyclonal plasma cells. This finding lends support to the theory that IMT is a reactive inflammatory process [5].

Eventhough it is indolent in nature IMT presents a unique diagnostic challenge because of the characteristics it shares with aggressive malignant neoplasms. So it is essential to distinguish this tumour from other malignant spindle cell tumours, such as the sarcomatoid variant of urothelial carcinoma, leiomyosarcoma and benign lesions such as post-operative spindle cell nodule of bladder [6].

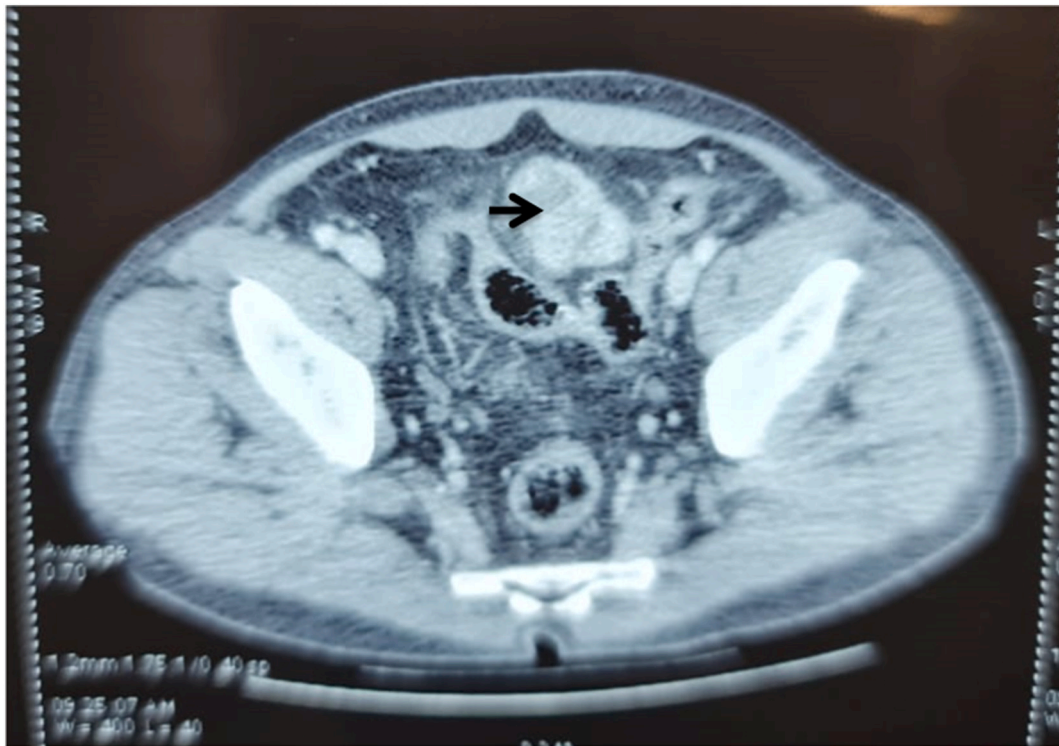
The outcome of these tumours can vary depending on anatomic location where lung and bladder tumours typically have a more favorable outcome. However, IMTs may locally recur in 25% of patients with abdominopelvic tumours. Patients may rarely develop metastatic disease; common sites include the lung, liver, bone, and brain [7].

We report a case of IMT of the urinary bladder in a 47-year-old male

\* Corresponding author at: Demonstrator in Surgery, Professorial Surgical Department, Teaching Hospital Jaffna, Sri Lanka.

E-mail address: [suvelogan123@gmail.com](mailto:suvelogan123@gmail.com) (L. Suvethini).

<sup>1</sup> Home address – No.351, Third lane, Thitunavatkulam, Vavuniya.



**Fig. 1.** CECT scan showed preoperative images of the bladder mass in the dome of the bladder and left side anterior bladder wall (indicated by arrow).

treated by partial cystectomy, and Histopathology results were consistent with an IMT.

This case report has been written according to the SCARE 2020 criteria [12].

## 2. Presentation of case

A 47-year old male mason was presented with a burning sensation while passing urine, mild lower abdominal pain, urgency and frequency for one month. He denied hematuria and fever with chills. He has no history of urinary tract infection, instrumentation, trauma or any other urological problems. His past medical, surgical and family history were not significant.

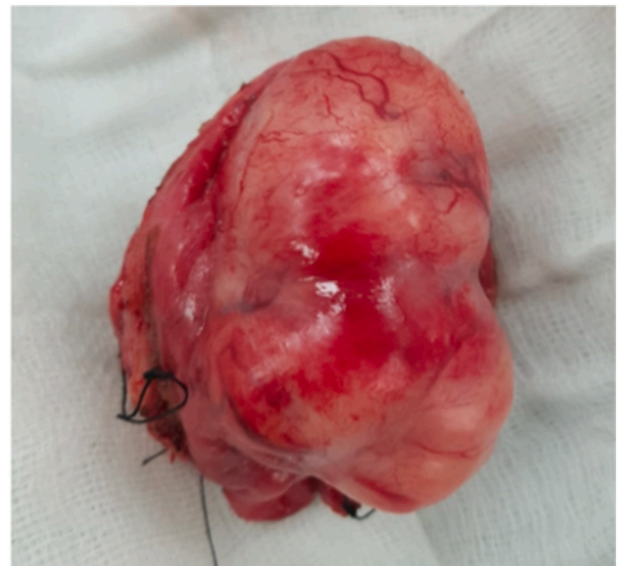The examination was essentially unremarkable other than mild abdominal tenderness in the suprapubic region.

An abdominal Ultrasound scan revealed heterogeneously hyper-echoic polypoidal mass located in the left lateral wall and dome of the bladder. Urine analysis and other blood investigations, including renal profile were normal. Contrast-Enhanced computed tomography (CECT) was performed and confirmed the presence of a tumour at the dome of the bladder and left side anterior bladder wall measuring  $6 \times 5.7 \times 5.5$  cm abutting the sigmoid colon. There was not metastasis. Lymph node was not involved (Fig. 1).

Biopsy of the tumour was taken with rigid cystoscopy, which revealed a solitary extra mucosal exophytic polypoidal tumour with surrounding oedema with normal surface mucosa at the dome of the bladder and left side anterior bladder wall. Colonoscopy was normal up to caecum.

After the cystoscopy & biopsy, patient developed continuous haematuria; his haemoglobin was reduced to 8.4 g/dl prompting transfusion of one unit of whole blood the day before the surgery.

He subsequently underwent laparotomy and partial cystectomy of urinary bladder tumour with 1 cm margin under general anaesthesia. Intraoperative findings showed a large solid bladder mass measuring  $6 \times 6 \times 5$  cm not infiltrating to sigmoid colon or any adjacent organs. We clinically diagnosed it as a mesenchymal tumour. Excised mass was sent

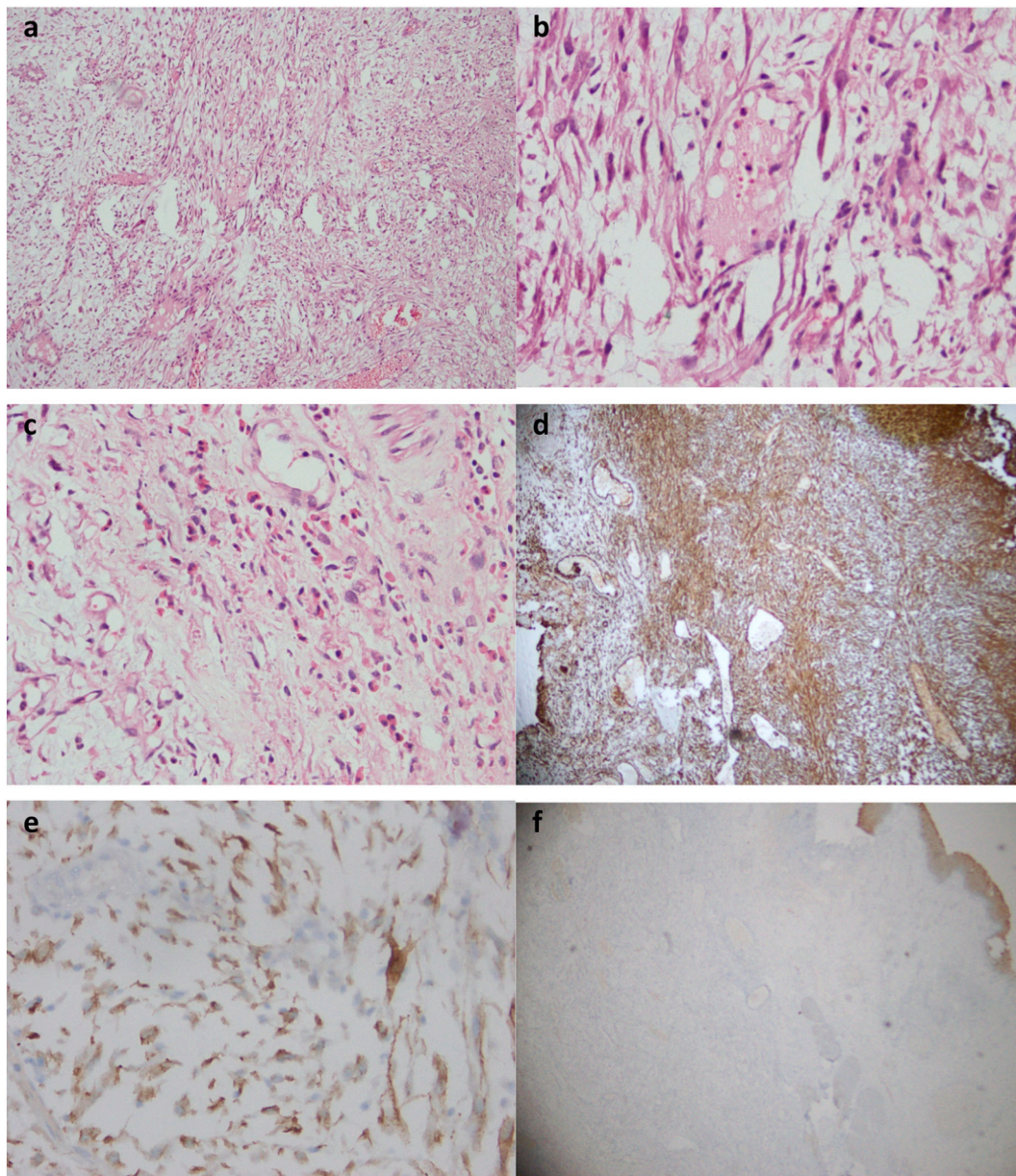


**Fig. 2.** Large solid bladder mass approximately measuring  $6 \times 6 \times 5$  cm.

for histological examination (Fig. 2).

He was discharged on the third postoperative day, and the urinary catheter was removed on day 14.

Histologic examination of the excised mass displayed that the tumour infiltrated and extended from a subserosal to the mucosa. The tumour was composed of predominantly spindle and a few stellate myofibroblastic cells. There was a variable cellularity. Hypocellular areas showed scattered haphazard cells in an abundant myxoid stroma. Hypercellular areas showed spindle cell fascicles and storiform patterns in a myxofibrous stroma. Focal necrosis was present. Mitotic count was 1 per h.p.f. Nuclear pleomorphism was absent. The serosal surface was intact and situated 3 mm away from the tumour at the closest point. The



**Fig. 3.** Histopathologic slides are showing a. variable cellularity (H & E,  $\times 40$ ) b. spindle cells (H & E,  $\times 100$ ) c. myofibroblasts and inflammatory cells (H & E,  $\times 100$ ) d. tumour cells stain strongly for vimentin (H & E,  $\times 40$ ) e. diffuse ALK positivity (H & E,  $\times 400$ ) f. EMA negativity (H & E,  $\times 40$ ).

tumour was situated 3 mm, 2 mm and 0.5 mm away from anterior, left lateral and posterior circumferential resection margins respectively. The mucosa was lined by transitional epithelium associated with Von Brunn's nests and cystitis cystica. Immunohistochemical stains showed that tumour cells were strongly positive for vimentin and diffusely positive for anaplastic lymphoma kinase (ALK). The tumour was negative for epithelial membrane antigen (EMA). Therefore leiomyosarcoma, carcinosarcoma and post-operative spindle cell nodule were excluded. Histopathology results were consistent with an IMT (Fig. 3).

He was on regular clinic follow up for six months. Post-operative flexible cystoscopy and CECT abdomen and pelvis were normal. Patient was satisfactory about his clinical outcome.

### 3. Discussion

The most common initial manifestation of IMT of the bladder is painless gross hematuria, resulting in anaemia. Other symptoms may include frequency of urination and dysuria. Urinary tract obstruction

may also occur [8]. The patient presented with vague symptoms like dysuria and abdominal pain. He did not have haematuria.

Inflammatory myofibroblastic tumour of the urinary bladder is a rare condition of unknown aetiology. Several predisposing factors have been described, such as recurrent cystitis and prior urinary bladder surgery, but the cause and the pathogenesis remain controversial [9]. Consistent with this theory, we could not find any aetiology or risk factors in our patient.

Due to the lack of specificity in clinical symptoms, it is not easy to arrive at a definite diagnosis before surgery. Therefore, usually, the final diagnosis depends on histomorphological features and the immune histochemical profile. Urologists, therefore, need to be aware of the possibility of rare cases of malignant bladder myofibroblasts. Inflammatory myofibroblastic tumour of the urinary bladder usually follows a benign clinical course. Therefore, the optimal curative management is conservative surgery, transurethral tumour resection or partial cystectomy. Recognition of this diagnostic entity is vital to avoid unnecessary surgical management with resulting functional impairment [10].

There are no standardized schemes regarding follow-up, but it is advisable since this tumour has 25% recurrence. However, given the indeterminate biological behavior of these tumours, continued monitoring of their clinical course is strongly recommended [11].

#### 4. Conclusion

This report describes a rare case of bladder IMT, which usually follows a relatively indolent course. However, it can be challenging to distinguish IMT from sarcomatoid carcinoma both clinically and histologically. As such, local surgical resection with close follow-up remains the mainstay of treatment for urinary tract IMT.

#### Sources of funding

No funding sources were used for this case report.

#### Ethical approval

Not applicable.

#### Informed consent

Written informed consent was obtained from the patient for publication of this case report and accompanying images. A copy of the written consent is available for review by the Editor-in-Chief of this journal on request.

#### Author contribution

B. Balagobi, S. Gobishankar, A. Ginige, D.S. Gamlaksha, J. Sanjeyan, and L. Suvethini have equally contributed to the concept, design, data collection, and writing of this case report.

#### Registration of research studies

Not applicable.

#### Guarantor

Dr. Balagobi Balasingam (MBBS, MD SURGERY, MRCS, FRCS UROLOGY), Senior lecturer, consultant urologist, professorial surgical department, Teaching hospital Jaffna.

#### Declaration of competing interest

All authors disclose any financial and personal relationships with other people or organizations that could inappropriately influence their work.

#### Acknowledgments

The authors would like to thank all health staff involved in managing this patient and the patient for consenting to publish this data and clinical images.

#### Provenance and peer review

Not commissioned, externally peer-reviewed.

#### References

- [1] I. Tsuboi, Y. Maruyama, T. Sadahira, K. Wada, N. Ando, Y. Mitsui, Y. Nishiyama, R. Arata, M. Araki, Y. Nasu, N. Ono, Inflammatory myofibroblastic bladder tumor with divergent behavior in a patient with spinal cord injury, *IJU Case Rep.* 2 (4) (2019 May 29) 212–214.
- [2] J.M. Coindre, Histologic classification of soft tissue tumors (WHO, 1994), *Ann. Pathol.* 14 (1994) 426–427.
- [3] J.Y.C. Teoh, N.H. Chan, H.Y. Cheung, S.S.M. Hou, C.F. Ng, Inflammatory myofibroblastic tumors of the urinary bladder: a systematic review, *Urology* 84 (3) (2014) 503–508.
- [4] L. Wei, L. Jianbo, W. Quiang, Y. Hai, L. Zhixiang, Inflammatory myofibroblastic tumor of the bladder: case report and review of the literature, *Can. Urol. Assoc. J.* 7 (2013) E237–E240.
- [5] O. Matsubara, N.S. Tan-Liu, R.M. Kenney, E.J. Mark, Inflammatory pseudotumors of the lung: progression from organizing pneumonia to fibrous histiocytoma or to plasma cell granuloma in 32 cases, *Hum. Pathol.* 19 (1988) 807.
- [6] T. Etani, T. Naiki, T. Nagai, et al., Inflammatory myofibroblastic tumor of the urinary bladder: a case report, *Case Rep Oncol.* 9 (2) (2016) 464–469. Published 2016 Aug 17.
- [7] Hiroyuki Sakurai, Tadashi Hasegawa, Shun-ichi Watanabe, Kenji Suzuki, Hisao Asamura, Ryosuke Tsuchiya, Inflammatory myofibroblastic tumor of the lung, *Eur. J. Cardiothorac. Surg.* 25 (2) (2004) 155–159.
- [8] S.B. Park, K.S. Cho, J.K. Kim, et al., Inflammatory pseudotumor (myoblastic tumor) of the genitourinary tract, *Am. J. Roentgenol.* 191 (4) (2008) 1255–1262.
- [9] A. Kumar, S.S. Bhatti, S. Sharma, S.D. Gupta, R. Kumar, Inflammatory pseudotumor of urinary bladder - a diagnostic and management dilemma, *Int. Urol. Nephrol.* 39 (3) (2007) 799–802.
- [10] J.C.V. Laylo, N.L. Lim, J.J.V. Remo, Inflammatory myofibroblastic tumor of the urinary bladder: a prognostically favorable spindle cell neoplasm, *Urol. Case Rep.* 34 (2020) 101474. Published 2020 Oct 29.
- [11] S. Santos Lopes, A. Furtado, R. Oliveira, et al., Inflammatory myofibroblastic tumor of the bladder: 2 rare cases managed with laparoscopic partial cystectomy, *Case Rep. Urol.* 2016 (2016).
- [12] R.A. Agha, T. Franchi, C. Sohrabi, G. Mathew, for the SCARE Group, The SCARE 2020 guideline: updating consensus Surgical CASE REport (SCARE) guidelines, *Int. Journal of Surgery* 84 (2020) 226–230.