

## Case Report

# Minimal-change disease as a paraneoplastic syndrome in a patient with ovarian carcinoma

Guido R. González-Fontal<sup>1</sup>, Juan G. Restrepo<sup>2</sup> and Andrés F. Henao-Martínez<sup>3</sup>

<sup>1</sup>Department of Internal Medicine, CES University-Fundacion Valle del Lili, Cali, Colombia, <sup>2</sup>Division of Hematology/oncology, Department of Medicine, CES University-Fundacion Valle del Lili, Cali, Colombia and <sup>3</sup>Division of Infectious Diseases, University of Colorado Denver, Aurora, CO, USA

Correspondence and offprint requests to: Andres F. Henao-Martinez; E-mail: andres.henaomartinez@ucdenver.edu

### Abstract

Minimal-change disease (MCD) is an exceptional paraneoplastic presentation. We are describing the case of an ovarian paraneoplastic nephrotic syndrome. The kidney biopsy was consistent with MCD. Steroids and immunosuppressive therapy were given with no change in the nephrotic-range proteinuria. A complete resolution of the nephrotic syndrome was soon observed with improvement of her clinical condition after five cycles of chemotherapy with paclitaxel and carboplatin and tumor-debulking surgery. Ovarian carcinoma paraneoplastic nephrotic syndrome secondary to MCD is an extremely rare event, which is important to recognize since it is responsive to the standard chemotherapy.

**Keywords:** minimal-change disease; nephrotic syndrome; ovarian carcinoma; paraneoplastic syndrome

### Background

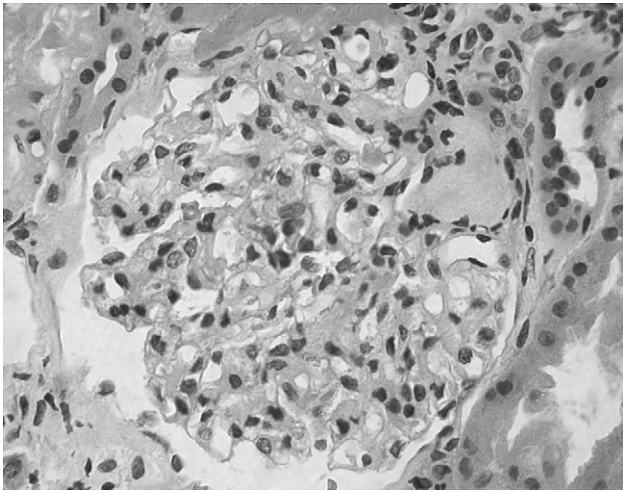
Nephrotic syndrome has been associated with malignant tumors in ~11% of the cases [1]. Membranous nephropathy is the most frequent form of paraneoplastic glomerulopathy associated with solid tumors [2]. Minimal-change disease (MCD) is mainly associated with Hodgkin lymphoma, however, it is also being linked with different solid tumors, the most common of which are thymoma, colorectal carcinoma and renal cell carcinoma [3]. We herein present a case of paraneoplastic MCD secondary to ovarian carcinoma. According to our knowledge, this is the second reported case where an MCD presented as a complication to ovarian papillary serous carcinoma.

### Case report

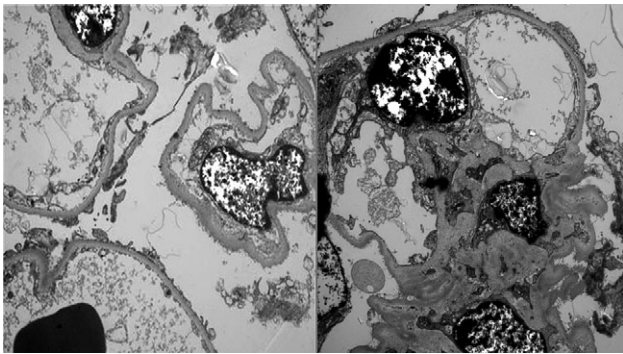
On 23 October 2008, a 73-year-old hispanic female was admitted with 8 weeks of exertional dyspnea, dry cough,

nausea, emesis, progressive lower extremity edema, 10 kg weight gain and asthenia. She has a history of stroke and hypertension diagnosed 3 years earlier. Her vital signs on admission were blood pressure of 90/60 mmHg, a heart rate of 76 beats/min, respiratory rate: 16/min, T°: 37.4°C, weight: 70 Kg and SaO<sub>2</sub>: 96% on room air. Physical examination was relevant for a 3+ pitting edema on her lower extremities. Blood tests showed normal complete blood count, serum creatinine 240.44 mmol/L (normal range 46–91.9 mmol/L), urea nitrogen 19.2 mmol/L (normal range 2.5–6.1 mmol/L), 24-h proteinuria of 4 g (normal range of 42–225 mg/24-h), no red cells or casts were found on urine sediment, serum albumin of 15 g/L (normal range 35–50 g/L), serum total protein was 37.2 g/L (normal range 61–79 g/L) and total cholesterol of 5.4 mmol/L (normal range 0–5.2 mmol/L). Complement component levels C3 and C4 were normal, antinuclear antibodies were positive 1:160 titers with a speckled pattern and anti-DNA antibodies were negative. Serological tests for hepatitis C virus, hepatitis B virus and human immunodeficiency virus infection were negative. Negative cryoglobulin levels and serum levels of immunoglobulin G, A, M, E were within normal limits, serum electrophoresis showed a monoclonal peak on the alpha2 and beta region and marked attenuation of the albumin region and urine immunofixation was negative for monoclonal immunoglobulin. Bone marrow biopsy was normal, without findings of plasma cell dyscrasia. Light microscopy of kidney biopsy indicated discrete mesangial proliferation and capillary wall thickening (Figure 1). The electronic microscopy findings are confined to the epithelial cells, they show diffuse foot process effacement, associated with aggregation of microfilaments, hypertrophy of epithelial cells, microvillous transformation and formation of vacuoles and some glomerular capillaries are collapsed (Figure 2). The lamina densa is irregular in thickness with subendothelial space widened lucent. The mesangial matrix is slightly expanded without deposits and the tubules show vacuolization (Figure 2). The above changes are consistent with MCD.

She was treated with methylprednisolone boluses of 250 mg/day for three doses followed by oral prednisone



**Fig. 1.** Light microscopy displayed discrete kidney mesangial proliferation and capillary wall thickening.



**Fig. 2.** Kidney electronic microscopy shows diffuse foot process effacement, hypertrophy of epithelial cells and tubules vacuolization.

50 mg/day and mycophenolate mofetil, 1.5 g/day. The kidney function improved, although the proteinuria in nephrotic range was persistent. An abdominal contrasted computerized tomography was performed with findings of mixed solid and cystic right ovarian mass with local infiltration of the pelvis wall, ascites and multiple solid hypodense subcapsular lesions in the liver and spleen. It also showed involvement of mesenteric fat with peritoneal implants. Ca 125 of 497 kU/L (normal range 0–21 kU/L) with normal carcinoembryonic antigen (CAE) and  $\alpha$ -fetoprotein. After discovering these results, steroid and immunosuppressive therapy were withdrawn. She was treated then with five cycles of paclitaxel (175 mg/m<sup>2</sup>) and carboplatin (area under curve 5). Significant improvement was observed after two cycles of chemotherapy with disappearance of edema. Normalization of creatinine, serum total protein, albumin and 24-h proteinuria were achieved and sustained during the chemotherapy period. Ca 125 was reduced to normal values of 13.1 kU/L before surgery debulking. Hysterectomy, bilateral salpingo-oophorectomy, omentectomy and segmental hepatic resection were performed. The pathology of the

right ovary revealed a high-grade Stage IV papillary serous adenocarcinoma.

## Discussion

Paraneoplastic syndrome refers to clinical manifestations not directly related to tumor burden, invasion or metastasis but caused by the secretion of tumor cell products (such as hormones, cytokines, growth factors and tumor antigens) [4]. Many authors have reported the association of nephrotic syndrome and extrarenal malignancies. The most common neoplasias associated with paraneoplastic glomerular diseases are adenocarcinomas of the lung and the gastrointestinal tract [2]; MCD glomerulopathy is also strongly associated with Hodgkin lymphoma [5]. Paraneoplastic glomerular diseases are rarely linked to ovarian cancer, with only nine cases of this association reported [1, 6–11] (Table 1). Approximately 64 cases of other solid tumors have been associated to MCD and from those at least 26 (40%) cases were associated with thymomas [3].

Since it is difficult to ascertain if the nephrotic syndrome is really a paraneoplastic manifestation, one criterion is particularly fulfilled in these specific cases: the clinical remission observed after complete removal of the tumor or full remission achieved by chemotherapy. These criteria were present in our case. The correlation between the level of proteinuria and the clinical course of the cancer reflected in part on the 24-h urine protein excretion level and the serum Ca 125, respectively, has been determined [10].

Among the hypothesized theories to explain the occurrence of paraneoplastic glomerulopathies, the presence of an unrecognized filtration factor has been theorized as the etiopathogenesis for some forms of Focal segmental glomerulosclerosis (FSGS). This observation is based on the recurrence of proteinuria in FSGS patients within hours of transplantation and remission following plasmapheresis or immunoadsorption. A permeability factor, soluble ST2 protein, has been recently implicated in cases of FSGS not related to malignancies [12]. Only one animal model (buffalo/Mna rat) of paraneoplastic glomerulopathies is currently available [3], but we believe that a possible yet undiscovered tumor-secreted product could at least partially explain this phenomenon. This theory, however, warrants further investigation. Specifically regarding MCD, the overproduction of vascular endothelial growth factor by cancer cells has been proposed to contribute to the pathogenesis of this form of paraneoplastic glomerulopathy [13].

According to our knowledge, this is the second reported case of a paraneoplastic MCD associated to ovarian carcinoma. There was a clearly established relationship between the clinical course of the cancer, the chemotherapy and the level of proteinuria. As documented in previously reported cases delineated in Table 1, it is critical to recognize this entity as a consequence of a paraneoplastic effect since nephrotic syndrome has been overlooked as paraneoplastic and immunosuppressive therapy may conceivably induce a flare in the tumor course and hence the establishment of the ovarian carcinoma therapy to assure the remission of both conditions becomes decisive [9–11].

**Table 1.** Paraneoplastic nephrotic syndrome cases associated with ovarian carcinoma<sup>a</sup>

Case and reference	Age/sex	Gap in months between onset of nephropathy and discovery of malignancy	Histology	Ovarian tumor	Treatment	Normalize Ca125/proteinuria	Outcome
1 (1)	65/F	19	MN <sup>b</sup>	Adenocarcinoma	Surgery	(...)	Death
2–3 (13)	(...)	(...)	MN	Adenocarcinoma	Surgery + prednisone	(...)	(...)
4 (14)	7/F	9	MN	Teratoma	Surgery + prednisone	NA	Resolution
5 (15)	65/F	8	MN	Adenocarcinoma	Cisplatinum Adriamycin Cytosaxan	Yes	(...)
6 (16)	15/F	32	MPGN <sup>c</sup>	Dysgerminoma	Surgery + prednisone	NA	Advanced RF <sup>d</sup>
7 (17)	68/F	1	MN	Adenocarcinoma	Surgery Carboplatin Paclitaxel	Yes	Death <sup>e</sup>
8 (18)	59/F	7	MN	Adenocarcinoma	Carboplatin Paclitaxel <sup>f</sup>	Yes	Remission
9 (19)	55/F	0	MCD <sup>g</sup>	Adenocarcinoma	Surgery + Prednisone Carboplatin Paclitaxel	Yes	Remission
10 (Ours)	73/F	6	MCD	Adenocarcinoma	Surgery + Prednisone Carboplatin Paclitaxel	Yes	Remission

<sup>a</sup>(...), information missing; NA, not applicable.

<sup>b</sup>Membranous nephropathy.

<sup>c</sup>Membranoproliferative glomerulonephritis.

<sup>d</sup>Renal failure.

<sup>e</sup>Death was related to paraneoplastic cerebellar degeneration syndrome.

<sup>f</sup>The patient was given second line treatment with oxaliplatin and capecitabine before remission.

<sup>g</sup>MCD nephropathy.

**Acknowledgements.** Adriana Flórez, Department of Pathology and Laboratory Medicine, Hospital Universitario Fundación Santa Fe de Bogotá, for the electronic microphotographs. The funding agencies had no role in the preparation, review or approval of the manuscript. The views expressed in this article are those of the author and do not necessarily represent the views of the CES University or University of Colorado Denver.

**Conflict of interest statement.** None declared.

## References

- Lee JC, Yamauchi H, Hopper J Jr. The association of cancer and the nephrotic syndrome. *Ann Intern Med* 1966; 64: 41–51
- Davison AM. Renal diseases associated with malignancies. *Nephrol Dial Transplant* 2001; 16 (Suppl 6): 13–14
- Bacchetta J, Juillard L, Cochat P *et al.* Paraneoplastic glomerular diseases and malignancies. *Crit Rev Oncol Hemat* 2009; 70: 39–58
- Ronco PM. Paraneoplastic glomerulopathies: new insights into and old entity. *Kidney Int* 1999; 56: 355–377
- Audard V, Larousserie F, Grimbert P *et al.* Minimal change nephrotic syndrome and classical Hodgkin's lymphoma: report of 21 cases and review of the literature. *Kidney Int* 2006; 69: 2251–2260
- Beauvais P, Vandour G, Boccon Gibod L *et al.* Membranous nephropathy associated with ovarian tumour in a young girl: recovery after removal. *Eur J Pediatr* 1989; 148: 624–625
- Hoyt RE, Hamilton JF. Ovarian cancer associated with the nephrotic syndrome. *Obstet Gynecol* 1987; 70: 513–514
- Salazar-Exaire D, Rodríguez A, Galindo-Rujana ME *et al.* Membranoproliferative glomerulonephritis associated with a mixed-cell germinal ovary tumor. *Am J Nephrol* 2001; 21: 51–54
- Forgy A, Ewing TL, Flaningam J. Two paraneoplastic syndromes in a patient with ovarian cancer: nephrotic syndrome and paraneoplastic cerebellar degeneration. *Gynecol Oncol* 2001; 80: 96–98
- Kim YT, Rha SY, Shim CY *et al.* A case of paraneoplastic nephrotic syndrome in a patient with ovarian carcinoma. *Yonsei Med J* 2003; 44: 539–543
- Ryu DR, Yoo TH, Kim YT *et al.* Minimal change disease in a patient with ovarian papillary serous carcinoma. *Gynecol Oncol* 2004; 93: 554–556
- Bruneau S, Le Berre L, Hervé C *et al.* Potential role of soluble ST2 protein in Idiopathic nephrotic syndrome recurrence following kidney transplantation. *Am J Kidney Dis* 2009; 54: 522–525
- Lien YH, Lai LW. Pathogenesis, diagnosis and management of paraneoplastic glomerulonephritis. *Nat Rev Nephrol* 2011; 7: 85–95

Received for publication: 26.7.11; Accepted in revised form: 28.7.11