

The reasons and clinical treatments of postoperative relapse of Pott's disease

Xin Hua Yin, MD, Zhong Kai Liu, MD*, Dingjun Hao, MD

Abstract

Literature about postoperative relapse of Pott's disease is rare. Accordingly, the risk factors and clinical treatments for postoperative relapse of Pott's disease remain controversial. In order to evaluate the clinical outcomes of surgical treatment of postoperative Pott's disease relapse, and to investigate its optimal therapeutic procedures with respect to focal characteristics, we performed a retrospective review of clinical and radiographic data that were prospectively collected between July 2008 and May 2014 from 753 consecutive spinal tubercular patients including 67 patients who were diagnosed and treated as postoperative relapse of Pott's disease in our hospital. Apart from 9 patients being treated conservatively, the remaining 58 cases received surgery in our series. Specifically, 12 cases underwent anterior debridement, interbody fusion with instrumentation; 15 cases received posterior instrumentation anterior debridement, and bone grafting; 10 cases underwent posterior decompression, bone grafting, and instrumentation; 7 cases with debridement, 5 with debridement and sinus resection. Nine cases received percutaneous drainage and low-dose local continuous chemotherapy. Clinical outcomes before and after treatment were evaluated with statistical analysis based on hematologic and radiographic examinations, bone fusion, and neurologic status. Patients were followed-up for a mean of 39.2 ± 8.2 months (range, 24–60 months). Postoperatively, the erythrocyte sedimentation rate (ESR) became normal within 4–6 months in all patients, and solid bone fusion was achieved within 8 months. Patients exhibited significant improvements in neurological deficits postoperatively, while the visual analog scale for pain showed significant improvements in all patients at final follow-up. The outcomes of follow-up showed that the reasons for postoperative relapse of Pott's disease were multiple. Individualized therapeutic methods should be chosen in accordance with the patient's general condition, recurrence focal characteristic, surgeon's experience, but above all is administration of appropriate chemotherapy.

Abbreviations: ASIA = American Spinal Injury Association, CT = computed tomography, ESR = erythrocyte sedimentation rate, MRI = magnetic resonance imaging, PCR = polymerase chain reaction, TB = tuberculosis, VAS = visual analog scale.

Keywords: Pott's disease, reasons, relapse, surgical strategy

1. Introduction

China has the second highest tuberculosis (TB) burden in the world.^[1] Similarly, China has 1.4 million new cases of Pott's disease (spinal tuberculosis) every year; Pott's disease, the most common form of extrapulmonary tuberculosis, is one of the most prevalent infectious diseases and represents an important cause of morbidity and mortality.^[2] Although, sufficient experience has demonstrated surgery could have good clinical results in spinal

tuberculosis treatment, postoperative deterioration of physical condition has been reported to occur in about 9% of patients.^[3] The relapse after surgical treatment for Pott's disease results in increased number of hospital stays, recovery times, and cost for the patient and the healthcare system. However, there is a paucity of comprehensive information describing postoperative relapse after surgical treatment for Pott's disease. In this study, we aim to evaluate the clinical outcomes of surgical treatment for postoperative relapse of Pott's disease, investigate possible associated recurrence factors, and identify optimal therapeutic procedures with respect to focal characteristics of disease.

2. Methods

This study was approved by the ethics board committee of our hospital, and informed consent was obtained in writing from all participants. Between July 2008 and May 2014, a signal-center retrospective review of clinical and radiographic data was performed where data from 753 consecutive spinal tubercular patients who had undergone surgical treatment in our hospital were prospectively collected. Of these 67 patients were diagnosed and treated as postoperative relapse of Pott's disease in our hospital. The diagnosis of postoperative relapse of Pott's disease was based on clinical presentation, radiologic findings, hematologic examination, and pathological examination. Polymerase chain reaction (PCR) was used to confirm the diagnosis of Pott's disease in approximately 50% of patients. The diagnosis of tuberculosis was made with reference to clinical and radiological findings and was verified histopathologically after debridement in

Editor: Mehmet Bakir.

Reprints: Hong Hui Hospital, Xi'an Jiaotong University College of Medicine, Xi'an, Shaanxi 710054, China.

This work was financially supported by Postdoctoral Science Foundation in Shanxi Province, China (2016BSHYDZZ41).

The authors have no conflicts of interest to disclose.

Department of Spine Surgery, Hong Hui Hospital, Xi'an Jiaotong University College of Medicine, Xi'an, China.

* Correspondence: Zhong Kai Liu, Department of Spine Surgery, Hong Hui Hospital, Xi'an Jiaotong University College of Medicine, Xi'an, Shanxi 710054, PR China (e-mail: spine2020@163.com).

Copyright © 2018 the Author(s). Published by Wolters Kluwer Health, Inc. This is an open access article distributed under the terms of the Creative Commons Attribution-Non Commercial-No Derivatives License 4.0 (CCBY-NC-ND), where it is permissible to download and share the work provided it is properly cited. The work cannot be changed in any way or used commercially without permission from the journal.

Medicine (2018) 97:39(e12471)

Received: 26 March 2018 / Accepted: 26 August 2018

<http://dx.doi.org/10.1097/MD.00000000000012471>

all patients. Routine radiologic procedures included chest radiograph, plain radiographs, computed tomography (CT), and magnetic resonance imaging (MRI).

Apart from 9 patients who were treated conservatively, the remainder (58 cases) received surgery, which made up our case series. This series was comprised of 35 males and 23 females with an average age of 48.5 ± 8.5 years (range, 20–73y). Choice of surgical procedures depended on many factors, including the nidus characteristics, patient's general condition, and surgical expertise; however, there were no well-defined preoperative selection criteria. Specifically, 12 cases underwent anterior debridement, interbody fusion with instrumentation; 15 cases received posterior instrumentation; anterior debridement and bone grafting; 10 cases underwent posterior decompression, bone grafting, and instrumentation; 7 cases with debridement, 5 with debridement and sinus resection. Around 9 cases with percutaneous drainage and low-dose local continuous chemotherapy.

Recurrent infection involvement included varied cervical to lumbosacral locations. Four patients had cervical involvement, 6 had cervicothoracic, 12 had thoracic, 15 had thoracolumbar, 14 had lumbar, and 7 patients had lumbosacral involvement. American Spinal Injury Association (ASIA) classification was used to assess the neurological function.^[4] There were 8 patients with grade B, 17 with grade C, 23 with grade D, and 10 with grade E. The visual analog scale (VAS) was used to assess pain preoperatively and at the last follow-up visit.^[5]

2.1. Preoperative management

The following antituberculosis drugs were administered: isoniazid (5 mg/kg), rifampicin (15 mg/kg), ethambutol (15–25 mg/kg), and pyrazinamide (15–30 mg/kg) preoperatively. Surgery was not carried out until patient erythrocyte sedimentation rate (ESR) and temperature returned to normal or had significantly decreased. Immediate surgery was recommended when patients had sudden onset of complete paralysis due to a large abscess. Enhancement of nutrition, correction of anemia and hypoproteinemia were routinely carried out.

2.2. Operative procedure

All surgery was performed under general anesthesia. If infection involvement was confined to the anterior column with spinal instability, anterior debridement, decompression, bone grafting, and instrumentation could be performed. Additionally, mild kyphosis could be corrected during anterior instrumentation. If the patient had severe kyphosis with focus involving more than 2 adjacent segments or had large paravertebral abscess, then anterior focal debridement, bone grafting, and posterior instrumentation could be performed in a single stage or in 2 stages depending on patient condition. Additionally, if a lesion was mono-segmental with or without a large paravertebral abscess, then posterior debridement, bone grafting, and instrumentation could be performed. If there was no occurrence of spinal instability, then debridement, or received debridement and sinus resection was performed under general anesthesia. Nine cases underwent CT-guided percutaneous puncture and local chemotherapy under local anesthesia.

2.3. Postoperative management

Patients were allowed to ambulate for 5 to 7 days postoperatively, then a brace was used by each patient until graft union was

Table 1
Clinical data on the patients.

Gender	
Male	35
Female	23
Age, years	48.5 ± 8.5
Average time to stand, days	5.2 ± 1.7
Operation time, minutes	410.2 ± 150.7
Amount of bleeding, mL	1580.2 ± 335.4
duration of follow-up, months	39.2 ± 8.2
Fusion time, months	5.9 ± 1.3
ASIA scale (preoperation)	
B	8
C	17
D	23
E	10

ASIA=American Spinal Injury Association.

achieved. Chemotherapy was administered for 12–18 months, postoperatively. For local chemotherapy was 0.1g isoniazid, twice per day. The tube was pulled out until ESR and C reactive protein (CRP), and body temperature had been consistently normal for 2 to 3 months. If the drug sensitivity results indicated resistance to any first-line drug, individualized chemotherapy was tailored for these patients based on their previous chemotherapy history and drug-susceptibility profiles. X-ray, ESR and liver hepatic function were examined at 1, 2, 3, 6, and 12 months after surgery and then once a year thereafter. Using SPSS 20.0 software, the results are reported as mean \pm standard deviation (SD).

3. Results

The patients were followed up for a mean of 39.2 ± 8.2 months (range, 24–60 months). In our series, all 58 patients had malnutrition, 9 patients developed Pott's disease recurrence as a result of inappropriate surgery indication. Additionally, 18 patients because of nonstandard chemotherapy, 15 patients because of nonradical debridement, and 9 patients failed to have strict postoperative immobilization. There was also unexplained postoperative recurrence in 7 patients.

All 58 patients were treated by surgery. Postoperatively, the average pretreatment ESR became normal within 4 to 6 months in all patients. There were 48 cases who suffered from neurologic deficits before surgery, at the last follow-up visit all such patients had improved. Additionally, 40 patients recovered to normal, 8 patients recovered to ASIA grade D. Bony fusion was achieved in all cases within 8 months postoperatively and compared with preoperation, the mean VAS was improved at the follow-up last visit. In this series, erythrocyte sedimentation rates returned to normal levels in all patients within 4 to 6 months after surgery. There were 5 patients who again had relapse; 3 of these patients were cured via CT-guided percutaneous puncture and local chemotherapy and individualized chemotherapy; the other 2 had open surgery. One patient showed internal fixation loosening postoperatively so instrumentation was removed after fusion. Furthermore, 1 patient presented with delayed wound healing due to diabetes, which successfully improved after systemic control of blood glucose levels. Finally, 5 patients reported harvest site pain postoperatively, and were treated with physical therapy and acupuncture at final follow-up (Table 2). The typical cases are showed in Figures 1–4.

Table 2
Clinical outcomes of surgical treatments for relapse of Pott's disease.

ASIA classification	
D	8
E	50
VAS	
Preoperative	8.1±2.7
Final follow-up	1.9±1.3
Complications	
Pain of graft harvesting site	5
internal fixation loosening	1
wound delayed healing	1

ASIA classification = American Spinal Injury Association (ASIA), VAS = visual analog scale.

4. Discussion

Although antituberculosis chemotherapy and various surgical methods can effectively treat Pott's disease, tuberculosis recurrence

after surgery is not uncommon. Previous single-institution studies have reported surgical recurrence rates of 1.28% to 25%,^[6,7] in our series, this figure was approximately 9%. Tuberculosis recurrence represents an important challenge for spine surgeons. We postulate that identification risk factors related to tuberculosis relapse will lead to a decrease in the incidence of tuberculosis relapse, relieve the sufferings of the patient, and improve quality of life of the patient. The uncertainty in relapse treatment was sufficiently resolved in our study. We found that Pott's disease recurrence increased significantly when associated with the following factors: malnutrition, nonstandard chemotherapy, nonradical debridement, immobilization, and inappropriate surgical indications.

We found that all 58 patients in our series had different levels of malnutrition. Nutritional support is an important part of therapy for those who are physically debilitated. These patients may even need hyperalimentation prior to starting treatment to restore premorbid nutritional status.^[8] It has been well established in spine surgery that malnutrition predisposes

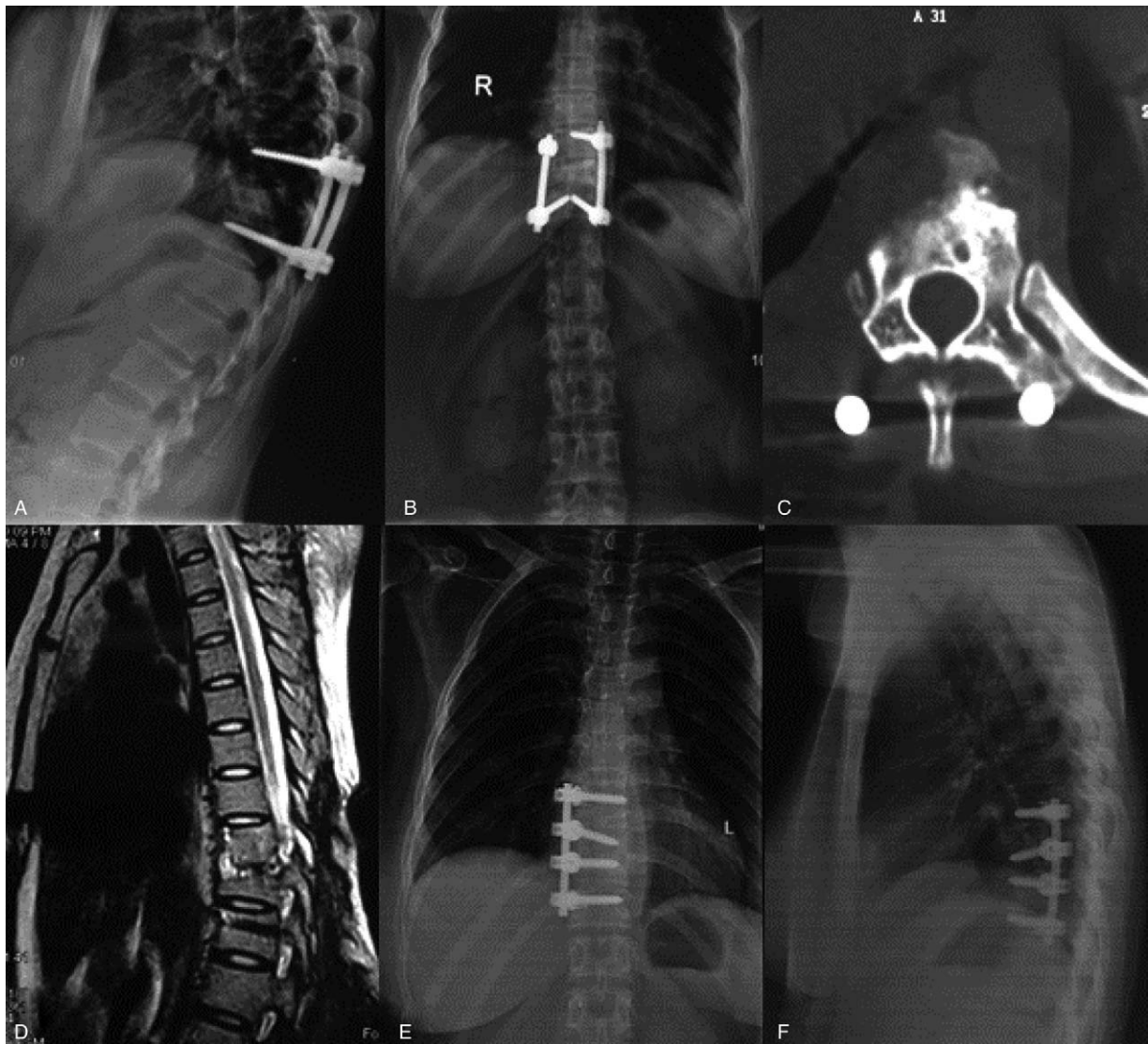


Figure 1. Case 1: A 56-year-old man was diagnosed as tuberculosis recurrence after anterior operation. (A, B) Radiograph showed tuberculosis recurrence after operation. (C, D) CT scan and MRI found the vertebral bone destruction and paravertebral abscess formation at the area of thoracic spine. Anterior debridement, instrumentation and allograft were performed on the patient. (E, F) X-ray at the final follow-up found the kyphotic angle was corrected and good bone fusion.

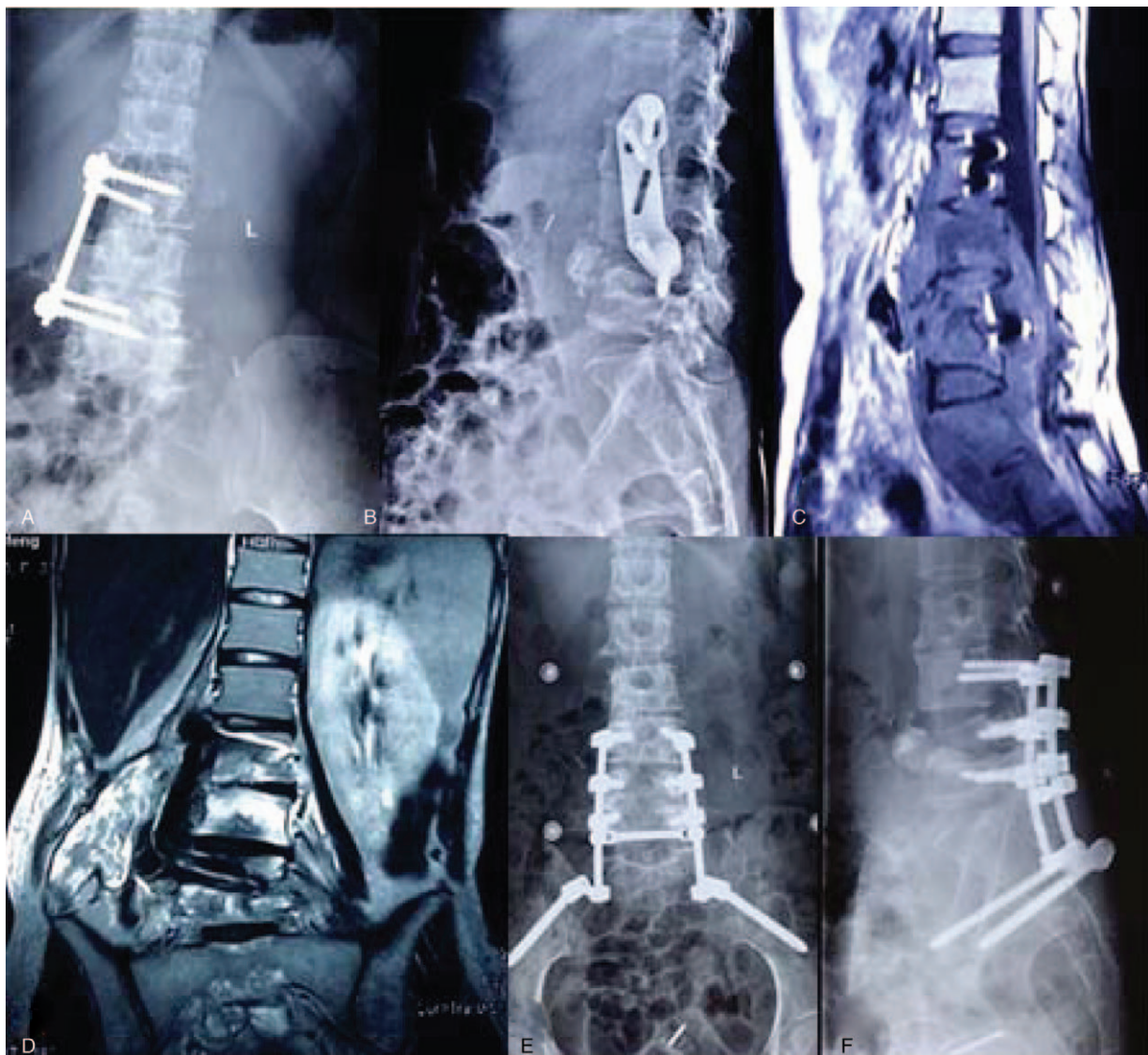


Figure 2. Case 2: A 63-year-old female with spinal tuberculosis recurrence after anterior approach. (A, B) radiographs showing screw dislocation. (C, D) MRI showed vertebral bone destruction and paravertebral abscess formation, serious spinal cord compression. (E, F) The patient underwent one-stage anterior debridement, interbody fusion, posterior instrumentation, and postural drainage. At final follow-up, fixation was in good shape, without signs of tuberculosis recurrence. CT=computed tomography, MRI=magnetic resonance imaging.

patients to postoperative relapse. Zachariah et al^[9] found that malnutrition in patients with tuberculosis is a risk factor associated with early death. In 2010, Moran-Mendoza et al^[10] reported that the main risk factors for TB development were malnutrition, and malnutrition as a better predictor of TB development. Furthermore, Xu et al^[11] suggested that effective nutritional support therapy enhances humoral immunity and cell-mediated immunity. The results of the present study demonstrate that malnutrition patients were more likely to suffer from postoperative tuberculosis relapse. Therefore, enhancement of nutrition and correction of anemia and hypoproteinemia are routinely carried out as a basic requirement of Pott's disease treatment.

In 1911, Albee and Hibbs treated Pott's disease with posterior bone graft fusion, but the result was unsatisfactory because of a dearth of effective anti-TB drugs at the time. It has been previously suggested that antituberculous chemotherapy has become the mainstay of the treatment of spinal tuberculosis. To

our knowledge, there is consensus on the period of postoperative standard chemotherapy, which may range from 12 to 18 months. Accordingly, our patients received the 4 drugs mentioned above for 3 months, and furthermore isoniazid, rifampicin and ethambutol for 9 to 15 months. Our series demonstrated that 18 patients had TB recurrence because of irregular anti-tuberculosis. There is no doubt that majority of spinal surgeons are aware of the importance of debridement in the treatment of Pott's disease. In our study, 15 patients failed to have radical debridement due to pleural adhesion, bilateral paravertebral abscess, gravitation abscess, or limited surgical vision. However, we believe that excessive surgical debridement should be avoided as this can cause iatrogenic instability.

Consistent with previous studies, our findings demonstrated that strict postoperative immobilization was as an independent predictor of recovery. Many studies have shown a direct correlation between sagittal spine imbalance and recurrence.^[12,13] In addition, early correction of spinal instability,

which is used to suppress the infection and afford a relatively stable internal environment to decrease recurrence, plays an important role in treating TB. To this end, patients treated at our hospital wore a brace for at least 3 months postoperatively. Patients carried out the day-to-day activities without bearing weight at first, and when fusion was confirmed by auxiliary examination, the patients were able to return normal life activities. Strict postoperative immobilization is the hinge of treatment for spinal tuberculosis as it helps to improve surgical outcomes by facilitating healing and reducing recurrence.

In our series, 9 patients had TB recurrence as a result of inappropriate surgical indication. Three different surgical methods (anterior approach, anterior and posterior approach, posterior approach) have been described for the management of Pott's disease up to now. The anteroposterior approach is suitable for patients with severe vertebral destruction, those who present with difficulties that preclude anterior fixation, or patients suffering from severe kyphosis. The anteroposterior approach allows for radical debridement and satisfactory correction of spinal deformities. However, disadvantages to the anteroposterior approach are also obvious. The results of the present study demonstrate that because 2 positions and 2 incisions are used in this procedure, a longer operation time, larger amount of bleeding, and larger wounds.^[14] Generally, the lesion is usually located in the anterior and middle column, the anterior approach creates enough operating space at a 360° angle under direct visualization for complete removal of the focal TB without injuring the spinal cord. However, it is difficult fixation of the lumbosacral segment. Additionally, anterior fixation is not reliable in patients with destruction of more than 3 adjacent vertebrae. This procedure may result in progression of kyphosis as a consequence of bone graft failure.^[15-18] The anterior approach is applicable to patients with vertebral destruction combined with abscess formation and those with anterior compression of the spinal cord.^[19] Because of the technical limitations of anterior fixation devices, patients with multi-vertebral destruction or who present difficulties for anterior fixation should not be treated by the anterior approach. The posterior-only approach remains controversial, because we

resected of the side of the facet joint, the diapophysis, costosternal joints and small rib portions, it may affect posterior spinal column stability.^[20,21] The procedure has the advantage of minor surgical invasion, effective kyphosis correction and less complications. It is contribute to postural drainage when the drain is placed from the posterior and then plays an important role in improving lesion healing and preventing sinus formation.^[22] In our study, we confirmed that the posterior only approach requires the following criteria: a mono-segment Pott's disease, small paravertebral abscess.

Abbas et al^[23] reported that local chemotherapy and systemic chemotherapy can be used to minimize surgical intervention in most patients. Regardless of treatment options, chemotherapy remains the cornerstone of treatment for tuberculosis. The most important question when using drugs to cure spinal TB is how to maximize the amount of drug reaching the lesions. Zhang et al^[24] found that local application of large doses of chemotherapy drugs, such as isoniazid, could kill pathogenic bacteria, thus preventing the development of further pathological changes. In our series, 9 patients underwent percutaneous intubation and low-dose irrigation under CT guidance. This is easy, safe, efficient, and less invasive methods for the treatment of postoperative relapse of Pott's disease. However, chemotherapy alone is suitable for patients with no obvious spinal instability because it can neither correct spinal deformity nor relieve canal compression. The advantages of using local chemotherapy to treat postoperative relapse of Pott's disease include simplicity, safety, short operative time and fewer complications. In addition, local chemotherapy quickly improves symptoms and attenuates illness (see).

The treatment of postoperative relapse of Pott's disease remains difficult and controversial, as individualized treatment is mandatory. The treatment methods depend on the patient's general condition, severity of the disease and the surgeon's experience and facilities, and focal characteristics of the occurrence, but above all is choice of chemotherapy regimen. In addition, good general supportive care and an effective chemotherapy regimen are the keys to the early eradication and minimizing recurrence of Pott's disease.

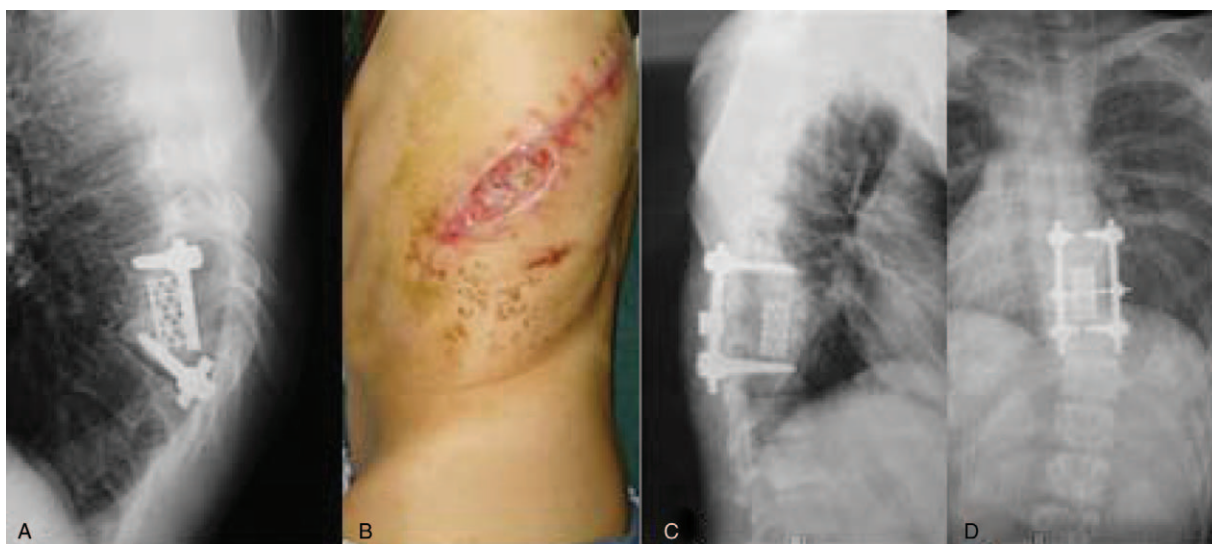

Figure 3. Case 3: A 45-year-old male was diagnosed as tuberculosis recurrence after anterior operation. (A, B) Postoperative x-ray showed fractures of titanium rods and sinus formation. (C, D) Radiographs showed correction of kyphosis and graft fusion after surgical revision.

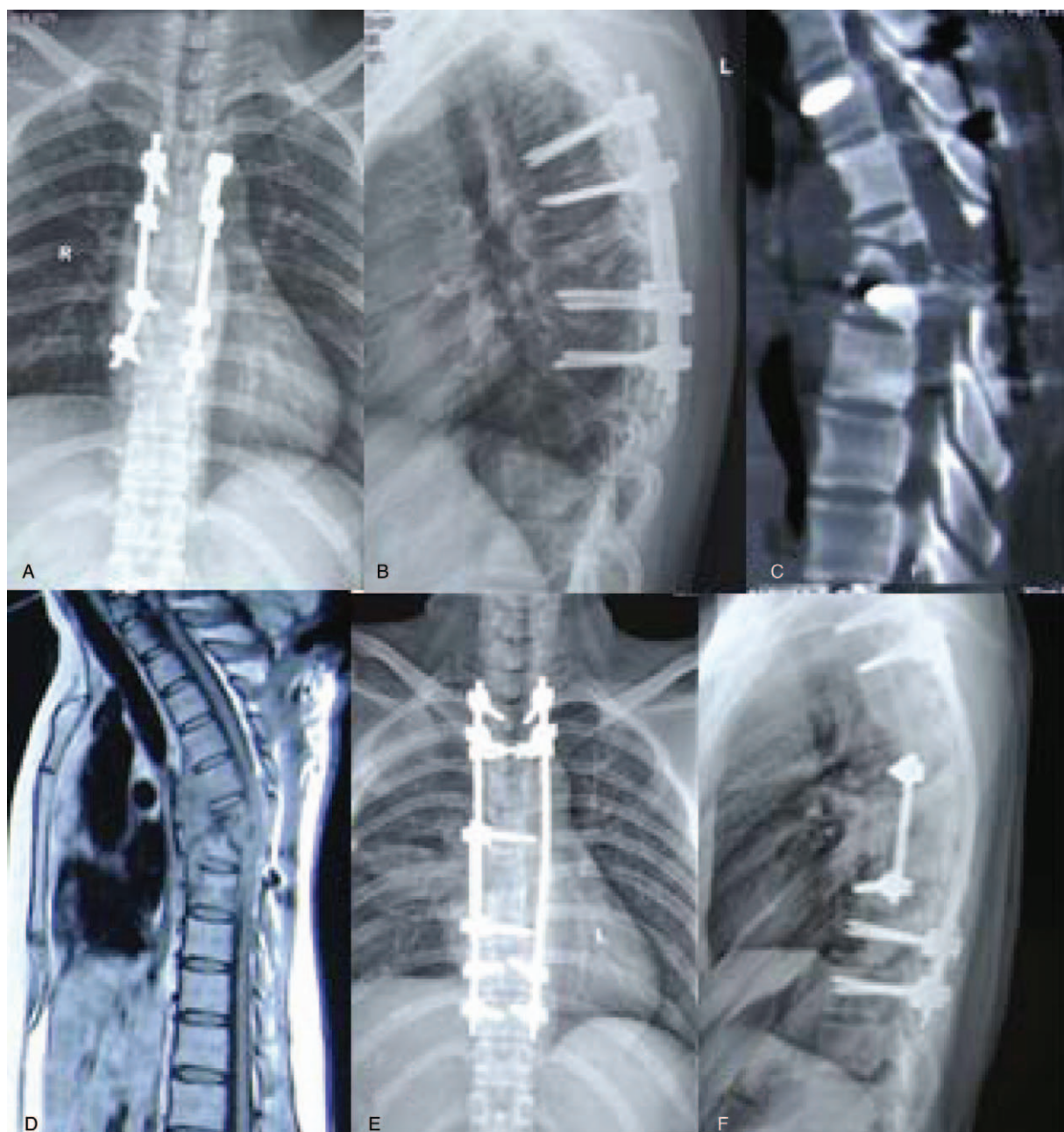


Figure 4. Case 4: A 25-year-old woman with tuberculous spondylitis recurrence after posterior surgery. (A–D) Postoperative radiographs, CT, and MRI showed that vertebral destruction and spinal cord compression after posterior operation. (E, F) Radiographs after surgical revision showed correction of kyphosis and graft fusion. CT=computed tomography, MRI=magnetic resonance imaging.

5. Conclusion

Our study demonstrates that the risks for postoperative recurrence in Pott's disease may be inappropriate surgery indication, malnutrition, irregular chemotherapy, non-radical debridement, and premature mobilization. Clinicians should take care to avoid those risk factors in perioperative period. Such efforts should lead to a decrease in the incidence of tuberculosis relapse, relieve patient suffering, and improve patient quality of life.

Author contributions

Conceptualization: Xinhua Yin.

Data curation: Xinhua Yin.

Formal analysis: Xinhua Yin.

Funding acquisition: Xinhua Yin.

Investigation: Xinhua Yin.

Project administration: Dingjun Hao.

Resources: Dingjun Hao.

Software: Dingjun Hao.

Supervision: Dingjun Hao.

Validation: Dingjun Hao.

Visualization: Dingjun Hao.

Writing – original draft: Zhongkai Liu.

Writing – review & editing: Zhongkai Liu.

References

- [1] Shi T, Zhang Z, Dai F, et al. Retrospective study of 967 patients with spinal tuberculosis. *Orthopedics* 2016;39:e838.
- [2] Wang X, Pang X, Wu P, et al. One-stage anterior debridement, bone grafting and posterior instrumentation vs. single posterior debridement, bone grafting, and instrumentation for the treatment of thoracic and lumbar spinal tuberculosis. *Eur Spine J* 2014;23:830–7.
- [3] Turgut M. Spinal tuberculosis (Pott's disease): its clinical presentation, surgical management, and outcome, a survey study on 694 patients. *Neurosurg Rev* 2001;24:8–13.
- [4] Zeng H, Shen X, Luo C, et al. Comparison of three surgical approaches for cervicothoracic spinal tuberculosis: a retrospective case-control study. *J Orthop Surg Res* 2015;10:1–0.
- [5] Qian J, Rijiepu A, Zhu B, et al. Outcomes of radical debridement versus no debridement for the treatment of thoracic and lumbar spinal tuberculosis. *Int Orthop* 2016;40:1–8.
- [6] Tuli SM. Tuberculosis of the spine: a historical review. *Clin Orthop Relat Res* 2007;460:29–38.
- [7] Lan X, Liu X, Ge B. Debridement and bone grafting with internal fixation via anterior approach for treatment of cervicothoracic tuberculosis. *Int Surg* 2011;96:358–62.
- [8] Moon MS, Kim S, Moon H. Tuberculosis of the spine: current views in diagnosis, management, and setting a global standard. *Orthop Trauma* 2013;27:185–94.
- [9] Zachariah R, Spielmann MP, Harries AD, et al. Moderate to severe malnutrition in patients with tuberculosis is a risk factor associated with early death. *Trans R Soc Trop Med Hyg* 2002;96:291–4.
- [10] Moran-Mendoza O, Marion SA, Elwood K, et al. Risk factors for developing tuberculosis: a 12-year follow-up of contacts of tuberculosis cases. *Int J Tuberc Lung Dis* 2010;14:1112–9.
- [11] Xu FL, Mai M, Dong XN, et al. The effect of nutritional support on immune function in critically ill patients. *Parent Enteral Nutr* 2006;13:221–3.
- [12] Glassman SD, Bridwell K, Dimar JR, et al. The impact of positive sagittal balance in adult spinal deformity. *Spine* 2005;4:S113–4.
- [13] Roussouly P, Nnadi C. Sagittal plane deformity: an overview of interpretation and management. *Eur Spine J* 2010;19:1824–36.
- [14] Zhang HQ, Li JS, Zhao SS, et al. Surgical management for thoracic spinal tuberculosis in the elderly: posterior only versus combined posterior and anterior approaches. *Arch Orthop Trauma Surg* 2012;132:1717–23.
- [15] Rajasekaran S, Soundarapandian S. Progression of kyphosis in tuberculosis of the spine treated by anterior arthrodesis. *J Bone Joint Surg* 1989;71:1314–23.
- [16] Alter AH. Tuberculosis of the spine in children: Operative findings and results in one-hundred consecutive patients treated by removal of the lesion and anterior grafting: HL Bailey, M. Gabriel, AR Hodgson, and JS Shin. *J Bone Joint Surg* 54: A1633-1657 (December), 1972. *J Pediatr Surg* 1973;8:567–8.
- [17] Fountain S, Hsu L, Yau A, et al. Progressive kyphosis following solid anterior spine fusion in children with tuberculosis of the spine. A long-term study. *J Bone Joint Surg* 1975;57:1104–7.
- [18] Upadhyay S, Sell P, Saji M, et al. 17-year prospective study of surgical management of spinal tuberculosis in children: Hong Kong operation compared with debridement surgery for short- and long-term outcome of deformity. *Spine* 1993;18:1704–11.
- [19] Pu X, Zhou Q, He Q, et al. A posterior versus anterior surgical approach in combination with debridement, interbody autografting and instrumentation for thoracic and lumbar tuberculosis. *Int Orthop* 2012;36:307.
- [20] Tuli S. Tuberculosis of the spine: a historical review. *Clin Orthop Relat Res* 2007;460:29–38.
- [21] Jain A. Tuberculosis of the spine a fresh look at an old disease. *J Bone Joint Surg* 2010;92:905–13.
- [22] Zhang H, Long W, Deng Z, et al. The correlative factors affected the clinical efficacy of one-stage surgical management of spinal tuberculosis with paraplegia. *Chin J Spine Spinal Cord* 2004;14:720–3.
- [23] Abbas A, Rizvi SRH, Mahesri M, et al. Conservative management of spinal tuberculosis: initial series from Pakistan. *Asian Spine J* 2013;7:73–80.
- [24] Zhang XF, Wang Y, Xiao SH, et al. Treatment of lumbar and lumbosacral spinal tuberculosis with minimally invasive surgery. *Orthop Surg* 2010;2:64–70.