



NOTE

Wildlife Science

Myxoma of the penis in an African pygmy hedgehog (*Atelerix albiventris*)

Yoshinori TAKAMI^{1,2)*}, Namie YASUDA¹⁾ and Yumi UNE¹⁾¹⁾The Laboratory of Veterinary Pathology, School of Veterinary Medicine Azabu University, 1-17-71 Fuchinobe, Chuo-ku, Sagami-hara, Kanagawa 252-5201, Japan²⁾Verts Animal Hospital, 2-21-5 Naka, Hakata-ku, Fukuoka-shi, Fukuoka 812-0893, Japan

ABSTRACT. A penile tumor (4 × 2.5 × 1 cm) was surgically removed from an African pygmy hedgehog (*Atelerix albiventris*) aged 3 years and 5 months. The tumor was continuous with the dorsal fascia of the penile head. Histopathologically, tumor cells were pleomorphic (oval-, short spindle- and star-shaped cells) with low cell density. Abundant edematous stroma was weakly positive for Alcian blue staining and positive for colloidal iron reaction. Tumor cells displayed no cellular atypia or karyokinesis. Tumor cell cytoplasm was positive for vimentin antibody, while cytoplasm and nuclei were positive for S-100 protein antibody. Tumor cell ultrastructure matched that of fibroblasts, and the rough endoplasmic reticulum was enlarged. The tumor was diagnosed as myxoma. This represents the first report of myxoma in a hedgehog.

KEY WORDS: hedgehog, myxoma, neoplasia, penis

J. Vet. Med. Sci.

79(1): 171–174, 2017

doi: 10.1292/jvms.16-0294

Received: 3 June 2016

Accepted: 14 October 2016

Published online in J-STAGE:
27 October 2016

The African pygmy hedgehog (*Atelerix albiventris*) has recently become popular as an exotic pet [5, 11, 14, 22, 24]. African pygmy hedgehogs are sometimes brought to veterinary clinics for examination, and multiple reports of tumors have been published [6–9]. A retrospective study of tumors in this species shows that the median age at the time of diagnosis is 3.5 years and that 80% or more of the tumors are malignant [20]. Tumors in the African pygmy hedgehog can occur in various organs and parts of the body [2, 4, 5, 8, 12, 13, 16, 18, 21, 23], but as far as we are aware, there have been no reports to date of tumors occurring on the penis. Here, we report the pathological and clinical features and prognosis of a case of myxoma of the penis in an African pygmy hedgehog.

The male African pygmy hedgehog was 3 years and 5 months old and weighed 648 g. It had been brought to the clinic with the chief complaint of loss of appetite and swelling of the lower abdominal region around the penis (Fig. 1). Physical examination revealed that the penis could not be readily extruded from the prepuce and a soft tumor was palpable inside the sheath. Ultrasonographic and radiographic examinations of the chest and abdomen showed no abnormalities other than the tumor inside the penile sheath. Hematological examination and 14-item plasma biochemistry revealed no abnormalities. As the tumor was large and could not be readily extruded from the prepuce, the animal was anesthetized, and pressure was gradually applied to the tumor to bring both the tumor and penis out of the penile sheath. The tumor was elliptical, 4 cm long along the major axis, and continuous with the fascia of the dorsal side of the head of the penis (Fig. 2). The tumor was easily separated and surgically removed from the fascia. The animal showed satisfactory recovery as of 100 days postoperatively, with no lymph node swelling or other clinical abnormalities observed.

The excised tumor was elliptical, 4 × 2.5 × 1 cm in size and grayish-white in color. The mass was covered by a distinct, thin membrane, had a smooth surface and was highly elastic. Section of the tumor revealed a gelatinous, somewhat-transparent material (Fig. 2a). The excised tumor tissue was fixed in 20% formalin, embedded in paraffin, cut into 4- μ m-thick sections and stained with hematoxylin and eosin. Some tumor sections were also stained with periodic acid-Schiff, Alcian blue and colloid iron reaction for mucus. Immunohistochemistry was applied to paraffin-embedded sections. These samples were incubated with primary antibodies to vimentin and S-100 protein (Dako, Carpinteria, CA, U.S.A.), as two antibodies that react to normal body tissues (mesenchymal cells and nerve fiber bundles, respectively) of the African hedgehog. Peroxidase-conjugated secondary antibody (Histofine; Nichirei, Tokyo, Japan) was then applied and visualized using diaminobenzidine. Solid proliferation of tumor tissue was present in the submucosal tissue directly below the mucous membrane of the penis. The tumor tissue showed abundant edematous connective tissue stroma, but the amount of connective tissue varied in different areas. The overall density of tumor cells was low. Tumor cells displayed small, oval or occasionally irregular chromatin-rich nuclei and scant eosinophilic cytoplasm (Fig. 3). These cells showed morphological variation, with oval, short spindle-shaped and star-shaped cells (Fig. 3a). Some tumor cells were binuclear, although

*Correspondence to: Une, Y., The Laboratory of Veterinary Pathology School of Veterinary Medicine Azabu University, 1-17-71 Fuchinobe, Chuo-ku, Sagami-hara, Kanagawa 252-5201, Japan. e-mail: une@azabu-u.ac.jp

©2017 The Japanese Society of Veterinary Science



This is an open-access article distributed under the terms of the Creative Commons Attribution Non-Commercial No Derivatives (by-nc-nd) License <<http://creativecommons.org/licenses/by-nc-nd/4.0/>>.

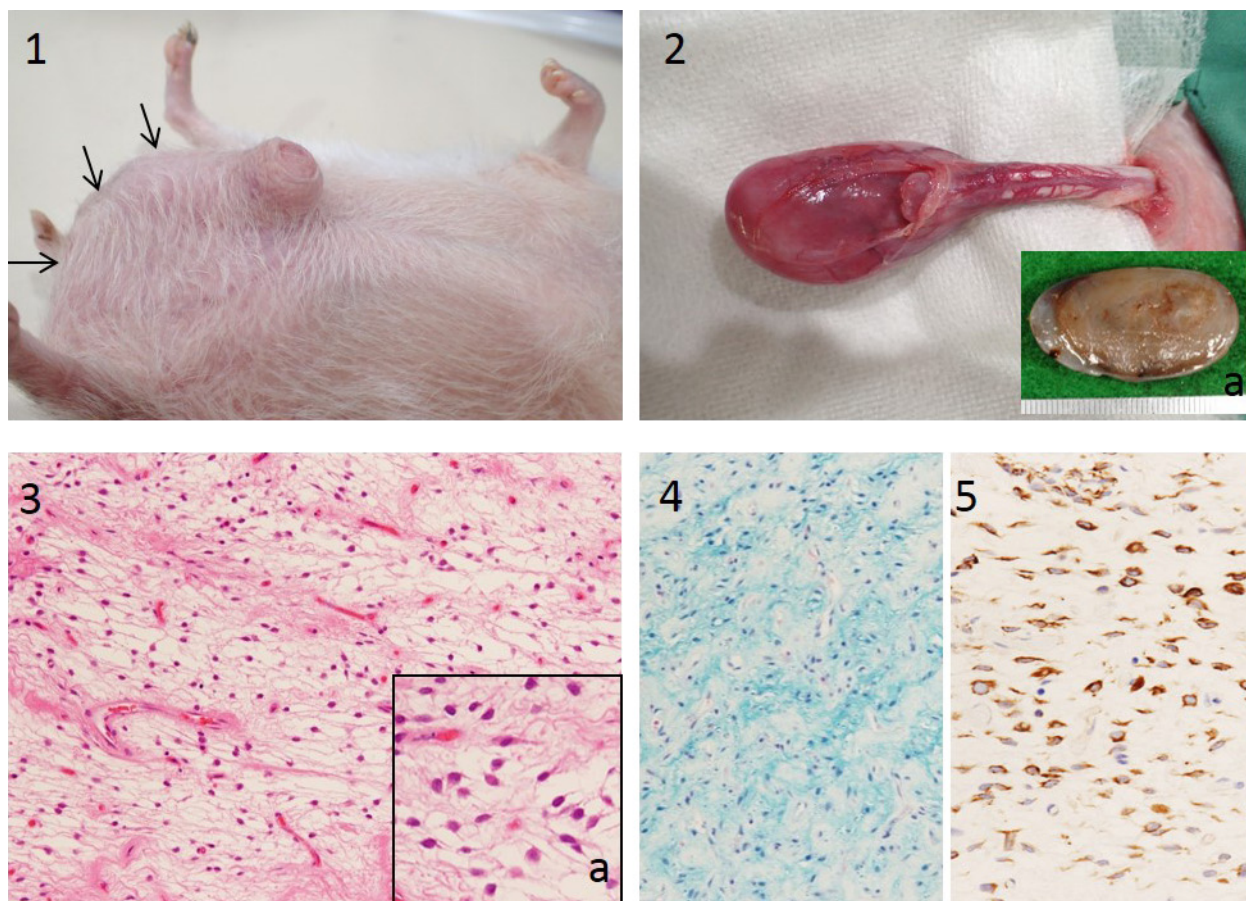


Fig. 1. Swelling of the lower abdomen (arrows). Visual examination shows extension of the opening of the penile sheath; the mucous membrane of the penile sheath is exposed.

Fig. 2. External view of the tumor. The tumor is continuous with the fascia of the dorsal side of the head of the penis. a) Section of the tumor. The section shows a gelatinous, somewhat-transparent material.

Fig. 3. Tumor tissue under low-power magnification. The nuclei of tumor cells are small and oval (or sometimes irregular), rich in chromatin, and have scant eosinophilic cytoplasm. a) Tumor tissue under high-power magnification. The morphology of tumor cells varies, including oval, short spindle-shaped and star-shaped cells.

Fig. 4. Special staining of tumor tissue. The edematous stroma of tumor tissue is weakly positive for Alcian blue staining and shows a positive colloidal iron reaction.

Fig. 5. Immunostaining of tumor tissue. The cytoplasm of tumor cells stains positive for vimentin antibody.

the nuclei were not different in size and no karyokinesis was apparent. In addition, some tumor cells had vacuoles of various sizes. The edematous stroma of the tumor tissue was weakly positive on Alcian blue staining and positive for the colloidal iron reaction (Fig. 4), but the intensity of staining varied in different areas. On immunostaining, the cytoplasm of tumor cells showed positive results for vimentin antibody (Fig. 5), and the cytoplasm and nuclei were positive for S-100 protein antibody. A clear boundary was seen between the tumor and surrounding tissue. Electron microscopy revealed that the tumor cells had cytoplasmic protuberances of different lengths, but no intertwining of these protuberances was observed and no basilar membranes or intercellular junctions were evident (Fig. 6). Tumor cell organelles were highly developed, with abundant rough endoplasmic reticulum that, in some places, had become enlarged with amorphous material of moderate electron density. In addition, small vacuoles that lacked a limiting membrane were observed (Fig. 7). Some of the nuclei displayed a deep notch, while others were circular.

Mucosal tissue comprises star-shaped cells and small numbers of cell fibers, with stroma that includes abundant mucopolysaccharides. Such tissue can be found in the umbilical cord of a developed fetus. Tumors that exhibit tissue morphology resembling this mucosal tissue are known as myxomas [27]. The histological features and special staining characteristics of the present case were consistent with those of myxoma, so myxoma was diagnosed. Myxomas originate from fibroblasts or multipotent mesenchymal cells with abundant mucus [7]. Myxomatous stromal changes are also seen in tumors of other origins, such as myxoid liposarcoma, so differentiation from other diseases is needed (or great care must be taken with diagnosis) [25]. In the present case, the tumor was positive for the nervous system marker, anti-S-100 protein antibody, but the anti-S-100 protein antibody used in this case has not been confirmed as valid in distinguishing nervous system tumors in hedgehogs. Moreover, at an

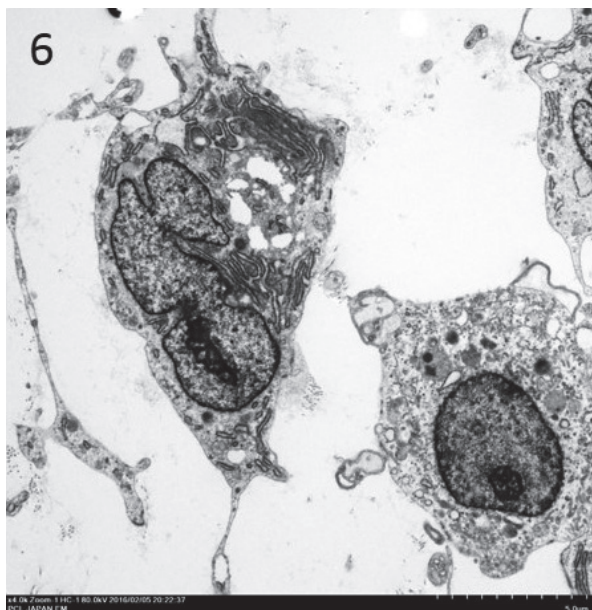


Fig. 6. Electron micrograph of tumor tissue. Tumor cells show protuberances of different lengths, but no intertwining of these protuberances is seen and no basilar membranes or intercellular junctions are evident.

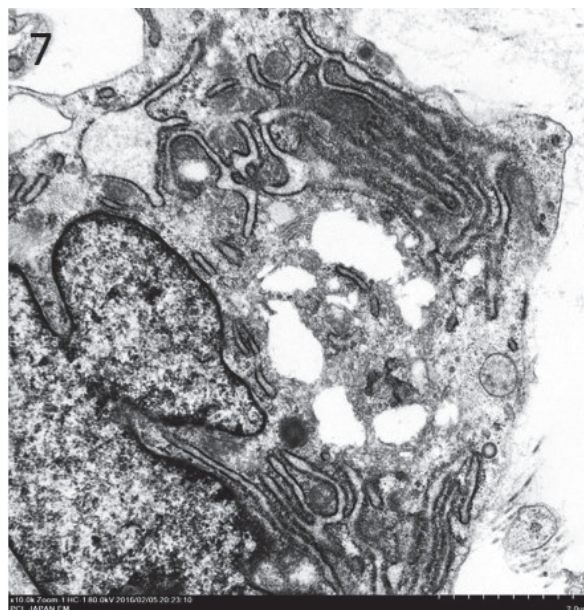


Fig. 7. Electron micrograph of tumor tissue. Organelles of tumor cells are highly developed; in particular, a large amount of rough endoplasmic reticulum is seen. This organelle sometimes includes amorphous material of moderate electron density and thus becomes enlarged. In addition, small vacuoles that lack a limiting membrane are apparent.

ultrastructural level, none of the characteristics of nerve sheath cells were observed in the tumor cells. Consequently, a diagnosis of nervous system tumor was rejected. While vacuoles of various sizes were observed in the cytoplasm of tumor cells, electron microscopy revealed no lipid droplets. The vacuoles were therefore judged to represent enlarged rough endoplasmic reticulum. In addition, the tumor cells did not present an atypical appearance, so myxoid liposarcoma was ruled out. As the ultrastructure of the tumor cells in the present case matched that of fibroblasts, the tumor was conjectured to have originated from fibrous cells, such as fibroblasts.

Myxoma is a benign soft-tissue neoplasm that is extremely rare in both humans and other animals. Myxoma has been reported in rabbits, and atrial myxoma has been reported in dogs [3, 17]. Myxoma arises from primitive mesenchymal cells, which produce abundant extracellular matrix comprising fibrocytes and mucin [1]. Myxoma may occur in various sites, including the heart, bone, hypodermis, tendon, urogenital organs and skeletal muscle, but the pathogenesis remains unclear [26]. Genetic and environmental factors, carcinogens and various toxic substances have been suggested as causes [15]. In the present case, no causal relationship with any of these factors was clear, and no traces of chronic inflammation or continuous stimulation of the penis or surrounding tissues were evident. In hedgehogs, the skin is the most common site for tumors, and nerve sheath tumor, plasmocytoma, angiosarcoma, fibrosarcoma, osteosarcoma, mastocytoma and breast tumor have all been reported [8, 12, 18–20]. However, no reports appear to have described myxoma in these or other sites. To the best of our knowledge, no previous reports have described tumor of the penis or prepuce in exotic pet animals, such as the hedgehog and although papilloma has been observed in livestock [10], that pathology shows notable differences in gross form from the present case. Discrimination was therefore relatively straightforward. In the present case, the myxoma was large and some tumor cells were binuclear, but cellular appearance was not atypical and no karyokinesis or necrosis was evident. No metastasis to the associated lymph nodes or other sites was observed, and with no clinical abnormalities observed even at 100 days postoperatively, the animal was considered to have a favorable prognosis. The present case represents the first report of myxoma in an African pygmy hedgehog.

REFERENCES

- Allen, P. W. 2000. Myxoma is not a single entity: a review of the concept of myxoma. *Ann. Diagn. Pathol.* **4**: 99–123. [Medline] [CrossRef]
- Benneter, S. S., Summers, B. A., Schulz-Schaeffer, W. J., Härtig, W., Mollitor, J. and Schöniger, S. 2014. Mixed glioma (oligoastrocytoma) in the brain of an African hedgehog (*Atelerix albiventris*). *J. Comp. Pathol.* **151**: 420–424. [Medline] [CrossRef]
- Bertagnoli, S. and Marchandau, S. 2015. Myxomatosis. *Rev. - Off. Int. Epizoot.* **34**: 549–556, 539–547. [Medline]
- Chung, T. H., Kim, H. J. and Choi, U. S. 2014. Multicentric epitheliotropic T-cell lymphoma in an African hedgehog (*Atelerix albiventris*). *Vet. Clin. Pathol.* **43**: 601–604. [Medline] [CrossRef]
- Dierenfeld, E. S. 2009. Feeding behavior and nutrition of the african pygmy hedgehog (*Atelerix albiventris*). *Vet. Clin. North Am. Exot. Anim. Pract.* **12**: 335–337, x. [Medline] [CrossRef]

6. Done, L. B., Deem, S. L. and Fiorello, C. V. 2007. Surgical and medical management of a uterine spindle cell tumor in an African hedgehog (*Atelerix albiventris*). *J. Zoo Wildl. Med.* **38**: 601–603. [[Medline](#)] [[CrossRef](#)]
7. Ginn, P. E., Mansell, J. E. K. L. and Rakich, P. M. 2007. Chapter 5: Skin and appendages. pp. 553–781. *In: Pathology of Domestic Animals*, 5th ed. Vol. 1 (Maxie, M. G. ed.), Saunders, Philadelphia.
8. Heatley, J. J., Mauldin, G. E., Glenna, E. and Cho, D. Y. 2005. A review of neoplasia in the captive African hedgehog (*Atelerix albiventris*). *Semin. Avian Exotic Pet Med.* **14**: 182–192. [[CrossRef](#)]
9. Johnson, D. 2014. African pygmy hedgehogs. pp. 139–147. *In: BSAVA Manual of Exotic Pets*, 5th ed. (Meredith, A. and Delaney, C. J. eds.), Quedgeley, Gloucester.
10. Kennedy, P. C., Cullen, J. M., Edwards, J. F., Goldschmidt, M. H., Larsen, S., Munson, L. and Nielsen, S. 1998. Definitions and explanatory notes. pp. 15–38. *In: Histological Classification of Tumors of Genital System of Domestic Animals Second Series* (Schulman, F. Y. ed.), vol.4, Armed Forces Institute of Pathology, Washington.
11. Lennox, A. M. 2007. Emergency and critical care procedures in sugar gliders (*Petaurus breviceps*), African hedgehogs (*Atelerix albiventris*), and prairie dogs (*Cynomys* spp). *Vet. Clin. North Am. Exot. Anim. Pract.* **10**: 533–555. [[Medline](#)] [[CrossRef](#)]
12. Martin, K. K. and Johnston, M. S. 2006. Forelimb amputation for treatment of a peripheral nerve sheath tumor in an African pygmy hedgehog. *J. Am. Vet. Med. Assoc.* **229**: 706–710. [[Medline](#)] [[CrossRef](#)]
13. Matute, A. R., Bernal, A. M., Lezama, J. R., Guadalupe, M. P. and Antonio, G. A. 2014. Sebaceous gland carcinoma and mammary gland carcinoma in an African hedgehog (*Ateletrix albiventris*). *J. Zoo Wildl. Med.* **45**: 682–685. [[Medline](#)] [[CrossRef](#)]
14. Mori, M. and O'Brien, S. E. 1997. Husbandry and medical management of African hedgehogs. *Iowa State Univ. Vet.* **59**: 64–71.
15. Muller, G. H., Kirk, R. W. and Scot, D. W. 1993. Neoplastic diseases. pp.743–744. *In: Small Animal Dermatology*, 3rd ed. (Hnilica, K. A. ed.), W.B. Saunders Company, Philadelphia.
16. Nakata, M., Miwa, Y., Itou, T., Uchida, K., Nakayama, H. and Sakai, T. 2011. Astrocytoma in an African hedgehog (*Atelerix albiventris*) suspected wobbly hedgehog syndrome. *J. Vet. Med. Sci.* **73**: 1333–1335. [[Medline](#)] [[CrossRef](#)]
17. Ori, J., Yamaguchi, T., Sasa, Y., Komiya, M. and Narama, I. 1994. A case of canine cardiac myxoma. *J. Jpn. Vet. Med. Assoc.* **47**: 499–501. [[CrossRef](#)]
18. Ramos-Vara, J. A. 2001. Soft tissue sarcomas in the African hedgehog (*Atelerix albiventris*): microscopic and immunohistologic study of three cases. *J. Vet. Diagn. Invest.* **13**: 442–445. [[Medline](#)] [[CrossRef](#)]
19. Raymond, J. T. and Gerner, M. 2000. Mammary gland tumors in captive African hedgehogs. *J. Wildl. Dis.* **36**: 405–408. [[Medline](#)] [[CrossRef](#)]
20. Raymond, J. T. and Garner, M. M. 2001. Spontaneous tumours in captive African hedgehogs (*Atelerix albiventris*): a retrospective study. *J. Comp. Pathol.* **124**: 128–133. [[Medline](#)] [[CrossRef](#)]
21. Rhody, J. L. and Schiller, C. A. 2006. Spinal osteosarcoma in a hedgehog with pedal self-mutilation. *Vet. Clin. North Am. Exot. Anim. Pract.* **9**: 625–631. [[Medline](#)] [[CrossRef](#)]
22. Riley, P. Y. and Chomel, B. B. 2005. Hedgehog zoonoses. *Emerg. Infect. Dis.* **11**: 1–5. [[Medline](#)] [[CrossRef](#)]
23. Rivera, R. Y. and Janovitz, E. B. 1992. Oronasal squamous cell carcinoma in an African hedgehog (*Erinaceidae albiventris*). *J. Wildl. Dis.* **28**: 148–150. [[Medline](#)] [[CrossRef](#)]
24. Smith, A. J. 1999. Husbandry and nutrition of hedgehogs. *Vet. Clin. North Am. Exot. Anim. Pract.* **2**: 127–141, vii. [[Medline](#)]
25. Weiss, S. W. and Goldblum, J. R. 2008. Cutaneous myxoma (superficial angiomyxoma). pp. 1076–1080. *In: Soft Tissue Tumors*, 5th ed. (Weiss, S. W. and Goldblum, J. R. eds.), Mosby, Philadelphia.
26. West, W. L., Gaillard, E. T. and O'Connor, S. A. 2001. Fibroma (myxoma) molle in a hamster (*Mesocricetus auratus*). *Contemp. Top. Lab. Anim. Sci.* **40**: 32–34. [[Medline](#)]
27. Willems, S. M., Wiweger, M., van Roggen, J. F. and Hogendoorn, P. C. 2010. Running GAGs: myxoid matrix in tumor pathology revisited: what's in it for the pathologist? *Virchows Arch.* **456**: 181–192. [[Medline](#)] [[CrossRef](#)]