

Aquaporin-4 positive neuromyelitis optica spectrum disorders secondary to thrombopenic purpura

A case report

Ying Wang, MD^a, Qiaoyun Gong, MD^b, Mingqin Zhu, MD, PhD^a, Chao Lu, MD^a, Li Sun, MD^a, Jiachun Feng, MD, PhD^{a,*}, Hongliang Zhang, MD, PhD^{a,c,*}

Abstract

Rationale: Neuromyelitis optica spectrum disorders (NMOSD) is considered as an immune-mediated disorder in the central nervous system (CNS). Numerous autoimmune diseases are frequently complicated with NMOSD and distinct clinical characteristics are noted in NMOSD patients with other autoimmune diseases. However, to our best knowledge, co-occurrence of NMOSD and thrombopenic purpura is rarely identified.

Patient concerns: We presented a rare case of a 72-year-old female with 6-year history of thrombopenic purpura, and 1-month history of blurred vision as well as chest zoster. Anti-aquaporin-4 (AQP4) antibodies was positive in the serum of the patient.

Diagnoses: With the addition of laboratory findings, iconography findings and physical examination results, the diagnosis of NMOSD was established according to the most recent diagnostic criteria.

Interventions and outcomes: With the treatment of intravenous immunoglobulin (IVIg), the patient felt better at discharge without changing of expanded disability status scale (EDSS) score.

Lessons: The case indicates that NMOSD could co-occur with thrombopenic purpura. The disturbance of immune system balance may explain this overlap. Further studies are warranted to reveal the mechanism and to explore whether patients with NMOSD with and without thrombopenic purpura have distinct clinical feature, drug responsiveness or prognosis.

Abbreviations: AQP4 = aquaporin-4, CNS = central nervous system, EDSS = expanded disability status scale, IVIg = intravenous immunoglobulin, NMOSD = neuromyelitis optica spectrum disorders.

Keywords: anti-aquaporin-4 antibody, autoimmune disease, intravenous immunoglobulin, neuromyelitis optica spectrum disorders, thrombopenic purpura

1. Introduction

Neuromyelitis optica spectrum disorders (NMOSD) is considered as an immune-mediated disorder in central nervous system

Editor: Massimo Tusconi.

Funding: The work was supported by grants from the Elite PHD Program of Bethune Health Science Center, Jilin University (no. 470110000421).

The authors have no conflicts of interest to disclose.

^a Department of Neurology, the First Hospital of Jilin University, ^b Department of Ophthalmology, the Second Hospital of Jilin University, Changchun, ^c Current address: Department of Life Sciences, the National Natural Science Foundation of China, Beijing, China.

* Correspondence: Jiachun Feng, Department of Neurology, the First Hospital of Jilin University, Xinmin Street 71#, 130021 Changchun, China (e-mail: fengjcfank@qq.com); Hongliang Zhang, Department of Neurology, the First Hospital of Jilin University, Xinmin Street 71#, 130021 Changchun, China (e-mail: drzh@hotmail.com).

Copyright © 2017 the Author(s). Published by Wolters Kluwer Health, Inc. This is an open access article distributed under the terms of the Creative Commons Attribution-Non Commercial License 4.0 (CCBY-NC), where it is permissible to download, share, remix, transform, and buildup the work provided it is properly cited. The work cannot be used commercially without permission from the journal.

Medicine (2017) 96:2(e5792)

Received: 21 April 2016 / Received in final form: 30 November 2016 / Accepted: 3 December 2016

<http://dx.doi.org/10.1097/MD.0000000000005792>

(CNS), mainly affecting the optic nerves and spinal cord. Aquaporin-4 (AQP4)-IgG is believed to be responsible in the pathogenesis of NMOSD, and the possible mechanisms includes complement-dependent cytotoxicity as well as antibody-dependent cellular cytotoxicity.^[1] Cytokines, chemokines, and other molecular biomarkers of inflammation are also involved in the development of NMOSD.^[2] The most recent diagnostic criteria of NMOSD is based on a combination of anti-AQP4 detection, clinical presentation, and MRI finding.^[3] Expanded disability status scale (EDSS) is a widely used scale to evaluate the severity of multiple sclerosis,^[4] however, it is applicable in NMOSD as well. According to the guideline proposed by the British Society of Haematology, the development of thrombopenic purpura is partly due to the platelet destruction mediated by autoantibodies targeting platelets.^[5] The diagnosis of thrombopenic purpura is based on the medical history, results of physical examinations, complete blood count, and peripheral smear.^[5] Although the mechanism remains unrevealed, approximately 25% of all NMOSD patients have other concomitant autoimmune disorders.^[6,7] Nevertheless, the overlap of NMOSD and thrombopenic purpura has scarcely been reported.

2. Ethic statement

This study was approved by the ethics committee of the First Hospital of Jilin University, Changchun, China. Written informed consent was obtained from the patient.

Table 1**Evaluation of expanded disability status scale score.**

Function system score/ambulation score/EDSS score	Detail	Description
Converted visual functional system score	3	Right eye with maximal visual acuity less than 0.1
Brainstem functional system score	0	No brainstem involvement
Pyramidal functional score	2	Muscle strength of 3 in the lower extremities
Cerebellar functional score	X	Not available
Sensory functional score	3	Moderate pain of the lower extremities
Converted bowel/bladder functional score	1	Mild constipation
Ambulation score	9	Walk approximately 30 m with bilateral assistance
EDSS score	6.5	Ambulation score of 9

EDSS = expanded disability status scale.

3. Case presentation

We presented a case of a 72-year-old female who complained of reduced vision of right eye and severe chest zonesthesia for about 1 month. At the age of 66, the patient was diagnosed with thrombopenic purpura based on following findings: clinical findings (ecchymosis of left iliac skin, gum bleeding); blood routine examination findings (white blood cell count, $5.8 \times 10^9/L$, reference range: $4.0\text{--}10.0 \times 10^9/L$; red blood cell count, $4 \times 10^{12}/L$, reference range: $3.5\text{--}5.0 \times 10^{12}/L$; platelet count, $9 \times 10^9/L$, reference range: $100\text{--}300 \times 10^9/L$); myelogram findings (dysmaturity of macrophage, platelets were barely observed).

At present, she complained of reduced vision of right eye and severe chest zonesthesia for approximately 1 month. Physical

examination was performed and her EDSS score was 6.5 (Table 1). The detection of anti-APQ4 IgG via a cell-based assay was performed (Euroimmun, Stockholm, Sweden). Briefly, the serum was incubated with the combinations of substrates. If the

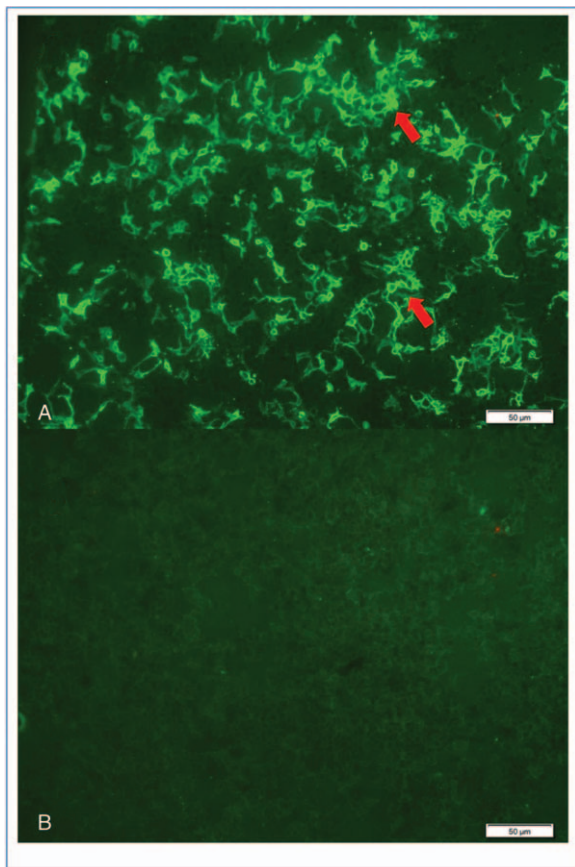


Figure 1. Antiaquaporin-4 (AQP4) antibody detection. (A) The anti-AQP4 antibody was positive in the serum of the patient (red arrows). (B) No fluorescence was observed in negative control.

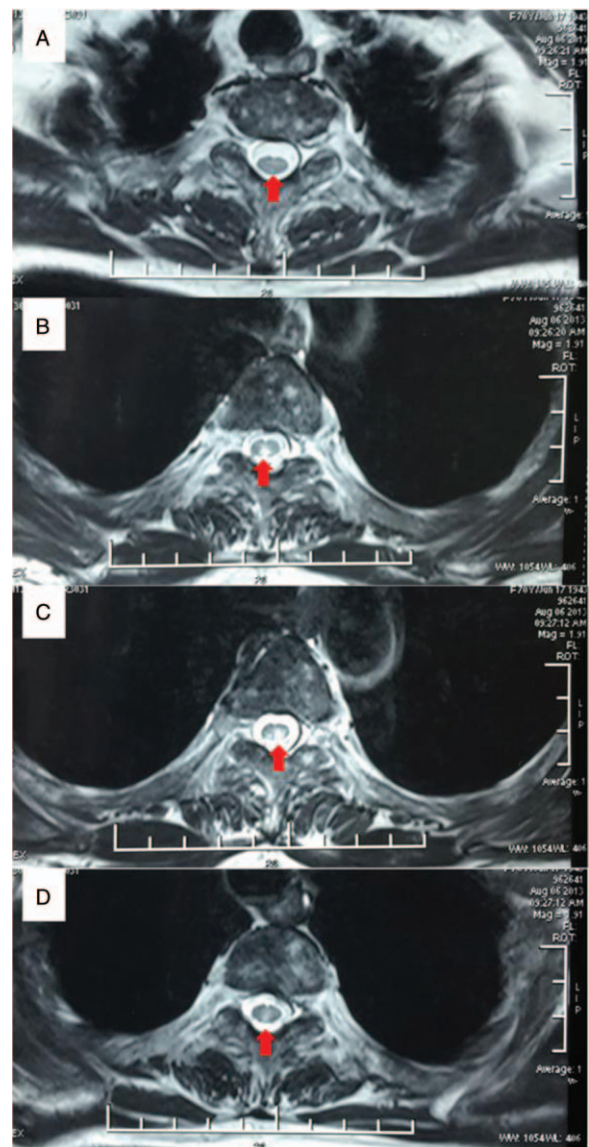


Figure 2. MRI of the spinal cord. MRI of spinal cord demonstrates abnormal signal intensity (red arrows) that extends from the level of the third to the sixth thoracic vertebrae in the horizontal plane.

reaction was positive, antibodies of IgA, IgG, and IgM were binding to the antigens. In the next step, a fluorescence microscope was used to observe the attached antibodies, which were stained by fluorescein-labeled antibodies. The serum anti-AQP4 IgG of the patient was positive (Fig. 1A), and the negative control (without serum) is presented in Fig. 1B. The results of laboratory routine examinations including complete blood count, urine, coagulation, creatinine, electrolytes, liver function tests, fasting blood glucose, and serum lipid were normal. The level of serum folic acid, vitamin B12, tumor biomarkers, paraneoplastic biomarkers were within the reference range. The results of autoimmune diseases related blood examinations were normal as well. Valid evoked wave of right eye was absent on the pattern visual evoked potential examination, and unstable waves were observed of both eyes on flashed-elicited visual evoked potential examination. MRI of the spinal cord revealed a T2-hyperintense lesion (Fig. 2). As the lesion was not showed clearly on sagittal scans, only horizontal scans are presented in Fig. 2. No significant lesion was identified on brain MRI. The diagnosis of NMOSD could be established according to medical history, physical examination, laboratory examination, and MRI findings.^[3] With the consideration of her medical history of bilateral necrosis of femoral heads and the unavailability of plasma exchange equipment in the hospital, intravenous immunoglobulin (IVIg) treatment at a dose of 0.4 g/kg daily was performed for 5 consecutive days. Though the EDSS score was not improved, the patient felt better at discharge.

4. Discussion

We have presented a rare case of anti-AQP4 positive NMOSD coexisting with thrombopenic purpura. With the combination of optic neuritis, acute myelitis, serum anti-AQP4 IgG positivity and exclusion of differential diagnosis, the diagnosis of NMOSD could be established according to the most recent diagnostic criteria.^[3] A growing body of evidence demonstrates a close relationship between NMOSD and other autoimmune diseases.^[6] Zhang et al^[6] retrospectively compared the clinical features between NMOSD patients with and without autoimmune diseases, and concluded that NMOSD patients with coexisting autoimmune diseases had more brain lesions. Though multiple lines of evidence point out that NMOSD could complicate with various other autoimmune diseases and NMOSD with other autoimmune diseases may have distinct clinical features,^[6,7] thrombopenic purpura has been rarely

identified in NMOSD patients. Investigations to explain the association between NMOSD and other autoimmune diseases are not available currently; nevertheless, the disturbance of the immune system may be to blame. Both humoral and cell-mediated mechanisms contribute to the pathogenesis of thrombopenic purpura.^[5] Antiplatelet antibody generation and Th0/Th1 cytokine profile imbalance play an important role in the development of thrombocytopenia.^[5] Similarly, anti-AQP4 production and abnormal secretion of cytokines/chemokines are found responsible for the occurrence of NMOSD.^[2] Thus, disorders of the immune system may serve as a bridge between NMOSD and thrombopenic purpura. Further studies are warranted to explain the association between NMOSD and thrombopenic purpura. Whether the NMOSD patients with and without thrombopenic purpura have distinct clinical features, drug responsiveness, or prognosis need to be further explored.

5. Summary

We presented a rare case of anti-AQP4 positive NMOSD coexisting with thrombopenic purpura. The disorders of immune system may be the mechanism of the overlap of thrombopenic purpura and NMOSD. Further studies are needed to explain this temporal association.

References

- [1] Ratelade J, Verkman AS. Neuromyelitis optica: aquaporin-4 based pathogenesis mechanisms and new therapies. *Int J Biochem Cell Biol* 2012;44:1519–30.
- [2] Melamed E, Levy M, Waters PJ, et al. Update on biomarkers in neuromyelitis optica. *Neurol Neuroimmunol Neuroinflamm* 2015;2:e134.
- [3] Wingerchuk DM, Banwell B, Bennett JL, et al. International consensus diagnostic criteria for neuromyelitis optica spectrum disorders. *Neurol Neuroimmunol Neuroinflamm* 2015;85:177–89.
- [4] Kurtzke JF. Natural history and clinical outcome measures for multiple sclerosis studies. Why at the present time does EDSS scale remain a preferred outcome measure to evaluate disease evolution? *Neurol Sci* 2000;21:339–41.
- [5] Lo E, Deane S. Diagnosis and classification of immune-mediated thrombocytopenia. *Autoimmun Rev* 2014;13:577–83.
- [6] Zhang BJ, Zhong Y, Wang YQ, et al. Neuromyelitis optica spectrum disorders without and with autoimmune disease. *BMC Neurol* 2014;14:162.
- [7] Freitas E, Guimaraes J. Neuromyelitis optica spectrum disorders associated with other autoimmune diseases. *Rheumatol Int* 2015;35:243–53.