



Case report

The high subangulomandibular approach for condylar fractures of the mandible

Amine Kaouani^{a,*}, Ouassime Kerdoud^a, Rachid Aloua^a, Ayoub Sabr^a, Faical Slimani^{a,b}

^a Department of Stomatology and Maxillofacial Surgery, 20 August 1953 Hospital, Ibn Rochd, B.P 2698, Casablanca, Morocco

^b Faculty of Medicine and Pharmacy of Casablanca, Hassan II University of Casablanca, B.P 5696, Casablanca, Morocco



ARTICLE INFO

Keywords:

Facial trauma

Fracture of the mandibular condyle

High subangulomandibular approach

ABSTRACT

Introduction: The approaches to mandibular condyle fractures are described in the literature in an abbreviated manner. Their complications, especially facial nerve damage, have limited the surgical indication.

Presentation of case: Through this clinical case, we reported the way and the interest of using a twisted steel wire to increase the visibility of the fracture site and facilitate the reduction of even the highest localized fractures.

Discussion: The high subangulomandibular approach remains a safe approach, with less risk of facial nerve injury if the planes are respected and the facial nerve is avoided if encountered. Nevertheless, this approach is indicated in low condylar and some neck fractures.

Conclusion: Given the benefits of this approach compared to other techniques, we recommend its use.

1. Introduction

Condylar fractures are quite frequent, representing 25% to 35% of mandibular fractures [1]. Their treatment leaves the surgeon confused between orthopedic treatment (maxillo-mandibular fixation for 15 days) and surgical treatment.

This problem has been addressed by several authors by posing classifications of fractures of the condyle, codified the indication and treat the multiple routes of approaches, but still remain in disagreement, especially because of complications, difficult access to the fracture site, making the anatomical reduction well despite the small size of the fragments and making the osteosynthesis [2].

Facial paralysis is the major constraint for surgeons, but the high subangulomandibular approach remains the safest [3]. This is why, in our department, it has been used for several years for low and neck condylar fractures. In this article we describe in detail its steps with the technique of the 'twisted steel wire', which is of great help, in a difficult case, we also report the rate of complications on a retrospective study of 4 years.

2. Surgical technique

Intubation should be naso-tracheal if the fracture is isolated or associated with another mandibular fracture, for verification of the

dental articulation with maxillo-mandibular fixation. Sometimes the fracture of the condyle is associated with a fracture of the nose requiring reduction during the operation or another fracture of the middle floor with a threat to the base of the skull during intubation. In these cases, intubation can be performed under the chin rest.

Do not forget to discuss with the anesthesiologist the possibility of not curarizing the patient throughout the procedure, for the detection of the facial nerve branches during the dissection of the masseter fascia.

The patient is in dorsal decubitus position. The swabbing must be oro-facio-cervical. A headrest is placed under a head in contralateral rotation, slightly in hyper-extension. The field must expose the sub-mandibular region and the entire face.

The skin incision must be 01 cm from the basilar border of the mandibular angle and 05 cm long towards the front. It should follow the tension lines or if possible made on a natural fold or wrinkle of the neck. The infiltration is done with adrenalized serum or adrenalized xylocaine to facilitate detachment and hemostasis. The infiltration is done subcutaneously up to the level of the ATM and against the bone on the external face of the ramus [Fig. 1].

A skin incision is made following the tracing, highlighting the platysma underneath so as not to make a mistake in the plan, so that we dissect, from the upper edge, strictly subcutaneous towards the ATM, up to about 04 cm above the basilar edge of the mandible, separating the skin plane from the SMAS [Fig. 1].

* Corresponding author.

E-mail address: emaildeamine@gmail.com (A. Kaouani).

<https://doi.org/10.1016/j.ijscr.2021.106146>

Received 9 May 2021; Received in revised form 20 June 2021; Accepted 24 June 2021

Available online 29 June 2021

2210-2612/© 2021 The Authors. Published by Elsevier Ltd on behalf of IJS Publishing Group Ltd. This is an open access article under the CC BY-NC-ND license

(<http://creativecommons.org/licenses/by-nc-nd/4.0/>).

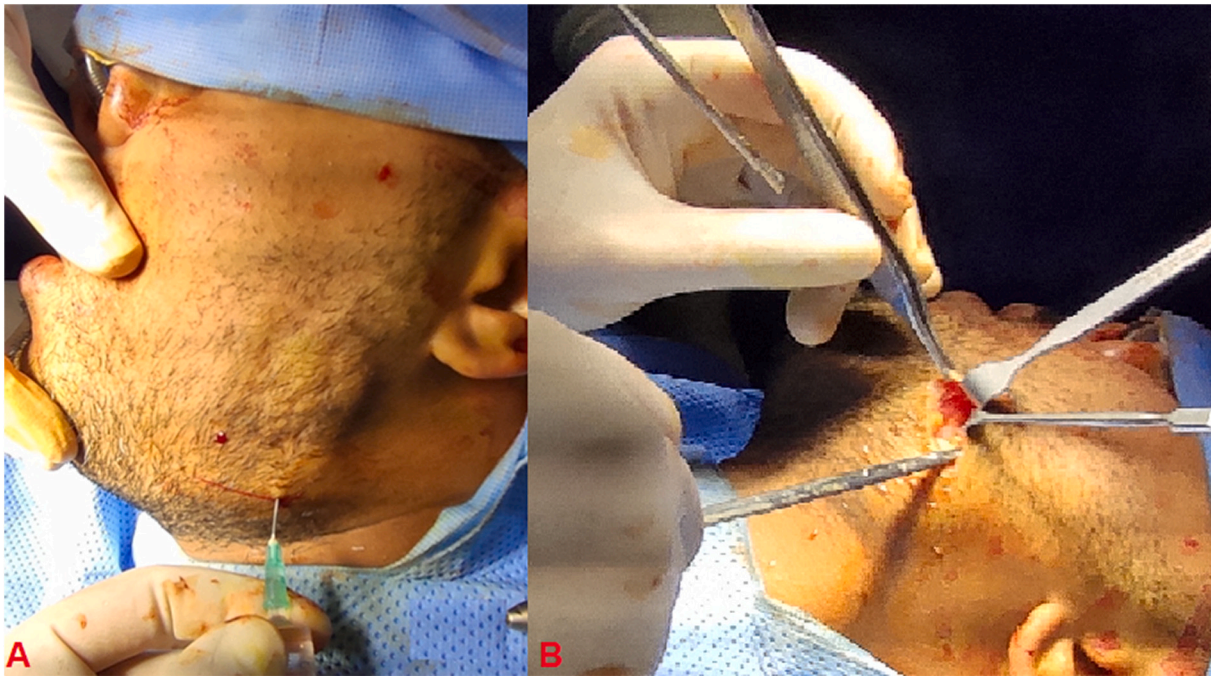

Fig. 1. A: The image shows the patient in dorsal decubitus position, head on headrest in slight hyper-extension and turned to the opposite side of the fracture, the preincision of 04 cm to 01 cm below the angular rim and the subcutaneous infiltration.
B: Strict subcutaneous dissection separating the skin plane from the SMAS.

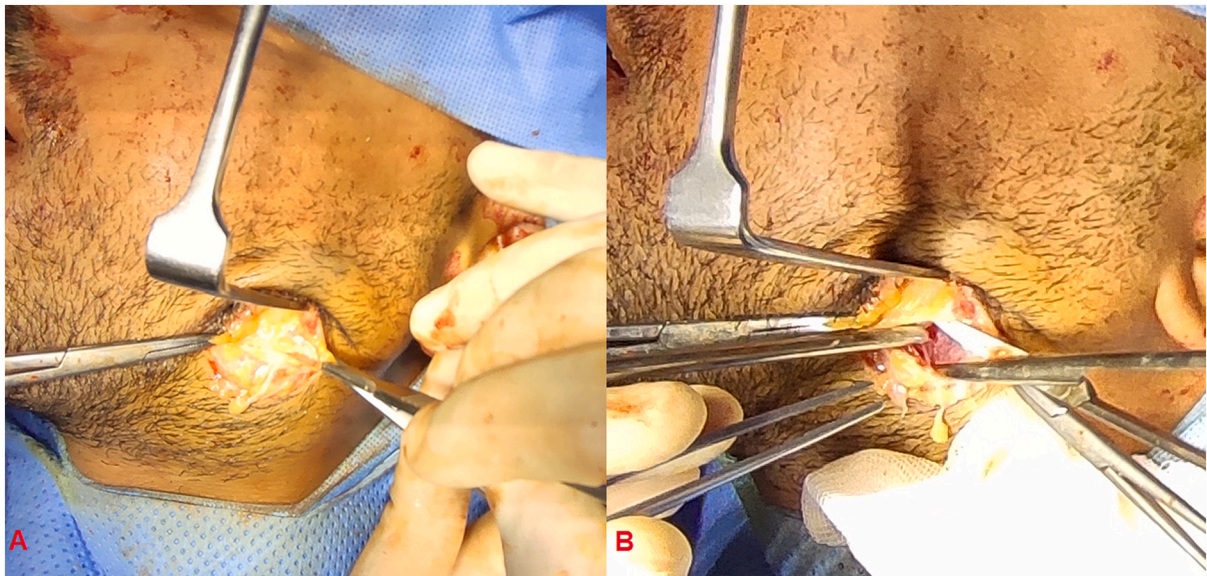


Fig. 2. A: Incision of the SMAS after salt serum infiltration between the SMAS and the masseter aponeurosis.
B: Dissection of the masseter aponeurosis.

At 03 cm from the mandibular angle, at the level of the so-called silent zone according to Friteau [4], the SMAS is lifted using two claw forceps, and then we infuse salty serum between the SMAS and the masseter aponeurosis to separate them and protect the facial branches. During this time, we always remember to ask the anesthesiologist if the patient is still curarized or not. A SMAS incision is made over a length of 02 cm from the posterior edge of the masseter muscle forward, in a line from the tragus to the labial commissure [Fig. 2]. Then we gently dissect the masseter fascia to expose the masseter muscle fibers, trying to avoid the easily detectable facial nerve branches if found in our path. At the same time, we must always keep an eye on the labial commissure to

detect any movement that indicates contact with the branches of the facial nerve [Fig. 2].

Now that the masseteric muscle is exposed between two retractors separating the planes: cutaneous, subcutaneous, SMAS and masseteric aponeurotic, which contains the branches of the facial, the muscle is cut in full thickness with a chisel until it touches the bone. It is especially necessary to expose the posterior edge of the ramus, to do this, from front to back, using an elevator, we separate the muscle fibers little by little and section them while avoiding the masseteric extension of the parotid gland [Fig. 3].

Then, using an elevator, the lateral cortical bone and the posterior

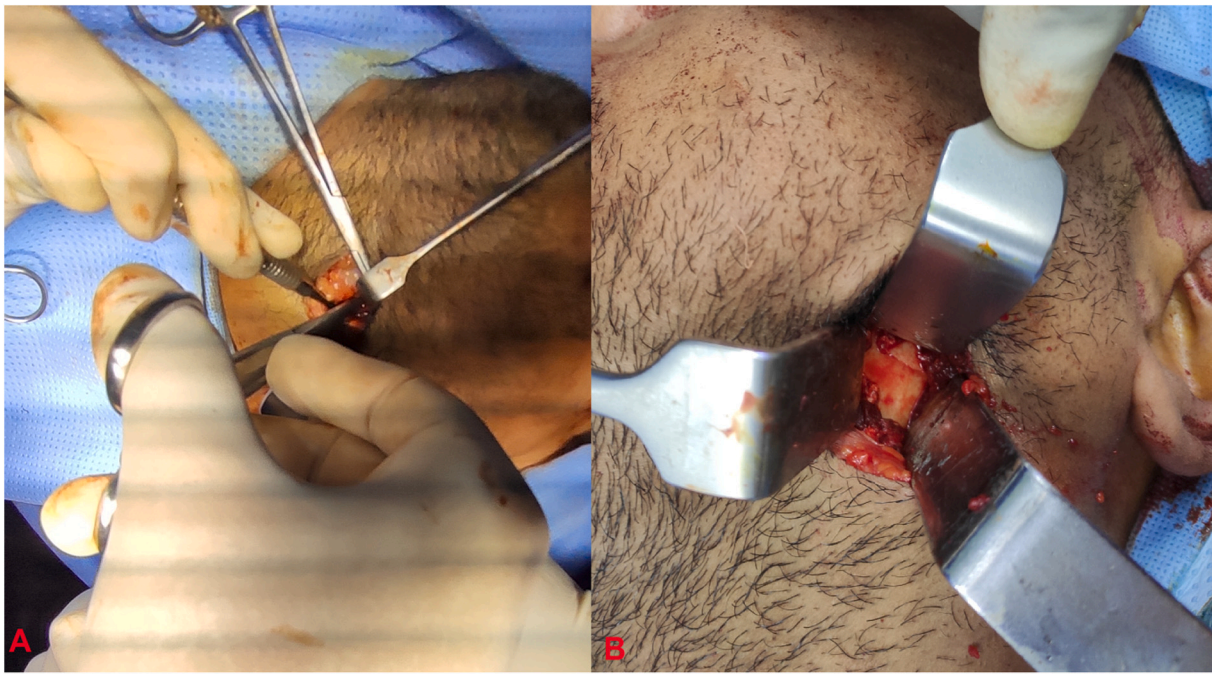


Fig. 3. A: Section of the masseter muscle by scissors using an elevator to individualize the muscle fibers. B: highlighting of the fracture site by sectioning the muscle and subperiosteal detachment.

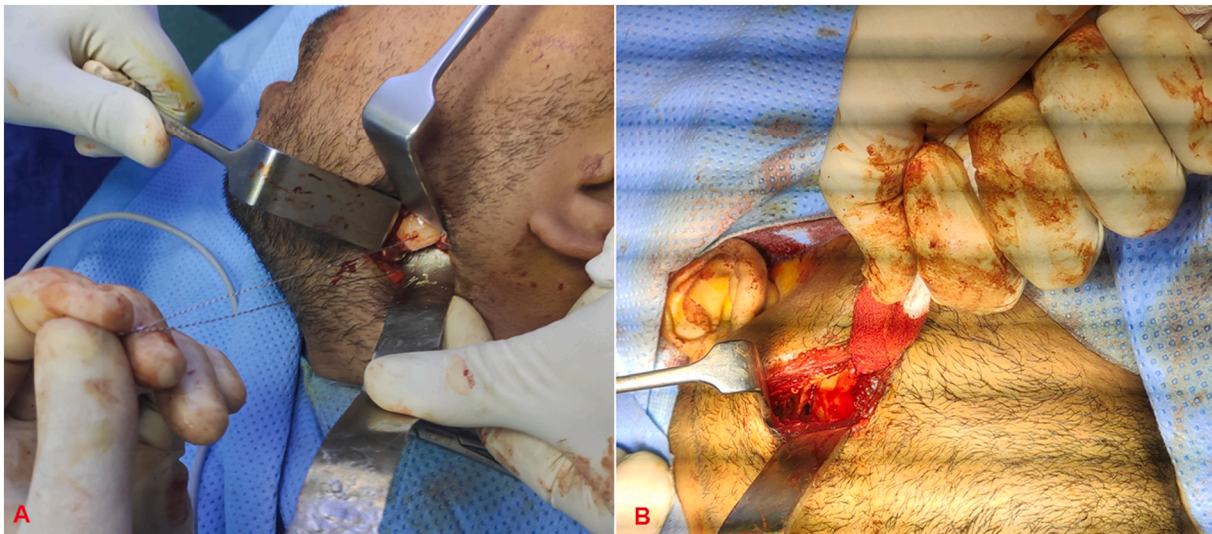

Fig. 4. A: Drilling a hole 01 cm from the mandibular angle and introducing a twisted steel wire while introducing a malleable blade at the level of the internal face of the angle to protect the underlying structures. B: Traction of the steel wire wound by a compress bringing down the ramus and helping to reduce the fracture line.

and inferior edge of the ramus are exposed; the fracture site must be perfectly visualized [Fig. 3].

At the level of the masseteric tuberosity, a malleable blade is placed on its medial side to protect the underlying structures. A transfixion hole is drilled 01 cm from the basilar edge. A previously prepared twisted steel wire is inserted. The two ends of the wire are held with a Kocher claw forceps, then a compress is wrapped around the wire to protect the superficial and deep planes [Fig. 4].

At this point, the anesthesiologist is asked to curarize the patient completely to facilitate the reduction maneuvers.

The twisted steel wire is a great help in moving the ramus in almost every direction, so that the fracture site, even if it is high up, can be easily manipulated and the condyle reduced. Instead of the twisted wire,

drape forceps can be used, which are attached to both sides of the hole drilled in the masseteric tuberosity. Alternatively, the ramus can be pulled downward by a Gillis or Hugonnier hook placed at the mandibular notch. An Edge placed at the level of the molars with anterior maxillo-mandibular fixation is also used [Fig. 4].

After reduction, a maxillo-mandibular fixation is made with a good articulation, then the osteosynthesis is performed. There are many choices of osteosynthesis materials for the condyle. In our department we use straight mini plates with 04 holes with a small gap that can be shaped and that gives us a lot of possibilities of placement [Figs. 5, 6].

Hemostasis is ensured as the procedure is carried out using bipolar forceps in order to avoid any diffusion to the facial nerve.

A diluted betadine wash is performed and then the wound is closed

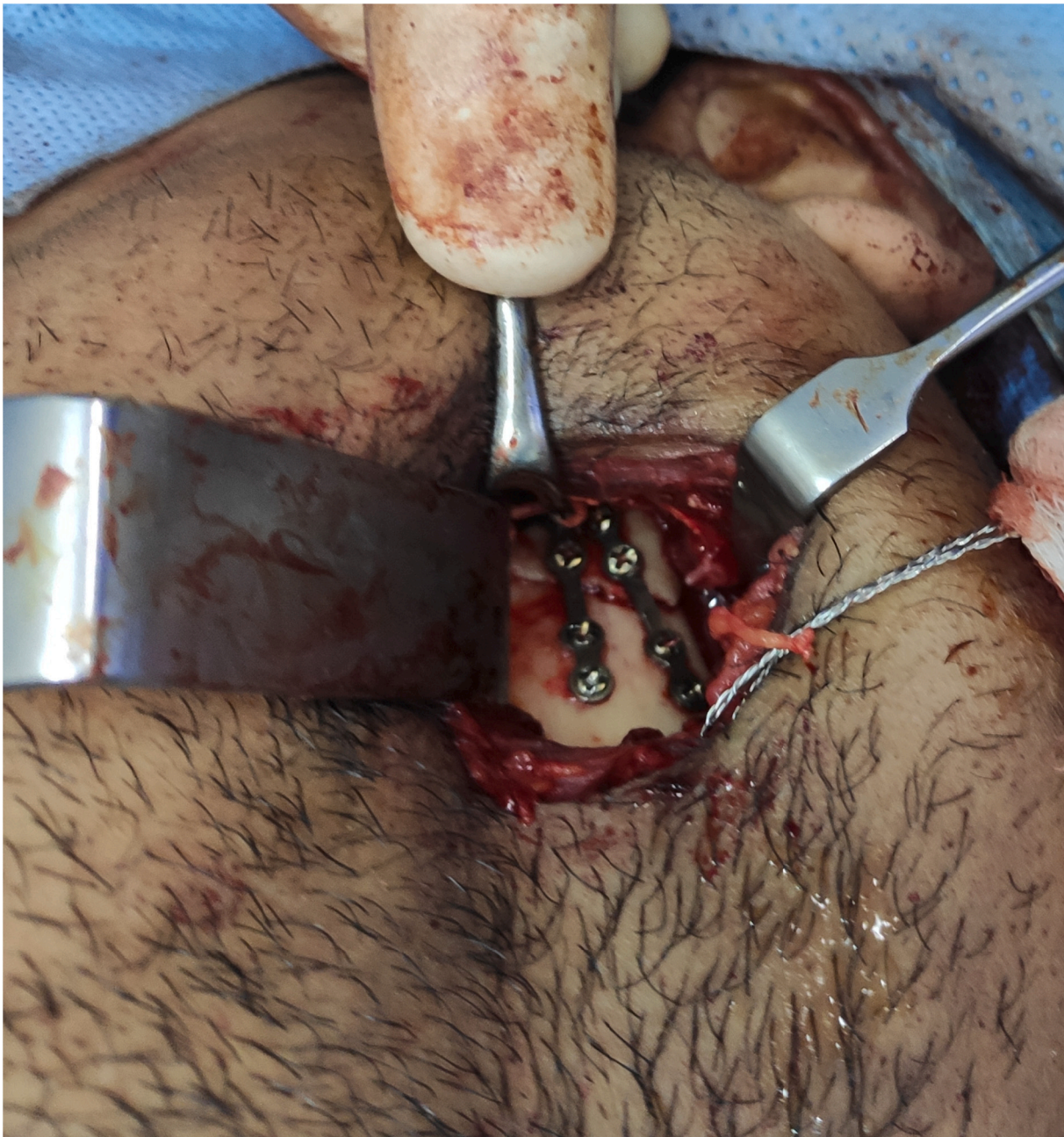

Fig. 5. Osteosynthesis of the fracture by 02 mini-plates with 04 holes.

plane by plane on a suction drain. The muscular plane is sutured with X-stitches, taking care not to catch the branches of the facial nerve in the stitches.

3. Result

From January 2016 to December 2019, 173 patients presented to our department of stomatology and maxillofacial surgery of the 20^{août} hospital in Casablanca, 128 patients (51 low subcondylar fractures and 77 high subcondylar fractures) benefited from surgical treatment by high subangulomandibular approach and osteosynthesis by 02 straight mini-plates, the average age of these patients was 27.6 years (16 to 58 years) with predominance of the male sex.

91% of the operations are performed by resident surgeons. The average time of the procedures, from incision to closure of the approach, was 45 min. The follow-up period was 12 months.

We did not note any cases of facial nerve paresis, even transient, or other notable complications. All our patients were satisfied with the scar at 12 months.

This case series has been reported in line with the PROCESS Guideline [19].

4. Discussion

Because of their high incidence, estimated at 25-35% of mandibular fractures, several treatment options have been described for these fractures by the authors. Essentially, there are 2 main methods: conservative (closed) and surgical (open) treatment [5].

Orthopedic treatment consists of a 15-day immobilization with a maxillo-mandibular fixation in good articulation taking into consideration the dental articulation prior to the trauma. This method is chosen by several schools because of the difficulty of exposing the condyle, the

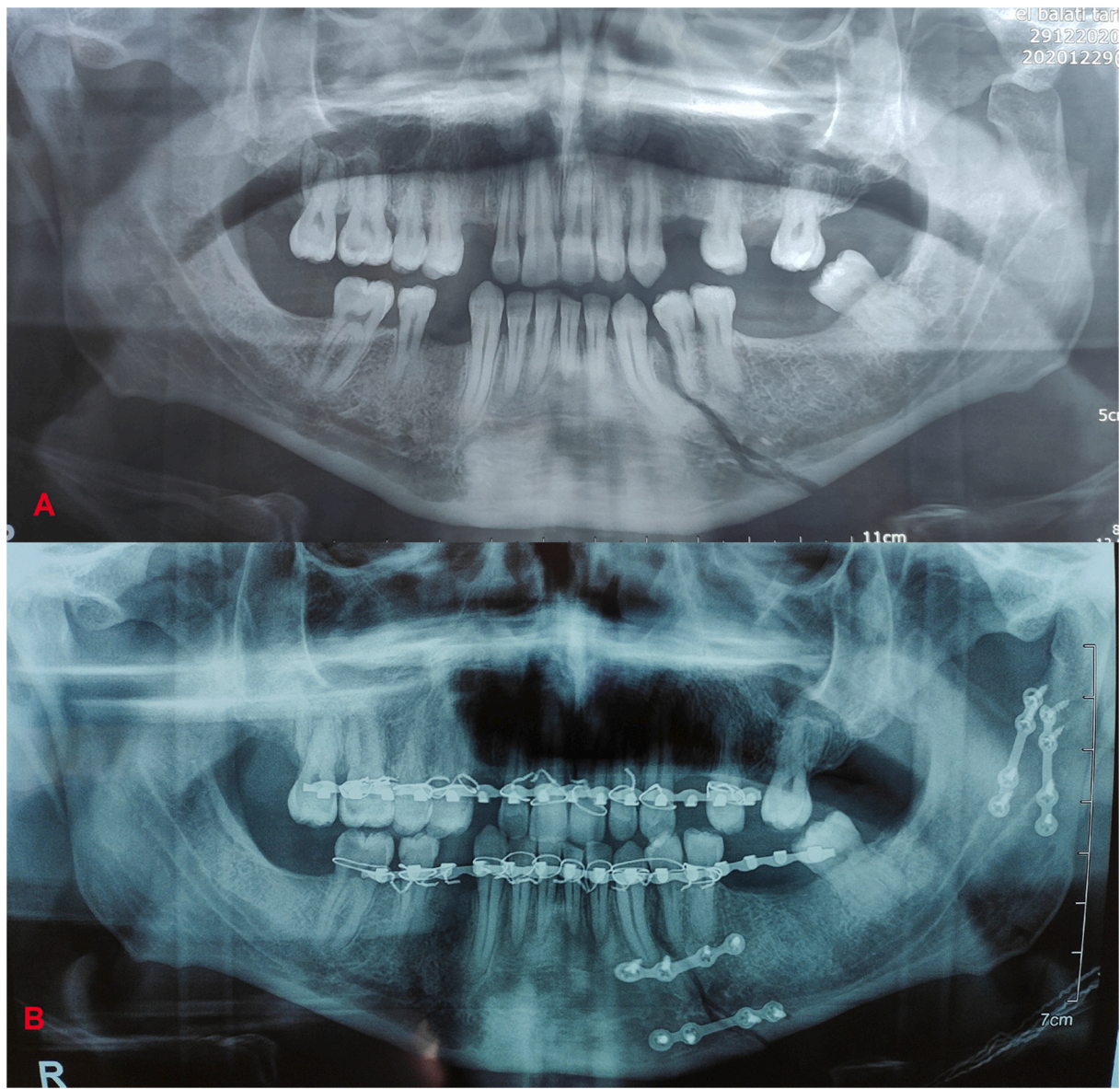


Fig. 6. Panoramic X-ray of the same patient.

A. Before surgery showing a fracture of the left horizontal branch and a fracture of the left condyle with dislocation of the head and shortening of the ramus.
 B. At Day 01 after osteosynthesis showing good reduction of the fracture sites.

risk of facial nerve injury, and the technical challenge of open reduction osteosynthesis. However, complications of conservative treatment are frequent and unexpected, including dental articulation disorder, facial asymmetry due to shortening of the ramus, reduced mandibular mobility and chronic pain.

The indications for surgical treatment are not codified and several studies have shown that osteosynthesis of condyle fractures gives better results. Most commonly, the practitioner balances the complications that may arise after surgical treatment that he has mastered against conservative treatment.

The choice of a particular approach to reach the condyle fracture depends on its location and the type of osteosynthesis considered (straight mini-plates or 3D plates). However, in our department, we have opted for the high subangulomandibular approach, because we consider it the safest, easiest and quickest approach, which gives us access to all low and high condylar fractures by using the twisted wire technique.

In a meta-analysis of 3873 patients and 96 studies, Al-Moraissi et al.

reported that the retromandibular approach to condylar fractures was responsible for up to 40% of transient facial paresis rates and 6.8% of permanent facial paralysis rates. For the preauricular approach, they reported up to 35.3% transient and 5% permanent facial nerve damage. Even the transoral approach under endoscopy or not, which is considered the safest for the facial nerve, they reported up to 20% of temporary paresis, while all the studies done on the high subangulomandibular approach did not report any case of damage to the facial nerve, which is also the case in our series [6,7].

The high subangulomandibular approach is a derivative of the Risdon or low subangulomandibular approach. The Risdon approach was described in 1934, and consists of a skin incision 03 cm from the mandibular angle over a length of 5-6 cm, crossing the platysma and reaching as far as the superficial layer of the cervical fascia. It performs an ascending subplatysmatic dissection in the direction of the mandibular angle, divides the pterygo-masseteric band on the inferior edge of the angle, and then reaches the condyles in a subperiosteal plane [8–10]. The Risdon approach gives great satisfaction in exposing the cortical

ramus and the basilar edge of the mandibular angle. However, to reach the condyle, this low incision prevents good exposure of condylar fractures, especially high ones, the subplatysmatic dissection endangers the marginal branch of the facial nerve, and the necessity of a strong spread of the upper edge of the incision traumatizes the branches of the facial nerve. The literature reports a large number of cases of facial nerve damage in this approach, up to 37% of procedures in some series [11,12].

Meyer et al. first described the surgical technique of the modified high subangulomandibular or risdon approach in 2006 [13]. The main points of this approach are: a higher incision at 01 cm from the mandibular angle edge and shorter at 04 cm, a strict ascending subcutaneous dissection preserving the marginal branch of the facial nerve, an oblique SMAS incision at 03 cm from the mandibular angle, verification of the presence of the branches of the facial nerve at the level of the aponeurosis of the masseter muscle, then section of the masseter muscle on the same oblique line exposing the posterior edge of the ramus, to then easily expose the fractures of the condyle and perform osteosynthesis with 3D plates.

For high situated fractures or fractures that are difficult to reduce because of displacement of the proximal fragment, downward traction of the ramus is necessary. In our department, we systematically use twisted steel wire, which increases the visibility of the fracture site and facilitates the placement of straight mini-plates for osteosynthesis if 3D plates are not available, thus decreasing operating time.

According to the literature, this route spares the patient from complications related to the involvement of the parotid gland such as salivary fistula, sialoceles or Frey syndromes encountered in other approaches [14,15,17], nevertheless, in 2020, in our department, we had a case of parotid salivary cyst as a complication of the high subangulomandibular approach [18].

The only disadvantage that the authors criticize with this approach is the visible skin scar and the scar of the masseter muscle with a temporary alteration of the mouth opening [16]. As with all approaches, wound infections and hematoma are possible.

Provenance and peer review

Not commissioned, externally peer-reviewed.

Sources of funding

The authors declared that this study has received no financial support.

Ethical approval

Written informed consent was obtained from the patient for publication of this study and accompanying images. A copy of the written consent is available for review by the Editor-in-Chief of this journal on request.

Guarantor

Amine Kaouani.

Registration of research studies

1. Name of the registry: researchregistry
2. Unique identifying number or registration ID: 6701

CRedit authorship contribution statement

Amine kaouani: Corresponding author writing the paper.

Ouassime kerdoud: writing the paper.

Rachid Aloua: writing the paper.

Faiçal Slimani: Correction of the paper.

Declaration of competing interest

Authors of this article have no conflict or competing interests. All of the authors approved the final version of the manuscript.

References

- [1] Elsevier Inc Hany A. Emam, M.S. BDS, Courtney A. Jatana, M.S. DDS, Gregory M. Ness, DDS*. Matching surgical approach to condylar fracture type, *Atlas Oral Maxillofac. Surg. Clin. N. Am.* (16) (2016) 1061–3315.
- [2] C Bouchard MH Perreault Postoperative complications associated with the retromandibular approach: a retrospective analysis of 118 subcondylar fractures J. Oral Maxillofac. Surg. 72 370e375.
- [3] C. Meyer, S. Zink, A. Wilk, La voie d'abord sous-angulo-mandibulaire haute (voie de Risdon modifiée) pour le traitement des fractures sous-condyliennes de la mandibule, *Rev. Stomatol. Chir. Maxillofac.* 107 (2006) 449–454.
- [4] E. Simon, L. Coffinet, S. Sellal, F. Durouire, M. Stricker*, Paralyse faciale. 1762-5661/\$ - see front matter ©, Elsevier SAS, Tous droits réservés, 2004 <https://doi.org/10.1016/j.emeden.2004.07.001>.
- [5] Hany A. Emam, Courtney A. Jatana, Gregory M. Ness, Matching surgical approach to condylar fracture type, *Atlas Oral Maxillofac Surg Clin North Am* 25 (1) (2017) 55–61, <https://doi.org/10.1016/j.cxom.2016.10.004>, 1061-3315/16/ 2016 Elsevier Inc.
- [6] E.A. Al-Moraissi, A. Louvrier, G. Colletti, L.M. Wolford, F. Biglioli, M. Ragaey, et al., Does the surgical approach for treating mandibular condylar fractures affect the rate of seventh cranial nerve injuries? A systematic review and metaanalysis based on a new classification for surgical approaches, *J. Craniomaxillofac. Surg.* 46 (2018) 398–412.
- [7] R. Gonzalez-Garcia, J.F. Sanroman, C. Goizueta-Adame, F.J. Rodriguez-Campo, G. Y. Cho-Lee, Transoral endoscopic-assisted management of subcondylar fractures in 17 patients: an alternative to open reduction with rigid internal fixation and closed reduction with maxillomandibular fixation, *Int. J. Oral Maxillofac. Surg.* 38 (2009) 19–25.
- [8] F. Risdon, Ankylosis of the temporomaxillary joint, *Oral Surg.* (1934) 1933–1936.
- [9] C.A. Louvrier, A. Barrabe, E. Weber, B. Chatelain, N. Sigaux, C. Meyer, The high sub-mandibular approach: our experience about 496 procedures, Elsevier Masson SAS, *J. Stomatol. Oral Maxillofac. Surg.* (2020) 2468–7855, <https://doi.org/10.1016/j.jormas.2020.03.009>.
- [10] U. Eckelt, S. Gerber, Zugschraubosteosynthese bei Unterkiefergelenkfortsatzfrakturen mit einem neuartigen Osteosynthesebesteck, *Zahn Mund Kieferheilkd Zentralbl* 69 (1981) 485–490.
- [11] M. Manisali, M. Amin, B. Aghabeigi, L. Newman, Retromandibular approach to the mandibular condyle: a clinical and cadaveric study, *Int. J. Oral Maxillofac. Surg.* 32 (2003) 253–256.
- [12] M.F. Zide, J.N. Kent, Indications for open reduction of mandibular condyle fractures, *J Oral Maxillofac Surg* 41 (1983) 89–98, [https://doi.org/10.1016/0278-2391\(83\)90214-8](https://doi.org/10.1016/0278-2391(83)90214-8).
- [13] C. Meyer, S. Zink, A. Wilk, La voie d'abord sous-angulo-mandibulaire haute (voie de Risdon modifiée) pour le traitement des fractures sous-condyliennes de la mandibule, *Rev. Stomatol. Chir. Maxillofac.* 107 (2006) 449–454.
- [14] O. Trost, P. Trouilloud, G. Malka, Open reduction and internal fixation of low subcondylar fractures of mandible through high cervical transmasseteric anteroparotid approach, *J. Oral Maxillofac. Surg.* 67 (2009) 2446e2451.
- [15] 143e153 A. Wilk, High perimandibular approach/modified RisdoneStrasbourg approach, in: *Fractures of the mandibular condyle basic considerations and treatment*, Quintessence Publishing, New Malden, 2009.
- [16] © Mauro Pau, Kawe Navisany, Knut Ernst Reinbacher, Tomislav Zrnc, Jürgen Wallner, Katja Schwenzer-Zimmerer, in: *Use of a Modified High Submandibular Approach to Treat Condylar Base Fractures: Experience With 44 Consecutive Cases Treated in a Single Institution*, European Association for Cranio-Maxillo-Facial Surgery. Published by Elsevier Ltd, 2016, pp. 1010–5182, <https://doi.org/10.1016/j.jcms.2016.07.009>.
- [17] A.V.J. Rozeboom, L. Dubois, R.R.M. Bos, R. Spijker, J. de Lange, Open treatment of condylar fractures via extraoral approaches: a review of complications, *J. Craniomaxillofac. Surg.* 46 (2018) 1232–1240.
- [18] Rachid Aloua, Faiçal Slimani, Salivary parotid cyst as an occurred complication of subangulomandibular approach of mandibular subcondylar fracture: a case report, *Ann. Med. Surg.* 60 (2020) 673–674, <https://doi.org/10.1016/j.amsu.2020.11.078>.
- [19] SCARE Group, R.A. Agha, T. Franchi, C. Sohrahi, G. Mathew, A. Kerwan, The SCARE 2020 guideline: updating consensus Surgical Case Report (SCARE) guidelines, *Int. J. Surg.* S1743-9191 (20) (2020) 30771–30778.