

# Expanding unilateral lung collapse using airway pressure release ventilation applied independently to the collapsed lung through the double-lumen endotracheal tube

**Mahmoud Saghaei**

Department of Anesthesia, Isfahan University of Medical Sciences, Isfahan, Iran and Anesthesiology and Critical Care Research Center, Isfahan University of Medical Sciences, Isfahan, Iran

Unilateral lung collapse (ULC) is a clinical challenge in the intensive care unit and requires sophisticated treatment approaches, especially if the collapse continued over several hours. If not responded to ordinary measures such as postural drainage and bronchoscopy, it may require insertion of a double-lumen endotracheal tube and independent lung ventilation or high-pressure manual re-expansion of the collapsed lung which may result in lung injury. In this article, a safe and gradual re-expansion method using airway pressure release ventilation is presented for the treatment of a ULC.

**Key words:** Airway pressure release ventilation, endotracheal intubation, lung collapse, mechanical ventilation, one-lung ventilation

**How to cite this article:** Saghaei M. Expanding unilateral lung collapse using airway pressure release ventilation applied independently to the collapsed lung through the double-lumen endotracheal tube. *J Res Med Sci* 2022;27:5.

## INTRODUCTION

Unilateral lung collapse (ULC) caused by the obstruction of a main stem bronchus is not uncommon in the intensive care unit and postoperative period, with a prevalence ranges from 2% to 40%.<sup>[1,2]</sup> ULC usually responds well to bronchoscopy, nebulized mucolytic agents, incentive spirometry, physiotherapy, and postural drainage.<sup>[3]</sup> After obstruction of a main stem bronchus, the alveolar air space becomes progressively deflated because of gradual absorption, and if not treated early it may lead to total ULC which may not respond easily to conventional treatments.<sup>[4]</sup> In the intubated patients since the collapsed lung has a very poor compliance, most of the tidal volume diverts to the normal lung causing overinflation injury which necessitates using the advanced method of lung recruitment selectively applied to the affected lung.

Using a double-lumen endotracheal tube facilitates the isolation of lungs and allows for manual inflation of collapsed lung using high pressure without affecting the healthy lung. Rapid re-expansion of the collapsed lung by forceful application of positive pressure to the collapsed lung may lead to adverse complications such as barotrauma, bronchospasm, lung edema, and pneumothorax.<sup>[5]</sup> A relatively safe approach for expanding the lung is to use independent lung ventilation (ILV) using two ventilators with different setting customized to each lung.<sup>[6]</sup> In this article, we have reported a case of total ULC treated successfully using the ventilation mode of airway pressure release ventilation (APRV).

## CASE REPORT

A 49-year-old male patient with multiple trauma admitted to the intensive care unit after emergency

### Access this article online

Quick Response Code:



Website:  
[www.jmsjournal.net](http://www.jmsjournal.net)

DOI:  
10.4103/jrms.jrms\_390\_21

This is an open access journal, and articles are distributed under the terms of the Creative Commons Attribution-NonCommercial-ShareAlike 4.0 License, which allows others to remix, tweak, and build upon the work non-commercially, as long as appropriate credit is given and the new creations are licensed under the identical terms.

**For reprints contact:** WKHLRPMedknow\_reprints@wolterskluwer.com

**Address for correspondence:** Dr. Mahmoud Saghaei, Al-Zahra Medical Center, Isfahan, Iran.

E-mail: [mahmood.saghaei@gmail.com](mailto:mahmood.saghaei@gmail.com)

**Submitted:** 04-May-2021; **Revised:** 17-Jul-2021; **Accepted:** 28-Jul-2021; **Published:** 29-Jan-2022

laparotomy for the removal of a ruptured spleen. The patient was receiving mechanical ventilation through a well-positioned tracheal tube. In the next post-operative day, oxygen saturation decreased and on auscultation respiratory sounds cannot be heard over the left hemothorax, which persisted after endotracheal suctioning. The depth of tracheal tube insertion was checked and appeared to be appropriate for the patient (21–22 cm). A portable chest X-ray showed complete collapse of the left lung. The appropriate position of the tracheal tube was confirmed in the chest X-ray. The preoperative chest X-ray showed no evidence of lung collapse and both lung fields were normal on auscultation as documented in patient's history. Therefore, we concluded that the collapse was developed during or after surgical operation. To treat lung collapse in addition to tracheal suction, the patient positioned on the right side and a nebulization of N-acetylcysteine 20% 3 ml Q8h administered and tidal volume reduced to 300 ml to prevent overinflation of the right lung. After 2 days, fiberoptic bronchoscopy was performed to open the bronchial obstruction and to expand the lung which proved to be ineffective. In the fifth postoperative day, the left lung was still totally collapsed in the chest X-ray [Figure 1], and it was decided to recruit the left lung using ILV. At this time, oxygen saturation was 88–90% with an  $FiO_2$  of 1.0, lung compliance 30 ml/cmH<sub>2</sub>O, and peak airway pressure 18 cmH<sub>2</sub>O. After sedation with midazolam 5 mg and fentanyl 100 µg cisatracurium 15 mg was administered as muscle relaxant to facilitate insertion of double-lumen tube. Then pharynx was suctioned, single-lumen tracheal tube was removed and a size 36F left-sided double lumen tube was inserted without difficulty. Ventilation of the right lung continued as before. For the left lung initially manual ventilation with a bag-valve was tried, but it soon appeared to be stiff and resistant to expansion. Therefore, after 30 min of bag-valve trial, the left lung connected to a second ventilator using APRV with the setting showed in Table 1. Patient's spontaneous ventilation was returned at this point and

preserved throughout the procedure. Fifteen minutes after start of APRV mode for the left lung, oxygen saturation and left lung compliance started to rise from the initial value of 90% and 30 ml/cmH<sub>2</sub>O toward a final value of 98% and 28 ml/cmH<sub>2</sub>O after 2 h respectively. A second chest X-ray showed re-expansion of the left lung [Figure 2]. At this point, double-lumen tube was replaced with a single-lumen tracheal tube and ventilation of both lungs continued using PSIMV mode with a pressure of 12 cmH<sub>2</sub>O and a PEEP of 10 cmH<sub>2</sub>O which resulted in an exhaled tidal volume of 600–640 ml.  $FiO_2$  gradually reduced to 40% and total lung compliance increased to 52 ml/cmH<sub>2</sub>O after 4 h. During the whole period, hemodynamic status was stable. Final blood gas values were appropriate, and the rest of the clinical course had no significant event and control X-rays showed fully expanded lungs. The patient was extubated the next day and discharged from the intensive care unit after another 2 days.

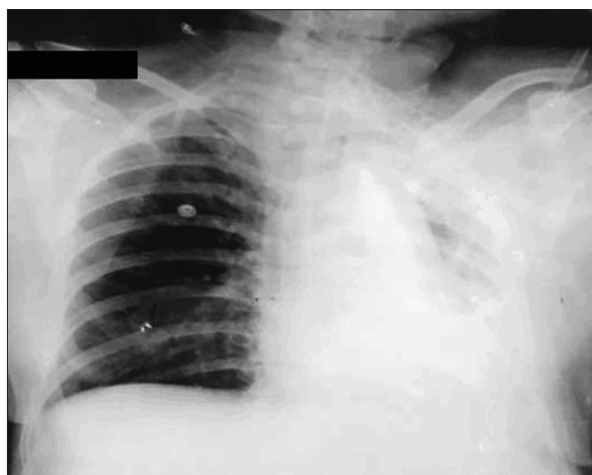
## DISCUSSION

During ILV lungs are separated anatomically and physiologically. Each lung ventilates using a separate

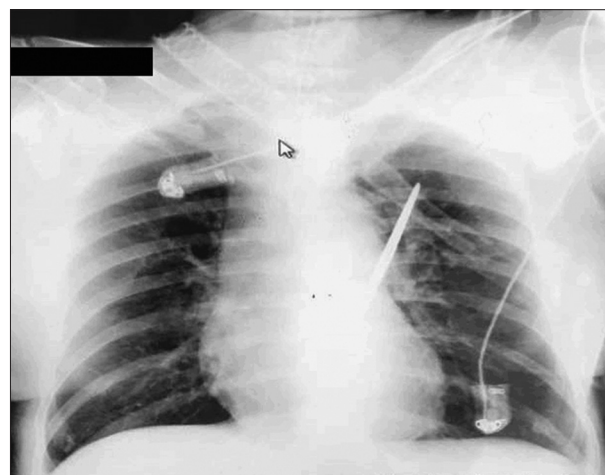
**Table 1: Ventilatory setting of the patient**

Setting	Value
Normal lung (right)	
Mode	SIMV
Tidal volume (ml)	300
Set rate (bpm)	12
PEEP (cmH <sub>2</sub> O)	8
Collapse lung (left)	
Mode	APRV
P high (cmH <sub>2</sub> O)	30
P low (cmH <sub>2</sub> O)	0
T high (s)	8
T low (s)	0.5

APRV=Airway pressure release ventilation; SIMV=Synchronized intermittent mandatory ventilation, PEEP=Positive end-expiratory pressure



**Figure 1:** Chest X-ray before insertion of double-lumen endotracheal tube, showing collapse of the left lung



**Figure 2:** Chest X-ray 2 h after the application of airway pressure release ventilation to the collapsed lung

ventilator with setting tailored to the characteristics of each individual lung.

In this article, a new method for safe and soft recruitment of collapsed lung is presented. APRV is a pressure controlled mode which applies a continuous distending airway pressure higher than the baseline pressure over several seconds with brief releases at set points to facilitate tidal exhalation. APRV is mainly used as a rescue mode in acute respiratory distress syndrome resistant to conventional mechanical ventilation. In this mode, the ratio of inspiration to expiration is high (inverse ratio ventilation) and the continuous distending pressure progressively re-expands the atelectatic areas of the lung. Therefore, it is a safe and gradual method of lung recruitment compared to invasive approaches of applying very high distending pressure in short time periods with potential volutrauma.

The exact cause of lung collapse in this case is not evident, but postoperative lung collapse is usually caused by impaired ventilation, retained secretions, decreased compliance of lung, postoperative pain that interferes with effective breathing and coughing, and malposition of tracheal tube into a main stem bronchus.<sup>[7]</sup>

Since ILV through a double-lumen endotracheal tube is inherently invasive, it should not be used as the first measure for the treatment of ULC. In this case, ordinary treatments consisting of postural drainage, chest physiotherapy, and fiberoptic bronchoscopy were not effective.

Previously, Purtuloglu *et al.*<sup>[5]</sup> used a mixture of Bi-level positive airway pressure and manual lung inflation using a bag-valve unit for 24 h; both were applied with relatively high distending pressure of 32 and 40 cmH<sub>2</sub>O, respectively. Although the APRV method used in our case used a lower pressure and expanded the lung in a shorter period of time, controlled clinical trials are necessary to determine the best distending pressure and duration of application.

In conclusion, selective application of APRV to one lung using ILV strategy may be considered a safe, effective and practical method for recruitment of collapsed unilateral lung in intubated patients. Double-lumen tracheal tubes are available in operating rooms and intensive care units. With a little experience, it can be used by intensivist to perform ILV for cases of ULC resistant to ordinary treatments. The insertion of double-lumen tube is more difficult than single lumen tubes, and therefore, patients must be anesthetized or deeply sedated and receive neuromuscular blockade to facilitate the tube insertion and prevent complications.

#### Financial support and sponsorship

Nil.

#### Conflicts of interest

There are no conflicts of interest.

#### REFERENCES

1. Smetana GW. Postoperative pulmonary complications: An update on risk assessment and reduction. *Cleve Clin J Med* 2009;76 Suppl 4:S60-5.
2. Dimick JB, Chen SL, Taheri PA, Henderson WG, Khuri SF, Campbell DA Jr. Hospital costs associated with surgical complications: A report from the private-sector National Surgical Quality Improvement Program. *J Am Coll Surg* 2004;199:531-7.
3. Restrepo RD, Braverman J. Current challenges in the recognition, prevention and treatment of perioperative pulmonary atelectasis. *Expert Rev Respir Med* 2015;9:97-107.
4. Rama-Maceiras P. Peri-operative atelectasis and alveolar recruitment manoeuvres. *Arch Bronconeumol* 2010;46:317-24.
5. Purtuloglu T, Eksert S, Simsek F, Sizlan A, Cosar A. A new treatment modality for unilateral atelectasis: Recruitment maneuver with endobronchial blocker. *Indian J Crit Care Med* 2013;17:240-2.
6. Berg S, Bittner EA, Berra L, Kacmarek RM, Sonny A. Independent lung ventilation: Implementation strategies and review of literature. *World J Crit Care Med* 2019;8:49-58.
7. Canet J, Mazo V. Postoperative pulmonary complications. *Minerva Anestesiol* 2010;76:138-43.