

# Combined Papillated Bowen Disease and Clear Cell Atypical Fibroxanthoma

Dimas Suárez-Vilela<sup>a</sup> Francisco Izquierdo-García<sup>b</sup>

Francisco Domínguez-Iglesias<sup>a</sup>

Jose Ramón Méndez-Álvarez<sup>a</sup>

<sup>a</sup>Department of Anatomía Patológica, Hospital Valle del Nalón, Riaño, and

<sup>b</sup>Department of Anatomía Patológica, Asturias, Hospital de León, León, Spain

## Key Words

Bowen disease · Papillated Bowen disease · Atypical fibroxanthoma · Clear cell atypical fibroxanthoma · Immunohistochemistry · p16

## Abstract

We describe a case of papillated Bowen disease (PBD), associated with a clear cell atypical fibroxanthoma (CCAFXA). The epidermal lesion showed a bowenoid papillomatous growth pattern with histologic features suggestive of infection by human papilloma virus (HPV). In the dermis a neoplasm made up by spindled or polygonal cells with wide clear cytoplasm and moderate nuclear pleomorphism was found. Immunohistochemical characteristics of these two lesions were clearly different. The atypical cells of the intraepidermal proliferation were positive for AE1-AE3 anticytokeratin antibody, EMA, p16, p53 and p63. The dermal tumor was positive for vimentin, CD10, CD68, CD99, alpha-1-antitrypsin and c-kit. Histological features and immunohistochemical profile of the dermal tumor corresponded to a CCAFXA, a very uncommon neoplasm of which only 10 cases have been reported. In situ hybridization for numerous types of HPVs was negative in both lesions.

## Introduction

Papillated Bowen disease (PBD) is an uncommon and not well recognized variant of Bowen disease (BD) characterized by verrucous-papillomatous architecture with severe intraepithelial dysplasia and koilocytic cells in the upper layers of the epidermis, similar to genito-anal or extragenital dysplastic lesions associated to human papilloma virus (HPV) [1]. Clear cell atypical fibroxanthoma (CCAFXA) is a rare variant of atypical fibroxanthoma (AFX) composed of polygonal and spindled cells with clear cytoplasm, polymorphic nuclei and abundant mitotic figures. Only 10 cases of CCAFXA have been

reported in the literature [2–8]. We describe a case in which both entities are found in a unique cutaneous lesion on the face of the patient. To our knowledge, the finding of these two unusual entities with different histogenesis in a unique cutaneous lesion has not been previously described.

### Case Report: Clinical History

A 86-year-old male patient had undergone a right nephrectomy because of a chromophobe carcinoma in 1997. Two tubular colonic adenomas were removed in 1998 and 1999. A basal cell carcinoma on the right ear and an intraepithelial squamous cell carcinoma, also on the right ear, were resected in 2007.

In March 2009, the patient was sent to our dermatology department for evaluation of a crusty lesion at the right preauricular area which had occurred 2 months before. It measured 1 × 0.7 cm in size, and under the suspicion of a squamous cell carcinoma, it was completely resected.

### Material and Methods

The specimen was fixed in 10% neutral buffered neutral formalin. Representative sections were embedded in paraffin, sectioned at 3 to 4 micrometer thickness and stained with standard HE, PAS and PAS after diastase digestion. Immunohistochemical staining of paraffin sections was performed in a Dako Techmate 500 Autostainer, using a heat-induced epitope retrieval technique and a universal secondary antibody kit (EnVision+System, Peroxidase; DAKO, Carpinteria, Calif., USA). The panel of antibodies included: CK AE1-AE3 (Dako 1/50), CK Cam 5.2 (Becton Dickinson prediluted), EMA (Dako 1/100), vimentin (Dako 1/800), smooth muscle actin (Dako 1/25), melan A (Dako 1/25),  $\alpha$ -1-antitrypsin (Dako 1/4,000), S100 protein (Dako 1/100), CD10 (Novocastra 1/20), CD34 (Novocastra 1/20), CD68 (Dako 1/100), CD99 (Dako 1/40), c-kit (Dako 1/25), Mib 1 (Novocastra 1/10), p16 (MTM Prediluted), p53 (Novocastra 1/10) and p63 (Dako 1/10).

In situ hybridization (ISH) for HPV on paraffin cut sections was performed (as provided in Dako ISH Cytomation GentPoint Detection System code K0620) using wide spectrum genomic probe (Y 1404) for 6, 11, 16, 18, 31, 33, 35, 39, 45, 51, and 52 serotypes and with complementary genomic probe (Y 1443) for 16, 18, 31, 33, 35, 39, 45, 51, 52, 56, 58, 59 and 68 serotypes

### Results

On light microscopy, an exophytic lesion with verrucous acanthosis, papillomatosis and variable hyperkeratosis and parakeratosis was found. The epidermis showed a loss of polarity and maturation in the whole thickness of the epithelium with atypical keratinocytes and numerous mitotic figures. The lesion contained vacuolated keratinocytes in the upper epidermis with koilocytic atypia and light hypergranulosis with keratohyaline granules (fig. 1a, b). At the periphery, the lesion was surrounded by thickened epidermis with acanthosis and hyperkeratosis, but with good maturation and without cellular atypia. In the dermis, just below the dysplastic epithelium and the reactive thickened epithelium, a solid tumor was found. It was surrounded by an epidermal collarette and did not ulcerate the epidermis. Tumor cells were polygonal or spindle with clear or microvacuolated cytoplasm, and the stroma of the tumor showed abundant and delicate vessels, with isolated and localized lymphoplasmacytic infiltrates (fig. 1c, d). Moderate to marked polymorphism of the nuclei was found throughout the tumor and around 5 mitotic figures per 10 high-powered fields, including some abnormal forms, were seen (fig. 1e). The cytoplasm of these cells was negative for both PAS stain and PAS stain after diastase digestion (fig. 1e). Immunohistochemical profile was completely different in the two lesions. The intraepidermal dysplastic proliferation

showed cytoplasmic staining for EMA, CK AE1-AE3, and nuclear and cytoplasmic staining for p16 in most of the epithelium (fig. 2a). Likewise, these cells presented nuclear staining for p53 (20%) and p63 (90%). The antibody Mib-1 demonstrated a proliferation index of 50%. The staining for p53 and Mib-1 was localized at different layers of the epithelium, whereas the expression of p63 was present in all layers of the epithelium (fig. 2b). The cells of the dermal tumor showed strong, diffuse cytoplasmic staining for vimentin,  $\alpha$ -1-antitrypsin and CD68 (fig. 2c), and diffuse membranous staining for CD10 (fig. 2d) and CD99. Some isolated cells showed cytoplasmic positivity for c-kit, and the proliferation index with the Mib-1 antibody was 30%. Immunostaining for Cam5.2, smooth muscle actin, S100 protein, melan A and CD34 were negative in both tumoral components.

ISH for HPV was negative in both bowenoid intraepidermal lesion and dermal tumor.

### Discussion

Our case shows two very unusual lesions: a BD with papillomatous growth pattern and cells with koilocytic characteristics in the epidermis and a CCAFXA in the dermis. The histologic features of the epidermal lesion corresponded to a papillomatous BD, an uncommon subtype of BD. This entity was recently described by Sun et al. [1] in a study of 26 cutaneous lesions, mostly localized on areas exposed to sun rays. These lesions were both exophytic and endophytic with verrucous acanthosis and papillomatosis. The full-thickness of the epidermis was replaced by atypical keratinocytes, with loss of polarity and of the normal maturation of the epithelium. All lesions contained vacuolated keratinocytes in the upper 1/3 to 1/4 of the epidermis with koilocytic atypia. Hypergranulosis was variable. In their study, using ISH method with widely screening genomic probes for HPV types, none of the specimens contained HPV DNA of the more common oncogenic HPV types. However, the authors suggested that more sensitive procedures, as polymerase chain reaction (PCR), should be used before being sure that PBD was pathogenetically not related to HPV infection. More recently, Corbalán-Vélez et al. [9] described 9 cases of bowenoid wart (BW) localized on the face, neck and temporal region. The lesions showed a verrucous growth pattern with intraepidermal bowenoid atypia and epithelial cells with koilocytic changes in the upper layers of the epidermis. Immunohistochemically, all cases of BW were negative for p16. PCR for DNA of HPV was not useful probably due to problems with the samples. These authors raise the possibility that BW, versus PBD, was induced by non-oncogenic HPV as those described in warts with in situ carcinoma [10, 11] or perhaps due to a synergistic effect of some type of HPV with solar radiation [9].

In our case, evidence of HPV infection was not demonstrated by ISH. Nevertheless immunohistochemically, we found an intense staining for p16. This finding is in agreement with the high incidence of p16 in BD [12, 13]. Willman et al. [13] found that 88% of cases of BD showed consistent expression of high levels of p16 and lacked pRb, but these patterns of expression were seen both in HPV-positive and in HPV-negative lesions. With the PCR method only 15% of cases were found to contain HPV DNA [13]. p53 or p63 proteins had not been previously studied in any of the cases of PBD or BW. We found moderate expression of p53 protein and obvious and intense expression of p63 protein. Both p53 and p63 were positive in most of BD [14, 15] and this overexpression could play a role in the pattern of differentiation and in the oncogenesis of BD and usual carcinomas of the skin [14, 15].

PBD and BW show overlap of microscopic findings and could be the same entity. Both lesions show histologic characteristics suggestive of HPV infection, but no type of HPV has been identified so far [1, 9], and p16 was negative in the 9 cases described by Corbalán-Vélez et al. [9]. So the pathogenesis of PBD-BW is not clear and the possible role of HPV in the genesis of these lesions keeps on being merely a speculation.

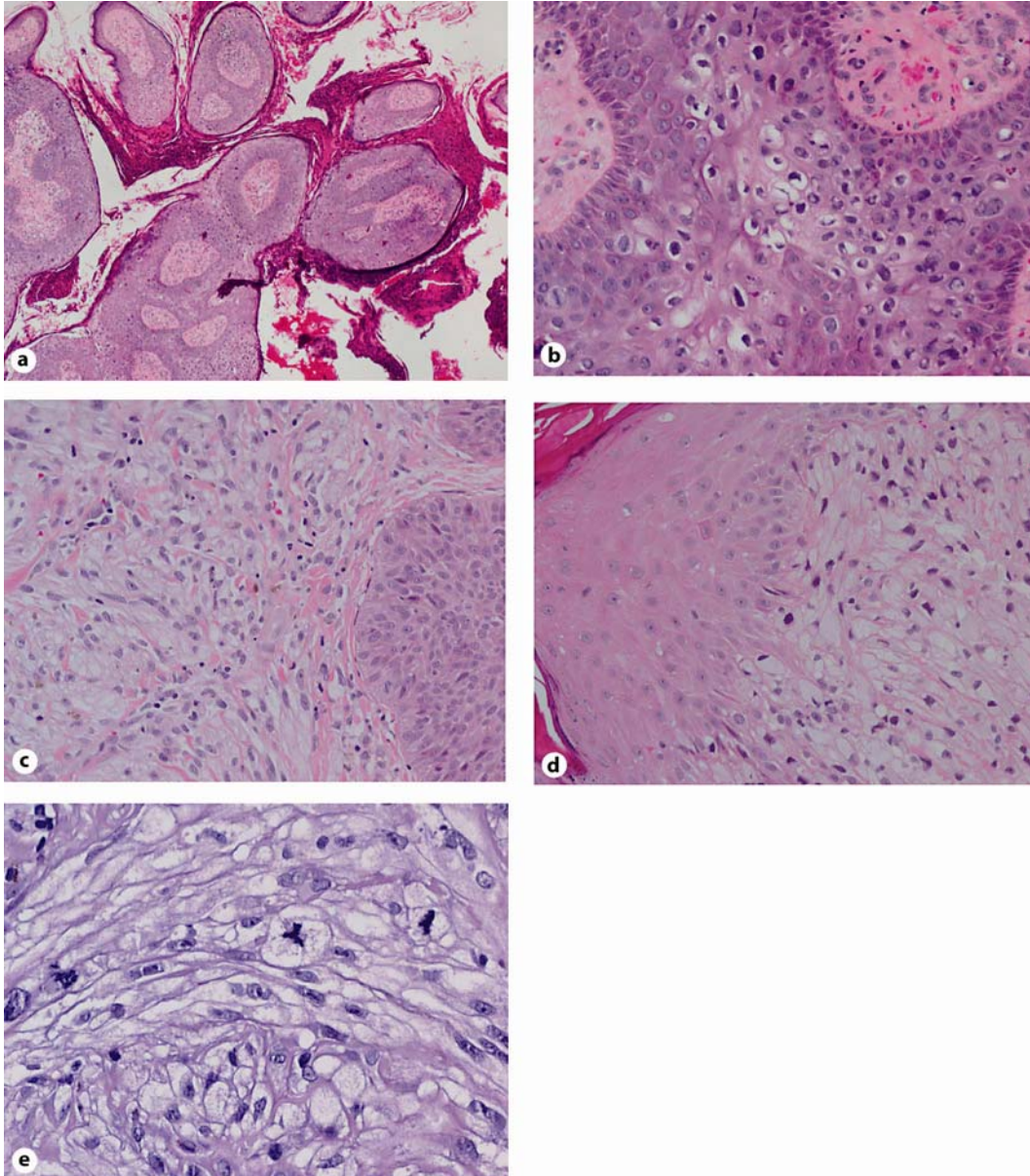
The dermal neoplasm found in our case is extremely uncommon with only 10 cases of CCAFSA described until now [2–8]. This tumor involves older patients, predominantly males, with a mean age of 80 years (range: 63–90). Seven tumors were localized on the head and neck [3–6, 8], and of the remaining 3 tumors, 1 was on the hand and 2 on the forearm [2, 5, 7]. The typical clinical presentation of these lesions consists of a rapidly growing nodular tumor of the skin similar to keratoacanthoma. Histologic findings are similar in all the reported cases with clear polygonal or spindle cells that showed moderate to severe nuclear atypia and common mitotic figures, some of them atypical [2–8]. One case showed extensive clear cell areas, as well as cellular areas composed of spindle cells in a fascicular arrangement [3]. The tumor cells did not stain with PAS or PAS after diastase digestion [2–8] and the immunohistochemical profile corresponded to a neoplasm without both epithelial and melanocytic features, and constant staining for vimentin and CD68 [3–8]. Two cases expressed smooth muscle actin and smooth specific actin [3] and one case HMB45 focally [7]. In our immunohistochemical study tumoral cells were diffusely stained with vimentin, CD10, CD68, CD99,  $\alpha$ -1-antitrypsin, and isolated cells for c-kit. Recently, CD99, CD10 and c-kit were described as sensitive markers of classic AFX [16–18]. However, these antibodies have not been studied in most of the published CCAFSA. Our case is the only with diffuse staining for CD10 and CD99, whereas in two previous cases studied with these antibodies only CD99 was positive [6, 8]. CCAFSA should be differentiated from dermal neoplasms, either primary or metastatic, composed of clear cells such as squamous cell carcinoma, melanoma, basal cell carcinoma, adnexal carcinoma, renal cell carcinoma, clear cell sarcoma, cutaneous leiomyosarcoma, dermal pleomorphic liposarcoma, parachordoma, clear cell dermatofibroma, etc. [2–8]. It is very important to diagnose this tumor correctly because, opposite to other dermal tumors with clear cells, CCAFSA has usually a low potential for metastatic spread [2–8], like conventional AFX [19]. Diagnosis of CCAFSA is based on histological features and mainly on the immunohistochemical profile, different to that of the other tumors with clear cells mentioned above [3–8].

In classic AFX the overlying epidermis rarely displays actinic atypia [19] and few cases of AFX combined with BD have been described. On this topic Engelbrecht et al. [20] reported a case of intraepithelial squamous neoplasia and atypical fibroxanthoma of the cornea and limbus. Histologic and immunohistochemical findings of this case corresponded to an intraepithelial BD, associated with an underlying spindle cell AFX. In the 10 cases of CCAFSA the epidermis showed attenuation, ulceration or surface erosion, but none of them showed actinic keratosis or BD [2–8]. The association of PBD and CCAFSA is an exceptional finding. In the review of the literature we have not found any case with these characteristics. The histogenesis of these lesions seems not related, but both of them could have a common etiopathogenesis secondary to chronic exposition to sun rays.

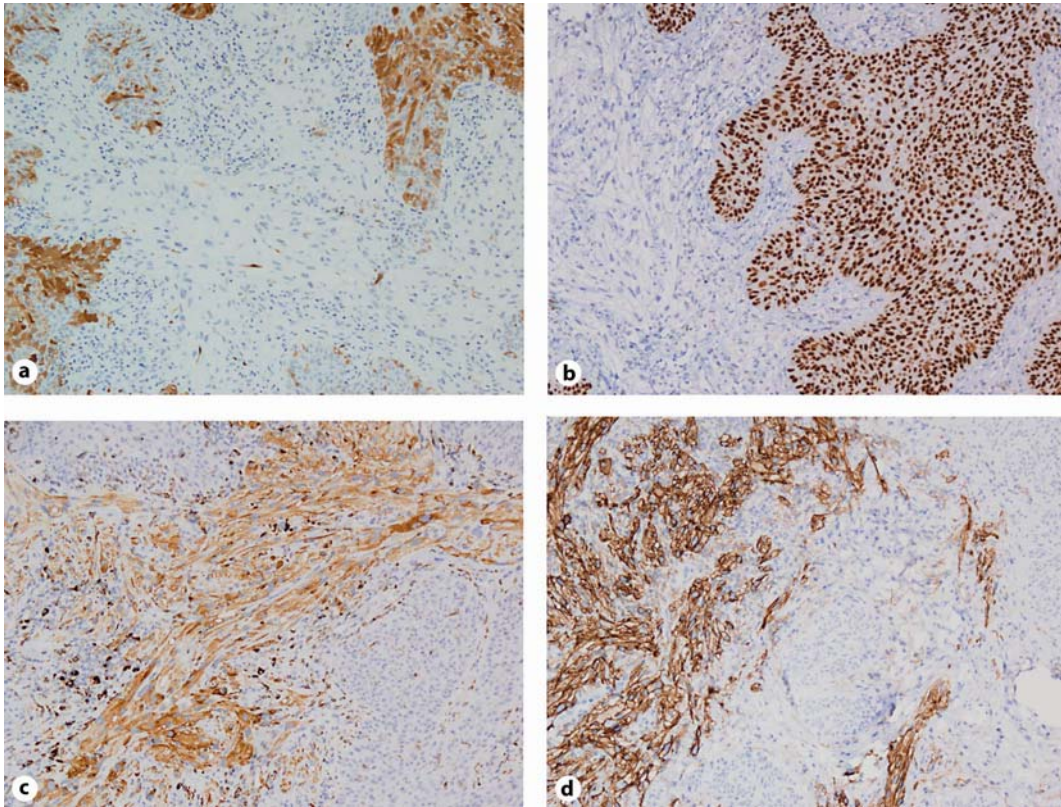
### Acknowledgements

We thank Dr. Miguel Angel SECO-NAVEDO from the department of Anatomía Patológica of Hospital Central de Asturias for performing ISH for HPV.

**Fig. 1.** **a** Verrucous exophytic lesion with hyper- and parakeratosis on the surface. The growth pattern is similar to those of the anal-genital condyloma. HE,  $\times 40$ . **b** Disorderly maturation and atypical keratinocytes associated with keratinocytes with prominent perinuclear halos reminiscent of koilocytes. HE,  $\times 200$ . **c, d** Tumoral proliferation with solid or fascicular growth pattern placed below the dysplastic epithelium (**c**) and the reactive epidermis (**d**). In both areas the spindle or polygonal cells show wide, clear, vacuolized cytoplasm. HE,  $\times 200$ . **e** Clear cells with moderate nuclear pleomorphism and abundant mitotic figures, some of them atypical. PAS,  $\times 400$ .



**Fig. 2.** **a** Stain for p16 in most of the bowenoid lesion. The dermal tumor is negative.  $\times 100$ . **b** Strong nuclear staining for p63 protein in the whole thickness of the dysplastic epithelium. The dermal tumor is negative.  $\times 100$ . **c** Diffuse cytoplasmic staining for CD68 in spindle cells of the dermal neoplasm. The bowenoid lesion is negative.  $\times 100$ . **d** Staining for CD10 at the cellular membrane in all the cells of the dermal tumor, without expression in the epidermal lesion.  $\times 100$ .



## References

- 1 Sun DJ, Barr JR: Papillated Bowen disease, a distinct variant. *Am J Dermatopathol* 2006;28:395–398.
- 2 Patterson JW, Konerding H, Kramer WM: Clear-cell atypical fibroxanthoma. *J Dermatol Surg Oncol* 1987;13:1109–1114.
- 3 Requena L, Sanguenza OP, Yus ES, Furio V: Clear-cell atypical fibroxanthoma: an uncommon histopathologic variant of atypical fibroxanthoma. *J Cutan Pathol* 1997;24:176–182.
- 4 Lazaro-Santander R, Andres-Gozalbo C, Rodriguez-Pereira C, Vera-Roman JM: Clear-cell atypical fibroxanthoma. *Histopathology* 1999;35:484–485.
- 5 Crowson AN, Carlson-Sweet K, Macinnis C, Taylor RJ, Battaglia T, La Mar LW, Minor D, Sutter S, Hill T: Clear-cell atypical fibroxanthoma: a clinicopathological study. *J Cutan Pathol* 2002;29:374–381.
- 6 Murali R, Palfreeman S: Clear-cell atypical fibroxanthoma – report of a case with review of the literature. *J Cutan Pathol* 2006;33:343–348.
- 7 Cai JP, Randall MB: HMB-45 expression in a clear-cell variant of atypical fibroxanthoma. *J Cutan Pathol* 2006;33:186–188.
- 8 Kemmerling R, Dietze O, Müller S, Neureiter D: Aspects of the differential diagnosis of clear-cell lesions of the skin in connection with the rare case of a clear-cell atypical fibroxanthoma. *Pathol Res Pract* 2009;205:365–370.
- 9 Corbalan-Velez R, Ruiz-Macia JA, Brufau C, Martinez-Escribano J, Ara-Martin M, Carapeto FJ: Bowenoid wart: wart with bowenoid histological changes? *Dermatology* 2009;218:159–163.
- 10 Inaba Y, Ewaka K, Ono T: Demonstration of human papillomavirus type I DNA in a wart with bowenoid histological changes. *Am J Dermatopathol* 1993;15:172–175.
- 11 Goette DK: Carcinoma in situ in verruca vulgaris. *Int J Dermatol* 1980;19:98–101.
- 12 Odges A, Smoller RB: Immunohistochemical comparison of p16 expression in actinic keratoses and squamous cell carcinomas of the skin. *Mod Pathol* 2002;15:1121–1125.
- 13 Willman HJ, Heinz D, Golizt EL, Shroyer RK: Correlation of p16 and pRb expression with HPV detection in Bowen's disease. *J Cutan Pathol* 2006;33:629–623.
- 14 Reis-Filho JS, Torio B, Albergaria A, Schmitt FC: p63 expression in normal skin and usual cutaneous carcinomas. *J Cutan Pathol* 2002;29:517–523.
- 15 Park HR, Min SK, Cho HD, Kim KH, Shin HS, Park YE: Expression profiles of p63, p53, survivin and hTERT in skin tumors. *J Cutan Pathol* 2004;31:544–549.
- 16 Monteagudo C, Calduch L, Navarro S, Joan-Figueroa A, Llombart-Bosch A: CD99 immunoreactivity in atypical fibroxanthoma: a common feature of diagnostic value. *Am J Clin Pathol* 2002;117:126–131.
- 17 Mathew RA, Schlauder SM, Calder KB, Morgan MB: CD117 immunoreactivity in atypical fibroxanthoma. *Am J Dermatopathol* 2008;30:34–36.
- 18 Feraudy SD, Mar N, McCalmon TH: Evaluation of CD10 and procollagen 1 expression in atypical fibroxanthoma and dermatofibroma. *Am J Surg Pathol* 2008;32:1111–1122.
- 19 Kempson LR, Fletcher CDM, Evans LH, Hendrickson RM, Sibley KR: Tumors of the soft tissues. *Atlas of Tumor Pathology AFIP* 2001;134–138.
- 20 Engelbrecht EN, Ford GJ, White LW, Yeatts PR: Combined intraepithelial squamous neoplasia and atypical fibroxanthoma of the cornea and limbus. *Am J Ophthalmol* 2000;129:94–96.