



Full-thickness resection of subepithelial nodules, allowing for the diagnosis of an unusual case of pneumatosis cystoides intestinalis

Sunil Amin, MD, MPH,¹ Russell Dorer, MD, PhD,² Shayan Irani, MD²

A 61-year-old otherwise healthy man was referred to us for further evaluation of multiple firm, large, subepithelial descending colonic nodules. The area of nodularity was found incidentally on a screening colonoscopy and was located in the descending colon near the splenic flexure. The nodules extended over a length of 5 cm and varied in size from 1 cm to 2.5 cm. One nodule was sampled several times; however, examination of biopsy specimens revealed only colonic mucosa with inflammation and architectural distortion. Further evaluation with conventional CT and gallium-68 positron emission tomography/CT showed no evidence of metastatic disease, neuroendocrine cause, or any visible abnormality in the colon. After surgical consultation, the patient was referred for repeated colonoscopy and endoscopic sampling.

Our colonoscopic examination showed at least 6 nodules ranging in size from 7 mm to 2.5 cm (Fig. 1). The nodules were firm upon probing with a biopsy forceps and would not decompress. The overlying mucosa appeared normal. The pediatric colonoscope was then

loaded with both a 14-mm over-the-scope clip (OTSC) and a snare with the intent to perform a full-thickness resection (Video 1, available online at www.VideoGIE.org).

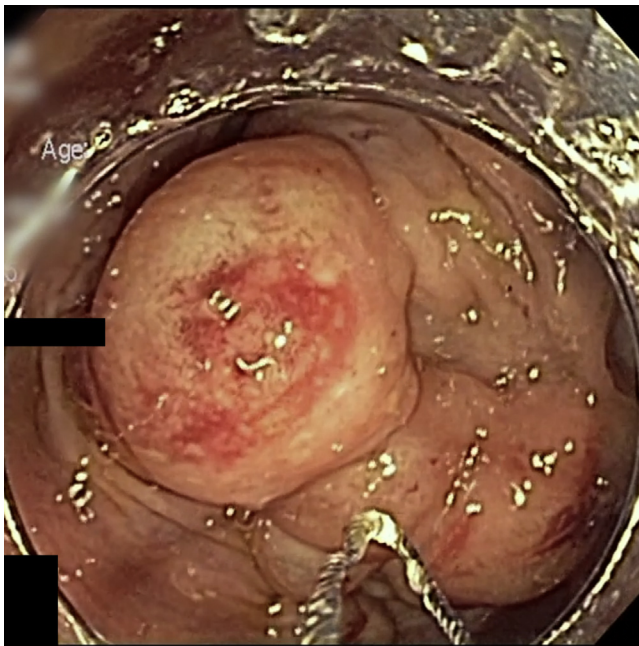


Figure 1. Descending colon nodules ranging in size from 1 cm to 2.5 cm.

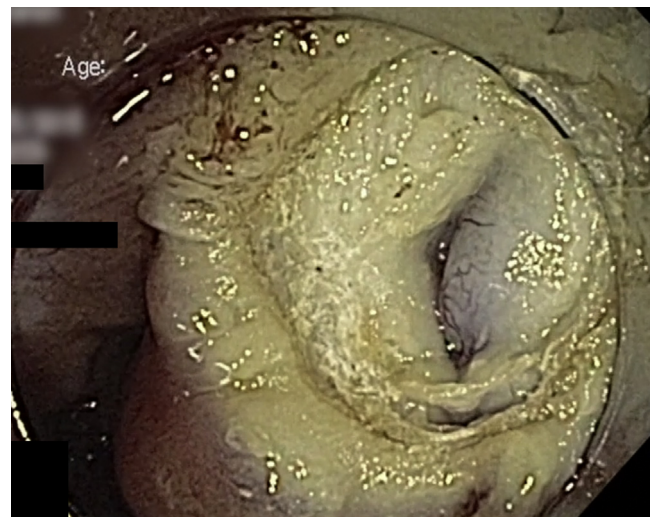


Figure 2. Peritoneal defect after full-thickness resection.

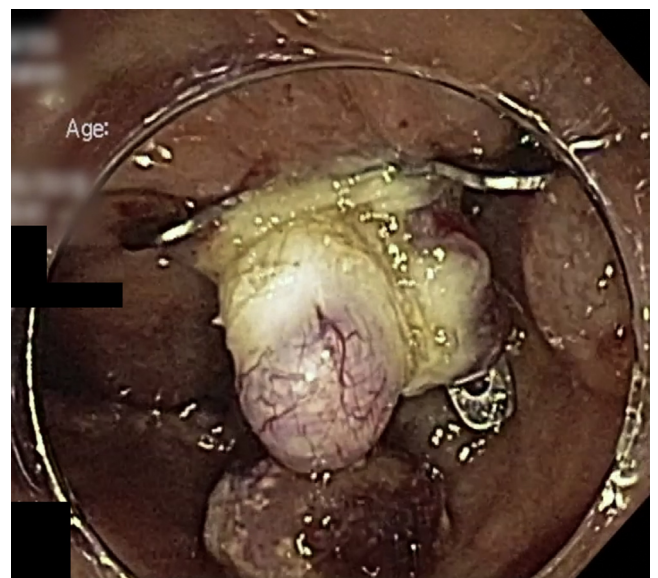


Figure 3. Deployed over-the-scope clip with complete closure of colonic defect.

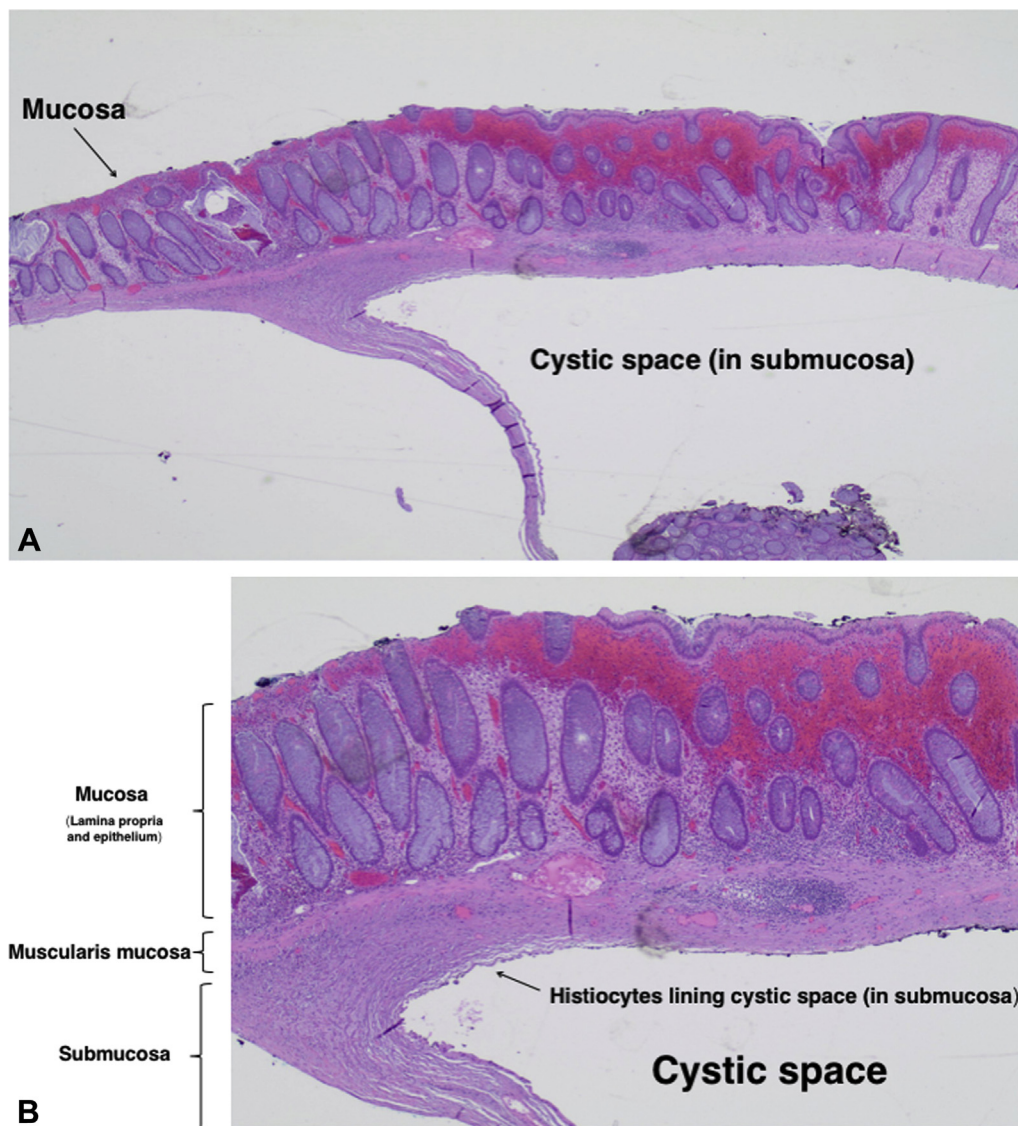


Figure 4. **A**, Low-power view of final histologic specimen confirming pneumatosis cystoides intestinalis (H&E, orig. mag. $\times 20$). Cyst can be seen in submucosa. **B**, Higher-power view (H&E, orig. mag. $\times 40$). Histiocytes can be seen lining the cystic space in the submucosa.

org). A 12-mm nodule was removed en bloc with a hot snare by use of a pure cut current in an effort to achieve full-thickness resection. During the resection, tiny bubbles were seen, which appeared unusual. After successful resection, a small full-thickness defect was seen with visualization of the peritoneum (Fig. 2). No peritoneal contamination occurred, given that the colonoscope was prefitted with an OTSC. The OTSC was deployed with complete closure of the colonic defect (Fig. 3). Biopsy of the base of the lesion was then performed with hot biopsy forceps to confirm that the lesion had been removed in its entirety. The patient was admitted for overnight observation and discharged the next day with no abdominal pain.

Gross pathologic examination revealed a 1.7-cm \times 1.4-cm \times 0.1-cm pink-red soft tissue fragment with a 0.8-

cm \times 0.6-cm \times 0.4-cm nodule under the mucosal surface. Histologic evaluation then confirmed benign mucosa and submucosa with a rim of histiocytes and multinuclear giant cells around a submucosal cyst, consistent with pneumatosis cystoides intestinalis (PCI) (Fig. 4). The location of the gas in the submucosa explained why the mucosal biopsy specimens were nondiagnostic.

PCI is a rare condition characterized by gas-filled cysts within the intestinal wall. The cysts are often incidentally discovered on screening colonoscopy because the majority of patients with colonic PCI are asymptomatic.¹ Most cysts tend to have a bluish hue and can be decompressed (often with an audible hiss) with the use of well biopsies. Diagnosis is usually confirmed by cross-sectional imaging or EUS.^{2,3} A host of conditions have been associated with PCI, including pulmonary

diseases such as chronic obstructive pulmonary disease.¹

Our case was a diagnostic challenge because the patient had neither pulmonary disease that would predispose him to segmental pneumatosis nor other commonly observed features at colonoscopy or cross-sectional imaging. The gas was located in the submucosa; thus, mucosal biopsy specimens at the time of colonoscopy were nondiagnostic. Furthermore, PCI was not detected on contrast-enhanced CT. Given this prior nondiagnostic evaluation, endoscopic intervention was planned. EUS was not possible, given the difficulty in navigating a tortuous left colon segment. Full-thickness resection with immediate closure proved to be a safe and reliable means of tissue sampling in this situation and can be considered for other similar indeterminate sub-epithelial colonic nodules.

DISCLOSURE

Dr Irani is a consultant for Boston Scientific. All other authors disclosed no financial relationships relevant to this publication.

Abbreviations: OTSC, over-the-scope clip; PCI, pneumatosis cystoides intestinalis.

REFERENCES

1. Heng Y, Schuffler MD, Haggitt RC, et al. Pneumatosis intestinalis: a review. *Am J Gastroenterol* 1995;90:1747-58.
2. Kernagis LY, Levine MS, Jacobs JE. Pneumatosis intestinalis in patients with ischemia: correlation of CT findings with viability of the bowel. *AJR Am J Roentgenol* 2003;180:733-6.
3. Ribaldone DG, Bruno M, Gaia S, et al. Endoscopic ultrasound to diagnose pneumatosis cystoides intestinalis (with video). *Endosc Ultrasound* 2017;6:416-7.

University of Miami, Miami, Florida, USA (1); Virginia Mason Medical Center, Seattle, Washington, USA (2).

If you would like to chat with an author of this article, you may contact Dr Amin at sunilpamin@gmail.com.

Copyright © 2019 American Society for Gastrointestinal Endoscopy. Published by Elsevier Inc. This is an open access article under the CC BY-NC-ND license (<http://creativecommons.org/licenses/by-nc-nd/4.0/>).

<https://doi.org/10.1016/j.vgie.2019.12.003>

Read Articles in Press Online Today!
Visit www.videogie.org

VideoGIE posts in-press articles online in advance of their appearance in a monthly edition of the journal. These articles are available on the *VideoGIE* website by clicking on the “Articles in Press” tab. Articles in Press represent the final edited text of articles that are accepted for publication but not yet scheduled to appear in a specific issue. They are considered officially published as of the date of Web publication, which means readers can access the information and authors can cite the research months prior to its availability in an issue. To cite Articles in Press, include the journal title, year, and the article’s Digital Object Identifier (DOI), located in the article footnote. Visit the website today to stay current on the latest research in the field of gastrointestinal endoscopy.