

Effect of a Self-Etch Adhesive Containing Nanobioglass on Postoperative Sensitivity of Posterior Composite Restorations - A Randomized Trial

Ahmed Zakaria Aboelenein^{1*}, Mona Ismail Riad², Mohammed Fouad Haridy^{2,3}

¹Operative Dentistry Department, Faculty of Dentistry, Fayoum University, Fayoum, Egypt; ²Operative Dentistry Department, Faculty of Oral and Dental Medicine, Cairo University, Cairo, Egypt; ³Operative Dentistry Department, British University in Egypt, Cairo, Egypt

Abstract

Citation: Aboelenein AZ, Riad MI, Haridy MF. Effect of a Self-Etch Adhesive Containing Nanobioglass on Postoperative Sensitivity of Posterior Composite Restorations - A Randomized Trial. Open Access Maced J Med Sci. 2019 Jul 30; 7(14):2313-2320. <https://doi.org/10.3889/oamjms.2019.585>

Keywords: Postoperative sensitivity; Bioglass; Composite restorations; Class II

***Correspondence:** Ahmed Zakaria Aboelenein, Operative Dentistry Department, Faculty of Dentistry, Fayoum University, Fayoum, Egypt. E-mail: azs11@fayoum.edu.eg

Received: 29-Apr-2019; **Revised:** 27-Jun-2019; **Accepted:** 28-Jun-2019; **Online first:** 25-Jul-2019

Copyright: © 2019 Ahmed Zakaria Aboelenein, Mona Ismail Riad, Mohammed Fouad Haridy. This is an open-access article distributed under the terms of the Creative Commons Attribution-NonCommercial 4.0 International License (CC BY-NC 4.0)

Funding: This research did not receive any financial support

Competing Interests: The authors have declared that no competing interests exist

BACKGROUND: Postoperative sensitivity is one of the major problems regarding posterior resin composite restorations that causes patient discomfort, maybe a reason for replacement of the restoration with an additional office time.

AIM: To evaluate the effect of the addition of a Nanobioglass to a self-etch adhesive on the reduction of post-operative sensitivity following composite restorations versus a self-etch adhesive that is free of Nanobioglass agent.

MATERIALS AND METHODS: Sixteen patients having class II carious lesions were included in the study. After cavity preparation, each tooth was randomised to one of the following restorative treatments. Teeth in the control group were restored using self-etch adhesive (OptiBond All-In-One, Kerr) that is free of nanobioglass agent, and nano-hybrid resin composite (Herculite Ultra, Kerr). Restoration of teeth in the experimental group was similar to the control except that a nanobioglass agent was added to the self-etch adhesive. Patients were contacted for evaluation of postoperative sensitivity at 1 day, 1 week, 1 month, and 3 months. Data were analyzed using friedmann test followed by fisher exact test.

RESULTS: The experimental group (self-etch adhesive containing nanobioglass) showed a significantly less postoperative sensitivity compared with the control group (Self-etch adhesive free of nanobioglass) at 1 day, and 1-week evaluation periods. While both groups did not possess any significant difference at 1 month, and 3 months periods.

CONCLUSION: The problem of postoperative sensitivity following resin composite restorations could be solved by the addition of bioglass nanoparticles into dental adhesives.

Introduction

Composite resins and adhesive technology have developed rapidly. Despite these developments, postoperative sensitivity following composite restorations is still a challenge for practitioners. Clinical studies revealed the presence of such complaints in 0-30% of the study populations [1]. It was reported that postoperative pain could be related to preparation trauma and microleakage of bacteria [2]. Other studies reported that polymerization shrinkage of composite leads to internal stresses,

debonding and gap formation between the composite and tooth, leading to deformation of restorations under occlusal stresses which transmits hydraulic pressure to the odontoblastic processes causing pain [3], [4].

Several strategies have been presented in the literature tried to solve the problem of postoperative sensitivity, by using different light-curing modes [5], different adhesive strategies [6], applying cavity disinfectants and desensitizers before the bonding procedure [7], and implementing different techniques for placement of posterior composite restorations [8].

Now, post-operative sensitivity solution has been related to dentin adhesives' ability to seal up the gaps and open dentinal tubules that are present at the interface between the dentin adhesive and the dentin rather than the continuous trial to decrease polymerization shrinkage and its effects on cuspal deflections and marginal adaptation as was generally believed [9]. To address this solution, it was necessary to develop novel dental adhesives that contain nanobioglass having remineralising capabilities that could block these gaps, thus decreasing postoperative sensitivity.

In the current literature, no randomised clinical trials have evaluated the effect of a self-etch adhesive containing nanobioglass on the incidence of postoperative sensitivity. In turn, this study would affect the feasibility of postoperative sensitivity reduction and consequently would benefit the patients.

Material and Methods

The materials used as well as their principal components, manufacturers and lot number are listed in Table 1.

Table 1: Materials' composition, manufacturers, and Lot number

Material	Specifications	Composition	Manufacturer	Lot Number
OptiBond All-In-One	One-Step, Self-Etch Adhesive system	Acetone, ethyl alcohol, uncured methacrylate ester monomers, inert mineral fillers, ytterbium fluoride, photoinitiators, accelerators, stabilisers, water		5811789
Herculite Ultra	Visible light cured Nano-Hybrid resin composite	Organic part: Bis-GMA ¹ , TEGDMA ² , Bis-EMA ³ Inorganic part: Barium glass (0.4 μ m; silica, 20-50 nm); pre-polymerized filler (barium glass and silica) Filler load 78% wt (57% vol)	Kerr, Italia S.r.l	2391712

Abbreviations: Bis-GMA, Bisphenol A diglycidylmethacrylate; TEGDMA, Triethyleneglycoldimethacrylate; BIS-EMA: Bisphenol A polyethylene glycol diether dimethacrylate.

Preparation and Characterization of Nanobioglass Powder Particles

The bioglass nanoparticles used in this study were prepared using the sol-gel technique [10]. Nitric acid in water (1 Mole solution) was added to tetraethyl orthosilicate (TEOS) for a final H₂O: TEOS molar ratio of 18. The solution was subjected to hydrolysis for 60 minutes while stirring at room temperature. The following reagents were added and allowed to react for 45 minutes in the following sequence: triethyl phosphate, calcium nitrate tetrahydrate, and sodium hydroxide. The solution was stored in a sealed container for 3 days at room temperature to allow gel formation. The gel was aged for 3 days at 70°C and

then dried in an oven at 150°C for 3 days. Finally, the dried gel was calcined in a high alumina crucible (furnace) at 700°C for 3 hours resulting in white bioglass nanoparticles.

The principal components and manufacturer of the nanobioglass are listed in Table 2. The resultant particles were characterised using Transmission electron microscope (TEM) (JEOL JEM-2100, Tokyo, Japan) to assess its size and shape. Scanning Electron Microscope (SEM) & Energy Dispersive Analytical X-ray (EDAX) (Fei Company, model: Quanta 250 FEG, Germany) was also used to examine its surface topography, and ensuring the purity of the resultant powder.

Table 2: Nanobioglass composition, and manufacturer

Preparation	Composition	Manufacturer
Nanobioglass powder	45% SiO ₂ , 25% CaO, 25% Na ₂ O and 5% P ₂ O ₅	Nanostreams Company, 6 th of October City, Egypt

Incorporation of Nanobioglass Into The Self-etch Adhesive

The optimum amount of nanobioglass that could be added to the self-etch adhesive without affecting its viscosity was determined by measuring the viscosity of the self-etch adhesive before and after nanobioglass incorporation according to previous studies [11], [12]. The whole self-etch adhesive bottle containing the nanobioglass was then sonicated in the ultrasonic mixer to produce a homogenous mixture.

Study Design

This was a double-blinded (operator and patient), randomised clinical trial.

Patients Recruitment

This study was revised and approved by the research ethics committee, Faculty of Oral and Dental medicine, Cairo University. Patients were recruited from the outpatient clinic of the Operative dentistry department, Faculty of Dentistry, Cairo University. They were then assessed for eligibility according to the inclusion and exclusion criteria listed below. Patients were informed of the nature of the study, consented to participate and signed a consent form.

Inclusion and Exclusion Criteria

Selected patients had to have a moderate to the deep proximal primary carious lesion in posterior teeth as diagnosed by clinical examination and a periapical radiograph. Selected teeth should have an occlusal contact with natural or a crowned antagonist tooth so that it could be tested for post-operative pain during food mastication. Patients had to have healthy gingival tissues, without gingival recession or alveolar

bone loss. Patients were excluded if they had any signs or symptoms of pulpal and periapical disease, spontaneous dental or orofacial pain, defective restorations that need replacement. Patients are taking medications and analgesics that could alter their normal pain perception level, and patients having medical, psychiatric histories, including the use of anti-inflammatory, psychotropic drugs were also excluded.

Randomisation

Patients were randomly allocated into two groups according to the investigated restorative treatment provided: 1. Experimental group: single-step self-etch adhesive containing nanobioglass and 2. Control group: a single-step self-etch adhesive that is free of nanobioglass. Randomisation depended on two interrelated aspects: Sequence generation, and allocation concealment. Sequence generation involved the allocation of each patient to one of the restorative treatment options according to a randomisation list generated using "random.org". Thus, the randomisation list defined the type of the used self-etch adhesive (either containing or free of nanobioglass). Allocation concealment involved unrevealing and concealing the randomisation list by placing them in an opaque and sealed envelope. At the day of restoration, each patient was allowed to pick up an envelope randomly. Each envelope contains a numbered paper that corresponds to one of the restorative treatment options, according to the previously created randomisation list.

Blinding

The current study was double-blinded. The patient did not know what treatment she/he was taking. The operator was blinded to the treatment option given; self-etch adhesive (containing or free of nanobioglass), as they were masked in two identical bottles and was given codes (A & B) (Figure 1). A researcher not involved in any of the experimental phases performed the procedures of Sequence generation, allocation concealment, and blinding.



Figure 1: Restorative treatment options masked in identical bottles

Interventions

Patients' general information, including name, gender, occupation, age, and phone number, were recorded. Also, medical and dental histories were taken. The diagnosis of caries was depending based on clinical examination that was done tentatively using a diagnostic mirror and an explorer aided by the light from the dental unit. Pre-operative radiographic examination (Figure 2) was routinely taken to evaluate cavity proximity to the pulp and any sign of periapical radiolucency that could preclude the patient inclusion into the study

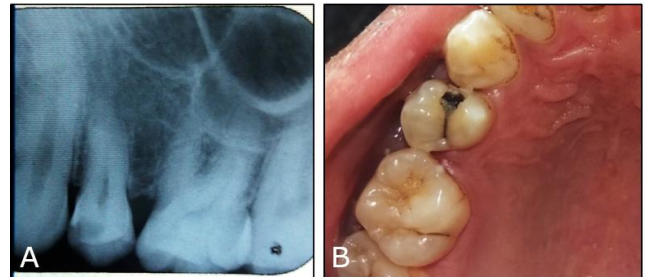


Figure 2: A): Periapical radiograph showing proximal caries; B): clinical picture

The patient was anaesthetised using a local anaesthetic, Mepecaine-L local anaesthesia, using a dose of 20mg Mepivacaine hydrochloride U.S.P., 0.06 mg Levonordefrin hydrochloride (Alexandria Co. for Pharmaceuticals, Alexandria, Egypt) to control tooth pain during caries removal. The field of operation was isolated with the application of a rubber dam. Entrance to the lesion and lateral extension through the cavity was then done using an inverted cone bur # 35 (MIDWEST, DENTSPLY) under air-water coolant. In case of deep cavities with a large amount of carious dentin, the highly softened dentin was removed using an excavator. A caries detector dye (Kuraray America) was then used to disclose the residual infected dentin at the pulpal floor and surrounding walls, by applying the dye using a disposable applicator brush for 10 seconds, rinsed off, then stainable (red) tissue was removed using a spoon excavator (Becht, Germany).

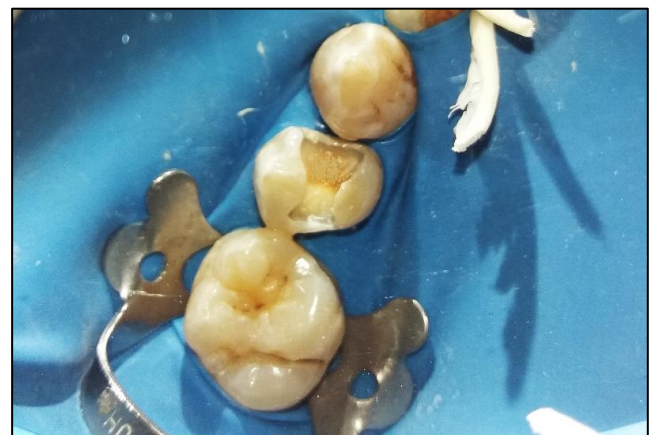


Figure 3: Finished cavity preparation

The procedure was repeated two times until the dentin surface was stained pale pink and was relatively hard. Teeth were excluded from the study in case of a pulp exposure, where calcium hydroxide agent was placed. The cavo-surface angle of the prepared cavity was entirely in enamel without beveling (Figure 3). The cavity walls were then smoothed with a straight fissure bur # 57 (MIDWEST, DENTSPLY).

Sectional metal matrices with rings (TOR VM LTD, Moscow, Russia) and wooden wedges were placed before the bonding and restorative procedures (Figure 4). OptiBond was applied according to the manufacturer's instructions as follows: a generous amount of the bonding agent was applied to the enamel and dentin surfaces using a disposable applicator brush. Scrubbing of the surfaces was then done with a brushing motion for 20 seconds. A second application of the bonding agent was then performed with a brushing motion for 20 seconds. The adhesive was then dried for 5 seconds with oil-free air, and light-cured for 10 seconds using Elipar LED curing light (3M ESPE) at a light intensity of 1200 mw/cm².

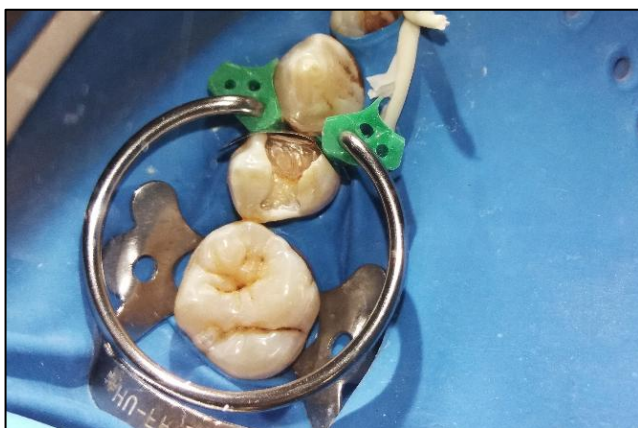

Figure 4: Sectional metal matrix

Cavity preparations were restored using Herculite Ultra nano-hybrid resin composite (Kerr, Italia). Proximal boxes were initially restored using oblique incremental packing technique. The increments were light-cured from both the occlusal surface and indirectly through the cusps using Elipar LED curing light for 10 seconds. After the final build-up, the restoration was further polymerised for 10 seconds in three directions: occlusal, buccal and lingual. After final polymerisation of the restoration, the rubber dam was removed. Premature contacts were detected with an articulating paper and removed with a flame shape finishing carbide bur # 7106 (MIDWEST, DENTSPLY) in a high-speed handpiece under air-water coolant. Restorations were then finished using a flame shape finishing carbide bur # 7106 (MIDWEST, DENTSPLY) and polished using rubber cup and flame polishers (HiLuster polishers, KerrHawe). Figure 5 illustrates the final restoration after finishing and polishing.

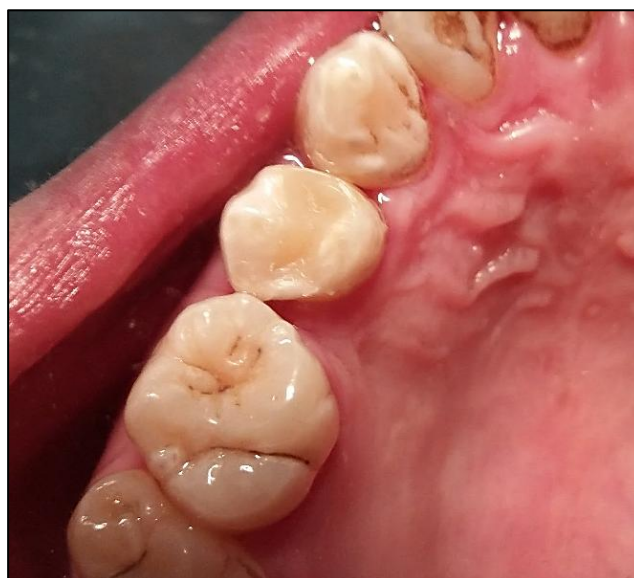

Figure 5: Final restoration after finishing and polishing

Postoperative Sensitivity Evaluation and Testing

Post-operative sensitivity was evaluated using a Visual Analog Scale (VAS). It is 100 mm horizontal line with a descriptor at its far-left end indicating no pain, and at its far-right end indicating the worst possible pain. Illustration of facial expressions with colour codes was added below the 10-centimetre line Visual Analog Scale (Figure 6).



Figure 6: Visual Analog Scale

Participants were instructed to rate the pain level using VAS scale as follows: If the pain were the worst possible, the participant would mark at the far-right end of the line, and in the absence of pain he would mark at the far-left end. For pain levels between the two extremes, participants made a mark at a point along the line that best represented their pain. The distance in millimetres from the far-left end of the line to the marked point of intersection was measured and recorded.

POS was tested against normal daily life stimuli, patients were requested to report their pain levels against cold, hot, sweet stimuli during drinking or eating, and pressure stimuli during their masticatory routine. The participants were instructed to avoid taking any analgesic or anti-inflammatory drugs during the whole study period.

Follow-up evaluation periods were scheduled at 1 day, 1 week, 1 month and 3 months intervals. At each evaluation period, patients were contacted via telephone calls to remind them to rate their sensitivity

levels on the VAS scale. They were also verbally questioned regarding the presence of spontaneous pain, and whether it is prolonged or not. Pre-operative sensitivity levels were assumed as zero as asymptomatic teeth were selected [13].

Statistical Analysis

Data were presented as mean and standard deviation (SD) values. Data were explored for normality using Kolmogorov-Smirnov and Shapiro-Wilk tests. Friedmann test was used to compare between different follow-up periods for different tested groups, followed by Fisher exact test for Pairwise comparison. Mann Whitney test was used to compare between different tested groups. The significance level was set at $P \leq 0.05$. Statistical analysis was performed with IBM® SPSS® (SPSS Inc., IBM Corporation, NY, USA) Statistics Version 24 for Windows.

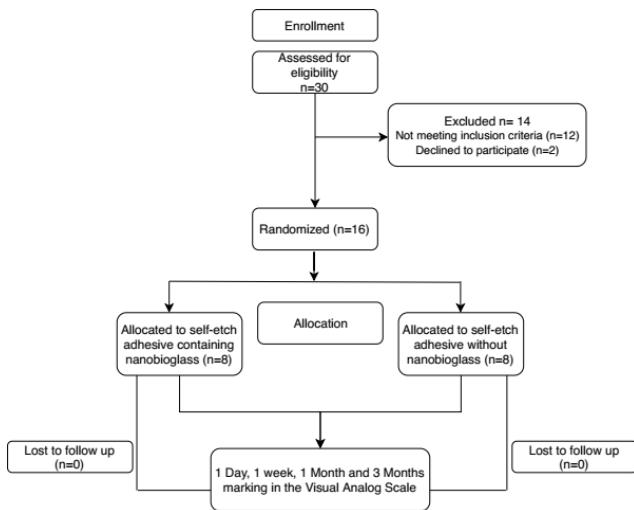


Figure 7: Participant flow diagram in the different phases of the study design

Results

The experimental protocols were implemented exactly as planned, and no modifications were performed. Figure 7 shows the participant flow diagram at the different phases of the study design. A total of 30 patients were recruited and assessed for eligibility. 14 patients were excluded (2 patients declined to participate, and 12 patients did not meet the inclusion criteria). 16 patients were then subjected to the randomisation procedure and allocated to one of the treatment options to be 8 patients in every group. All patients returned to a 3 months recall.

None of the subjects needed an analgesic drug to reduce postoperative sensitivity (POS). Regardless of the group, most of the postoperative

sensitivity complaints occurred within the 1 day and 1-week evaluation periods. Mean and standard deviation (SD) of Visual Analog Scale (VAS) scores for different groups at all follow-up periods are shown in Table 3 and Figure 8.

Table 3: Mean and SD values of VAS scores for tested materials at different evaluation periods

	Group A (Nanobioglass)		Group B (Control)		p-value
	Mean	SD	Mean	SD	
Pre-operatively	0.00 ^a	0.00	0.00 ^a	0.00	1.00 NS
1 Day	2.06 ^b	2.24	4.75 ^b	1.75	0.038*
1 Week	1.38 ^b	1.69	3.69 ^b	1.51	0.015*
1 Month	0.44 ^c	0.62	0.63 ^c	0.74	0.721 NS
3 Months	0.00 ^a	0.00	0.00 ^a	0.00	1.00 NS
p-value	$\leq 0.001^*$		$\leq 0.001^*$		

Means with different letter within each column indicates significant difference; * = Significant, NS = Non-significant.

The mean VAS scores for the nanobioglass and control groups at 1 day and 1-week evaluation periods was higher than the 1 month, and 3 months periods with a significant difference ($p \leq 0.001$; Fisher exact test). This dictates that the peak of POS was in the first week after treatment. The mean VAS scores for both groups declined at the 1 month, and 3 months period. All patients reported no sensitivity after 3 months.

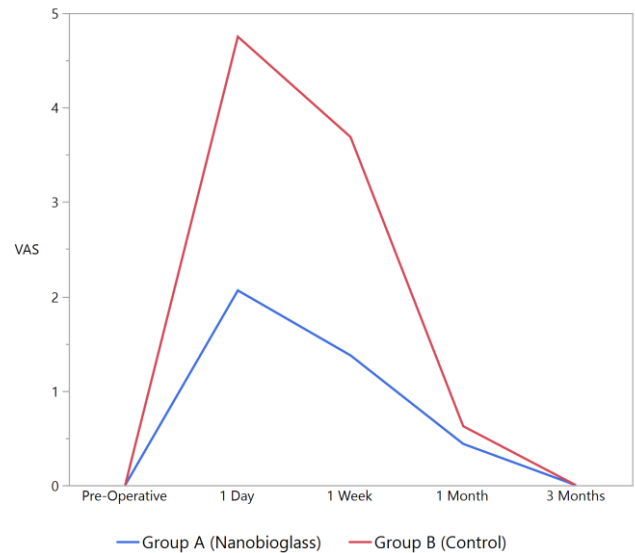


Figure 8: A-Line Chart showing the mean VAS Scores for tested materials at different evaluation periods

As for the comparison between the two groups, the mean VAS scores for the nanobioglass group was lower than the control group at the 1-day (2.06 and 4.75 respectively), and 1-week (1.38 and 3.69 respectively) evaluation periods with a statistically significant difference. While at the 1 month, and 3 months, the difference between the mean VAS scores for both groups was statistically insignificant. This indicates that nanobioglass was effective in decreasing POS.

Discussion

Placing successful posterior composite restorations is challenging and technique sensitive, so any mistake during placement of such restorations will lead to postoperative problems. It is well reported that POS is one of the main problems regarding this type of restoration. The postulated theory for POS following composite restorations include gap formation that predisposes to microleakage. This, in turn, causes compressibility of the restoration during loading, causing fluid to be forced in and out from underneath the restoration causing pain. The current theory of pulpal tooth pain dictates that any change in the hydraulic pressure within the dentinal tubules stimulates the pain receptors within the pulp, causing pain. Consequently, how efficient the dentin adhesive seals the cut dentinal tubules seem to be the winning factor in decreasing POS.

In this regard, a nanobioglass was incorporated into the dental adhesive in the current study. Concerning its nano-sized bioactive components, those gaps in the dentinal tubules could be sealed. Besides, its high surface area allows the release of more calcium and phosphate ions at low concentrations. This is important because a low filler concentration could be used for adhesives so that the adhesive could maintain its viscosity and ability to flow into the dentinal tubules.

Another important reason for using nanobioglass particles is that its average size of about 20 nm that could infiltrate into the dentinal tubules more easily than the traditional particles of several microns to tens of microns in size [11]. In addition, nanobioglass is a precursor that can convert to an apatite, similar to the minerals in tooth enamel and dentin. Bioglass, when exposed to a physiological fluid, cation exchange of Na⁺ and Ca²⁺ by protons (H⁺ or H₃O⁺) occurs on the bioglass surface to form microporous silica (SiO₂⁻ rich layer) upon which Hydroxy Carbonate Apatite (HCA) layer forms. Changes in pH and weight loss happen with the change in the ionic dissolution and consecutive precipitation of hydroxy carbonate apatite [11].

A single step self-etch adhesive strategy was selected for the current trial. Early clinical studies [14], [15] attributed the cause of POS to the use of etch and rinse adhesive systems. This was not the case for the more recent studies [16], [17] who believed that self-etch adhesive systems lowers the risk of POS as they do not remove, but incorporate the smear layer in the hybridised area. Furthermore, because dentin conditioning and resin infiltration occur simultaneously, dentin tubules are more likely to remain sealed. Nevertheless, a recent systematic review [18] has helped to support or refute these findings; they stated that the type of adhesive strategy, either etch and rinse or self-etch for posterior resin composite restoration does not influence the risk

and intensity of POS.

Class II cavities were chosen for this study because of the incidence of post-operative sensitivity in class II cavities is higher than that of other cavity preparations [19], as the increased amount of destruction of dental structure that is found in class II cavities seems to be the determinant factor in the occurrence of POS, this was explained by a series of cuspal contraction and expansion that occurs during the bonding procedure [13].

Only moderate to deep cavities were included in the current study. As the dentin is prepared closer to the pulp, the tubule density and diameter increase, thus increasing both the volume and flow of pulpal fluid (hydrodynamic effects) when teeth are subjected to stimuli [20] which is perceived by patients as pain. In other words, it would be expected that restorations placed in deep cavities are associated with more postoperative sensitivity [21]. Therefore, it was logical to determine the ability of the tested materials to occlude those tubules under the circumstances of such hydrodynamic effects. Shallow cavities were not included in the current study, since post-operative sensitivity is low or infrequently detected in shallow cavities, as reported by other clinical studies [22], [23].

Resin composite restorations in the current study were placed directly in posterior teeth without the use of liners and bases in accordance with a systematic review [24] that linked the use of liners to the reduction in postoperative sensitivity, they revealed that there is an inconsistent evidence regarding the difference in POS between resin composite restorations placed with or without liners. Resin composite was placed using an incremental filling technique and indirect curing through the cusps, to minimize the deleterious effects of polymerization shrinkage stresses on the marginal integrity of the composite restorations as well as on the microscopic integrity of the adhesive bond to dentin [22].

The Visual Analog Scale (VAS) method that was used to evaluate POS in the current study offers participants a broader range of responses and more uniform instructions by avoiding descriptors such as mild, moderate and severe, which can be interpreted quite differently from one participant to another [25]. Furthermore, it provides a more accurate and effective statistical test than tests based on fixed categories [26]. Besides, its ability to detect minor changes in pain intensities over time or due to treatment [27].

Illustration of facial expressions with colour codes was added below the 10-centimetre line Visual Analog Scale, in an attempt to make it better understood by patients. Furthermore, more cooperation from the patients was experienced when facial expressions were added rather than a plain 10-centimetre line was used alone [28]. POS testing in the current study, has typically been based on the patient's day-to-day experiences (real life) to various stimuli like pressure, cold and sweet stimuli during

drinking, eating and chewing. This has provided a more realistic scenario for POS testing rather than a standardised, controlled stimulus that the patient may not encounter throughout his life [16].

The 3 months evaluation period that was assigned for the current study might have provided a more reasonable scenario for testing the effectiveness of the investigated materials, giving them more time to block the incompletely sealed dentinal tubules present in the hybridised layer, thus decreasing POS on longer periods. This was by a previous study [13] who evaluated postoperative sensitivity after 33 months despite the study design was to evaluate it at 48 hours and 1 week only, as they were contacted by patients complaining of post-operative sensitivity after 33 months of their study. All clinical work in this study was carried out by one clinician to reduce the variability among clinicians in handling and manipulating materials.

Post-operative sensitivity (POS) results revealed that the nanobioglass group has lower VAS scores than the nanobioglass free one with a statistically significant difference. This might be due to the presence of nanoparticles of calcium and phosphate in the composition of the nanobioglass. Furthermore, the presence of an acidic self-etching primer in the composition of the self-etch adhesive has demineralised the peritubular dentin. The dissolved ions from the peritubular dentin, in addition to the calcium and phosphate ions from the bioglass, all together have formed a precipitate that might have occluded the cut dentinal tubules, thus reducing POS.

These results were similar to the findings of a previous study [11] who incorporated nanoparticles of amorphous calcium phosphate (NACP) into dental adhesives. They found numerous NACP nanoparticles in the adhesive layer, in the hybrid zone, and inside the dentinal tubules. NACP was not only able to infiltrate with the adhesive into straight tubules but also into bent and irregularly shaped tubules without impairing the adhesive bond strength to dentin.

In conclusion, within the limitations of this clinical trial, we have concluded that the problem of postoperative sensitivity following posterior resin composite restorations could be solved by the addition of bioglass nanoparticles into dental adhesives.

References

1. Wassell RW, Walls AW, McCabe JF. Direct composite inlays versus conventional composite restorations: three-year clinical results. *Br. Dent. J.* 1995; 179(9):343-9. <https://doi.org/10.1038/sj.bdj.4808919> PMID:7495630
2. Brännström M. Infection beneath composite resin restorations: can it be avoided? *Oper. Dent.* 1987; 12(4):158-63.
3. Eick JD, Welch FH. Polymerization shrinkage of posterior composite resins and its possible influence on postoperative sensitivity. *Quintessence Int.* 1986; 17(2):103-11.
4. Jordan RE, Suzuki M, Boksman L. Posterior composite restorations--where do we stand? *Ont. Dent.* 1985; 62(12):13-4, 17-8, 20.
5. Alomari Q, Omar R, Akpata E. Effect of LED curing modes on postoperative sensitivity after Class II resin composite restorations. *J. Adhes. Dent.* 2007; 9(5):477-81.
6. Coelho-de-Souza FH, Klein-Júnior CA, Camargo JC, Beskow T, Balestrin MD, Demarco FF. Double-blind randomized clinical trial of posterior composite restorations with or without bevel: 6-month follow-up. *J. Contemp. Dent. Pract.* 2010; 11(2):001-8. <https://doi.org/10.5005/jcdp-11-2-1>
7. Hajizadeh H, Ghavamnasiri M, Majidinia S. Randomized clinical evaluation of the effect of chlorhexidine on postoperative sensitivity of posterior composite resin restorations. *Quintessence Int.* 2013; 44(10):793-8.
8. Costa T, Rezende M, Sakamoto A, Bittencourt B, Dalzochio P, Loguercio A, et al. Influence of Adhesive Type and Placement Technique on Postoperative Sensitivity in Posterior Composite Restorations. *Oper. Dent.* 2017; 42(2):143-54. <https://doi.org/10.2341/16-010-C> PMID:27892839
9. Sarrett DC, Brooks CN, Rose JT. Clinical performance evaluation of a packable posterior composite in bulk-cured restorations. *J. Am. Dent. Assoc.* 2006; 137(1):71-80. <https://doi.org/10.14219/jada.archive.2006.0024> PMID:16457002
10. Zhong J, Greenspan DC. Processing and properties of sol-gel bioactive glasses. *J. Biomed. Mater. Res.* 2000; 53(6):694-701. [https://doi.org/10.1002/1097-4636\(2000\)53:6<694::AID-JBM12>3.0.CO;2-6](https://doi.org/10.1002/1097-4636(2000)53:6<694::AID-JBM12>3.0.CO;2-6)
11. Melo MAS, Cheng L, Zhang K, Weir MD, Rodrigues LKA, Xu HHK. Novel dental adhesives containing nanoparticles of silver and amorphous calcium phosphate. *Dent. Mater.* 2013; 29(2):199-210. <https://doi.org/10.1016/j.dental.2012.10.005> PMID:23138046 PMID:PMC3552134
12. Liang K, Weir MD, Reynolds MA, Zhou X, Li J, Xu HHK. Poly (amido amine) and nano-calcium phosphate bonding agent to remineralize tooth dentin in cyclic artificial saliva / lactic acid. *Mater. Sci. Eng. C* 2017; 72:7-17. <https://doi.org/10.1016/j.msec.2016.11.020> PMID:28024641
13. Chermont AB, Carneiro KK, Lobato MF, Machado SMM, Silva e Souza Junior MHS. Clinical evaluation of postoperative sensitivity using self-etching adhesives containing glutaraldehyde. *Braz. Oral Res.* 2010; 24(3):349-54. <https://doi.org/10.1590/S1806-83242010000300015> PMID:20877974
14. Stangel I, Barolet RY. Clinical evaluation of two posterior composite resins: two year results. *J. Oral Rehabil.* 1990; 17(3):257-68. <https://doi.org/10.1111/j.1365-2842.1990.tb00007.x>
15. Wendt SL, Leinfelder KF. Clinical evaluation of Clearfil photoposterior: 3-year results. *Am. J. Dent.* 1992; 5(3):121-5.
16. Gordan V V, Mjör IA. Short- and long-term clinical evaluation of post-operative sensitivity of a new resin-based restorative material and self-etching primer. *Oper. Dent.* 2002; 27(6):543-8.
17. Unemori M, Matsuya Y, Akashi A, Goto Y, Akamine A. Self-etching adhesives and postoperative sensitivity. *Am. J. Dent.* 2004; 17(3):191-5.
18. Reis A, Loguercio AD, Schroeder M, Luque-Martinez I, Masterson D, Maia LC. Does the adhesive strategy influence the post-operative sensitivity in adult patients with posterior resin composite restorations?: A systematic review and meta-analysis. *Dental Materials.* 2015; 31(9):1052-67. <https://doi.org/10.1016/j.dental.2015.06.001> PMID:26122377
19. Briso ALF, Mestrener SR, Delício G, Sundfeld RH, Bedran-Russo AK, de Alexandre RS. Clinical assessment of postoperative sensitivity in posterior composite restorations. *Oper. Dent.* 2007; 32(5):421-6. <https://doi.org/10.2341/06-141> PMID:17910217
20. Pashley DH, Matthews WG, Zhang Y, Johnson M. Fluid shifts across human dentine in vitro in response to hydrodynamic stimuli. *Arch. Oral Biol.* 1996; 41(11):1065-72.

[https://doi.org/10.1016/S0003-9969\(96\)00059-3](https://doi.org/10.1016/S0003-9969(96)00059-3)

21. Hebling J, Giro EM, Costa CA. Human pulp response after an adhesive system application in deep cavities. *J. Dent.* 1999; 27(8):557-64. [https://doi.org/10.1016/S0300-5712\(99\)00034-2](https://doi.org/10.1016/S0300-5712(99)00034-2)
22. Casselli DSM, Martins LRM. Postoperative sensitivity in Class I composite resin restorations in vivo. *J. Adhes. Dent.* 2006; 8(1):53-8.
23. Unemori M, Matsuya Y, Akashi a, Goto Y, Akamine a. Composite resin restoration and postoperative sensitivity: clinical follow-up in an undergraduate program. *J. Dent.* 2001; 29(1):7-13. [https://doi.org/10.1016/S0300-5712\(00\)00037-3](https://doi.org/10.1016/S0300-5712(00)00037-3)
24. Schenkel AB, Peltz I, Veitz-Keenan A. Dental cavity liners for Class I and Class II resin-based composite restorations. *Cochrane Database Syst. Rev.* 2016; 2016(10). <https://doi.org/10.1002/14651858.CD010526.pub2> PMID:27780315 PMCID:PMC6461160
25. Browning WD, Blalock JS, Callan RS, Brackett WW, Schull GF, Davenport MB. Postoperative sensitivity: a comparison of two

bonding agents. *Oper. Dent.* 2007; 32(2):112-7. <https://doi.org/10.2341/06-58> PMID:17427818

26. Wolfart S, Wegner SM, Kern M. Comparison of using calcium hydroxide or a dentine primer for reducing dentinal pain following crown preparation: a randomized clinical trial with an observation time up to 30 months. *J. Oral Rehabil.* 2004; 31(4):344-50. <https://doi.org/10.1046/j.1365-2842.2003.01238.x> PMID:15089940
27. Li L, Liu X, Herr K. Postoperative pain intensity assessment: a comparison of four scales in Chinese adults. *Pain Med.* 2007; 8(3):223-34. <https://doi.org/10.1111/j.1526-4637.2007.00296.x> PMID:17371409
28. Burrow MF, Banomyong D, Harnirattisai C, Messer HH. Effect of glass-ionomer cement lining on postoperative sensitivity in occlusal cavities restored with resin composite--a randomized clinical trial. *Oper. Dent.* 2009; 34(6):648-55. <https://doi.org/10.2341/08-098-C> PMID:19953773