

Journal section: Oral Medicine and Pathology  
 Publication Types: Review

doi:10.4317/jced.57981  
<https://doi.org/10.4317/jced.57981>

## COVID-19 and oral lesions, short communication and review

Sonia Egido-Moreno <sup>1</sup>, Joan Valls-Roca-Umbert <sup>2</sup>, Enric Jané-Salas <sup>3</sup>, José López-López <sup>4</sup>, Albert Estrugo-Devesa <sup>3</sup>

<sup>1</sup> DDS. Professor of Oral Pathology. Department of Odontostomatology. Faculty of Medicine and Health Sciences (Dentistry), University of Barcelona. University Campus of Bellvitge, Barcelona, Spain

<sup>2</sup> DDS, Professor of Master's degree, School of Dentistry, University of Barcelona. University Campus of Bellvitge, Barcelona, Spain

<sup>3</sup> PhD, DDS, MD. Professor of Oral Pathology. Department of Odontostomatology. Faculty of Medicine and Health Sciences (Dentistry), University of Barcelona. University Campus of Bellvitge, Barcelona, Spain / Oral Health and Masticatory System Group (Bellvitge Biomedical Research Institute) IDIBELL, University of Barcelona, L'Hospitalet de Llobregat, Barcelona, Spain

<sup>4</sup> DDS, MD, PhD, Department of Odontostomatology. Faculty of Medicine and Health Sciences (School of Dentistry), University of Barcelona. University Campus of Bellvitge, Barcelona, Spain. / Dental Hospital University of Barcelona, (Barcelona University) / Oral Health and Masticatory System Group (Bellvitge Biomedical Research Institute) IDIBELL, Barcelona, Spain

### Correspondence:

Facultad de Medicina y Ciencias de la Salud (Odontología)  
 Universidad de Barcelona  
 Campus Universitario de Bellvitge  
 Pabellón de Gobierno  
 C/ Feixa Llarga s/n 08907  
 L'Hospitalet de Llobregat Barcelona – España  
[18575jll@gmail.com](mailto:18575jll@gmail.com)

Received: 25/10/2020  
 Accepted: 28/11/2020

Egido-Moreno S, Valls-Roca-Umbert J, Jané-Salas E, López-López J, Estrugo-Devesa A. COVID-19 and oral lesions, short communication and review. J Clin Exp Dent. 2021;13(3):e287-94.

Article Number: 57981 <http://www.medicinaoral.com/odo/indice.htm>  
 © Medicina Oral S. L. C.I.F. B 96689336 - eISSN: 1989-5488  
 eMail: [jced@jced.es](mailto:jced@jced.es)

### Indexed in:

Pubmed  
 Pubmed Central® (PMC)  
 Scopus  
 DOI® System

### Abstract

**Background:** The COVID-19 disease first appeared in December 2019 in Wuhan, China. The World Health Organization (WHO) declared the pandemic in March 2020, with 40 million cases and a million deaths in October 2020. COVID-19 also includes manifestations on the skin and mucous mucosal membrane. **Objective:** To evaluate the prevalence of the oral lesions associated to COVID-19 disease; and evaluate their clinical presentation and the hypothesized etiology.

**Material and Methods:** An electronic literature search was performed in PubMed, Scopus and Índice Médico Español databases. The following combination of keywords and Boolean operators were used: “COVID-19 AND oral manifestations”; “COVID-19 AND oral lesions”; “COVID-19 AND mucosal lesions” ; “COVID-19 AND mucosal manifestations”; “SARS-COV-2 AND oral manifestations”; “SARS-COV-2 AND oral lesions”; “SARS-COV-2 AND mucosal lesions”; “SARS-COV-2 AND mucosal manifestations”. Furthermore, the bibliography was reviewed to manually include additional articles. The risk of bias in individual studies was assessed by two blinded reviewers using the Joanna Briggs Institute (JBI) and the evidence levels of the articles found will be cataloged according to the level of evidence and grade of recommendation of Oxford Centre for Evidence-Based Medicine (CEBM).

**Results:** 249 articles were found in the Medline / Pubmed database. There are no additional articles in the Scopus

and Índice Médico Español databases. We selected 14 articles plus 5 more articles due to manual searching. Patients presented a wide variety of oral manifestations. The most prevalent were lesions with a solution of continuity ( $n = 48, 73.85\%$ ) and the most frequent area was the tongue ( $n = 41, 52.56\%$ ). The preferred treatment for the lesions is a localized one by using rinses.

Conclusions: To conclude, after the bibliographic review was performed, we can expect that the COVID-19 disease can cause cutaneous and mucosal lesions as secondary manifestations. Despite more studies being needed to confirm this.

**Key words:** COVID-19, SARS-COV-2, oral lesions, oral manifestations.

## Introduction

The COVID-19 disease first appeared in December 2019 in Wuhan, China (1). The World Health Organization (WHO) declared the pandemic in March 2020, with confirmed cases in October 2020 that exceeded 40 million affected and more than 1 million deaths worldwide (2). The most common symptoms associated with this viral infection are: fever, cough, headache, diarrhea, fatigue, and myalgia (1,3).

COVID-19 also includes manifestations on the skin and mucous mucosal membranes (4). To date, few descriptions of the cutaneous manifestations of COVID-19 and few clinical images have been published due to safety reasons (4,5). Erythematous eruptions, generalized urticaria, or chickenpox-like vesicles are especially present (5). On the other hand, in April 2020 Martín Carreras-Presas *et al.* (6) published the first work on oral manifestations associated with the disease; since then different publications have referred to the subject. Given that the oral health of COVID-19 patients can be affected by infection, there are still doubts as to whether these manifestations could be a typical pattern resulting from direct viral infection, caused by systemic deterioration, considering the possibility of opportunistic infections, or adverse reactions to treatments (7).

The aim of this work is to evaluate the prevalence of oral lesions associated with COVID-19 disease; and assess the clinical presentation and its etiological hypothesis.

## Material and Methods

An electronic literature search was performed in PubMed, Scopus and Índice Médico Español databases.

Articles were selected by two blinded reviewers (SEM and JVR). Firstly, they reviewed titles and abstracts (phase-1). If papers were considered eligible for inclusion, a full-text reading was blindly performed by the same reviewers (phase-2). In case of disagreements, a third reviewer (AED) was involved to make the final decision and agreed upon with JLL. The reporting of these systematic review followed the Preferred Reporting Items for Systematic Review and Meta-Analyses (PRISMA) (8) guidelines for adequate conductance of systematic reviews.

The following combination of keywords and Boolean operators were used: “COVID-19 AND oral manifestations”; “COVID-19 AND oral lesions”; “COVID-19

AND mucosal lesions”; “COVID-19 AND mucosal manifestations”; “SARS-COV-2 AND oral manifestations”; “SARS-COV-2 AND oral lesions”; “SARS-COV-2 AND mucosal lesions”; “SARS-COV-2 AND mucosal manifestations”. Furthermore, the bibliography was reviewed to manually include additional articles.

The following inclusion criteria were applied: Studies that were only related with SARS-COV2; No language or publication date restrictions; Humans; Case series, case studies or letters to the editor.

The risk of bias in individual studies was assessed by two blinded reviewers using the Joana Briggs Institute (JBI) (9) critical appraisal checklist for case reports. The answers could be “yes”, “unclear”, “no”, or “not applicable”. Decisions about scoring were agreed upon by all reviewers before the critical appraisal commenced, and studies were characterized according to the following: (a) low risk of bias, if studies reached more than 70% scores of “yes”; (b) moderate risk of bias, if “yes” scores were between 50% and 69%; and (c) high risk of bias, if “yes” scores were below 49% (9). The evidence levels of the articles found will be cataloged according to the level of evidence and grade of recommendation of Oxford Centre for Evidence-Based Medicine (CEBM) (10) (Table 1).

## Results

Using our search strategy, 249 articles were found in the Medline / Pubmed database. There are no additional articles in the Scopus and Spanish Medical Index databases. Of the 249 articles initially found, 138 were excluded because they were duplicates. After reading the titles and abstracts, 80 were excluded because they did not meet the inclusion and exclusion criteria. Of these, the remaining 34 studies were read in full text and 17 articles were deleted because they were only comments of other articles (14), reviews (1) or the articles did not mention a relationship between oral lesions and COVID-19 disease (5). Finally, we included 14 articles for this synthesis and added 5 more studies by manual search (Fig. 1).

With regard to the risk of bias in the individual studies based on CEBM, most were letters to the editor (11-23) and case reports (6,7,24-27), therefore the level of evidence and the grade of recommendation is low. Despite the low evidence we included these articles due to the

**Table 1:** Study characteristics and risk of bias assessed by the Joanna Briggs Institute critical appraisal tool for case reports and, level of evidence and grade of recommendation of Oxford Centre for Evidence-Based Medicine (10).

Authors [Country]	Type of study	Joana Riggs Institute check list									Total (% scores “yes”) / Risk of bias	Oxford CEBM Level of evidence /grade of recommendation
		Q1	Q2	Q3	Q4	Q5	Q6	Q7	Q8			
Amorim dos Santos <i>et al.</i> (7) [Brazil]	CR	Y	Y	Y	Y	Y	Y	Y	NA	Y	100% / Low	4/C
Ansari <i>et al.</i> (11) [Iran]	LE	Y	N	Y	Y	Y	Y	Y	NA	Y	85% / Low	5/D
Brandao <i>et al.</i> (27) [Brazil]	CS	Y	Y	Y	Y	Y	Y	Y	NA	Y	100% / Low	4/C
Chaux-Bodard <i>et al.</i> (12) [France]	LE	N	N	Y	Y	NA	Y	NA	Y	Y	66% / Moderate	5/D
Cebeci <i>et al.</i> (13) [Turkey]	LE	Y	N	Y	Y	U	Y	Y	NA	Y	71% / Low	5/D
Ciccarese <i>et al.</i> (14) [Italy]	LE	N	Y	Y	Y	N	Y	Y	NA	Y	71% / Low	5/D
Corchuelo <i>et al.</i> (24) [Colombia]	CR	Y	Y	Y	Y	Y	Y	Y	NA	Y	100% / Low	4/C
Cruz-Tapia <i>et al.</i> (25) [Mexico]	CR	Y	Y	Y	N	N	N	NA	Y	Y	57% / Moderate	4/C
Díaz <i>et al.</i> (15) [Spain]	LE	Y	N	Y	Y	Y	Y	Y	NA	Y	57% / Moderate	5/D
Glavina <i>et al.</i> (16) [Croatia]	LE	Y	Y	Y	Y	Y	Y	Y	NA	Y	100% / Low	5/D
Jiménez-Cahué <i>et al.</i> (17) [Spain]	LE	N	Y	Y	Y	Y	Y	Y	NA	Y	85% / Low	5/D
Kitakawa <i>et al.</i> (26) [Brazil]	CR	Y	N	Y	Y	Y	Y	Y	NA	Y	71% / Low	4/C
Labé <i>et al.</i> (18) [France]	LE	N	Y	Y	N	Y	N	NA	Y	Y	57% / Moderate	5/D
Martín Carreras-Presas <i>et al.</i> (6) [Spain]	CR	N	Y	Y	N	Y	Y	Y	NA	Y	71% / Low	4/C
Patel <i>et al.</i> (19) [United Kingdom]	LE	Y	Y	Y	N	Y	Y	Y	NA	Y	85% / Low	5/D
Riad <i>et al.</i> (20) [Czech Republic]	LE	N	N	Y	Y	Y	Y	Y	NA	Y	71% / Low	5/D
Sakaida <i>et al.</i> (21) [Japan]	LE	N	Y	Y	Y	Y	Y	N	NA	Y	71% / Low	5/D
Soares <i>et al.</i> (22) [Brazil]	LE	Y	N	Y	Y	Y	Y	Y	NA	Y	85% / Low	5/D
Tomo <i>et al.</i> (23) [Brazil]	LE	Y	Y	Y	Y	Y	Y	Y	NA	Y	100% / Low	5/D

CR: Case report. LE: Letter to editor. Q1. Were patient’s demographic characteristics clearly described? Q2. Was the patient’s history clearly described and presented as a timeline? Q3. Was the current clinical condition of the patient on presentation clearly described? Q4. Were diagnostic tests or assessment methods and the results clearly described? Q5. Was the intervention(s) or treatment procedure(s) clearly described? Q6. Was the post-intervention clinical condition clearly described? Q7. Were adverse events (harms) or unanticipated events identified and described? Q8. Does the case report provide takeaway lessons?

Abbreviations: Y: Yes; N: No; NA: Not applicable, U: Unclear; CEBM: Centre for Evidence-Based Medicine

lack of available data until this time. The risk-of-bias in individual studies is also assessed with JBI critical appraisal checklist for case reports. Most were judged as low risk (6,7,11,13-17,19-24,26,27), and three as a moderate risk (12,18,25) (Table 1).

The characteristics of patients and lesions are summarized in Table 2, 2 cont. The total population included

was of 60 patients, comprised of 24 men (40%) and 36 women (60%). The medium age of the patients was of 41.26±19.05 years. PCR test was positive to SARS-COV-2 (confirming the diagnosis of COVID-19) in 55 patients (91.67%) and for 5 patients the diagnosis was probably because of the symptoms but a test was not performed to confirm this suspicion.

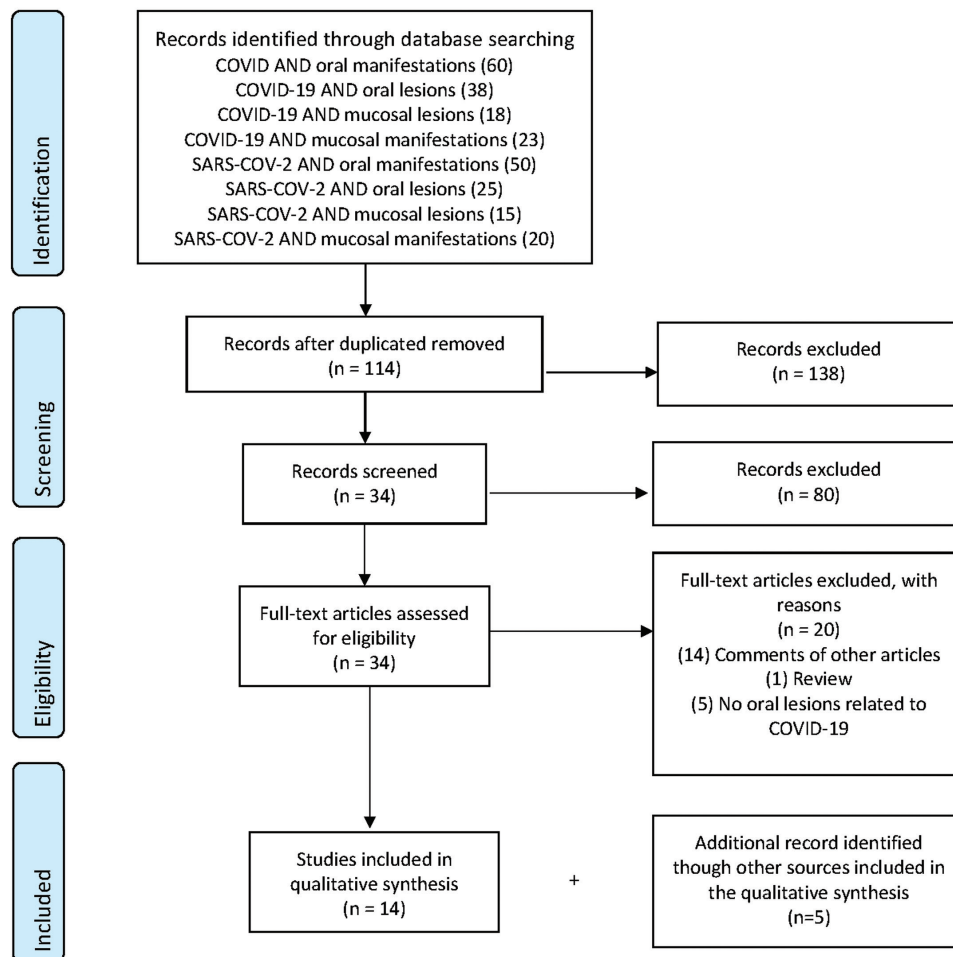


Fig. 1: Flow chart of search strategy in Pubmed.

Patients presented a wide variety of oral manifestations. The most prevalent were lesions with a solution of continuity (n = 48, 73.85%) such as ulcers, aphtous-like lesions or erosions (n = 36, 55.38%; n = 8, 12.31%; n = 4, 6.15% respectively), followed by macules (n = 4, 6.15%) and petechiae (n = 3, 4.61%), plaques (n = 3; 4.61%), bullae (n = 2, 3.08%); gingival abnormalities, such as desquamative and necrotizing gingivitis (n = 1, 1.54% both) and finally blisters and pustules (n = 1, 1.54% both).

The most frequent location was on the tongue (n = 41, 52.56%), followed by the palate and lip (n = 13, 16.67%), gingiva (n = 6, 7.69%), jugal mucosa (n = 3, 3.85%) and finally the commissure (n = 2, 2.56%).

Regarding probable etiologies, authors seem to agree that the lesions are due to rashes directly associated with COVID-19 and the compromised state of the patients due to immunosuppression and stress. It has also been related to thrombotic alterations produced by the virus itself, without ruling out the eruptions associated with drugs for the treatment of COVID-(19).

The preferred treatment for the lesions is a localized one by using rinses. The rinses were based on antifungals (nystatin and fluconazole) (7,16,24), antibiotics (tetracycline, neomycin (11,13,26), ampicillin, sulbactam and clarithromycin (21), metronidazole (19)), antivirals (valacyclovir, acyclovir) (6,27), anesthetics (lidocaine) (11,16), topical corticosteroids (dexamethasone, triamcinolone, mometasone furoate) (11,15,25), chlorhexidine (7,6,15,19,10,23,24,25,27), 1% hydrogen peroxide, (7) and hyaluronic acid (6), also authors performed daily photobiomodulation (PBTM) therapy (27). In some cases, they were treated with systemic medications such as corticosteroids (6,17,21), antifungals (acyclovir) (16) or analgesics (paracetamol) (20).

### Discussion

This study is carried out to review the new information that is emerging on oral lesions related to the COVID-19 disease. Being an emerging disease and becoming a global pandemic, there are constant changes and new information published/discovered about it. Chauv-Bodard *et*

**Table 2:** Characteristics of the patients and lesions.

Author	n Sex mean age [Dx]	Oral manifestations (n of cases)	Treatment of oral manifestations [Histology]	Onset [Resolution] *mean days (n of cases)	Probable cause
Amorim Dos Santos <i>et al.</i> (7)	1M 67 [+]	White plaque on the tongue dorsum and multiple pinpoint yellowish ulcers in the tongue dorsum resembling the late stage of herpetic recurrent oral lesions	Fluconazol, nystatin, clorhexidine 0.12%, hydrogen peroxide 1%, and oral health care. [Culture by scraping tongue compatible with <i>Saccharomyces cerevisiae</i> ]	24 days from onset of symptoms [17 days]	Secondary lesions resulting from deterioration of systemic health or due to treatments for COVID-19.
Ansari <i>et al.</i> (11)	1M, 1F 65.5 [+]	Several painful ulcers with irregular margins and varying sizes in red and nonhemorrhagic background. hard palate (1), tongue (1).	Difenhidramine, dexametasone, tetraciline and lidocaine. [Hard palate biopsy: Tissue diffuses edema with mucosal desquamation, along with granulation and ulceration under the mucosa with invasion of mononuclear cells with large and glassy nuclei. Neutrophilic cell invasion was also seen following secondary bacterial infection]	Case 1: 5 days after the onset symptoms. Case 2: 1 week after hospitalization [7 days]	Stress-related SARS-COV-2 viral rash.
Brandão <i>et al.</i> (27)	5M, 3F 53.88 [+]	Aptous-like lesions and necrosis (3) Hemorrhagic ulcerations with necrotic areas (1) Aptous-like lesions (4) Localization: upper and lower lip mucosa (4), tongue (5), hard palate (1)	Acyclovir, PBTM, chlorhexidine 0.12%. [NA]	6 days after COVID-19 confirmation [7.75 days]	Directly associated with COVID-19 infection and severe compromised state of the patient.
Cebeci Kahraman <i>et al.</i> (12)	1M 51 [+]	Largery erythematous surface, few petechiae, and pustular enanthema in palate	Antibiotic therapy. [NA]	10 days after the onset symptoms [after a few days of therapy]	SARS-COV-2 viral rash
Ciccarese <i>et al.</i> (14)	1F 19 [+]	Erosions, ulcerations and blood crusts on the inner surface of the lips and palatal and gingival petechiae	Palliative. [NA]	5 days after fever and sore throat, and 3 days after consult [5 days]	Vascular disorder (thrombocytopenia) associated with COVID-19
Chaux-Bodard <i>et al.</i> (24)	1F 45 [+]	Irregular ulcer in dorsum of tongue	NA [NA]	Initial symptom 8 days before COVID-19 diagnosis [10 days]	Vascular inflammatory reaction due to COVID-19 disease
Corchuelo <i>et al.</i> (24)	1F 40 [+]	Reddish plaques on the lower lip, whitish area on the back of the tongue, apparently accompanied by bacterial plaque in the tongue, trush lesions at the level of the attached gingiva, and well-defined brown band in the attached gingiva	Nystatin oral suspension, rinses with clorhexidina 0.12%. [NA]	3 days after COVID-19 confirmation [20 days]	Inflammatory process in response SARS-COV-2
Cruz-Tapia <i>et al.</i> (25)	1M, 3F 47 [+]	(2) nonbleeding bulla diagnosed as angina bullosa hemorrhagic-like lesion in the hard palate and the tongue (1) Diffuse vascular-like purple macule (1) Multiple and irregular reddish macules Hard palate (4), tongue (1)	Self-control measures Clorhexidine 0.12%, momethasone furoate 0.1% mouthwash. [Case purple macules: squamous parakeratinized stratified epithelium with paranuclear and cytoplasmic vacuolization in the spinous layer, hemorrhage and vascular congestion with focal thrombi formation in the stroma with erythrocyte extravasation and chronic inflammation cells]	(1) 8 days after COVID-19 confirmation (1) 7 days after treatment (2) NA [(2) NA, (2) 9.5 days]	Vascular disorder associated with COVID-19
Díaz <i>et al.</i> (15)	1M, 2F 57 [+]	1) Aptous-like lesions and burning sensation (2) Burning mouth sensation and lateral commissural fissures (3) Lesions on the tongue, palate and commissure compatible with pseudomembranous candidiasis and angular cheilitis.	Rinses with a solution containing triamcinolone acetone 0.05%, chlorhexidine 0.12%, nystatine and neomycin. [NA]	Unclear [(1) after treatment (2) 12.5 days]	State of immunosuppression and stress.
Glavina <i>et al.</i> (16)	1F 40 [+]	Pain and burning in the oral cavity. Recurrent HSV of the hard palate, white hairy tongue	Systemic acyclovir therapy and local therapy (antiseptic, nystatin, panthenol and local anesthetic)	7 days after COVID-19 confirmation	Recurrent HSV triggered by SARS-COV-2.

**Table 2 cont.:** Characteristics of the patients and lesions.

		and non-specific white lesions of the ventral side of the tongue.	[NA]	[14 days]	Secondary manifestation of the host's compromised immune system and stress-induced.
Jimenez-Cahué <i>et al.</i> (17)	1F 58 [+]	Macules and petechiae on the palate	Corticoesteroides sistémicos. [ Cutaneous biopsy: normal basket-weave stratum corneum, and mild to moderate spongiosis in epidermis. The dermis showed dilated vessels filled with neutrophils, extravasation of red blood cells, and lymphocytic perivascular and interstitial infiltrate]	24 days after the onset of COVID-19 symptoms [2-3 weeks]	Infectious rash associated with COVID-19
Kitakawa <i>et al.</i> (26)	1F 20 [+]	Herpetic lesions in the median lower lip semimucosa and pruritus	Nebacetin ointment. [NA]	NA [14 days]	NA
Labé <i>et al.</i> (18)	2M 4.5 [(1) +, (1) P]	Severe erosive cheilitis and gingival erosions.	NA [NA]	2 weeks after the anosmia onset [2 weeks]	COVID-19 associated with erythema multiforme (negative test for HSV and Mycoplasma pneumoniae)
Martín Carreras-Presas <i>et al.</i> (6)	2M, 1F 59.67 [(2) P, (1) +]	(2) Painful herpetic-like ulcers in hard palate (1) Blisters in the lower lip mucosa and descamative gingivitis	Valaciclovir, chlorhexidine 0.12 and hyaluronic mouthwash and, systemic prednisone. [ Cutaneous biopsy: non-specific morphological findings with some criteria suggestive of viral exanthema or urticariform dermatitis with discrete blood extravasation]	(1) First symptom, (2) 30 days after (2) 30 days after 1st symptom [3 days]	Viral exanthema due to SARS-COV-2
Patel <i>et al.</i> (19)	1F 35 [P]	Erythematous and edematous gingivae, and necrotic interdental papillae.	Metronidazole, 0.12% chlorhexidine mouthwash. [NA]	3 days after fever [5 dias]	Bacterial infection
Riad <i>et al.</i> (20)	9M, 17F 36.8 [+]	Tongue ulcers	Oral paracetamol, and chlorhexidine mouthwash. [NA]	3.9 days after COVID-19 confirmation [8.3 days]	Direct manifestation of SARS-COV-2 or co-infection due to the immune dysregulation
Sakaïda <i>et al.</i> (21)	1F 52 [+]	Erythematous and erosive lesions on the lips and oral mucosa.	Prednisolone, ampicilin/sulbactam and claritromicine. [ Cutaneous biopsy: slight liquefaction with perivascular and periadnexal mixed cell infiltrations from the papillary dermis to the deep subcutaneous tissue]	10 days after COVID-19 confirmation y 2 days after the administration of medication for tooth problems [NA]	Drug-associated rash
Soares <i>et al.</i> (22)	1M 42 [+]	Painful ulcer in the buccal mucosa with ischemic aspect, and multiple reddish macules of different sizes scattered along the hard palate, tongue, and lips.	Preservation. [Diffuse chronic inflammatory infiltrate with focal areas of necrosis and hemorrhage in the lamina propria. Intense lymphocytic infiltration in adjacent minor salivary glands. Negative IHC reactions against HHV-1, HHV-2, CMV, treponema pallidum, and EBV]	NA [21 days]	Thrombotic disorders due to COVID-19
Tomo <i>et al.</i> (23)	1F 37 [+]	Oral mucositis characterized by painful diffuse bilateral erythema and depapilation in the borders of tongue and dry mouth	Chlorhexidine 0.12% mouthwash. [NA]	9 days after symptoms onset [14 days]	Oral mucositis due to a mucosal hypersensitivity to the presence of the SARS-COV-2

F: Female; M: Male; +: Positive, NA: Not applicable; PBTM: Photobiomodulation; EM: Erythema multiforme; P: Possible; n: number; Dx: Diagnostic number of cases diagnostic; NA: Not Applicable.



*al.* (12) described the first lesion associated with SARS-COV-2. Given the worldwide spread of the disease, the paucity of reports on oral manifestations suggests that oral lesions are rare in these patients (23). It is important to highlight the difference with SARS-COV-1 in which no associated oral lesions appear in the literature.

Regarding the etiology of the lesions, various hypotheses have been proposed. It has been discussed whether the lesions may be typical of COVID-19 or that COVID-19 is the promoter of the development of these oral manifestations. It now seems clear that coronavirus damage to respiratory organs and other organs could be related to the distribution of angiotensin converting enzyme 2 (ACE2) receptors. Therefore, cells that present the ACE2 receptor can become host cells for the virus and cause inflammatory reactions in oral organs and tissues (28,29,30). The recently published tropism of SARS-COV-2 to the tongue and salivary gland epithelium (31) suggest that the oral mucous membrane may be targeted by the virus. This leads to speculate that the development of oral manifestations may be directly associated with the COVID-19 infection (27).

In contrast, authors state that there is insufficient evidence to support an oral damage caused by SARS-COV-2 (23). Acute COVID-19 infection, together with associated therapeutic measures, could contribute to triggering alterations in the oral mucosa, which could probably cause various opportunistic fungal infections, recurrent oral herpes simplex virus infection, nonspecific oral ulcerations, dysgeusia, drug-associated eruptions, xerostomia related to decreased salivary flow, ulcers, and gingivitis. Also, most patients presented oral mucosal injury during the hospitalization period, supporting the hypothesis of coinfections, immunity impairment, or adverse reactions from medications to COVID-19 treatments (28).

On the other hand, it has been suggested that, among the probable causes of oral lesions, that they could be secondary to the deterioration of the immune system or due to disease treatments (28,17,21,32). The drug eruption can develop during the latency period. Drug hypersensitivity and urticaria have been reported by several patients and may not only be accidental, but may be related to the COVID-19-induced cytokine storm (21).

The immune status of the patient also influences the appearance of lesions. The signs and symptoms that some patients present (compatible with infections) can lead the patient to an immunosuppressed state that can trigger a reactivation of the Herpes simplex virus (32) or Varicella-Zoster virus (33).

Moreover, a concomitant bacterial superinfection may also occur (19,30) or the lesions may arise from an inflammatory reaction that induces vascular inflammation (30). In addition, injuries have been proposed to be a manifestation of the stress associated with the pandemic (11,29,32,33). The complications of the COVID-19 di-

sease, the possibility of losing a friend or family member, the damage to economic conditions (32), work pressure and confinement increase stressful situations among patients (29). Therefore, the mental state of the patient should also be considered (32).

Regarding oral lesions, gingival alterations have occurred, such as desquamative (6) or necrotizing (19) gingivitis. Authors like Brandan *et al.* (34) hypothesized that periodontal pocket could be a favorable anatomical niche for the virus and thus acting as a reservoir for SARS-CoV-2. They justified this hypothesis, since periodontal pockets are ideal environments for subgingival bacterial biofilms, that interact with the supragingival oral cavity, mucosal tissues of the pocket and a peripheral circulatory system. Periodontal pockets have been found to harbor viral species such as the Herpes simplex viruses' family; so, the same could happen with SARS-COV-2 (34).

Concerning the beginning of the oral manifestations, it varied considerably between the cases due to the lack of reference points. Days of laboratory testing, drug administration, hospital admission, hospital discharge, and respiratory and systemic manifestations were used as reference time points to describe the onset of oral symptoms. Although no case presented oral lesions prior to respiratory symptoms; although biases in data collection can be attributed (30).

The truth is that the SARS-COV-2 virus can cause oral lesions, which its incidence has probably been underestimated given the situation (27). Based on this, patients diagnosed with COVID-19 should undergo an oral inspection (16, 22) in order to understand the pathobiology of these alterations (22). It is important that the new signs and symptoms are known, so that as we clinicians can report cases of COVID-19 (33). Dentists should be part of the multidisciplinary team for the diagnosis and treatment of these patients; as well as, on some occasions, being the first to identify the disease (28,29); as well as given the need for support, pain control, and quality of life (28).

This review has several limitations. First, the articles that relate oral lesions associated with COVID-19 disease are limited and also of low methodological quality. On the other hand, at the beginning of the pandemic, diagnostic tests were limited, so that some of the cases that are exposed are only suspected of infection by SARS-COV-2, based on the symptoms that the patients presented (6,18,25). Therefore, some lesions and symptoms could correspond to other frequent viral diseases (6,32). Another limitation is the difficulty for oral examination of patients, even some patients were visited indirectly (through photos or videoconferences) due to the high risk of contagion and the lack of protective equipment at the beginning of the pandemic. Furthermore, clinical imaging was not performed adequately due to the risk of contamination of photographic equipment (5,28). It is also worth noting that due to the severity of the disease,

such an assessment becomes difficult for clinicians and, often without painful symptoms, patients end up reporting no injuries to the mouth (6,33).

## Conclusions

In conclusion, after conducting the literature review, it can be expected that the COVID-19 disease causes skin and mucosal lesions, probably as secondary manifestations. Although, more research of these clinical manifestations is needed to help us understand the disease.

## References

- Phelan AL, Katz R, Gostin LO. The novel coronavirus originating in Wuhan, China: challenges for global health governance. *JAMA*. 2020;323:709-10.
- OMS. Coronavirus disease (COVID-19). Accessed 17-10-20: <https://www.who.int>
- Tang K, Wang Y, Zhang H, Zheng Q, Fang R, Sun Q. Cutaneous manifestations of the coronavirus disease 2019 (COVID-19): A brief review. *Dermatol Ther*. 2020;7:e13528.
- Galván Casas C, Català A, Carretero Hernández G, Rodríguez-Jiménez P, Fernández Nieto D, Rodríguez-Villa Lario A, et al. Classification of the cutaneous manifestations of COVID-19: a rapid prospective nationwide consensus study in Spain with 375 cases. *Br J Dermatol*. 2020;183:71-77.
- Recalcati S. Cutaneous manifestations in COVID-19: a first perspective. *J Eur Acad Dermatol Venereol*. 2020;34:e212-3.
- Martín Carreras-Presas C, Amaro Sánchez J, López Sánchez AF, Jané Salas E, Somacarrera Pérez ML. Oral vesiculobullous lesions associated with SARS-CoV-2 infection. Oral vesiculobullous lesions associated with SARS-CoV-2 infection. *Oral Dis*. 2020 May 5;10.1111/odi.13382. Online ahead of print.
- Amorim dos Santos J, Normando AGC, Silva RLCD, de Paula RM, Cembranel AC, Santos-Silva AR, et al. Oral mucosa lesions in a Covid-19 patient: new signs or secondary manifestations? *Int J Infect Dis*. 2020;97:326-8.
- Moher D, Liberati A, Tetzlaff J, Altman DG, PRISMA Group. Preferred Reporting Items for Systematic Reviews and Meta-Analyses: The PRISMA Statement. *PLoS Med*. 2009;6:e1000097.
- The University of ADELAIDE. Joanna Briggs Institute. JBI critical appraisal checklist for case reports. Adelaide, SA: The Joanna Briggs Institute; 2016. Accessed 10-10-20: <https://joannabriggs.org/critical-appraisal-tools>.
- Oxford Centre for Evidence-based Medicine (2009). Oxford Centre for Evidence-based Medicine - Levels of Evidence. Accessed 6-9-20. Retrieved from <https://www.cebm.net/2009/06/oxford-centre-evidence-based-medicine-levels-evidence-march-2009/>
- Ansari R, Gheitani M, Heidari F, Heidari F. Oral cavity lesions as a manifestation of the novel virus (COVID-19). *Oral Dis*. 2020 Jun 8. Online ahead of print.
- Chaux-Bodard AG, Deneuve S, Desoutter A. Oral manifestation of Covid-19 as an inaugural symptom? *J Oral Med Oral Surg* 2020;26:10.
- Cebeci Kahraman F, Çaçkurlu H. Mucosal involvement in a COVID-19-positive patient: a case report. *Dermatol Ther*. 2020;33:e13797.
- Ciccarese G, Drago F, Boatti M, Porro A, Muzic SI, Parodi A. Oral erosions and petechiae during SARS-CoV-2 infection. *J Med Virol*. 2021;93:129-132.
- Díaz Rodríguez M, Jiménez Romera A, Villarroel M. Oral manifestations associated with COVID-19. *Oral Dis*. 2020 Jul 22;10.1111/odi.13555. Online ahead of print.
- Glavina A, Biočina-Lukenda D, Mravak-Stipetić M, Markeljević J. Oral symptoms and lesions in SARS-CoV-2-positive patient. *Oral Dis*. 2020 Aug 9;10.1111/odi.13596. Online ahead of print.
- Jiménez-Cahué J, Ortega-Quijano D, Carretero-Barrio I, Suárez-Valle A, Saceda-Corralo D, Moreno-García del Real C, et al. Erythema multiforme-like eruption in patients with COVID-19 infection: clinical and histological findings. *Clin Exp Dermatol*. 2020;45:892-895.
- Labé P, Ly A, Sin C, Nasser M, Chapelon-Fromont E, Ben Said P, Mahé E. Erythema multiforme and Kawasaki disease associated with COVID-19 infection in children. *Dermatol Venereol*. 2020;34:e539-41.
- Patel J, Woolley J. Necrotizing periodontal disease: Oral manifestation of COVID-19. *Oral Dis*. 2020 Jun 7;10.1111/odi.13462. Online ahead of print.
- Riad A, Kassem I, Hockova B, Barah M, Klugar M. Tongue ulcers associated with SARS-CoV-2 infection: A case series. *Oral Dis*. 2020 Sep 5. Online ahead of print.
- Sakaida T, Tanimoto I, Mtsubara A, Nakamura M, Morita A. Unique skin manifestations of COVID-19: Is drug eruption specific to COVID-19? *J Dermatol Sci*. 2020;99:62-4.
- Soares CD, Carvalho RA, Carvalho KA, Carvalho MG, Almeida OP. Letter to Editor: Oral lesions in a patient with Covid-19. *Med Oral Patol Oral Cir Bucal*. 2020;25:e563-4.
- Tomo S, Miyahara GI, Simonato LE. Oral mucositis in a SARS-CoV-2-infected patient: Secondary or truly associated condition? *Oral Dis*. 2020 Jul 29. Online ahead of print.
- Corchuelo J, Ulloa FC. Oral manifestations in a patient with a history of asymptomatic COVID-19: Case report. *Int J Infect Dis*. 2020;100:154-7.
- Cruz Tapia RO, Peraza Labrado AJ, Guimaraes DM, Matos Valdez LH. Oral mucosal lesions in patients with SARS-CoV-2 infection. Report of four cases. Are they a true sign of COVID-19 disease? *Spec Care Dentist*. 2020;40:555-560.
- Kitakawa D, Oliveira FE, Neves de Castro P, Carvalho LFCS. Short report - Herpes simplex lesion in the lip semimucosa in a COVID-19 patient. *Eur Rev Med Pharmac Sci*. 2020;24:9151-3.
- Brandão TB, Gueiros LA, Melo TS, Prado-Ribeiro AC, Nesrallah ACFA, Prado GVB, et al. Oral lesions in patients with SARS-CoV-2 infection: could the oral cavity be a target organ?. *Oral Surg Oral Med Oral Pathol Oral Radiol*. 2021;131:e45-e51.
- Amorim dos Santos J, Normando AGC, Carvalho da Silva RL, Acevedo AC, de Luca Canto G, Sugaya N, et al. Oral Manifestations in Patients with COVID-19: A Living Systematic Review. *J Dent Res*. 2021;100:141-154.
- Petrescu N, Lucaciu O, Roman A. Oral mucosa lesions in COVID-19. *Oral Dis*. 2020 Jun 19;10.1111/odi.13499. Online ahead of print.
- Riad A, Klugar M, Krsek M. COVID-19 Related Oral Manifestations, Early Disease Features? *Oral Dis*. 2020 Jun 30;10.1111/odi.13516. Online ahead of print.
- Xu H, Zhong L, Deng J, Peng J, Dan H, Zeng X, Li T, Chen Q. High expression of ACE2 receptor of 2019-n-Cov on the epithelial cells of oral mucosa. *Int J Oral Sci*. 2020;12:8.
- Burgos Ponce J, Trijoe KC. Overlapping findings or oral manifestations in new SARS-CoV-2 infection. *Oral Dis*. 2020 Jun 10;10.1111/odi.13478. Online ahead of print.
- de Carvalho LFDCEs, Kitakawa D, Cabral LAG. Oral lesions of herpes zoster in COVID-19 patients or truly associated to the disease? *Oral Dis*. 2020 Jun 10;10.1111/odi.13472. Online ahead of print.
- Bradán Z, Gaudin A, Struillou X, Amador G, Sueidan A. Periodontal pockets: A potential reservoir for SARS-CoV-2? *Med Hypotheses*. 2020;143:109907.

### Source of funding

The authors received no funding.

### Authors' contributions

Sonia Egidio Moreno (SEM): selected the articles.  
Joan Valls Roca-Umbert (JVR): selected the articles.  
Albert Estrugo Devesa (AED): final decision in case of disagreements.  
José López López (JLL): final decision in case of disagreements.

### Conflict of interest

The authors declare no conflict of interest.