

---

## **Gastric and colonic metastasis from cancer cervix: An unusual progression with an uncommon cause of mortality**

**DOI:** 10.4103/2278-330X.149959

Dear Editor,

Stomach is an unusual site for metastasis. Information on duodenal metastasis is generally limited to single case reports. Gastric lesions are identified in less than 2% of patients with cancer of cervix and are usually asymptomatic.<sup>[1]</sup> Melanoma, lung, breast and esophagus are the common primary metastatic sites.<sup>[2]</sup> Symptoms of metastatic tumors include pain, vomiting and bleeding but are nonspecific. Cervical cancer is known for its local infiltration and the sequelae of local involvement constitute the common causes of mortality such as ureteral stricture, uremia secondary to obstruction, urosepsis and local bleeding. Distant metastasis from cancer cervix is very rare and limited to isolated case reports with cancer cachexia and

metastasis constituting an uncommon cause of death. This case attempts to highlight an unusual cause of mortality from cervical cancer with gastric bleeding secondary to an unusual progression of disease.

This is a case report of 48-year-old female patient who was diagnosed to have squamous cell cancer of the cervix and underwent panhysterectomy 8 years back for the same. The histology of the specimen reported well differentiated squamous cell cancer of the ectocervix, pathological stage I with clear margins [Figure 1]. She received no adjuvant treatment. 6 years post-surgery she presented with features of sub-acute intestinal obstruction. On examination, a lump was palpable in the left iliac fossa. Computed tomography (CT) revealed thick irregular bowel thickening at the junction of sigmoid and descending colon leading to marked luminal narrowing with stranding into the adjacent omental and mesenteric fat. Colonoscopy revealed a friable constricting growth extending into the mesentery of the sigmoid colon

at 40 cm from anal verge [Figure 2]. Biopsy was suggestive of dysplastic squamous epithelial cells infiltrating into the lamina propria with the presence of nests of cells within the lymphatics suggesting a metastatic lesion. Her serum carcinoembryonic antigen was normal. She underwent segmental resection for the same with colo-colic anastomosis and final histopathology showed an infiltrating growth composed of anastomosing trabeculae and cords of atypical squamous cells infiltrating from the serosa to the colonic wall and extending at places up to lining epithelium with keratin pearl formation in the serosal nests with surrounding dysplastic reaction suggestive of squamous cell carcinoma (SCC) [Figure 3]. She was administered 6 cycles of cisplatin and 5-fluorouracil (5 FU) after surgery. She remained asymptomatic for 2 years. After 2 years of follow-up, she developed a lesion in the lesser sac with involvement of pancreatic tail and multiple splenic metastases. She was given 6 cycles of cisplatin, paclitaxel and 5 FU following which, her lesser sac mass and splenic metastasis decreased in size by almost 70%. She then presented with complaints of vomiting, hematemesis and epigastric pain. Endoscopy showed a gastric mass involving the fundus and body. CT scan showed a mass involving the fundus of stomach with minimal extension outside the gastric wall. The lesser sac mass had almost completely resolved [Figure 4]. Biopsy tissue retrieved by endoscopy showed tissue infiltrated by sheets and clusters of tumor cells which were round to oval with high nucleo-cytoplasmic ratio, pleomorphic nuclei, vesicular

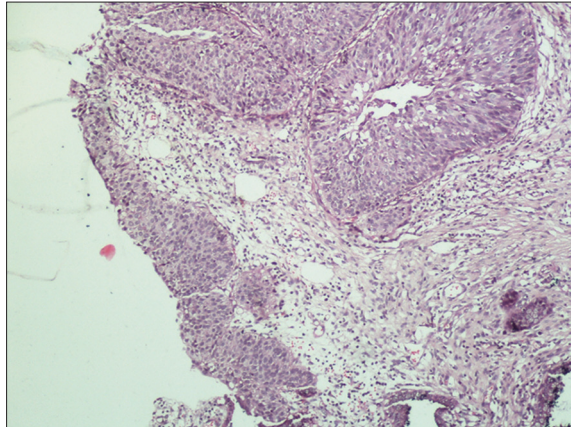


Figure 1: Hysterectomy specimen showing squamous cell carcinoma in the cervix (H and E, x400)

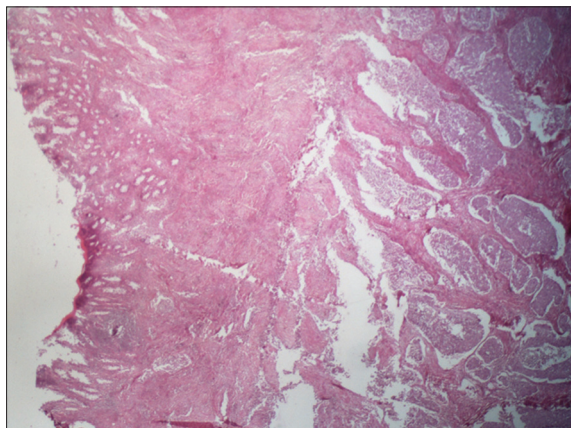


Figure 3: Colectomy specimen showing metastatic squamous cell carcinoma in lamina propria (H and E, x400)

chromatin and prominent nucleoli with no keratin. Tissue tested positive for epithelial membrane antigen, cytokeratin 7 (CK), CK5/6 and negative for CK20, which was consistent with tumor origin from cervix. The basaloid appearance and nuclear morphology suggest SCC. Patient developed massive gastric bleeding episodes and was planned for embolization and palliative surgery but succumbed to her illness before surgery.

Primary squamous cell cancer of the stomach is a rare entity (fewer than 100 cases of primary SCC of the stomach have been reported in the literature) and whenever it occurs is usually the result of metastasis from a different primary. The primary sites generally include esophagus, skin, lung, cervix, breast, sigmoid colon and testis.<sup>[3]</sup> They usually present as solitary lesions and are mainly located in the middle (40%) and upper third (40%) of the stomach.<sup>[4]</sup> The clinical presentation of gastric metastases mimics the primary gastric tumor, as symptoms can be nonspecific and include dysphagia, dyspepsia, anorexia, abdominal pain, early satiety, nausea, vomiting, bleeding and anemia. The radiological and endoscopic findings can also be similar to those of primary gastrointestinal tumor. The discovery of gastric tumor in a patient with a history of cervical cancer is more likely to be a primary gastric lesion, but metastasis from cervical cancer may be possible and must be ruled out. Cervical cancer metastasizing to the stomach is a rare event with probably none reported in the literature although duodenal metastasis has been reported.<sup>[1]</sup> Most common sites of distant metastasis from cervical cancer are lung, liver and supraclavicular lymph nodes and unusually to brain, heart, skin, thyroid, spleen. Carcinoma of the cervix usually spreads in an orderly

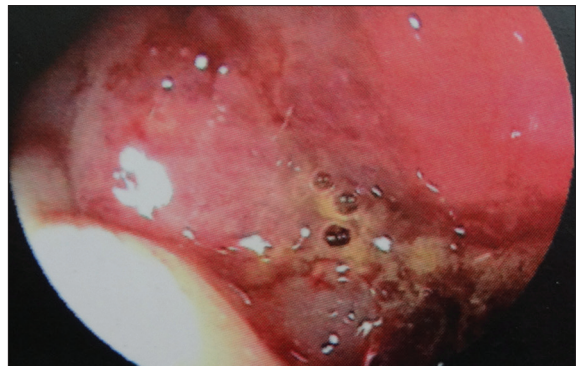

Figure 2: Colonoscopy image showing ulceration in the sigmoid colon

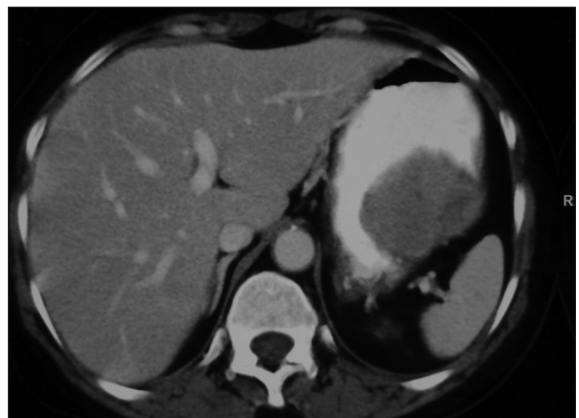

Figure 4: Contrast-enhanced computed tomography scan showing gastric mass with minimal extension into lesser sac

and predictable fashion.<sup>[5]</sup> The earliest and most common metastases are by direct extension to the contiguous structures including the vagina, peritoneum, urinary bladder, ureters, rectum and paracervical tissue;<sup>[5]</sup> however, distant metastatic spread with unusual patterns such as pulmonary lymphangitic carcinomatosis have also been reported.<sup>[6]</sup> Up to 50% of stage IV patients can present with distant metastases.<sup>[6]</sup> Common sites of such occurrences are the liver, lungs and bone marrow. The GI tract is involved in approximately 8% of patients with carcinoma of the cervix; these being commonly found in the recto sigmoid as a result of local extension.<sup>[1]</sup> Gastric lesions are identified in less than 2% of patients with carcinoma of the cervix and are usually asymptomatic.<sup>[1]</sup> To confirm gastric metastasis from cancer cervix, one should get a full metastatic work-up, which includes upper gastrointestinal endoscopy with biopsy and immunohistochemical (IHC) analysis, positron emission tomographic and contrast-enhanced computed tomography fusion scan to look for other sites of metastasis. Contrast-enhanced computed tomography and barium examination can be done to support the diagnosis. Endoscopic, radiological and histological evaluation is essential to discriminate primary gastric cancer from other primary cancers metastasizing to the stomach. Radiological and endoscopic findings are non-specific and may be hard to distinguish from primary gastric cancer. The common patterns of metastasis to the stomach are linitis plastica, discrete nodules or external compression. As the lesion is often limited to the sub mucosal and sero-muscular layers of the stomach, the endoscopic evaluation may be normal in 50% of cases or may show only discrete mucosal abnormalities indistinguishable from other tumors or benign disease. Radiological findings on CT scan or barium meal may include encasement of the whole stomach, multiple lesions of the stomach or extrinsic lesions of the gastric wall. Deep biopsies are needed to obtain representative material and the histological features should be compared with those of the primary tumor in order to confirm the diagnosis. Detailed IHC analysis may be the only reliable method to differentiate between metastatic and primary gastric carcinoma. Metastatic cervical carcinoma is usually positive for CK7, epithelial membrane antigen, CK5/6 and negative for CK20. The basaloid appearance and nuclear morphology also help in locating the primary. Furthermore, the original biopsy from the primary site should be reviewed and compared with the metastatic site to confirm the histomorphological similarity of the neoplastic cells.<sup>[7]</sup> Usually gastric metastasis are treated with palliative intent, i.e., for gastric outlet obstruction gastrojejunostomy, for nutritional support feeding jejunostomy, for bleeding palliative radiotherapy and/or embolization or palliative gastrectomy if not controlled by simple measures, pain relief by analgesics

and/or celiac block. Other supportive medicines can be given to relieve the symptoms. Gut metastasis from cervical cancer is extremely rare and such spread is believed to occur commonly through the lymphatics usually the para-aortic or mesenteric nodes to the bowel serosa and less often via the blood stream or by peritoneal seeding.<sup>[8]</sup> The involvement of transverse mesocolon as in our case, extended locally to involve the lesser sac through which it has possibly spread into the gastric wall. In addition, stomach has a rich vascularity which may predispose it to hematological metastasis. As this patient also had splenic metastasis, possibility of both local extension and hematological spread can be taken into account. This paucity of neoplasms metastasizing to the bowel is due to the innate local micro environmental protection in the small intestine, which includes motility and rapid transit, local immune factors and intraluminal microbial ecosystem.<sup>[7]</sup>

We want to highlight an unusual progression of cervical cancer and gastric bleeding secondary to gastric metastasis as an unusual cause of mortality from this disease and one should keep in mind that such progression may occur with the advent of more effective chemotherapeutic regimes and longer survival.

**Ashish Singhal<sup>1</sup>, Shakeel Masood<sup>2</sup>, Charu Mahajan<sup>1</sup>, Rahat Hadi<sup>3</sup>, Shalini Bhalla<sup>4</sup>**

Departments of <sup>1</sup>Surgical Oncology, <sup>2</sup>Surgical Gastroenterology, and <sup>3</sup>Radiation Oncology, Dr. Ram Manohar Lohia Institute of Medical Sciences,

<sup>4</sup>Department of Pathology, Sahara Hospital, Lucknow, Uttar Pradesh, India

**Correspondence to:** Dr. Ashish Singhal,  
E-mail: ashishpgi@yahoo.co.in

## References

1. Gurian L, Ireland K, Petty W, Katon R. Carcinoma of the cervix involving the duodenum: Case report and review of the literature. *J Clin Gastroenterol* 1981;3:291-4.
2. Kanthan R, Gomez D, Senger JL, Kanthan SC. Endoscopic biopsies of duodenal polyp/mass lesions: A surgical pathology review. *J Clin Pathol* 2010;63:921-5.
3. Campoli PM, Ejima FH, Cardoso DM, Silva OQ, Santana Filho JB, Queiroz Barreto PA, *et al.* Metastatic cancer to the stomach. *Gastric Cancer* 2006;9:19-25.
4. De Palma GD, Masone S, Rega M, Simeoli I, Donisi M, Addeo P, *et al.* Metastatic tumors to the stomach: Clinical and endoscopic features. *World J Gastroenterol* 2006;12:7326-8.
5. Christopherson W, Voet R, Buchsbaum HJ. Recurrent cervical cancer presenting as small bowel obstruction. *Gynecol Oncol* 1985;22:109-14.
6. Kanthan R, Senger JL, Diudea D. Pulmonary lymphangitic carcinomatosis from squamous cell carcinoma of the cervix. *World J Surg Oncol* 2010;8:107.
7. Kanthan R, Senger JL, Diudea D, Kanthan S. A review of duodenal metastases from squamous cell carcinoma of the cervix presenting as an upper gastrointestinal bleed. *World J Surg Oncol* 2011;9:113.
8. Misonou J, Natori T, Aizawa M, Jou B, Tamaki A, Ogasawara M. Stage (Ia) cervical cancer recurring 13 years after hysterectomy and causing small intestinal perforation. A case report with a review of the literature. *Acta Pathol Jpn* 1988;38:225-34.