

Xanthogranulomatous pyelonephritis: Rare presentation of a rare disease

Saifullah Khalid, Sufian Zaheer¹, Samreen Zaheer², Ibne Ahmad, Mohd Khalid

Abstract

Xanthogranulomatous pyelonephritis is a rare chronic renal infection of unknown pathogenesis characterized by replacement of renal parenchyma by lipid filled macrophages frequently associated with an enlarged, non-functioning kidney and an obstructing calculus. We report a case of a 45 year old non diabetic female who presented with gradually enlarging renal mass with extensive retroperitoneal involvement and a non-functioning kidney with *no evidence of obstructing stone or fat density* and simulating malignancy. She was diagnosed as stage III Xanthogranulomatous pyelonephritis and managed with radical nephrectomy with favourable outcome.

Key words: Chronic renal infection, nephrectomy, non-functioning kidney, xanthogranulomatous pyelonephritis, xanthoma cells

Introduction

Xanthogranulomatous pyelonephritis is known to be a “great imitator”. Differentiation with renal masses can often be a diagnostic challenge. It is a rare form of chronic renal infection with unknown aetiology. Xanthogranulomatous pyelonephritis (XPN) is frequently associated with an obstructing calculus and infection in diabetic females. We report a stage III XPN in a different clinical presentation with detailed radiological features to illustrate the variability of this rare entity.

Case Report

A 45-year-old female was referred to the radiology department for investigation of gradually progressive abdominal lump in right lumbar region which she first noticed about 6 months back. She had complains of right flank pain, fullness and pus in urine for the same duration, but intensity of pain has increased since last 15 days and had an episode of hematuria few days back. She also gave history of off and on fever, for which she took medications from local practitioners. However, she had no previous history of diabetes, hypertension, renal disease or urinary tract infection.

On local examination, temperature was slightly raised with an ill-defined firm to hard mass palpable in right lumbar region and was tender on palpation. Laboratory investigation showed leukocytosis with increase in neutrophil count. On admission, investigations done at our hospital showed raised

blood serum creatinine (1.8 mg%) and urea (60 IU) level. However, blood sugar level was normal.

An X-ray kidney urinary bladder (KUB) showed a large soft tissue density mass in right lumbar region displacing bowel loops to the left side. Loss of right psoas shadow, blurring of pre-peritoneal fat planes and mild scoliosis of spine with concavity to right side was also noted [Figure 1]. CT abdomen was advised immediately which showed ill defined, poorly excreting right kidney with loss of corticomedullary differentiation. There was extensive heterogeneously enhancing collection with involvement of adjacent soft tissue in perinephric and pararenal space, pelvis and under surface of liver with involvement of ipsilateral psoas, quadratus lumborum and lateral abdominal wall muscles. No evidence of calculus was seen on CT. Inferior vena cava IVC was displaced anteriorly due to retroperitoneal lymphadenopathy; however, no evidence of extension of the lesion into IVC was seen [Figure 2]. A radiological diagnosis of Xanthogranulomatous pyelonephritis was suggested even in the presence of negative history of diabetes, prior episode of urinary infections, absence of calculus and presence of hematuria.

Drainage of extrarenal abscess under coverage of piperacillin-tazobactam and metronidazole was performed and aspirate sent for cytology which showed lipid laden macrophages with few haemosiderin laden macrophages consistent with the diagnosis of Xanthogranulomatous type of Pyelonephritis [Figure 3]. This was followed by radical nephrectomy. The patient recovered well with uneventful post-operative period and patient was discharged on 7th post-operative day. The patient was last seen at 3 months follow up and has progressed well.

Discussion

Xanthogranulomatous pyelonephritis (XPN) was first described by Schlagenhauer in 1916.^[1] XPN is a rare renal infection characterized by replacement of renal parenchyma by lipid filled (Xanthoma cells) macrophages.^[2] XPN is considered a granulomatous reaction to severe

Departments of Radiodiagnosis, ¹Pathology, ²Radiotherapy, Jawaharlal Nehru Medical college & Hospital, AMU, Aligarh, Uttar Pradesh, India-202002

Correspondence to: Dr. Saifullah Khalid,

E-mail: saif2k2@gmail.com

Access this article online

Quick Response Code:



Website:

www.sajc.org

DOI:

10.4103/2278-330X.105863

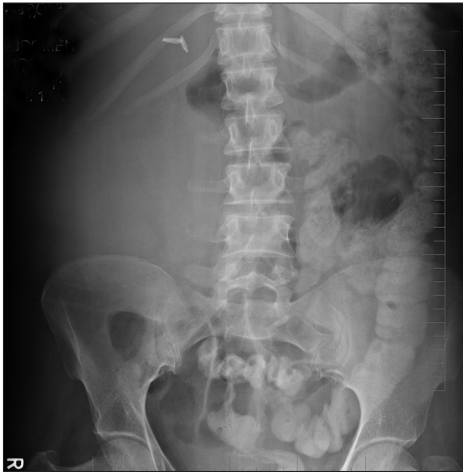

Figure 1: Digital X-ray KUB showed a large soft tissue density in right lumbar region with loss of right psoas shadow, blurring of preperitoneal fat planes, displaced bowel loops and mild scoliosis of spine

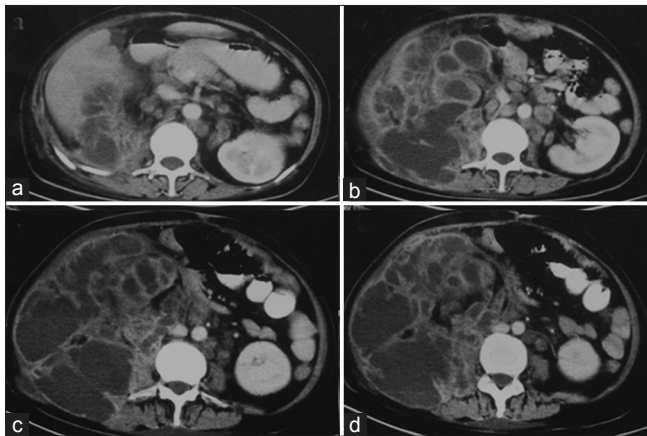


Figure 2: Contrast enhanced CT scan Abdomen shows poorly excreting right kidney with loss of contour and corticomedullary differentiation. Heterogeneous collection replacing the kidney with extension into right pararenal space, under surface of liver, pelvis and involvement of right Psoas, quadratus lumborum and lateral abdominal wall muscles. Also noted is retroperitoneal lymphadenopathy

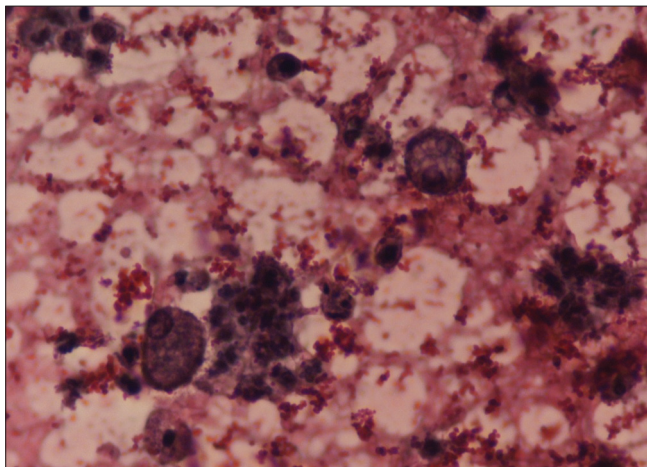


Figure 3: Fine needle aspirate smear shows lipid laden macrophages and few haemosiderin laden macrophages consistent with the diagnosis of Xanthogranulomatous pyelonephritis (Haematoxylin and eosin; x40)

obstruction, secondary to calculus, stricture or rarely tumor. On the basis of morphological involvement, two forms are described; more common diffuse form and relatively rarer focal form. The focal form closely mimics renal carcinoma.

The peak age incidence of XPN is in 5th to 6th decade, but can occur at any age, with females to male incidence ratio of 2:1.^[2-4] Patient presents with symptoms of flank mass, pain, intermittent high-grade fever and pyuria.^[4] Hematuria is relatively rare symptom and was seen in our case.^[2] Unilateral disease involvement is common with deranged renal function. Calculus is seen in majority of cases with compensatory hypertrophy of contralateral kidney seen in half of the cases.^[4] However, our case is typical as no obstructing calculus was seen and patient had hematuria as one of the symptoms.

Based on the severity of the disease XPN has been described in 3 stages.^[5] In stage I the lesion is confined to kidney, in stage II the lesion extends to Gerota's fascia and in stage III extends to the paranephric space and other retroperitoneal structures.

Histologically, both the focal and global form appears similar, showing mixed infiltration by plasma cells, histiocytes and includes significant population of lipid-filled macrophages. These lipid laden macrophages stain positive with periodic acid-schiff (PAS), thus differentiating from clear cell found in renal cell carcinoma.

Radiological diagnosis of XPN can be challenging as it can often be difficult to differentiate it from primary renal neoplasms, pyonephrosis and other retroperitoneal mesenchymal tumors.

X-ray KUB typically shows increased soft tissue density in lumbar region with calculus and evidence of displacement of bowel loops. Loss of psoas shadow, blurring of preperitoneal fat planes and mild scoliosis of spine are indicative of extra renal extension. CT is the imaging modality of choice as it not only suggests the diagnosis but also shows the extrarenal extent of the disease. Thus, helps in surgical planning. CT shows diffuse enlargement of the kidney with loss of renal architecture with large and heterogeneous low density areas and evidence of obstructing calculi. Treatment of XPN is antibiotics and partial or total nephrectomy.^[6-8]

Considering the age and symptoms of flank mass, hematuria in a non-diabetic patient with no evidence of calculus; differentials of a Ruptured pyonephrosis, Xanthogranulomatous pyelonephritis, primary renal mass and undifferentiated mesenchymal tumors were considered. Ruptured pyonephrosis was close differential but no evidence of obstructing calculus, absence of high grade fever were against it. Renal cell carcinoma is the most common renal mass in adults and should be in the differentials in an adult presenting with hematuria and a flank mass. Renal cell carcinoma attains large size containing areas of hemorrhage and necrosis and vascular invasion into IVC is a well-known

feature. The next differential was rare mesenchymal tumors presenting as large infiltrative renal masses. Their imaging features are non-specific and diagnosis is confirmed only on histopathology.

Conclusion

Xanthogranulomatous pyelonephritis should be considered in the differentials of flank mass with non-functioning kidney in non-diabetic patients even in the absence of obstructing calculus or fat density within the collection.

References

1. Schlagenhauser F. Uber eigentumliche Staphylomykosen der Nieren und des pararenalen Bindegewebes Frankfurter. Zeitschrift fur Pathologie 1916;19:139-48.
2. Goldman SM, Hartman DS, Fishman EK, Finizio JP, Gatewood OM, Siegelman SS. CT of xanthogranulomatous pyelonephritis: Radiologic-pathologic correlation. AJR Am J Roentgenol 1984;141:963-9.
3. Gingell JC, Roylance J, Davies ER, Penry JB. Xanthogranulomatous pyelonephritis. Br J Radiol 1973;46:99-109.
4. Dwivedi US, Goyal NK, Saxena V, Acharya RL, Trivedi S, Singh PB, *et al.* Xanthogranulomatous pyelonephritis: Our experience with review of published reports. ANZ J Surg 2006;76:1007-9.
5. Khalid M, Ahmad M, Siddiqui MA, Khalid S. Diagnostic difficulties in diffuse Xanthogranulomatous pyelonephritis: A case report and review of the Literature. Kidney Int 2010;19:73-5.
6. Al-Ghazo MA, Ghalayini IF, Matalaka II, Al-Kaisi NS, Khader YS. Xanthogranulomatous pyelonephritis: Analysis of 18 cases. Asian J Surg 2006;29:257-61.
7. Loffroy R, Guiu B, Watfa J, Michel F, Cercueil JP, Krause D. Xanthogranulomatous pyelonephritis in adults: Clinical and radiological findings in diffuse and focal forms. Clin Radiol 2007;62:884-90.
8. Craig WD, Wagner BJ, Travis MD. Pyelonephritis: Radiologic-pathologic review. Radiographics 2008;28:255-77.

How to cite this article: Khalid S, Zaheer S, Zaheer S, Ahmad I, Khalid M. Xanthogranulomatous pyelonephritis: Rare presentation of a rare disease. South Asian J Cancer 2013;2:4.

Source of Support: Nil. **Conflict of Interest:** None declared.