

CASE REPORT

Open Access



Infliximab therapy of relapsing tracheal stenosis in a pediatric patient with granulomatosis with polyangiitis: a case report

Alexander Schnell^{1*} , Renate Ruppel¹, Christina Tremel¹, Matthias Galiano², Maria-Elena Meßbacher³ and Tobias Krickau⁴

Abstract

Background: Granulomatosis with polyangiitis is a granulomatous, necrotizing small-vessel vasculitis affecting both children and adults. However, subglottic tracheal stenosis appears more frequently in the pediatric cohort. To date, granulomatosis with polyangiitis is often treated with steroids, cyclophosphamide, azathioprine, or rituximab, but tumor-necrosis-factor- α -antagonistic drugs are increasingly gaining significance in treatment of refractory cases.

Case presentation: We report the case of a 15-year-old Caucasian male diagnosed with proteinase-3-positive granulomatosis with polyangiitis with acute shortness of breath. X-ray and magnet resonance imaging showed extensive subglottic narrowing. Forced expiratory volume in 1 s was reduced to 50% of age norm, with massively increased effective airway resistance. The patient initially responded very well to high-dose steroids and maintenance therapy with azathioprine. He was subsequently treated with four doses of rituximab, and levels of proteinase 3 antibodies normalized. After 6 months of clinical remission, the patient presented again with acute respiratory symptoms. Again, he was treated with high-dose steroids, but showed poor clinical response this time. Therefore, we decided to commence a tumor-necrosis-factor- α -antagonistic treatment with infliximab, under which our patient achieved clinical remission and normalization of lung function parameters.

Conclusions: The use of tumor-necrosis-factor- α -antagonistic agents might be a promising alternative for the treatment of refractory tracheal stenosis in pediatric patients with granulomatosis with polyangiitis.

Keywords: Granulomatosis with polyangiitis, Tracheal stenosis, Children, TNF- α inhibitor

Introduction

Granulomatosis with polyangiitis (GPA) is a granulomatous, necrotizing small-vessel vasculitis associated with the presence of antineutrophil cytoplasmic antibodies (cANCA) affecting both adults and children. However,

within the pediatric cohort incidence rates are found to be approximately sevenfold higher than in adults (1.8 versus 12.8 cases per million per year) [1], with proper diagnosis presenting a challenge for pediatricians. The exact pathophysiology remains elusive, but GPA is thought to appear in a two-stage course. It usually begins as a granulomatous disease of the respiratory tract in response to an exogenous or endogenous antigen, mainly affecting the ear–nose–throat (ENT) tract in the form of sinusitis/rhinitis, septal perforation, oral or nasal ulcerations, and otitis [2, 3]. Moreover, subglottic stenosis as a primary

*Correspondence: alexander.schnell@uk-erlangen.de

¹ Pediatric Pneumology and Allergology, Department of Pediatrics and Adolescent Medicine, University Hospital Erlangen, Friedrich-Alexander-University, Erlangen-Nuremberg, Germany
Full list of author information is available at the end of the article



© The Author(s) 2022. **Open Access** This article is licensed under a Creative Commons Attribution 4.0 International License, which permits use, sharing, adaptation, distribution and reproduction in any medium or format, as long as you give appropriate credit to the original author(s) and the source, provide a link to the Creative Commons licence, and indicate if changes were made. The images or other third party material in this article are included in the article's Creative Commons licence, unless indicated otherwise in a credit line to the material. If material is not included in the article's Creative Commons licence and your intended use is not permitted by statutory regulation or exceeds the permitted use, you will need to obtain permission directly from the copyright holder. To view a copy of this licence, visit <http://creativecommons.org/licenses/by/4.0/>. The Creative Commons Public Domain Dedication waiver (<http://creativecommons.org/publicdomain/zero/1.0/>) applies to the data made available in this article, unless otherwise stated in a credit line to the data.

symptom of GPA has been reported to appear in around 4–10% and tends to be more frequently diagnosed in children than in adults [3–5]. The disease can progress to the systemic stage, resulting in diffuse vasculitis of one or several organs, such as kidney or lung. Yet, there are no significant differences between the pediatric and the adult cohort with regard to the pattern of clinical manifestations. However, if untreated, GPA is associated with a high mortality rate of up to 90% [6, 7]. Recommended therapy for remission induction usually is high-dose steroids in combination with cyclophosphamide, although the latter is of inferior relevance in the pediatric cohort because of fertility concerns. Since the RAVE trial (“rituximab in ANCA-associated vasculitis”) in 2010, B-cell-depleting therapy with rituximab has been a considerable possibility and often used as first-line therapy in children. For remission maintenance, low-dose steroids in combination with azathioprine, methotrexate (MTX), or RTX can be used [8]. However, there are several reports where a tumor necrosis factor α (TNF- α)-antagonistic therapy, either stand-alone or in combination with RTX, was successfully used for treatment of patients with refractory GPA [9, 10].

Case presentation

We report the case of a 15-year-old Caucasian male presenting with unclear fever, relapsing otitides, and facial and nasal ulcerations for the first time in March 2020. Nasal biopsies showed extensive necrotizing granulomatous inflammation. cANCA/PR3 antibodies were highly elevated (360 U/ml, upper reference limit 20 U/ml). Imaging [sonography and magnetic resonance imaging (MRI)] revealed splenic infarction due to arteritis lienalis. There were no signs of kidney, lung, joint, or central nervous system involvement. The patient met the 2017 American College of Rheumatology criteria (ACR) for GPA. He was treated with high-dose steroids (1 g/day over 3 days), followed by azathioprine (2 mg/kg/day) and low-dose steroids as maintenance treatment. Owing to the splenic infarction caused by vasculitis of the splenic artery, he also received prophylactic antibiotic (penicillin) and anticoagulatory treatment (salicylic acid). The patient initially responded very well to the immunosuppressive treatment, and levels of PR3 antibodies normalized until May 2020. Consequently, glucocorticoids, salicylic acid, and penicillin could be discontinued. However, after discontinuation of steroid treatment, we detected another increase of PR3 antibodies up to 128 U/ml in June 2020, but owing to the good clinical apparition no further action was taken and levels of autoantibodies tended to decrease spontaneously.

In September 2020, he was admitted with a 2-week history of shortness of breath, even without physical

activity, and inspiratory stridor. Moreover, he complained about hearing loss after discontinuation of glucocorticoid treatment. Lung function testing showed severe obstruction of the upper airways [forced expiratory volume in 1 s (FEV₁) 50% of age norm] and a massively increased airway resistance [effective airway resistance (sR_{eff}) 1018% of age norm]. MRI revealed a circular subglottic tracheal narrowing over a length of 2 cm. The levels of the beforehand-elevated PR3 antibodies showed no further increase (93 U/ml). We initiated a high-dose steroid treatment for 3 days followed by four subsequent doses of rituximab (RTX, 375 mg/m², cumulative dose: 4 × 700 mg) in 4-week intervals for remission induction according to the therapy protocol of the RAVE study [11]. Clinical apparition and lung function parameters clearly improved under therapy, but the patient still reported shortness of breath under heavy physical activity and the flow profile in the body plethysmography still showed signs of tracheal stenosis. To match the decreasing dosages of oral glucocorticoids, he received inhalative corticosteroids (ICS; budesonide) together with a slow-acting bronchodilator (formoterol) in addition to the ongoing maintenance therapy with AZA on the occasion of a routine appointment in our pediatric pneumology department in November 2020. At that time, levels of PR3 antibodies also reached the normal range (Fig. 1).

After 3 months, in February 2021, his obstructive respiratory symptoms worsened as he complained about increasing inspiratory stridor. Blood gas analysis revealed a mild CO₂ retention, and his lung function parameters showed a deterioration to similar values as in September 2020 (FEV₁ 55% of age norm, sR_{eff} 1039% of age norm). Again, we performed an MRI, which showed a circular subglottic tracheal narrowing over a length of 1.5 cm (Fig. 2). To exclude further affection of the lower airways, we performed a chest computed tomography (CT) scan. Direct laryngoscopy showed a Cotton–Myer grade III subglottic stenosis, beginning 1 cm below the vocal cords with a length of 1.5 cm (Fig. 3). A biopsy taken from the subglottic tracheal lesion revealed ongoing neutrophilic inflammation. Again, high-dose steroids were initiated, but, in contrast to the prior admission in September 2020, the patient responded poorly. After consideration of the increased risk of infection due to the severe acute respiratory syndrome coronavirus 2 (SARS-CoV-2) pandemic and the persistently low B-cell count after the first RTX treatment, we decided against a second RTX cycle or other therapeutic alternatives (for example, cyclophosphamide) and initiated a TNF- α -antagonistic treatment with infliximab with a starting dose of 6 mg/kg. In induction phase, he received the first three doses in 2-week intervals, followed by 4-week intervals in maintenance phase. Moreover, AZA dosage was adapted to body

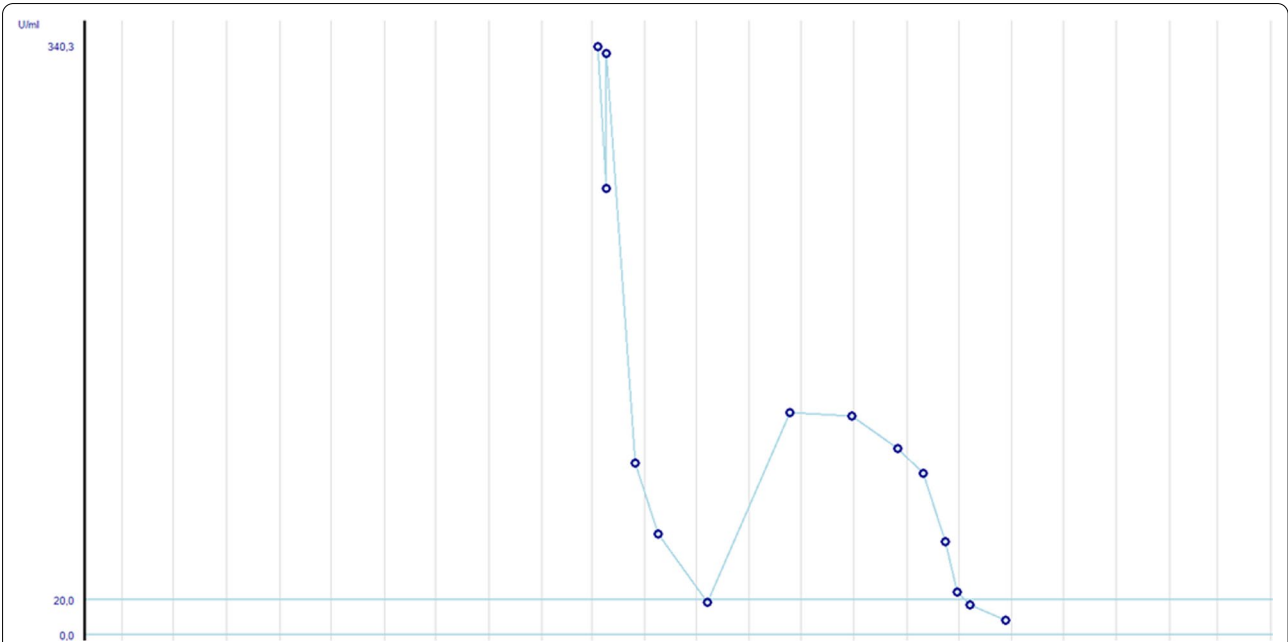


Fig. 1 Levels of proteinase-3 antibodies over the past 15 months since initial presentation. After November 2020, no proteinase-3 antibodies were detectable. Blue lines indicate the normal range

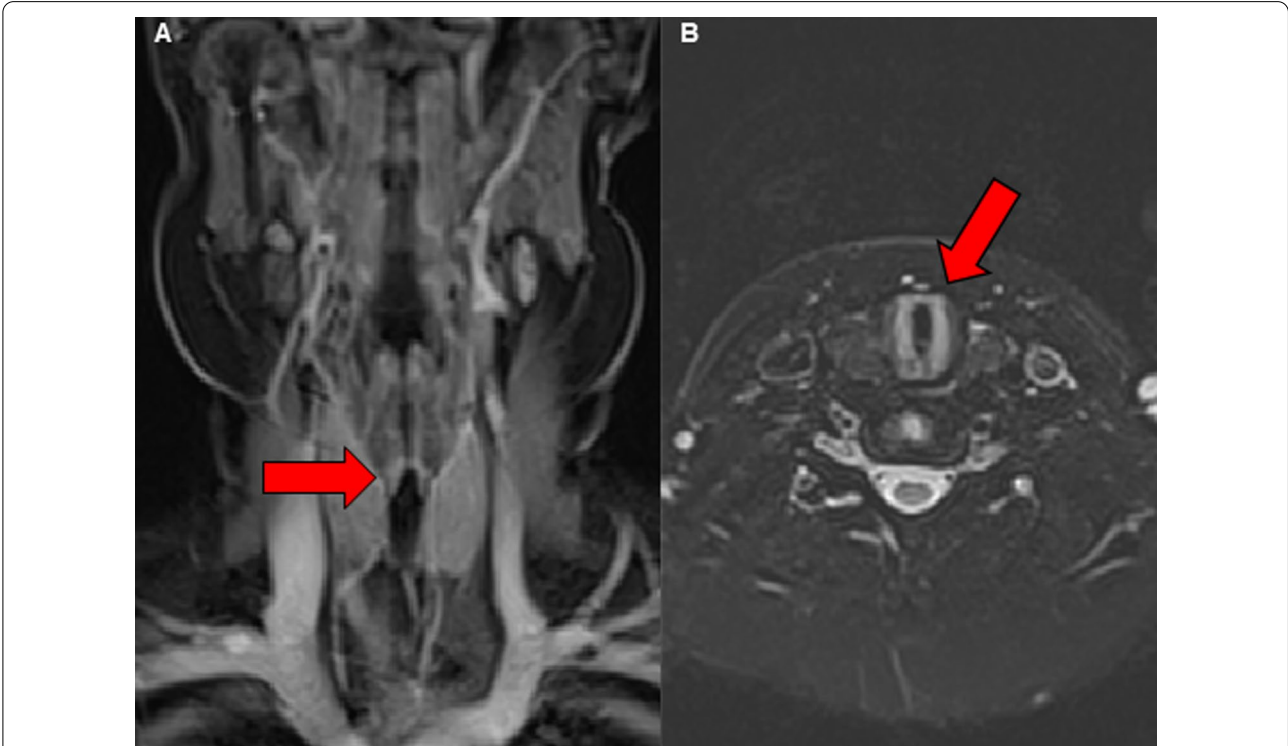


Fig. 2 Radiological imaging of the subglottic tracheal stenosis in frontal (A) and transverse (B) plane. Abnormal findings are marked with red arrows

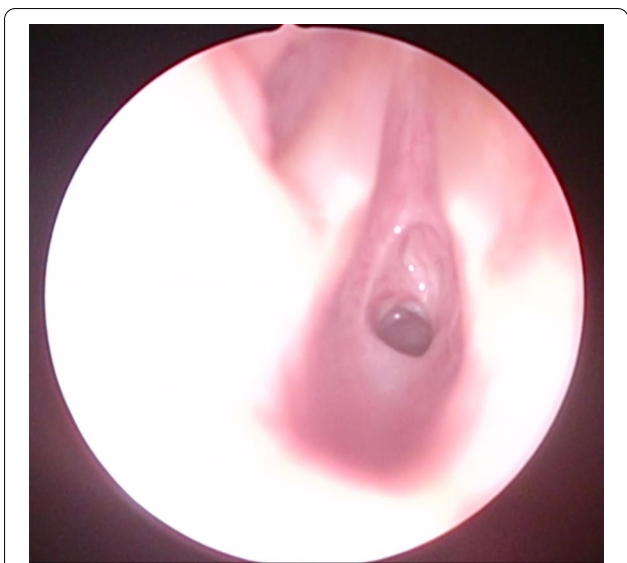

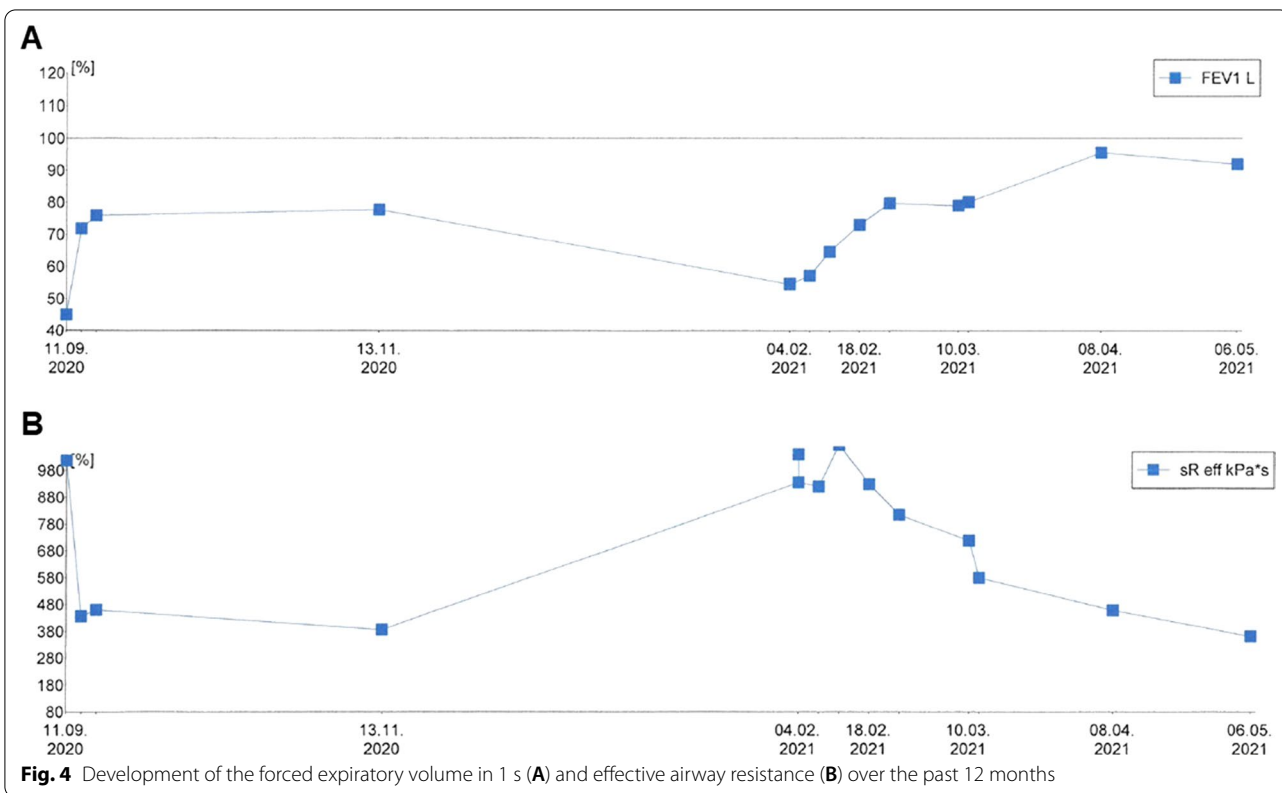
Fig. 3 Fiberoptic imaging of the subglottic tracheal stenosis during laryngoscopy

weight. Our patient responded very well to the TNF- α -antagonistic treatment as his respiratory symptoms resolved completely and his lung function parameters normalized entirely (FEV₁ 92% of age norm, sR_{eff} 361% of

age norm; Fig. 4). At his last appointment in May 2021, he was in complete clinical remission.

Conclusion

The development of biological drugs such as RTX or IFX has revolutionized the treatment of inflammatory disorders since they allow a therapy strategy tailored to the specific pathomechanism of the underlying disease. In the case of ANCA-associated vasculitis with its formation of PR3 antibodies by autoreactive B cells, a CD20-depleting therapy with RTX has consequently been established as a reliable option for induction and maintenance therapy alike. However, there is a notable number of patients with persistent autoantibody production after B-cell depletion since RTX treatment only disrupts the generation of plasmablasts but leaves the existing long-lived plasma cells untouched [12, 13]. Moreover, RTX has been described to have poor effectiveness in cases of predominant granulomatous disease activity (such as subglottic tracheal stenosis) in contrast to vasculitis-mediated glomerulonephritis [14, 15]. Taking a closer look at the pathogenesis of GPA, TNF- α can be identified as playing a pivotal role in the formation of granulomata in the localized stage. Effector memory T cells (T_{EM}) produce large amounts of T_{H1} cytokines such as IFN- γ and TNF- α in response to antigens in the respiratory tract,



thereby recruiting neutrophils to the site of inflammation [16, 17]. Moreover, there is evidence that the granulomata in the ENT tract might serve as tertiary lymphoid follicles, resulting in abundant formation of autoantibodies directed against neutrophilic proteinase 3 (PR3)/cANCA [18]. Consequently, regarding the central implications of TNF- α in GPA, it appears reasonable to consider a TNF- α -antagonistic treatment with, for example, IFX as a potential therapy alternative. Previous studies support the efficacy of IFX therapy in refractory cases [19, 20], and also the combination of TNF- α blockade and B-cell depletion has been used successfully [21, 22]. However, data concerning the use of infliximab in children diagnosed with GPA are scarce. However, the fact that subglottic stenosis represents a not uncommon symptom of pediatric GPA in connection with the severe constraints that are placed on the daily life of patients highlights the importance of effective therapy strategies, especially with regard to refractory cases. Our case report supports the potential of the additional use of infliximab in steroid and RTX refractory cases, yet there is a strong need for further evidence for the safe use of IFX in children.

Abbreviations

ACR: American College of Rheumatology; AZA: Azathioprine; cANCA: Anti-neutrophil cytoplasmic antibodies; CYC: Cyclophosphamide; FEV1: Forced expiratory volume in 1 s; GPA: Granulomatosis with polyangiitis; ICS: Inhalative corticosteroids; IFX -: Infliximab; MRI: Magnetic resonance imaging; MTX: Methotrexate; PR3: Proteinase 3; RAVE: Rituximab in ANCA-associated vasculitis; RTX: Rituximab; sR_{eff} : Effective airway resistance; T_{EM} : Effector memory T cells; TNF- α : Tumor necrosis factor α .

Acknowledgements

Radiological material is provided by the courtesy of the Radiologic Department, University Hospital Erlangen, Friedrich-Alexander-University Erlangen-Nuremberg.

Authors' contributions

AS, RR, CT, MG, EM, and TK contributed to the treatment design and patient management. AS conceived the presented idea and wrote the paper with input from TK. All authors gave consent for publication. All authors read and approved the final manuscript.

Funding

Open Access funding enabled and organized by Projekt DEAL. No financial support was received from any funding bodies in the public or commercial to carry out the work described in this manuscript.

Availability of data and materials

Not applicable.

Declarations

Ethics approval and consent to participate

Specific ethical approval of this case report was not considered necessary by the ethics committee of the Friedrich-Alexander University Erlangen-Nuremberg.

Consent for publication

Written informed consent was obtained from the patient's legal guardian for publication of this case report and any accompanying images. A copy of the written consent is available for review by the Editor-in-Chief of this journal.

Competing interests

The authors declare no competing interests.

Author details

¹Pediatric Pneumology and Allergology, Department of Pediatrics and Adolescent Medicine, University Hospital Erlangen, Friedrich-Alexander-University, Erlangen-Nuremberg, Germany. ²Pediatric Nephrology, Department of Pediatrics and Adolescent Medicine, University Hospital Erlangen, Friedrich-Alexander-University, Erlangen-Nuremberg, Germany. ³Department of Otolaryngology, Head and Neck Surgery, University Hospital Erlangen, Friedrich-Alexander-University, Erlangen-Nuremberg, Germany. ⁴Pediatric Rheumatology, Department of Pediatrics and Adolescent Medicine, University Hospital Erlangen, Friedrich-Alexander-University, Erlangen-Nuremberg, Germany.

Received: 9 July 2021 Accepted: 9 March 2022

Published online: 01 April 2022

References

- Panupattanapong S, et al. Epidemiology and outcomes of granulomatosis with polyangiitis in pediatric and working-age adult populations in the United States: analysis of a large national claims database. *Arthritis Rheumatol*. 2018;70(12):2067–76.
- Bosch X, et al. Immunotherapy for antineutrophil cytoplasmic antibody-associated vasculitis: challenging the therapeutic status quo? *Trends Immunol*. 2008;29(6):280–9.
- Cabral DA, et al. Comparing presenting clinical features in 48 children with microscopic polyangiitis to 183 children who have granulomatosis with polyangiitis (Wegener's): an ARChiVe cohort study. *Arthritis Rheumatol*. 2016;68(10):2514–26.
- Akikusa JD, et al. Clinical features and outcome of pediatric Wegener's granulomatosis. *Arthritis Rheum*. 2007;57(5):837–44.
- Lee PY, et al. The presentation and management of granulomatosis with polyangiitis (Wegener's granulomatosis) in the pediatric airway. *Laryngoscope*. 2017;127(1):233–40.
- Almouhawis HA, et al. Wegener's granulomatosis: a review of clinical features and an update in diagnosis and treatment. *J Oral Pathol Med*. 2013;42(7):507–16.
- Bohm M, et al. Clinical features of childhood granulomatosis with polyangiitis (Wegener's granulomatosis). *Pediatr Rheumatol Online J*. 2014;12:18.
- Jariwala MP, Laxer RM. Primary vasculitis in childhood: GPA and MPA in childhood. *Front Pediatr*. 2018;6:226.
- de Menthon M, et al. Infliximab or rituximab for refractory Wegener's granulomatosis: long-term follow up. A prospective randomised multicentre study on 17 patients. *Clin Exp Rheumatol*. 2011;29(1 Suppl 64):S63–71.
- Huugen D, Tervaert JW, Heeringa P. TNF-alpha bioactivity-inhibiting therapy in ANCA-associated vasculitis: clinical and experimental considerations. *Clin J Am Soc Nephrol*. 2006;1(5):1100–7.
- Stone JH, et al. Rituximab versus cyclophosphamide for ANCA-associated vasculitis. *N Engl J Med*. 2010;363(3):221–32.
- Looney RJ, et al. B cell depletion as a novel treatment for systemic lupus erythematosus: a phase I/II dose-escalation trial of rituximab. *Arthritis Rheum*. 2004;50(8):2580–9.
- Hoyer BF, et al. Long-lived plasma cells and their contribution to autoimmunity. *Ann NY Acad Sci*. 2005;1050:124–33.
- Aries PM, et al. Lack of efficacy of rituximab in Wegener's granulomatosis with refractory granulomatous manifestations. *Ann Rheum Dis*. 2006;65(7):853–8.
- Eriksson P. Nine patients with anti-neutrophil cytoplasmic antibody-positive vasculitis successfully treated with rituximab. *J Intern Med*. 2005;257(6):540–8.

16. Sarraf P, Sneller MC. Pathogenesis of Wegener's granulomatosis: current concepts. *Expert Rev Mol Med*. 2005;7(8):1–19.
17. Komocsi A, *et al*. Peripheral blood and granuloma CD4(+)CD28(–) T cells are a major source of interferon-gamma and tumor necrosis factor-alpha in Wegener's granulomatosis. *Am J Pathol*. 2002;160(5):1717–24.
18. Voswinkel J, *et al*. B lymphocyte maturation in Wegener's granulomatosis: a comparative analysis of VH genes from endonasal lesions. *Ann Rheum Dis*. 2006;65(7):859–64.
19. Bartolucci P, *et al*. Efficacy of the anti-TNF-alpha antibody infliximab against refractory systemic vasculitides: an open pilot study on 10 patients. *Rheumatology (Oxford)*. 2002;41(10):1126–32.
20. Lamprecht P, *et al*. Effectiveness of TNF-alpha blockade with infliximab in refractory Wegener's granulomatosis. *Rheumatology (Oxford)*. 2002;41(11):1303–7.
21. Valor-Mendez L, *et al*. Sustained clinical remission under infliximab/rituximab combination therapy in a patient with granulomatosis with polyangiitis. *Auto Immun Highlights*. 2021;12(1):5.
22. Donmez S, *et al*. A case of granulomatosis with polyangiitis and pyoderma gangrenosum successfully treated with infliximab and rituximab. *Int J Rheum Dis*. 2014;17(4):471–5.

Publisher's Note

Springer Nature remains neutral with regard to jurisdictional claims in published maps and institutional affiliations.

Ready to submit your research? Choose BMC and benefit from:

- fast, convenient online submission
- thorough peer review by experienced researchers in your field
- rapid publication on acceptance
- support for research data, including large and complex data types
- gold Open Access which fosters wider collaboration and increased citations
- maximum visibility for your research: over 100M website views per year

At BMC, research is always in progress.

Learn more biomedcentral.com/submissions

