

## Original Article

# Assessment of slice thickness effect on visibility of inferior alveolar canal in cone beam computed tomography images

Daryoush Goodarzi Pour<sup>1,2</sup>, Banafsheh Arzi<sup>3</sup>, Ahmad Reza Shamschiri<sup>4</sup>

Departments of <sup>1</sup>Maxillofacial Radiology and <sup>4</sup>Research Center for Caries Prevention, Dentistry Research Institute, <sup>2</sup>Department of Community Oral Health, Dental School, Tehran University of Medical Sciences, Tehran, <sup>3</sup>Department of Maxillofacial Radiology, Dental School, Arak University of Medical Sciences, Arak, Iran

## ABSTRACT

**Objective:** The aim of this study is to evaluate the effect of slice thickness on the visibility of inferior alveolar canal (IAC) in cone-beam computed tomography (CBCT) images.

**Materials and Methods:** CBCT images of thirty patients (15 male and 15 female) with an age range between 40–50 years old were used. Cross-sectional images were obtained with 0.5, 1, and 2 mm slice thickness and 2 mm interval. Two oral radiologists with at least 5 years' of experience observed all of the 90 images and rated the images based on the visibility of IAC in a 4-score classification (highly visible, visible, nearly visible, nearly invisible). Friedman test was used for the comparison of visibility of IAC in different slice thicknesses. To do the above test, the average of the scores of two examiners was calculated. A *P* value below 0.05 was considered significant.

**Results:** Visibility of IAC in different slice thicknesses of both raters showed no significant difference (*P* = 0.20).

**Conclusion:** Within the limitations of this study the slice thickness has no effect on visibility of IAC in cross-sectional images. Future studies on other multiplanar images are recommended.

**Key Words:** Cone beam computed tomography, cross, inferior alveolar nerve, section

Received: November 2015  
Accepted: April 2016

Address for correspondence:  
Dr. Daryoush Goodarzi Pour,  
Department of Maxillofacial  
Radiology, Dental School,  
Tehran University of Medical  
Sciences, Tehran, Iran.  
E-mail: drgoodarzi@  
tums.ac.ir

## INTRODUCTION

Successful dental surgery needs complete information about regional anatomy. Some of the surgical procedures including insertion of dental implants, mandibular third molar surgery, osteotomy, and other surgeries close to inferior alveolar canal (IAC) require assessment of IAC to prevent injuries to neurovascular bundles.<sup>[1]</sup> Mandibular canal is one of the most important anatomic structure due to its content and risk of damage during surgery. This is more critical in atrophic ridges in premolar and molar area. In conventional radiographic images, IAC could be seen

as a radiolucent line with two thin cortical borders. In some osteoporotic mandibles detection of IAC may be difficult due to its lack of well-defined cortical boundaries. Panoramic is a widely used technique for tracing IAC and estimating its position in vertical dimension.<sup>[2,3]</sup> In the late 1990s, cone-beam computed tomography (CBCT) was introduced to dentistry which provided more sharpness.<sup>[2]</sup> Linear measurements in CBCT are accurate enough for implant surgery.<sup>[3,4]</sup> CBCT images are useful for evaluating IAC and its position three-dimensionally, considering tooth roots,

This is an open access article distributed under the terms of the Creative Commons Attribution-NonCommercial-ShareAlike 3.0 License, which allows others to remix, tweak, and build upon the work non-commercially, as long as the author is credited and the new creations are licensed under the identical terms.

**For reprints contact:** reprints@medknow.com

**How to cite this article:** Pour DG, Arzi B, Shamschiri AR. Assessment of slice thickness effect on visibility of inferior alveolar canal in cone beam computed tomography images. Dent Res J 2016;13:527-31.

### Access this article online



Website: [www.drj.ir](http://www.drj.ir)  
[www.drjjournal.net](http://www.drjjournal.net)  
[www.ncbi.nlm.nih.gov/pmc/journals/1480](http://www.ncbi.nlm.nih.gov/pmc/journals/1480)

and alveolar crest. Furthermore, abnormal mandibular canals like branched canals can be identified by CBCT. This technology facilitates the evaluation of IAC due to its cross-sectional images which overcome the weak points of conventional images.<sup>[5]</sup> Various parameters influence the characteristics of CBCT image, such as field of view, slice interval, and tube current. One of the parameters which may affect the visibility of anatomic structures like IAC is the slice thickness. There is a common belief in multi-detector computed tomography (MDCT) that thin slices make better images.<sup>[6]</sup> It is known that thinner slices provide less partial volume averaging and better image quality with more detailed visibility.<sup>[7]</sup> The aim of this study is to evaluate the effect of slice thickness on visibility of IAC in CBCT images.

### MATERIALS AND METHODS

We used CBCT archive in the Oral and Maxillofacial Department of Radiology, Tehran University of Medical Sciences, Tehran, Iran. CBCT images of

30 patients (15 male and 15 female) with age range between 40 and 60 years old were used. Imaging was performed by Alphard VEGA (Asahi Roentgen, Japan). Peak kilovoltage and mA was 80 and 4, respectively for all samples. The images were processed using Neo 3D software Version 2.01 (Asahi Roentgen, Japan) and cross-sectional images were prepared by 0.5, 1, and 2 mm slice thicknesses and 2 mm interval. Default thickness of cross-sectional images in the software was 1 mm, and we selected half and double thicknesses of default. All of the 90 images were coded and saved in joint photographic experts format [Figures 1-3]. Two oral radiologists with at least 5 years of experience observed images randomly and blindly using 19" LCD monitor (Samsung, SyncMaster P23700). They rated the images based on the visibility of IAC in a 4-score classification (highly visible, visible, nearly visible, nearly invisible). For the second time, all images were rated 10 days later with different codes.

Intraclass correlation coefficient (ICC with two-way random model and absolute agreement type) was

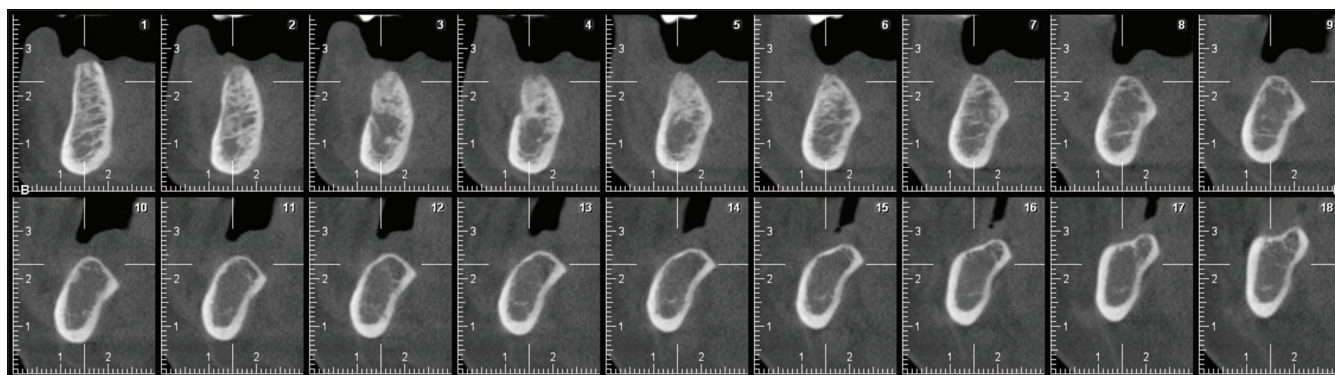


Figure 1: Cross sectional image, 0.5 mm thickness.

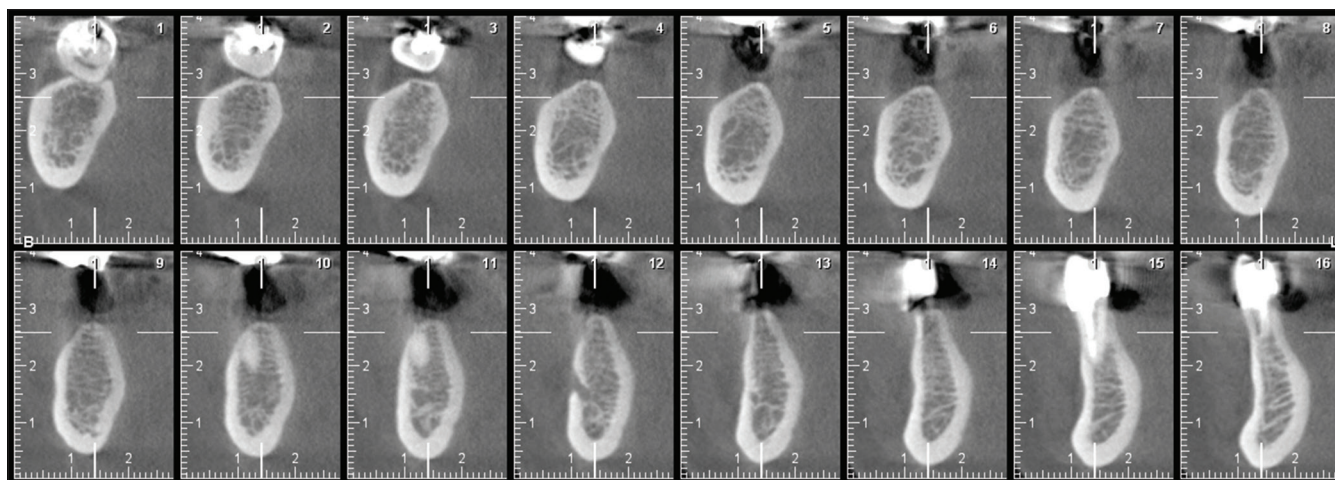
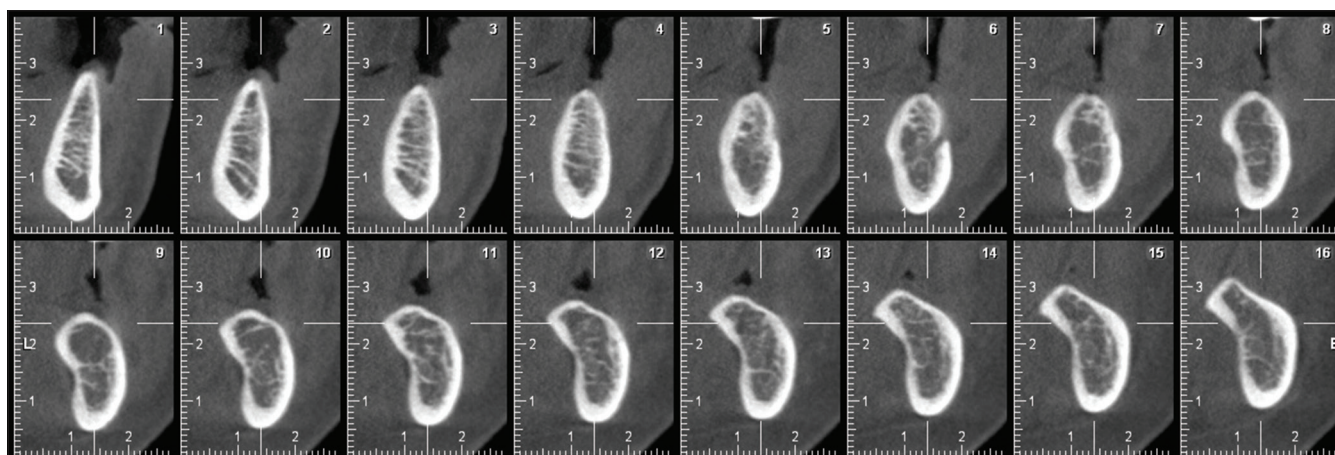


Figure 2: Cross sectional image, 1 mm thickness.



**Figure 3:** Cross sectional image, 2 mm thickness.

performed to evaluate inter- and intra-observer agreement. We found favorable agreement considering the resulted ICC [Tables 1-3].

### Statistical analysis

SPSS for Windows Version 21 (IBM Corp. Released 2012. IBM SPSS Statistics for Windows, Version 21.0. Armonk, NY, USA) was used. Friedman test was used for the comparison of visibility of IAC as an ordinal variable in different slice thicknesses. To do the above test, the average of the scores of two raters was calculated. A *P* value below 0.05 was considered significant.

## RESULTS

Visibility of IAC in different slice thicknesses of both raters had no significant difference (*P* = 0.20) [Table 4].

Our result demonstrates that 53.3% of images in females were highly visible, compared with 80% of images in males. Samples were not adequate to compare males and females.

## DISCUSSION

Image quality is a subjective interpretation of visual data and does not have an exact definition. An image should have enough information to obtain a clinical decision. The aim of our study was to evaluate the effect of slice thickness of CBCT images on the visibility of IAC. IAC is one of the most important anatomical structure of mandible due to its content, including inferior alveolar nerve, artery, and vein. It is critical to consider the location and variations of IAC, especially in atrophic ridges before implant installation.<sup>[8]</sup>

**Table 1: Inter-observer reliability in different slice thickness**

Statistical indicators	Slice thickness (mm)		
	0.5	1	2
ICC	0.915	0.789	0.736
<i>P</i>	0.000	0.000	0.000

ICC: Intra-class correlation coefficient

**Table 2: Intra-observer reliability in different slice thickness (Observer 1)**

Statistical indicators	Slice thickness (mm)		
	0.5	1	2
ICC	0.757	0.767	0.686
<i>P</i>	0.000	0.000	0.000

ICC: Intra-class correlation coefficient

**Table 3: Intra-observer reliability in different slice thickness (Observer 2)**

Statistical indicators	Slice thickness (mm)		
	0.5	1	2
ICC	0.761	0.828	0.76
<i>P</i>	0.000	0.000	0.000

ICC: Intra-class correlation coefficient

**Table 4: Visibility of inferior alveolar canal in different slice thickness**

Level of visibility	Slice thickness (mm) (%)		
	0.5	1	2
<b>Observer 1</b>			
Highly visible	20 (66.7)	18 (60)	21 (70)
Visible	5 (16.7)	8 (26.7)	7 (23.3)
Nearly visible	3 (10)	1 (3.3)	1 (3.3)
Nearly invisible	2 (6.7)	3 (10)	1 (3.3)
<b>Observer 2</b>			
Highly visible	21 (70)	23 (76.7)	16 (53.3)
visible	6 (20)	4 (13.3)	8 (26.7)
Nearly visible	2 (6.7)	2 (6.7)	4 (13.3)
Nearly invisible	1 (3.3)	1 (3.3)	2 (6.7)

CBCT machine provides perfect images with low dose and cost, compared to MDCT.<sup>[9]</sup> There is a wide variety of specification of CBCT machines which are used with different acceptable images and exposure doses.<sup>[10]</sup> One of the parameters which can be altered in CBCT to affect the image quality is slice thickness.<sup>[11]</sup> There have been few researches about the efficacy of slice thickness of CBCT and its effect on visibility of anatomical structure.

In our study, there was no significant difference between visibility of IAC in different slice thicknesses and any attempt to change slice thickness did not cause better visualization of IAC in cross-sectional images.

Any change in slice thickness either increasing or decreasing may affect subject's contrast and visibility. In the present research, the subject contrast of IAC was not affected by the thickness of cross-sectional images. It may be due to the favorable contrast in well-corticated IACs so that good visibility of IAC was not influenced by slice thickness. On the other hand, ill-defined IAC has low contrast and may be mistaken with surrounding bone marrow space, to an extent that altering the thickness is of no benefit to its visibility.

There are some other researches with different methods which concluded positive effect of slice thickness. Sezgin *et al.* evaluated the effect of slice thickness on volumetric calculation of CBCT, showing that estimated volumes of intrabony lesions did not change with different slice thicknesses.<sup>[12]</sup> Jia *et al.* studied the effect of slice thickness of CBCT on the precision of image-guided radiotherapy. They showed that slice thickness has no significant effect on positioning precision.<sup>[13]</sup>

Similar research was done in MDCT with different methods and results. Mühler *et al.* studied the accuracy and reliability of age estimation, using clavicular epiphyseal plate in forensic medicine. In their study, the best result was obtained with slice thickness of 1 mm.<sup>[14]</sup> Dogan evaluated the effect of heart rate and slice thickness on volumetric analysis of CT images of cardiac phantom and concluded that slice thickness of 2 and 8 mm have the same diagnostic value.<sup>[15]</sup> Guggenbuhl *et al.* studied microstructure of tibia in CT and concluded that increasing the slice thickness will result in lower accuracy of tissue analysis parameters.<sup>[16]</sup> In another research, Rubinstein *et al.* noticed that the diagnostic accuracy of fractures

in odontoid process will increase with 1 mm section thickness.<sup>[17]</sup> Jung *et al.* studied the multiplanar reformation using 1.25, 2.5, 3.75, and 5 mm slice thicknesses for quantitative measurement in CT and demonstrated that thinner slice thicknesses result in better image quality.<sup>[18]</sup> Sirin studied diagnostic accuracy of reconstructed CBCT images, using different slice thicknesses, in detection of simulated mandibular condylar fracture. They concluded that the diagnosis will be more accurate using slice thickness of 0.2 and 1 mm, compared to 2 and 3 mm.<sup>[19]</sup>

## CONCLUSION

Our study showed that slice thickness has no effect on visibility of IAC in cross-sectional images. Tracing ill-defined IACs can be achieved by other multiplanar images, such as panoramic or axial view; also nerve tracing tools in software's used for CBCT might be useful. Further studies with different methodology may be useful to achieve more results.

### Financial support and sponsorship

Nil.

### Conflicts of interest

The authors of this manuscript declare that they have no conflicts of interest, real or perceived, financial or non-financial in this article.

## REFERENCES

1. Denio D, Torabinejad M, Bakland LK. Anatomical relationship of the mandibular canal to its surrounding structures in mature mandibles. *J Endod* 1992;18:161-5.
2. Panmekiate S, Apinhasmit W, Petersson A. Effect of electric potential and current on mandibular linear measurements in cone beam CT. *Dentomaxillofac Radiol* 2012;41:578-82.
3. Parnia F, Moslehifard E, Hafezeqoran A, Mahboub F, Mojaver-Kahnamoui H. Characteristics of anatomical landmarks in the mandibular interforaminal region: A cone-beam computed tomography study. *Med Oral Patol Oral Cir Bucal* 2012;17:e420-5.
4. Liang X, Lambrichts I, Sun Y, Denis K, Hassan B, Li L, *et al.* A comparative evaluation of cone beam computed tomography (CBCT) and Multi-Slice CT (MSCT). Part II: On 3D model accuracy. *Eur J Radiol* 2010;75:270-4.
5. Asaumi R, Kawai T, Sato I, Yoshida S, Yosue T. Three-dimensional observations of the incisive canal and the surrounding bone using cone-beam computed tomography. *Oral Radiol* 2010;26:20-8.
6. Richards PJ. Cervical spine clearance: A review. *Injury* 2005;36:248-69.
7. Whyms BJ, Vorperian HK, Gentry LR, Schimek EM, Bersu ET, Chung MK. The effect of computed tomographic scanner parameters and 3-dimensional volume rendering techniques on the accuracy of linear, angular, and volumetric measurements

- of the mandible. *Oral Surg Oral Med Oral Pathol Oral Radiol* 2013;115:682-91.
8. Feifel H, Riediger D, Gustorf-Aeckerle R. High resolution computed tomography of the inferior alveolar and lingual nerves. *Neuroradiology* 1994;36:236-8.
  9. Scarfe WC. Imaging of maxillofacial trauma: Evolutions and emerging revolutions. *Oral Surg Oral Med Oral Pathol Oral Radiol Endod* 2005;100 2 Suppl: S75-96.
  10. De Vos W, Casselman J, Swennen GR. Cone-beam computerized tomography (CBCT) imaging of the oral and maxillofacial region: A systematic review of the literature. *Int J Oral Maxillofac Surg* 2009;38:609-25.
  11. Hassan B, Couto Souza P, Jacobs R, de Azambuja Berti S, van der Stelt P. Influence of scanning and reconstruction parameters on quality of three-dimensional surface models of the dental arches from cone beam computed tomography. *Clin Oral Investig* 2010;14:303-10.
  12. Sezgin OS, Kayipmaz S, Sahin B. The effect of slice thickness on the assessment of bone defect volumes by the Cavalieri principle using cone beam computed tomography. *J Digit Imaging* 2013;26:115-8.
  13. Jia MX, Zhang X, Li N, Han CB. Impact of different CBCT imaging monitor units, reconstruction slice thicknesses, and planning CT slice thicknesses on the positioning accuracy of a MV-CBCT system in head-and-neck patients. *J Appl Clin Med Phys* 2012;13:3766.
  14. Mühler M, Schulz R, Schmidt S, Schmeling A, Reisinger W. The influence of slice thickness on assessment of clavicle ossification in forensic age diagnostics. *Int J Legal Med* 2006;120:15-7.
  15. Dogan H, Veldkamp WJ, Dibbets-Schneider P, Spijkerboer AM, Mertens BJ, Kroft LJ, *et al.* Effects of heart rate, filling and slice thickness on the accuracy of left ventricular volume measurements in a dynamic cardiac phantom using ECG-gated MDCT. *Br J Radiol* 2008;81:577-82.
  16. Guggenbuhl P, Chappard D, Garreau M, Bansard JY, Chales G, Rolland Y. Reproducibility of CT-based bone texture parameters of cancellous calf bone samples: Influence of slice thickness. *Eur J Radiol* 2008;67:514-20.
  17. Rubinstein D, Escott EJ, Mestek MF. Computed tomographic scans of minimally displaced type II odontoid fractures. *J Trauma* 1996;40:204-10.
  18. Jung H, Kim HJ, Kim DO, Hong SI, Jeong HK, Kim KD, *et al.* Quantitative analysis of three-dimensional rendered imaging of the human skull acquired from multi-detector row computed tomography. *J Digit Imaging* 2002;15:232-9.
  19. Sirin Y, Guven K, Horasan S, Sencan S, Bakir B, Barut O, *et al.* The influence of secondary reconstruction slice thickness on NewTom 3G cone beam computed tomography-based radiological interpretation of sheep mandibular condyle fractures. *Oral Surg Oral Med Oral Pathol Oral Radiol Endod* 2010;110:638-47.