

## Malignant melanoma of the mandibular gingiva

Sandeep Fauzdar,<sup>1</sup> Dipesh D. Rao,<sup>1</sup>  
Kaneesh Karthik Arthanari,<sup>1</sup>  
Gopal Krishnan,<sup>1</sup>  
Venkatesh G. Naikmasur,<sup>2</sup>  
Manjunatha M. Revanappa<sup>2</sup>

<sup>1</sup>Department of Oral and Maxillofacial Surgery; <sup>2</sup>Department of Oral Medicine and Radiology, S.D.M. College of Dental Sciences and Hospital, Sattur, Dharwad, Karnataka, India

### Abstract

Oral malignant melanoma is an infrequent neoplasia making up less than 1% of all melanomas, which exhibits much more aggressive behavior than those found on the skin. We present an aggressive case of oral malignant melanoma located on the mandibular gingiva in a 24-year-old male patient, who developed metastases to not only the regional lymph nodes but also the lungs and liver. The advanced stage of the disease contraindicated any surgical intervention and palliative chemotherapy was planned.

### Introduction

Melanomas are malignant neoplasms arising from melanocytes, which originate from the neural crest. The cells and the corresponding neoplasms arising from the neural crest are grouped under Dispersed Neuro-Endocrine System (DNES) tumors. Melanomas are present primarily in the basal portion of the epidermis at the dermal-epidermal junction. Primary malignant melanoma has been described in virtually all sites and organ systems to where neural crest cells migrate.<sup>1</sup>

Over 90% of melanomas occur in the skin with slightly more than 1% of melanomas arising from mucosal surfaces.<sup>2</sup> Among mucosal malignant melanomas, the common site is the rectum and vulvo-vaginal regions. In the head and neck region, nasal and paranasal melanomas are three times more common than oral malignant melanoma (OMM).<sup>3</sup> Primary OMM is rare, representing 0.2-8% of all melanomas<sup>4</sup> and accounting for 0.5% of all oral malignancies.<sup>5</sup> This tumor is characterized by marked aggressive behavior that manifests by both local and distant metastases.<sup>6</sup> Males are affected three times as frequently as females are, with a mean age of 56 years at the time of diagnosis.<sup>7</sup> Maxillary gingiva and

palate are the most frequently affected sites in the oral cavity.<sup>3,7-9</sup>

In this paper we present a case report of a 24-year-old male patient referred to us with a painless, pigmented swelling on the mandibular gingiva, which was diagnosed clinically and histologically to be a primary malignant melanoma of the oral mucosa with metastases to the regional lymph nodes and to the liver and lungs.

### Case Report

A 24-year-old male patient reported to the Department of Oral Medicine with the complaint of a swelling in relation to the right lower molar teeth, present for nine months. Initially the patient had noticed the change in the color of the gums. Three months later he noticed a swelling in the same region. The patient did not consult anybody until he noticed the swelling gradually increasing in size. The swelling was asymptomatic.

Extra-orally, there was a diffuse swelling present over the region of the right mandibular angle, measuring 4×3 cms in size. The skin over the swelling appeared normal. On palpation, the swelling was non-tender and firm in consistency. Intra-orally, the swelling extended from the region of the lower left lateral incisor to the lower right second molar, crossing the midline. Both buccal and lingual gingivae were affected by the swelling. Its surface was lobulated with the brownish-black discoloration of the overlying mucosa (Figure 1). Considering the history and clinical examination, a differential diagnosis of Kaposi's sarcoma, malignant melanoma, or a giant cell lesion was made. A mandibular occlusal radiograph and an orthopantomogram were unremarkable. The routine blood investigations were found to be normal and

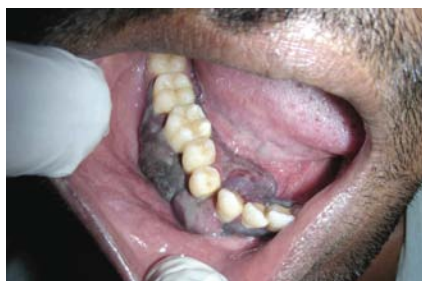

Figure 1. A large, intra-oral swelling is shown, extending from the region of the lower left lateral incisor to the right second molar, crossing the midline, with both the labial and lingual gingiva affected. The surface of the swelling appears lobulated with a brownish-black discoloration of the overlying mucosa.

Correspondence: Dipesh D Rao, Department of Oral and Maxillofacial Surgery, S.D.M. College of Dental Sciences and Hospital, Sattur, Dharwad, Karnataka – 580 009, India.  
E-mail: drdipesh.rao@gmail.com

Key words: oral malignant melanoma, melanoma, oral mucosa, oral pigmentation, mucosal melanoma.

Received for publication: 20 January 2010.  
Accepted for publication: 24 March 2010.

This work is licensed under a Creative Commons Attribution 3.0 License (by-nc 3.0).

©Copyright S. Fauzdar et al., 2010  
Licensee PAGEPress, Italy  
Rare Tumors 2010; 2:e25  
doi:10.4081/rt.2010.e25

the patient was non-reactive for HIV I and II. A biopsy was advised, which the patient refused to undergo.

Four-and-a-half months later, the patient returned to the hospital stating that one of his teeth on the right side of the lower jaw had exfoliated on its own and the adjacent teeth had become mobile. He also complained of pain associated with the swelling and loss of

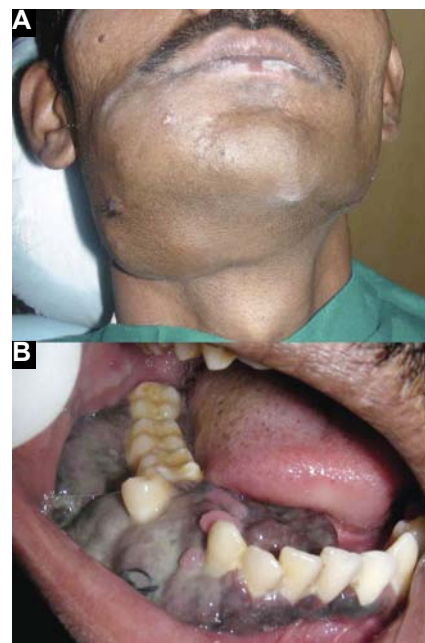
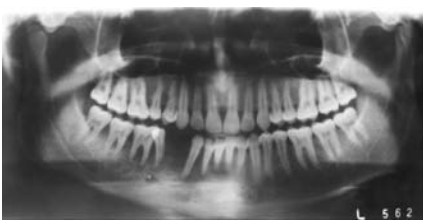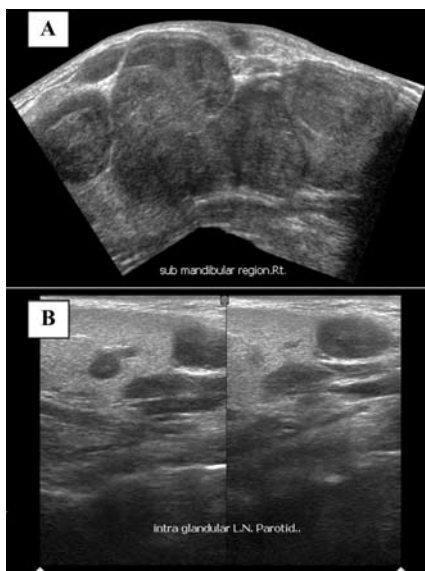


Figure 2. (A) The extra-oral swelling because of enlarged submandibular and jugulo-diaphragmatic groups of lymph nodes is illustrated. (B) The intra-oral swelling is seen to extend from the region of the lower left lateral incisor to the retro-molar trigone, and the lower right first premolar is missing, with the lower right second premolar displaced buccally.

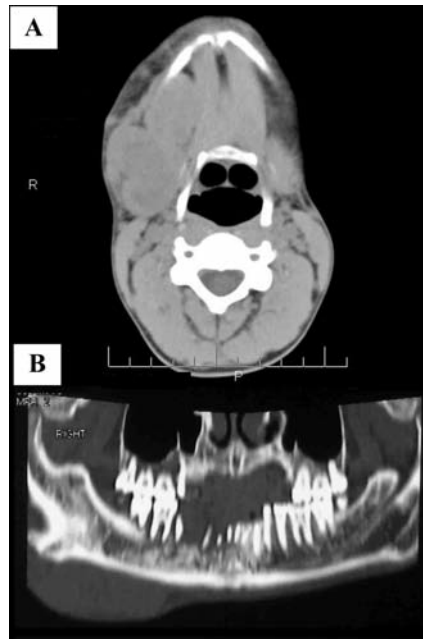


**Figure 3.** The orthopantomogram revealed a permeative pattern of bone destruction extending from the region of the lower right first molar to the lower left central incisor; loss of lamina dura in relation to the lower right quadrant, and the first premolar was missing whereas the canine exhibited a floating tooth appearance.



**Figure 4.** (A) Ultrasound scan of the neck indicates a large, irregular, lobulated, aggressive soft tissue lesion occupying the right sublingual and submandibular spaces and infra-hyoid anterior neck space. (B) Multiple, enlarged cervical lymph nodes in levels I, II, and the intra-parotid region are evident.

appetite for the past three months. On examination, a definite increase in the size of the swelling was found; this time it was 7×6 cm in size. The submandibular and jugulo-digastric group of lymph nodes were enlarged and palpable. They were firm and fixed to underlying structures (Figure 2A). Intra-orally, the swelling extended from the region of the lower left lateral incisor to the retro-molar trigone on the opposite side; the lower right first premolar was missing, and the second premolar was displaced buccally, and all the other teeth in that quadrant exhibited severe mobility (Figure 2B). The patient now agreed to undergo a biopsy. To establish the extent of the lesion and lymph node metastasis, ultrasound (US) and computerized tomography

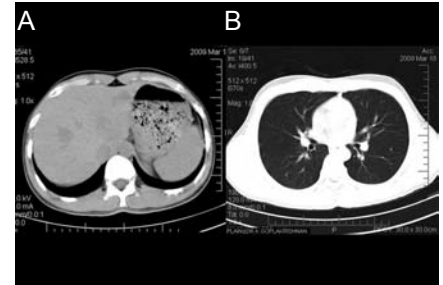


**Figure 5.** (A) Computerized tomographic scan of the neck shows evidence of a large, multilobulated, soft tissue mass occupying the right side of the anterior triangle, extending partially into the right half of face. (B) Permeative erosion in the right para-symphiseal region is illustrated in this orthopantomogram.

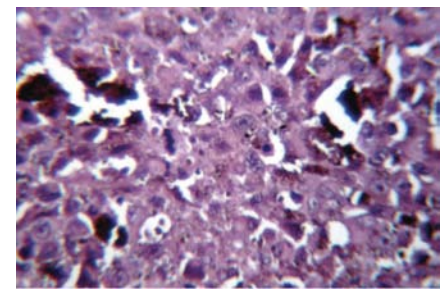
(CT) were performed in the head and neck region as well as the thorax. In addition, abdominal US was performed.

### Imaging findings

The orthopantomogram revealed a permeative pattern of bone destruction extending from the region of the lower left central incisor to the lower right first molar. There was also loss of the lamina dura in relation to the lower right quadrant, and the first premolar was missing whereas the canine exhibited a floating tooth appearance (Figure 3). The US scan of the neck was suggestive of multiple enlarged cervical lymph nodes in levels I, II, and the intra-parotid region, with predominant metastatic features (Figures 4A and B). The CT study of the neck revealed a large, irregular, lobulated, aggressive, soft tissue lesion occupying the right sublingual space, submandibular space, and infra-hyoid anterior neck space (Figure 5A). The lesion showed heterogenous attenuation. There were necrotic areas within the lesion. There was permeative erosion in the right para-symphiseal region (Figure 5B). The CT scan of the thorax and upper abdomen revealed nodular lesions involving the left lung and multiple, hypodense lesions involving both the lobes of the liver, suggestive of possible distant metastases (Figure 6A and B).



**Figure 6.** Computerized tomography scan of the thorax and upper abdomen, showing multiple hypodense lesions involving both the lobes of the liver (A) and nodular lesions involving the left lung (B), suggestive of possible distant metastases.



**Figure 7.** Microscopically the lesion was composed of sheets of discohesive, spindle-to-polygonal, pleomorphic cells with granular cytoplasm, hyperchromatic nuclei, and prominent nucleoli. Mitosis and melanin pigment is evident in a few cells, possibly melanocytes (hematoxylin and eosin stain; magnification 400X).

### Histopathology findings

Microscopically the lesion was composed of sheets of discohesive, spindle-to-polygonal, pleomorphic cells with granular cytoplasm, hyperchromatic nuclei, and prominent nucleoli. Mitosis and melanin pigment was evident in a few cells in the sheets, suggesting melanocytes (Figure 7). These histopathological findings were suggestive of malignant melanoma. Based on the clinical staging system for primary OMM, the present case was grouped under stage III.<sup>10</sup> Based on the extensive size of the lesion and the infiltration into the deeper structures and probable distant metastases, it was decided to put the patient on palliative care with chemotherapy. However, again he failed to report back.

### Discussion

Primary OMM is a very rare entity and represents 0.2-8% of all melanomas. The etiology of OMM is essentially unknown. It can occur



either owing to certain risk factors, like tobacco use and chronic irritation, or may arise *de novo*.<sup>5</sup> Our present case belonged to the latter group as he consumed neither tobacco nor alcohol. There was no source of chronic micro-trauma at the vicinity of the lesion.

Although OMM can occur at any age, it is extremely rare below 30 years of age. In a study of 74 patients by Shah *et al.* based on clinical findings, only one such case was reported.<sup>8</sup> In one of the retrospective studies of 35 cases of primary OMM, there were no patients below 30 years of age, with the mean age of presentation being 55 years old.<sup>4,9</sup> One-third of the patients with OMM are symptomatic at the time of diagnosis, and hemorrhage is the most common presenting symptom.<sup>11</sup> Our case reported to us with an asymptomatic swelling initially, and later with the complaint of tooth exfoliation.

In the oral cavity, malignant melanoma almost exclusively occurs in the palate and maxillary gingiva, with an incidence of 80% and 91.4%, respectively.<sup>3,9</sup> In a recent study of a series of 14 patients, none of the cases had malignant melanoma affecting the mandible.<sup>12</sup> Our patient is one of those rare cases as the site of occurrence was the mandibular gingiva. Lopez *et al.* identified five types of OMM on the basis of clinical appearance: pigmented nodular type, non-pigmented nodular type, pigmented macular type, pigmented mixed-type, and non-pigmented mixed type.<sup>11</sup> The lesion in our case was of the pigmented nodular type.

Various authors claim that biopsies that violate the tumor are detrimental to the treatment, whereas others insist that there is no evidence suggesting that a biopsy of a primary lesion increases the risk of metastatic dissemination or unfavorably affects prognosis.<sup>13</sup> Based on cellular composition, three different types of melanoma can be distinguished histologically: spindle cell, polygonal cell, and mixed cell varieties.<sup>1</sup> Without histopathology the diagnosis is not confirmative and the treatment would be empirical. Considering this, a biopsy was performed in our case, which was confirmative of the spindle cell variety of malignant melanoma.

The depth of invasion by mucosal melanomas has been studied by various authors with conflicting results. On one hand, few authors report that the prognosis of the mucosal melanoma is not influenced by the size of the primary lesion;<sup>7</sup> on the other hand, some authors report a survival rate of 30% in tumors having a thickness of <5 mm, dropping to 18% in tumors with >5 mm thickness, and to 10% in patients with tumor thickness >1 cm.<sup>8</sup>

Based on this our case would belong to the group of patients having 10% survival rate as the tumor thickness is more than 1 cm.

One reason for the poor prognosis of OMM is early invasion of the underlying tissue, increasing the likelihood of metastasis.<sup>13</sup> The average rate of distant metastasis is 10% at the time of presentation,<sup>9</sup> which depends on the time period from onset to definitive diagnosis. This has been found in various studies to vary from 1 to 30 months.<sup>2</sup> Diagnosis in our case was delayed by around 14 months because of the patient's reluctance to undergo a biopsy in his first visit. OMM is a highly aggressive tumor with a high mortality rate. The five-year survival rate for OMM ranges from 9.4-15.6% even after radical treatment, as compared to a 43-44% five-year survival rate of skin melanomas. The survival rate decreases parallel to the time that elapses from diagnosis to treatment.<sup>5</sup>

Green *et al.* proposed three criteria for the diagnosis of primary OMM: demonstration of malignant melanoma of the oral mucosa, presence of so-called junctional activity (i.e. the melanocytes are arranged along the basal layer of the surface epithelium) in the lesion, and the inability to show malignant melanoma in any other primary site.<sup>14</sup> Based on these criteria, our case was diagnosed as primary OMM.

The preferred treatment for OMM is ablative surgery, if the tumor is considered resectable. In the cases where metastasis has occurred, as in the case presented here, and/or where there are recurrences, the disease is considered as classically incurable, surgery being considered only for palliative care,<sup>6</sup> and other treatment modalities like radiotherapy and chemotherapy could be considered under the palliative care.

The reported prognosis of oral melanoma is poor, with a five-year survival of 0-55% of cases. The median survival for all oral mucosal melanomas is slightly more than two years from the time of diagnosis.<sup>4</sup> It depends on whether there is lymph node involvement (18 months) or not (46 months),<sup>5</sup> and worsens with distant metastasis. Our case had an extremely poor prognosis. Had the patient taken treatment in his first visit, the five-year survival rate probably could have been better. The present case presentation emphasizes the importance of early diagnosis, and patient counseling and management, which could improve the survival rate in patients with OMM.

## References

1. Pandey M, Abraham EK, Mathew A, et al. Primary malignant melanoma of the upper aero-digestive tract. *Int J Oral Maxillofac Surg* 1999;28:45-9.
2. Garzino-Demo P, Fasolis M, Maggiore GMLT, et al. Oral mucosal melanoma: a series of case reports. *J Cranio-Maxillofac Surg* 2004;32:251-7.
3. Eneroth CM. Malignant Melanoma of the Oral Cavity. *Int J Surg* 1975;4:191-7.
4. Chidzonga MM, Mahomva L, Marimo C, et al. Primary malignant melanoma of the oral mucosa. *J Oral Maxillofac Surg* 2007; 65:1117-20.
5. Meleti M, Leemans CR, Mooi WJ, et al. Oral malignant melanoma: a review of the literature. *Oral Oncol* 2007;43:116-21.
6. Martinez EA, Alonso FC, Siles MS, et al. Melanoma of the oral mucosa with cerebral metastasis: a clinical case. *Oral Oncol Extra* 2005;41:30-3.
7. Gorsky M, Epstein JB. Melanoma arising from the mucosal surfaces of the head and neck. *Oral Surg Oral Med Oral Pathol Oral Radiol Endod* 1998;86:715-9.
8. Shah JP, Huvos AG, Strong EW. Mucosal Melanomas of the Head and Neck. *Am J Surg* 1977;134:531-5.
9. Tanaka M, Mimura M, Ogi K, et al. Primary malignant melanoma of the oral cavity: assessment of outcome from the clinical records of 35 patients. *Int J Oral Maxillofac Surg* 2004;33:761-5.
10. Balch CM, Buzaid AC, Soong SJ, et al. New TNM melanoma staging system: linking biology and natural history to clinical outcomes. *Semin Surg Oncol* 2003;21:43-52.
11. Lopez-Graniel CM, Ochoa-Carrillo FJ, Menese-Garcia A. Malignant melanoma of the oral cavity: diagnosis and treatment experience in a Mexican population. *Oral Oncol* 1999;35:425-30.
12. Marco M, Rene CL, Wolter JM, et al. Oral malignant melanoma: The Amsterdam experience. *J Oral Maxillofac Surg* 2007;6: 2181-6.
13. Tanaka N, Nagai I, Hiratsuka H, et al. Oral malignant melanoma: long-term follow up in three patients. *Int J Oral Maxillofac Surg* 1998;27:111-4.
14. Greene GW, Haynes JW, Dozier M, et al. Primary malignant melanoma of the oral mucosa. *Oral Surg Oral Med Oral Pathol* 1953;6:1435-43.