



CASE REPORT

REVISED Case Report: First report of *Elizabethkingia miricola* infection in a patient with cystic fibrosis [version 2; referees: 2 approved, 1 approved with reservations]

Freddy Frost , Dilip Nazareth

Liverpool Heart & Chest Hospital, Liverpool, L14 3PE, UK

v2 First published: 10 Apr 2018, 7:440 (doi: 10.12688/f1000research.14441.1)
 Latest published: 08 May 2018, 7:440 (doi: 10.12688/f1000research.14441.2)

Abstract

Elizabethkingia miricola is a rare non-fermenting Gram-negative rod that has previously been reported to be associated with blood stream and pulmonary abscess infections, but never before in cystic fibrosis (CF). Here we present the first reported case of *Elizabethkingia miricola* infection in a patient with CF and discuss the management options. We describe a patient with CF in whom we observed clinical and spirometric evidence of pulmonary exacerbation with the associated growth of *E. miricola* in sputum culture. The period of clinical instability was observed to coincide with the obtainment of four sputum samples from which *E. miricola* was cultured; improvement was seen following treatment with ciprofloxacin and the subsequent eradication of *E. miricola*. We conclude that *E. miricola* is able to survive in the CF lung and in this case was associated with pulmonary exacerbation. Empirical treatment with fluoroquinolones is appropriate, based on our experience.

Keywords

Cystic fibrosis, shortness of breath, chest infection, exacerbation, fluoroquinolone

Open Peer Review

Referee Status:

	Invited Referees		
	1	2	3
REVISED			
version 2		report	report
published			
08 May 2018		↑	
version 1			
published	report	report	
10 Apr 2018			

- Simon C. Langton Hewer**, Bristol Royal Hospital for Children, UK
- Andrew M. Jones**, University Hospital of South Manchester, UK
- Jamie Duckers**, Cardiff and Vale University Health Board, UK

Discuss this article

Comments (0)

Corresponding author: Freddy Frost (freddy.frost@lhch.nhs.uk)

Author roles: **Frost F:** Conceptualization, Data Curation, Investigation, Writing – Original Draft Preparation, Writing – Review & Editing; **Nazareth D:** Conceptualization, Writing – Original Draft Preparation, Writing – Review & Editing

Competing interests: No competing interests were disclosed.

Grant information: The author(s) declared that no grants were involved in supporting this work.

Copyright: © 2018 Frost F and Nazareth D. This is an open access article distributed under the terms of the [Creative Commons Attribution Licence](#), which permits unrestricted use, distribution, and reproduction in any medium, provided the original work is properly cited. Data associated with the article are available under the terms of the [Creative Commons Zero "No rights reserved" data waiver](#) (CC0 1.0 Public domain dedication).

How to cite this article: Frost F and Nazareth D. **Case Report: First report of *Elizabethkingia miricola* infection in a patient with cystic fibrosis [version 2; referees: 2 approved, 1 approved with reservations]** *F1000Research* 2018, 7:440 (doi: [10.12688/f1000research.14441.2](https://doi.org/10.12688/f1000research.14441.2))

First published: 10 Apr 2018, 7:440 (doi: [10.12688/f1000research.14441.1](https://doi.org/10.12688/f1000research.14441.1))

REVISED Amendments from Version 1

In response to the reviewers' comments we have now included the following information:

- More information regarding the genotype and basis for diagnosis of CF
- Rationale for initial chloramphenicol treatment.
- Details regarding chronic inhaled antibiotics
- Details regarding the culture plates and conditions used
- Details regarding ABPA therapy and the relevance of oral corticosteroids in this case

See referee reports

Introduction

Elizabethkingia miricola, a non-fermenting Gram-negative rod (NFGNB) was first identified following isolation from condensation water in the Russian space laboratory Mir¹. Originally identified as belonging to the *Chryseobacterium* genus, it has since been re-classified and is closely related to *Elizabethkingia meningoseptica* (previously *C. meningosepticum*). *E. miricola* has been demonstrated to be pathogenic, with reports of bacteraemia resulting in sepsis and pulmonary abscesses^{2,3}. Here, we report the presence of *E. miricola* in the sputum of a patient with cystic fibrosis (CF). To our knowledge, this is the first reported case of *E. miricola* infection in CF. Herein, we discuss the case itself and the literature surrounding this bacterium to help guide clinicians faced with similar clinical scenarios.

Case report

A 49-year-old male with a diagnosis of CF presented to his routine CF outpatient department complaining of feeling generally unwell. He reported increased cough, but this was predominantly non-productive. There was a drop in lung function, from a baseline forced expiratory volume in one second (FEV1) of 2.39 l (65% of the predicted volume) to 2.19 l (60%

predicted). A sputum sample was obtained following chest physiotherapy and sent for routine culture on blood agar, chocolate agar, Sabouraud agar, Staphylococcus agar, m-Kleb agar and cepacia selective agar. Given the non-specific symptoms and mild drop in FEV1, it was agreed that no immediate treatment was required and a follow-up in 4 weeks' time was arranged.

Co-morbidities of the patient included osteoporosis and pancreatic insufficiency; he was also receiving maintenance treatment for allergic bronchopulmonary aspergillosis (ABPA) in the form of oral anti-fungal therapy and long-term low-dose oral corticosteroids. Cultured respiratory samples in the previous year had consistently grown non-epidemic *Pseudomonas aeruginosa*. The patient was receiving a continuous alternating inhaled anti-pseudomonal antibiotic regime in the form of tobramycin (TOBI 300mg BD) and aztreonam lysine (Cayston 75mg tds). The diagnosis of CF was made in adulthood and was based upon the presence of bilateral upper zone bronchiectasis on a chest CT scan and a raised sweat chloride level following a sweat test. Initial genetic testing revealed one copy of the F508del mutation, a second mutation was not identified despite extended screening. Family history included a younger sister who had died aged 23 years from pancreatitis. Serum immunoglobulin testing at the annual screen performed two months prior was within normal limits aside from a chronically raised IgG anti-aspergillus of 154 mg/L.

A sputum sample taken at the clinic appointment was positive for *P. aeruginosa*, and extended 10 day incubation on cepacia selective agar resulted in isolation of a cream coloured colony. The colony was identified as *Elizabethkingia miricola* by MALDI-TOF (matrix-assisted laser desorption/ionisation time-of-flight) mass spectrometry. At the next appointment, worsening symptoms were observed, including increasing shortness of breath, wheeze and productive cough. There was a further drop in FEV1 to 1.91 L (52% predicted) (Figure 1). An oral course of chloramphenicol (500 mg four times a day)

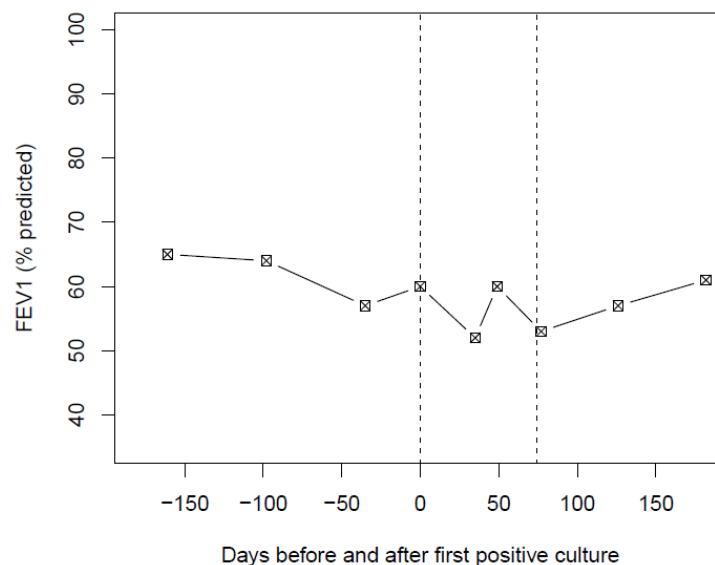


Figure 1. Lung function before and after positive sputum culture for *Elizabethkingia miricola*. Dotted lines represent the time period between which four sputum cultures were positive for *E. miricola*.

along with prednisolone (30 mg daily) for 2 weeks was commenced and a further sputum sample was obtained. Chloramphenicol was chosen empirically based on a previously observed clinical response to the agent and also patient preference to avoid ciprofloxacin due to skin photosensitivity. The sputum culture taken prior to treatment initiation was again positive for *P. aeruginosa* and *E. miricola*.

A further 4 weeks later, symptoms were somewhat improved and FEV1 had increased to 2.19 l (60% predicted). However, another 2 weeks later, symptoms deteriorated again, with an associated decline in lung function (FEV1, 1.95 l; 53% predicted). Sputum cultures from the previous encounter were again positive for *P. aeruginosa* and *E. miricola*. Sensitivities from previous samples revealed *E. miricola* resistant to meropenem and ceftazidime, but sensitive to piperacillin/tazobactam and ciprofloxacin (CIP). A 2-week course of oral CIP (750 mg thrice daily) was therefore commenced.

The patient noted an improvement in symptoms and at the next clinic appointment FEV1 had improved to 2.08 l (57% predicted). Sputum then grew *P. aeruginosa* and yeast only. A further four subsequent sputum samples 1, 4, 8 and 12 months later have grown *P. aeruginosa* but no *E. miricola*, and lung function returned towards baseline.

Discussion

Here, we describe an adult with CF in whom we observed clinical and spirometric evidence of pulmonary exacerbation, with associated growth of *E. miricola* in sputum culture. The period of clinical instability was observed to coincide with four sputum samples culturing *E. miricola* and improvement was seen with treatment. This is the first report of *E. miricola* in an individual with CF, meaning this report should therefore be relevant to all CF clinicians and microbiologists involved in the care of people with CF.

E. miricola has been described in a number of healthcare settings, but not previously in CF. One of the first reports of *E. miricola* infection was of positive growth in blood and sputum cultures of a septic patient whom had recently undergone a stem-cell transplant for mantle-cell lymphoma. Since then it has been reported in only a handful of cases, including septicaemia in a young patient with alcoholic pancreatitis and in the sputum of a septic patient with pulmonary abscesses^{2,3}. A degree of immunocompromise is a unifying feature in these cases, and the long-term oral corticosteroids required for treatment of ABPA in the present case may have predisposed to infection with *E. miricola*. However, more recently, *E. miricola* has also been identified as causing a UTI in an immunocompetent adult⁴.

All case reports of *E. miricola* infection mentioned above report identification by MALDI-TOF²⁻⁴. MALDI-TOF has been widely adopted for bacterial identification, facilitating diagnosis quickly and reliably. In the CF setting, MALDI-TOF has also been shown to be particularly useful in identifying non-fermenting gram-negative bacteria, for which classification can be difficult using conventional phenotypic approaches⁵. Given the increasing use of MALDI-TOF in clinical microbiology laboratories, identification of NFGNB infections is likely to rise. Hence, establishing the optimal initial management strategies for these infections is important.

In this case, initial empirical treatment with oral chloramphenicol did not clear the infection, but treatment with oral CIP (based on culture sensitivities) successfully treated the exacerbation. Eradication of *E. miricola* was also observed, with contemporaneous clinical improvement. Notably, the sputum culture sensitivities revealed that *P. aeruginosa* was resistant to CIP, further supporting the idea that *E. miricola* had a pathogenic role. Our experience of treatment with a fluoroquinolone is in keeping with that of previous reports, in which *E. miricola* bacteraemia has been associated with sensitivity to levofloxacin and/or CIP, both of which resulted in successful treatment^{2,6,7}. Susceptibility to co-trimoxazole (SXT) has also been reported, and it would seem that treatment with fluoroquinolones or SXT is an appropriate empirical strategy.

Conclusion

E. miricola appears to have the potential to grow in the CF lung and can be associated with pulmonary exacerbation. Given the paucity of information on *E. miricola* infection in CF, we hope that the case report and literature review herein are relevant to CF clinicians and microbiologists alike. Treatment based on culture sensitivity is recommended, but empirical treatment with fluoroquinolones may be an appropriate initial strategy if there is suspicion of pathogenicity.

Consent

Written informed consent for the creation and publication of this report was obtained from the patient.

Data availability

All data underlying the results are available as part of the article and no additional source data are required.

Competing interests

No competing interests were disclosed.

Grant information

The author(s) declared that no grants were involved in supporting this work.

References

1. Li Y, Kawamura Y, Fujiwara N, *et al.*: ***Chryseobacterium miricola* sp. nov., a novel species isolated from condensation water of space station Mir.** *Syst Appl Microbiol.* 2003; **26**(4): 523–8.
[PubMed Abstract](#) | [Publisher Full Text](#)
2. Green O, Murray P, Gea-Banacloche JC: **Sepsis caused by *Elizabethkingia miricola* successfully treated with tigecycline and levofloxacin.** *Diagn Microbiol Infect Dis.* 2008; **62**(4): 430–2.
[PubMed Abstract](#) | [Publisher Full Text](#) | [Free Full Text](#)
3. Gonzalez C, Coolen-Allou N, Allyn J, *et al.*: **[Severe sepsis and pulmonary abscess with bacteremia due to *Elizabethkingia miricola*].** *Med Mal Infect.* 2016; **46**(1): 49–51.
[PubMed Abstract](#) | [Publisher Full Text](#)
4. Gupta P, Zaman K, Mohan B, *et al.*: ***Elizabethkingia miricola*: A rare non-fermenter causing urinary tract infection.** *World J Clin Cases.* 2017; **5**(5): 187–190.
[PubMed Abstract](#) | [Publisher Full Text](#) | [Free Full Text](#)
5. Alby K, Gilligan PH, Miller MB: **Comparison of matrix-assisted laser desorption ionization-time of flight (maldi-tof) mass spectrometry platforms for the identification of gram-negative rods from patients with cystic fibrosis.** *J Clin Microbiol.* 2013; **51**(11): 3852–4.
[PubMed Abstract](#) | [Publisher Full Text](#) | [Free Full Text](#)
6. Rossati A, Kroumova V, Bargiacchi O, *et al.*: ***Elizabethkingia miricola* bacteremia in a young woman with acute alcoholic pancreatitis.** *Presse Med.* 2015; **44**(10): 1071–2.
[PubMed Abstract](#) | [Publisher Full Text](#)
7. Eriksen HB, Gumpert H, Faurholt CH, *et al.*: **Determination of *Elizabethkingia* Diversity by MALDI-TOF Mass Spectrometry and Whole-Genome Sequencing.** *Emerg Infect Dis.* 2017; **23**(2): 320–323.
[PubMed Abstract](#) | [Publisher Full Text](#) | [Free Full Text](#)

Open Peer Review

Current Referee Status:



Version 2

Referee Report 20 July 2018

doi:10.5256/f1000research.16111.r36139



Jamie Duckers

Cardiff and Vale University Health Board, Cardiff, UK

This is an interesting and well written case describing isolation of *Elizabethkingia miricola* in a patient with Cystic Fibrosis during a period of clinical deterioration.

The authors have addressed previous referees comments. I would add that there is a paper by Dervla et al. 2018 in Diagnostic Microbiology and Infectious disease which highlights the prevalence of an *E. miricola* cluster over other *Elizabethkingia* species among UK cystic fibrosis patients. However the paper by Dervla et al. concentrates on identification rather than clinical course and management which Frost et al. describe.

I would point out that in vitro sensitivity of *pseudomonas* will not always predict in vivo response and the ciprofloxacin used could have actually treated the *pseudomonas* as well as the *E. miricola* thus making it more difficult to be definitive that the clinical decline was entirely due to *E. miricola* and not the *pseudomonas*.

Is the background of the case's history and progression described in sufficient detail?

Yes

Are enough details provided of any physical examination and diagnostic tests, treatment given and outcomes?

Yes

Is sufficient discussion included of the importance of the findings and their relevance to future understanding of disease processes, diagnosis or treatment?

Yes

Is the case presented with sufficient detail to be useful for other practitioners?

Yes

Competing Interests: No competing interests were disclosed.

I have read this submission. I believe that I have an appropriate level of expertise to confirm that it is of an acceptable scientific standard.

Referee Report 08 May 2018

doi:10.5256/f1000research.16111.r33793



Andrew M. Jones

Manchester Adult Cystic Fibrosis Centre, University Hospital of South Manchester, Manchester, UK

The authors have revised the article and addressed all the comments satisfactorily.

Competing Interests: No competing interests were disclosed.

I have read this submission. I believe that I have an appropriate level of expertise to confirm that it is of an acceptable scientific standard.

Version 1

Referee Report 30 April 2018

doi:10.5256/f1000research.15719.r33065



Andrew M. Jones

Manchester Adult Cystic Fibrosis Centre, University Hospital of South Manchester, Manchester, UK

This is the first case described as far as I am aware of Elizabethkingia mircola in a patient with cystic fibrosis. The authors describe isolation of Elizabethkingia mircola in association with clinical deterioration of a patient, and subsequent clinical improvement and eradication of the organism following quinolone therapy.

The report could be further improved by addressing the points below:

- The authors state in the first paragraph that the patient had a cough that was unproductive, but in contrast also state that a sputum sample was obtained.
- The report states that the patient was receiving treatment for ABPA; it is important to know what exactly the treatment was and in particular if this could have caused immunosuppression and lead to increased susceptibility to unusual infections.
- The authors state the patient was heterozygous for F508del; did they identify the other CF gene?
- The authors state Elizabethkingia mircola was isolated after extended incubation: what culture media was used and how long was the extended incubation before Elizabethkingia mircola was isolated?

Is the background of the case's history and progression described in sufficient detail?

Partly

Are enough details provided of any physical examination and diagnostic tests, treatment given and outcomes?

Yes

Is sufficient discussion included of the importance of the findings and their relevance to future understanding of disease processes, diagnosis or treatment?

Yes

Is the case presented with sufficient detail to be useful for other practitioners?

Yes

Competing Interests: No competing interests were disclosed.

I have read this submission. I believe that I have an appropriate level of expertise to confirm that it is of an acceptable scientific standard, however I have significant reservations, as outlined above.

Author Response 01 May 2018

Freddy Frost, Liverpool Heart & Chest Hospital NHS Foundation Trust, UK

We are grateful to Professor Jones for his time and review of our case-report. We have moved to clarify the points he has raised. In particular we have reviewed the electronic patient record and clarified that sputum sample was actually obtained by our physiotherapist. We have also expanded on the treatment for ABPA which did include low-dose oral corticosteroids and have discussed the relevance of this in our discussion.

We have confirmed that only one gene was present despite extended genotype screening, but highlighted the reasons for making a robust clinical diagnosis of CF. We have also confirmed that growth was seen on the cepacia selective plate.

Competing Interests: Author of case-report

Referee Report 23 April 2018

doi:10.5256/f1000research.15719.r33066



Simon C. Langton Hewer

Paediatric Respiratory Medicine, Bristol Royal Hospital for Children, Bristol, UK

I agree that this appears to be the first report of this organism in CF and as such this is a relevant and important article and so should be published. The Case Report para 2 states the patient was heterozygous for CFTR mutation F508del but does not give the other mutation. Readers (including me) would be interested to know the second mutation so this should be stated.

Para 4 states treatment of *P. aeruginosa* and *E. miricola* took place with oral chloramphenicol. This is an unusual choice as *P. aeruginosa* would usually be treated with ciprofloxacin or IV therapies and/or nebuliser amino glycoside. It would be helpful to know why chloramphenicol was chosen and whether any neb antibiotics were used as well (which is likely the case).

These details should be included to give a more complete picture of the case.

Is the background of the case's history and progression described in sufficient detail?

Partly

Are enough details provided of any physical examination and diagnostic tests, treatment given and outcomes?

Yes

Is sufficient discussion included of the importance of the findings and their relevance to future understanding of disease processes, diagnosis or treatment?

Yes

Is the case presented with sufficient detail to be useful for other practitioners?

Yes

Competing Interests: No competing interests were disclosed.

I have read this submission. I believe that I have an appropriate level of expertise to confirm that it is of an acceptable scientific standard, however I have significant reservations, as outlined above.

Author Response 24 Apr 2018

Freddy Frost, Liverpool Heart & Chest Hospital NHS Foundation Trust, UK

We are very grateful to Dr Langton-Hewer for his review and comments. In response to Dr Langton-Hewer's comments:

- Only one gene was identified despite extended testing. The diagnosis of CF was made based on one gene, raised sweat test, upper lobe bronchiectasis and family history. We have now included more detail with regard to this point.
- Oral chloramphenicol was chosen empirically based on previous response and the patients desire to avoid photosensitivity associated with ciprofloxacin. We have now included more detail in the manuscript.
- Nebulised therapy included Cayston and TOBI, these were continued throughout and we have now included this detail within the manuscript

Competing Interests: Author of case-report

The benefits of publishing with F1000Research:

- Your article is published within days, with no editorial bias
- You can publish traditional articles, null/negative results, case reports, data notes and more

- The peer review process is transparent and collaborative
- Your article is indexed in PubMed after passing peer review
- Dedicated customer support at every stage

For pre-submission enquiries, contact research@f1000.com

F1000Research