

## Case report

# Rupture of a duodenal stromal tumor during EUS-FNA: a case report

Wen Liu, Siyu Sun\*, Nan Ge, Sheng Wang, Xiang Liu, Guoxin Wang, Jintao Guo

Endoscopy Center, Shengjing Hospital, China Medical University, Liaoning Province, China

## Introduction

Endoscopic ultrasound-guided fine-needle aspiration (EUS-FNA) has been in use for 20 years.<sup>1</sup> Owing to its high degree of accuracy and generally low incidence of complications,<sup>2</sup> this technique has gained wide acceptance as a diagnostic and therapeutic tool. While complications such as hemorrhage, perforation, and infection occur infrequently, we recently observed rupture of a duodenal stromal tumor during EUS-FNA. Details of this incident are described herein.

## Case report

A 71-year-old female presented with abdominal pain, for which esophagogastroduodenoscopy (EGD) was performed. Subsequently, a smooth, protuberant mass of descending duodenum was found (**Figure 1A**). By endoscopic ultrasound (EUS), performed at Shengjing Hospital, the lesion was homogeneous and hypoechoic, and measured approximately 36 mm x 35 mm (**Figure 1B**). No internal vessels or blood flow was detectable. Due to its size and indistinct margins, the site of origin was also difficult to ascertain. EUS-FNA was thus elected.

A linear echo endoscope (EG3630, Pentax, Tokyo, Japan) and a 22-gauge needle (Echo Tip Ultra, Cook Endoscopy, Winston-Salem, North Carolina, USA) were used to access the mass. After lesion the needle was inserted (under EUS guidance) into the targeted tissue (**Figure 1C, D**), the stylet was completely withdrawn by carefully retracting the plastic hub housed in the needle handle. A syringe (prepped in advance) was attached by way of Luer lock to the fitting on the needle handle, and its stopcock was turned to the "open" position (aligned with the syringe), 10 cc of negative pressure was allowed

in the syringe for aspiration of cells. Guided by EUS, the needle handle was moved back and forth gently in small increments. The tissue had been penetrated several times, when a hyperechoic line was noted in the needle track (**Figure 1E**). Thereafter, a 10 mm x 7 mm cystic area materialized within the mass, and hyperechoic flow was noted (**Figure 1F**). In a matter of seconds, the cystic zone grew to roughly 25 mm x 20 mm, and the entire mass expanded to 62 mm x 40 mm (**Figure 1G, H**). Because hemorrhage within the mass was likely, the procedure was halted, and the patient was hospitalized.

Two hours afterwards the patient complained of severe abdominal pain, later developing diffuse abdominal rigidity and guarding. Non-coagulated blood was withdrawn by abdominocentesis. By contrast-enhanced computed tomography (CT), the mass of descending duodenum was now measured 81 mm x 62 mm. Its appearance bordered on high-density, with a low-density mass inside (**Figure 2**). Findings were suggestive of rupture, accompanied by hematocele, accumulated exudate, and ascites.

Four hours following EUS-FNA, emergency surgery was performed, and the clinical impressions were confirmed. The abdominal cavity contained approximately 1000 ml of blood. Consequently, the tumor was completely resected.

Immunohistochemical staining of the lesion was positive for CD-117, CD-34, and DOG-1 markers, as well as for smooth muscle actin. Positivity of Ki67 was <5%, and staining for Desmin was negative. A diagnosis of high-risk duodenal stromal tumor was ultimately rendered.

## Discussion

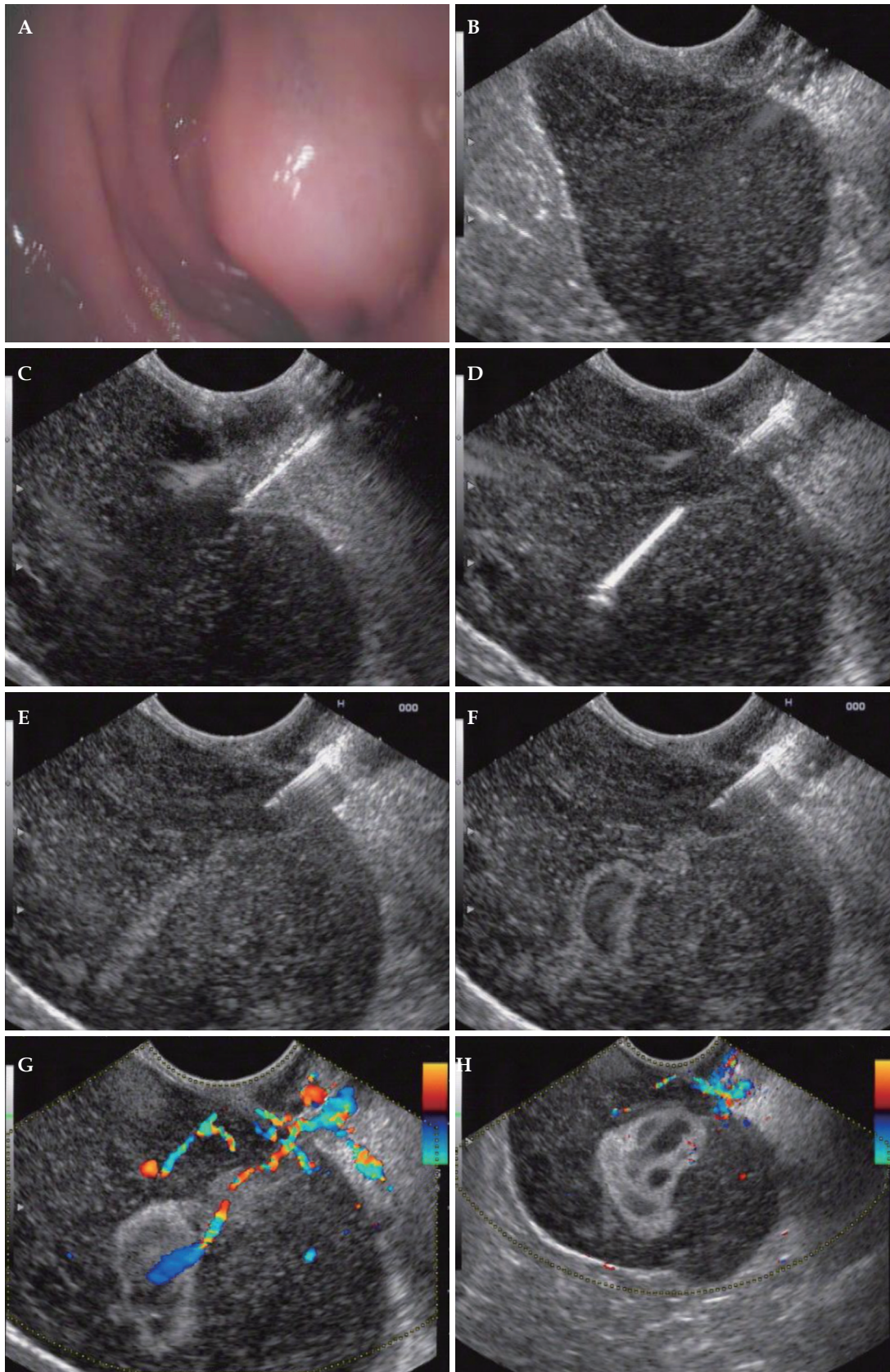
Gastrointestinal stromal tumors (GISTs) commonly arise in the upper digestive tract and are capable of malignant behavior.<sup>3-5</sup> EUS-FNA has become a staple in the evaluation of GISTs<sup>6,7</sup> owing to the generally low risk of related complications, such as hemorrhage, bacteremia,

\*To whom correspondence should be addressed.

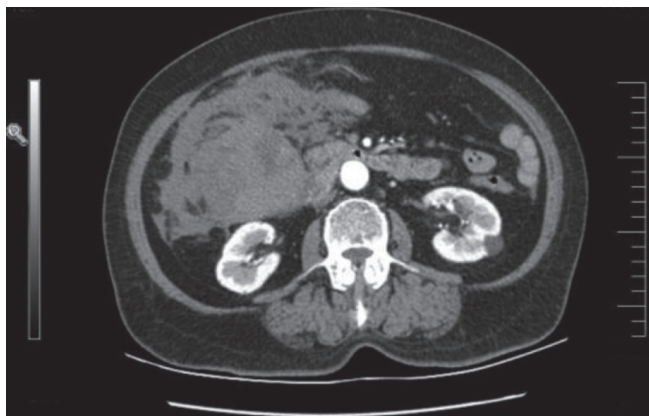
E-mail: sunsiyu@hotmail.com

Submitted: 2012-02-10; Received: 2012-02-15; Accepted: 2012-03-08

doi: 10.7178/eus.01.009



**Figure 1.** A: Smooth, protuberant mass of descending duodenum (EGD); B: Homogeneous, hypoechoic lesion (EUS), 36 mm x 35 mm; C, D: 22-gauge needle (EUS guided) piercing targeted tissue; E: Hyperechoic line in needle track upon aspiration; F: Immediate tumor expansion to 62 mm x 40 mm, with inner cyst, 10 mm x 7 mm; G, H: Hyperechoic flow of cyst (EUS).



**Figure 2.** Contrast-enhanced computed tomography (CT) image.

pneumoperitoneum, bacterial peritonitis, and perforation.<sup>8,9</sup> However, serious consequences may be resulted in whenever these tumors are breached. Use of FNA must therefore be judicious, supported by close follow-up observation and timely delivery of needed treatment.

With our patient, rupture of the tumor during EUS-FNA culminated in a medical emergency. Although ultrasonic Doppler scan disclosed no internal blood flow beforehand, the tumor precipitously expanded from 36 mm x 35 mm to 62 mm x 40 mm on aspiration, just as flow signals emerged. Within two hours, the patient developed peritonitis, and non-coagulated intra-abdominal blood was withdrawn to confirm tumor rupture. We believe that the sudden increase in pressure from hemorrhage may have triggered this event. As a precautionary measure,

thorough EUS examination (including ultrasonic Doppler) should precede every FNA; and FNA itself should be conducted with great care. Close EUS monitoring during and after the procedure is mandatory. If any flow signal in the tumor appears, FNA has to be halted. Once rupture is established, it should be dealt with immediately.

## References

1. Vilmann P, Jacobsen GK, Henriksen FW, *et al.* Endoscopic ultrasonography with guided fine needle aspiration biopsy in pancreatic disease. *Gastrointest Endosc* 1992; 38:172-3.
2. Kida M, Araki M, Miyazawa S, *et al.* Fine needle aspiration using forward-viewing endoscopic ultrasonography. *Endoscopy* 2011; 43:796-801.
3. Sun S, Jin Y, Chang G, *et al.* Endoscopic band ligation without electrosurgery: a new technique for excision of small upper-GI leiomyoma. *Gastrointest Endosc* 2004; 60:218-22.
4. Sun S, Ge N, Wang C, *et al.* Endoscopic band ligation of small gastric stromal tumors and follow-up by endoscopic ultrasonography. *Surg Endosc* 2007; 21:574-8.
5. Sun S, Ge N, Wang S, *et al.* EUS-assisted band ligation of small duodenal stromal tumors and follow-up by EUS. *Gastrointest Endosc* 2009; 69:492-6.
6. Akahoshi K, Sumida Y, Matsui N, *et al.* Preoperative diagnosis of gastro-intestinal stromal tumor by endoscopic ultrasound-guided fine needle aspiration. *World J Gastroenterol* 2007; 13:2077-82.
7. Turhan N, Aydog G, Ozin Y, *et al.* Endoscopic ultrasonography-guided fine-needle aspiration for diagnosing upper gastrointestinal submucosal lesions: a prospective study of 50 cases. *Diagn Cytopathol* 2011; 39:808-17.
8. Micames C, Jowell P, White R, *et al.* Lower frequency of peritoneal carcinomatosis in patients with pancreatic cancer diagnosed by EUS-guided FNA vs. percutaneous FNA. *Gastrointest Endosc* 2003; 58:690-5.
9. DeWitt J, LeBlanc J, McHenry L, *et al.* Endoscopic ultrasound guided fine needle aspiration of ascites. *Clin Gastroenterol Hepatol* 2007; 5:609-15.