

A prospective study comparing side-firing KTP laser enucleation vs bipolar transurethral resection of bladder tumor for small bladder tumors in an outpatient setting

Mahesh Chandra Tripathi¹, Pirzada Faisal Masood¹, Rajeev Sood¹, Anurag Singla¹, Nikhil Khattar², T Manasa¹, Rajpal Singh³

¹Department of Urology and Renal Transplant, Atal Bihari Vajpayee Institute of Medical Sciences & Dr. Ram Manohar Lohia Hospital, New Delhi, India

²Department of Urology, Medanta the Medicity, Gurugram, India

³Department of Anesthesia, Atal Bihari Vajpayee Institute of Medical Sciences & Dr. Ram Manohar Lohia Hospital, New Delhi, India

Citation: Tripathi MC, Masood PF, Sood R, et al. A prospective study comparing side-firing KTP laser enucleation vs bipolar transurethral resection of bladder tumor for small bladder tumors in an outpatient setting. Cent European J Urol. 2021; 74: 215-221.

Article history

Submitted: Jan. 18, 2021
Accepted: March 30, 2021
Published online: Apr. 10, 2021

Corresponding author

Anurag Singla
ORCID iD: 0000-0001-6055-3932
Atal Bihari Vajpayee
Institute of Medical
Sciences & Dr. Ram
Manohar Lohia Hospital
Department of Urology
and Renal Transplant
Baba Kharak
Singh Marg 31
110001 New Delhi, India
phone: +91 8527313464
eversmilinganurag@
gmail.com

Introduction Laser therapy provides an alternative option for treating non-muscle-invasive bladder cancer. The clinical evidence for potassium-titanyl-phosphate (KTP) laser en bloc resection is still limited. Here, we evaluated the efficacy, safety profile, and outcomes of side-firing KTP laser enucleation with bipolar transurethral resection of bladder tumor (TURBT) in carefully selected patients with small bladder tumors in an office setting.

Material and methods A total of 83 patients with small bladder tumors were treated with either side-firing KTP laser enucleation (Group A; n = 40) or bipolar TURBT (Group B; n = 43). Intraoperative and postoperative parameters of interest were recorded and analyzed as per the study so as to evaluate the efficacy, safety profile, and outcome of KTP laser enucleation.

Results The mean enucleation time was 23 ± 5.24 min in Group A and the mean operative time was 21.98 ± 4.77 min in Group B (p = 0.207). Group A had a lower risk of obturator reflex (0 vs 8; p = 0.005) and lesser amount of irrigation used intraoperatively as compared to Group B (6.2 ± 0.61 L vs 7.65 ± 0.75 L; p < 0.0001). There were no perioperative complications. The recurrence rate at 6 months was none in Group A and 2.3% in Group B.

Conclusions The present study shows that, in patients with small bladder tumors (<3 cm), KTP laser enucleation is an effective and feasible alternative to bipolar TURBT in an office setting and can be carried out safely with comparable treatment outcomes, lesser use of irrigation fluid and lower risk of obturator reflex. However, further studies in larger cohorts are warranted.

Key Words: KTP enucleation <> bladder cancer <> transurethral resection of bladder tumor

INTRODUCTION

Bladder cancer is the 9th most common cancer and 13th most common cause of death worldwide [1]. Smoking is the most common cause of urothelial cancer and accounts for 60% and 30% of all urothelial cancers in males and females, respectively [2]. At initial presentation, nearly 80% of patients present with superficial 'non-muscle-invasive' bladder cancers [3].

Currently the treatment of choice for superficial bladder tumor is transurethral resection of bladder tumor (TURBT). Retrieval of tissue for histologic evaluation is essential to the accurate staging and grading of bladder tumors [4]. While TURBT is still regarded as gold standard for the diagnosis of all bladder tumors and treatment of non-muscle invasive bladder tumors, its effectiveness is limited by the quality of the resection and by the limitations

of the technique. Consequently, TURBT is associated with high rates of tumor recurrence (50–70%) and under staging (34–62%) with detrusor muscle absent in 30 to 50% of specimens [5]. Among the various modifications, laser techniques have gained wide acceptance. Several studies have demonstrated the advantages of laser resection in safety and efficacy over TURBT. However clinical data of laser resection are still limited.

Various lasers used in bladder tumor include: Nd:YAG, KTP (potassium-titanyl-phosphate laser green light) laser and Holmium laser [6]. The use of a laser combined with endoscopic techniques allows en bloc enucleation of small bladder tumors [7, 8], allowing certain advantages in terms of better tissue yield and lower recurrence rates over conventional piecemeal resection [9]. They can be performed as outpatient procedures even in patients on anticoagulants. In contrast, an inadequate resection depth of the basal parts of tumors during TURBT to avoid bladder perforation may result in a higher recurrence rate [10]. In addition, it is easier to form encrustation when using electrocautery to stop bleeding during TURBT, which may result in tumor cells remaining in situ [11]. Some authors also believed that the recurrence rate of laser treatment for bladder tumors is lower than that of TURBT because of an active immune effect of the laser techniques [12].

Presently, there is limited data comparing bipolar TURBT and KTP laser enucleation of bladder tumor. The present study was undertaken to evaluate and compare the efficacy, safety profile and outcomes of bipolar transurethral resection and KTP laser enucleation of bladder tumor in carefully selected patients with small urinary bladder tumors in an outpatient setting [13].

MATERIAL AND METHODS

All patients presenting to our department with gross hematuria secondary to bladder mass were evaluated over a period of 2 years. After obtaining ethics committee approval and informed written consent, we included patients with primary or recurrent bladder tumor of size ≤ 3 cm in largest diameter and tumor number ≤ 3 on radiological/cystoscopic evaluation. Those with a history of prior irradiation, urethral stricture disease, double malignancy, tumor over the ureteric orifice and metastatic disease were excluded. All patients underwent a detailed clinical history, physical examination, relevant blood and urine investigations. An ultrasound of the kidney ureter and bladder region (KUB) was performed to assess the bladder mass size and location and to evaluate

the upper tracts. Contrast enhanced computed tomography (CECT) of the abdomen was performed as and when required. Only once a diagnosis of bladder mass was confirmed, all patients willing to be a part of the study were randomized by simple randomization with a sealed envelope 1:1 technique into Group A & Group B. Group A underwent en bloc resection/enucleation of bladder tumor with side firing KTP laser (120W) while bipolar TURBT was performed in Group B. All procedures were performed in an outpatient setting under the supervision of an experienced anaesthesiologist.

A pre-anesthetic evaluation was carried out prior to the procedure. All patients were admitted on the day of the surgery after fasting for 4–6 hours. Following an informed written consent, an intravenous antibiotic (3rd generation cephalosporin) was given followed by sedative analgesia in the lithotomy position. Sedation and anxiolysis was obtained with intravenous pentazocine (0.5 mg/kg) and promethazine (1 mg/kg). Local anesthesia included instillation of lignocaine jelly 2% into the urethra for a minimum of 10 minutes followed by infiltration of 1% lignocaine (100–200 mg) into the obturator nerve (LABAT technique) in those with lateral bladder wall tumor in both the groups [14].

For Group A, a continuous flow 21 Fr laser scope with a 30-degree lens was employed and 0.9% sodium chloride used as an irrigant. A 600-micron, side-firing laser fiber emitting green light at 532 nm was used and tumor tissue en bloc resection was performed. A circular mark was made about 1.0 cm away from the tumor edge using coagulation around the lesion initially. Adequate depth was reached until the underlying detrusor muscle layer was visible and the enucleated specimen was sent for histopathology en bloc (Figure 2). Group B patients underwent bipolar TURBT using a 24/26 Fr continuous flow resectoscope with loop electrode. The base of the resection zone was biopsied for pathological examination separately. On achieving complete hemostasis, 22 Fr triway catheter was inserted into the bladder and connected to 0.9% saline until clear effluent was seen.

Intraoperative factors assessed were operative time, amount of irrigation, requirements of any blood transfusion and intraoperative complications such as bleeding, obturator nerve reflex and bladder perforation. Mitomycin-C (40 mg) was instilled intravesically within 6 h of surgery. Patients were discharged once the urine was clear after catheter removal. An oral antibiotic (fluoroquinolone) was given for 3 days after catheter removal. All patients were followed up in the department after 2 weeks with a histopathology report. Restaging was done whenever needed within 2-6 weeks of primary resection as per the European

Table 1. Demographic profile of the study population across both groups

Parameter	Sub-parameters	Group A (KTP enucleation) (n = 40)	Group B (Bipolar TURBT) (n = 43)	p-value
Mean age (years)		55.62 ±12.75	56.12 ±12.11	.858
Sex	Males	32 (80%)	30 (70%)	.413
	Females	8 (20%)	13 (30%)	
Chief complaints	Hematuria alone	22 (55 %)	28 (65%)	.499
	Hematuria with LUTS	14 (35%)	10 (23%)	
	Growth on cystoscopy	4 (10%)	5 (11%)	
Comorbidity	No	30 (75%)	37 (86%)	.319
	Yes	10 (25%)	6 (14%)	
	COPD	1 (10%)	0	
	CAD with HTN	3 (30%)	1 (16%)	
	CVD with HTN	2 (20%)	1 (16%)	
	HTN only	3 (30%)	2 (33%)	
	DM	1 (10%)	2 (33%)	
Anti-coagulant	Yes	5 (12.5%)	2 (4.65%)	.254
	No	35 (87.5%)	41 (95.3%)	
Growth number	One	35 (87.5%)	36 (83.7%)	.839
	Two	4 (10%)	5 (11.67%)	
	Three	1 (2.5 %)	2 (4.65 %)	
Mean growth size (centimeters)		1.71 ±0.64	1.74 ±0.62	.819
Growth location	Lateral wall	10 (22%)	10 (19%)	.943
	Posterior wall	11 (24%)	12 (23%)	
	Postero-lateral wall	14 (30%)	18 (35%)	
	Posterior wall and trigone	5 (11%)	7 (13%)	
	Anterior wall only	1 (2%)	1 (2%)	
	Trigone only	5 (11%)	4 (8%)	
Upper tract	Hydroureteronephrosis absent	39 (97%)	42 (97.67%)	1
	Hydroureteronephrosis present	1 (3%)	1 (3%)	

KTP – potassium-titanyl-phosphate; TURBT – transurethral resection of bladder tumor; LUTS – lower urinary tract symptoms; COPD – chronic obstructive pulmonary disease; CAD – coronary artery disease; HTN – hypertension; CVD – cerebrovascular disease; DM – diabetes mellitus; n – number

Association of Urology (EAU) guidelines. Intravesical Bacillus Calmette–Guérin (BCG) and follow-up was done as per 2016 American Urological Association (AUA)/Society of Urologic Oncology (SUO) Guideline Suggested Surveillance Strategies.

Primary outcome: Quality of resected specimens with the presence of detrusor muscle and recurrence at 6,12 months.

Secondary outcome: How do the two procedures compare in terms of perioperative outcome?

Statistical analysis

The data analysis was done using SPSS version 21.0. Categorical variables were presented in number and percentage (%) and continuous variables were presented as mean ± standard deviation (SD) or median [interquartile range (IQR)]. Normality of data was tested by Kolmogorov-Smirnov test. If the normality was rejected then a non-parametric test was used. Statistical tests were applied as follows:

1. Quantitative variables were compared using independent t-test/Mann-Whitney Test (when the

data sets were not normally distributed) between the two groups.

2. Qualitative variables were correlated using Chi-Square test /Fisher's exact test.

RESULTS

A total of 280 patients presented to our department with primary or recurrent bladder tumor presenting with hematuria and/or lower urinary tract symptoms over a period of 2 years. Of these, 86 patients were found eligible and randomized by simple randomization with a sealed envelope 1:1 technique into Group A & Group B. Three patients in Group A opted out of the study (Figure 1). The demographic profile of the study population across both the groups were comparable, as shown in Table 1.

The mean operative time (surgical duration in minutes) was comparable between Group A and Group B (23 ±5.24 vs 21 ±4.77; p = 0.207). Group A had a lower rate of obturator reflex compared to Group B (0 vs 8; p = 0.005). Moreover, the mean intraoperative irrigation (in litres) was significantly lower

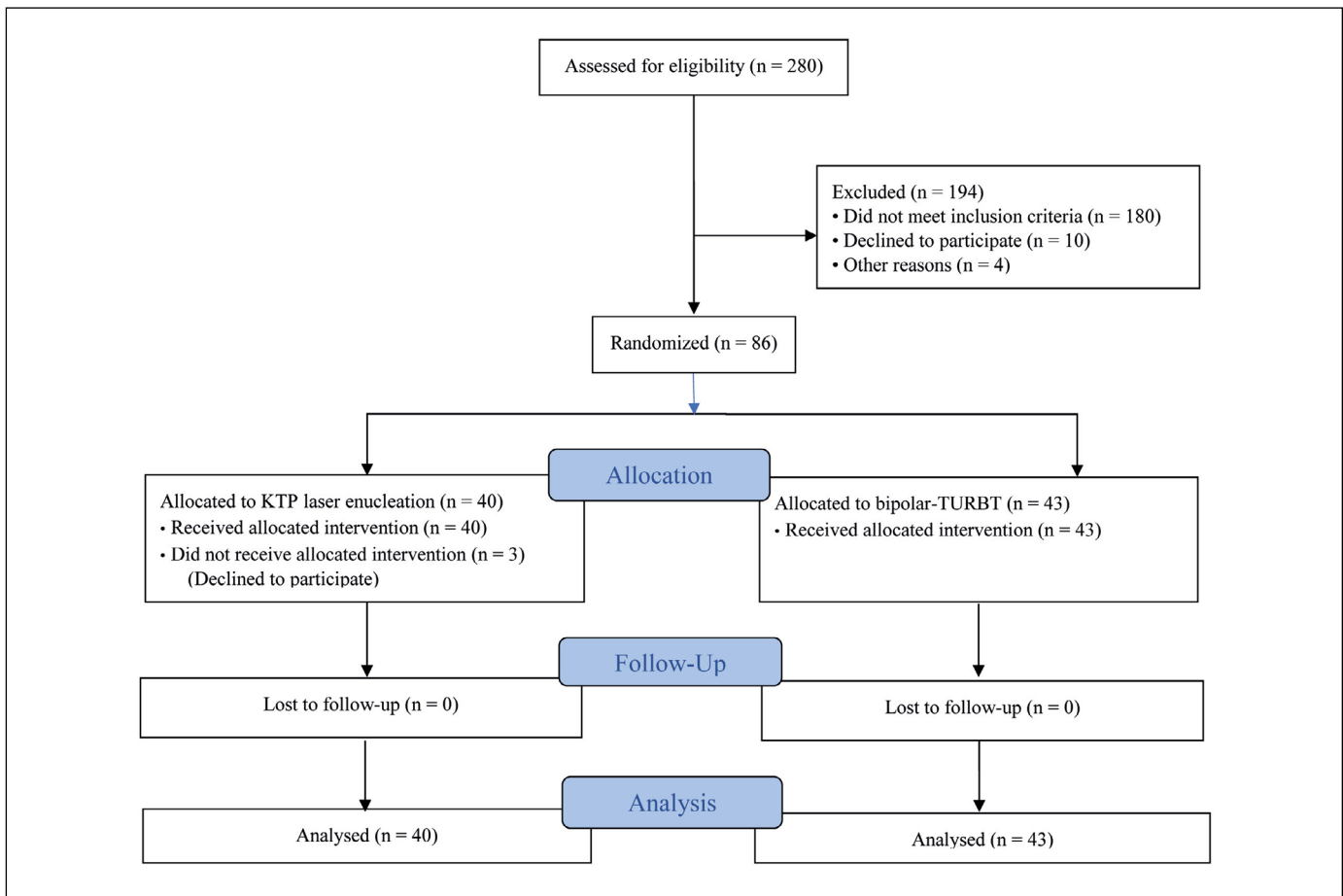


Figure 1. CONSORT diagram of the study.

in Group A as compared with Group B (6.2 ± 0.6 L vs 7.65 ± 0.75 L; $p < 0.0001$). However, the catheter duration and the mean duration of hospital stay (in hours) were not statistically significantly different between these two groups (Table 2).

In both groups, none of the patients experienced bladder perforation, required blood transfusion, re-catheterization or readmission. The distribution of histopathology of resected tumor tissues is summarized in Table 3 with no statistically significant difference across both groups. Presence of muscle in the histopathological specimen (Figure 3) was noted in 22 (55%) patients in Group A and 24 (55.8%) in Group B and was comparable ($p = .884$) (Table 3). Recurrence was noted on follow-up cystoscopy after 12 months in only 1 (2.32%) patient in Group B.

DISCUSSION

Superficial bladder cancers (non-muscle-invasive) comprise around 80% of the total bladder cancer patients for which TURBT currently remains the treatment of choice. The goal is to remove all visible

Table 2. Intraoperative and postoperative parameters in the two groups

Parameters	Sub-parameters	Group A (n = 40)	Group B (n = 43)	p-value
Operative time (in minutes)		23.38 \pm 5.24	21.98 \pm 4.77	.207
Irrigation fluid (Litres)	Intraoperative	6.2 \pm 0.61	7.65 \pm 0.75	<0.0001
	Postoperative	3.12 \pm 0.33	3.26 \pm 0.44	.131
Obturator reflex (yes)		0	8 (18%)	0.005

Table 3. Postoperative histopathology in the two groups

Histopathology	Group A (n = 40)	Group B (n = 43)	p-value
PUNLMP	5 (12.5%)	6 (14%)	0.971
Low-grade, LP invasion absent	17 (42.5%)	15 (34%)	
Low-grade, LP invasion present	13 (32.5%)	16 (37.2%)	
High-grade, LP invasion present	4 (10%)	5 (11%)	
High-grade, deep muscle invasion present	1 (2.5%)	1 (2.32%)	
Deep muscle present	22 (55%)	24 (55.8%)	0.884
Deep muscle absent	18 (45%)	19 (44.2%)	

PUNLMP – papillary urothelial neoplasm of low malignant potential; LP – lamina propria

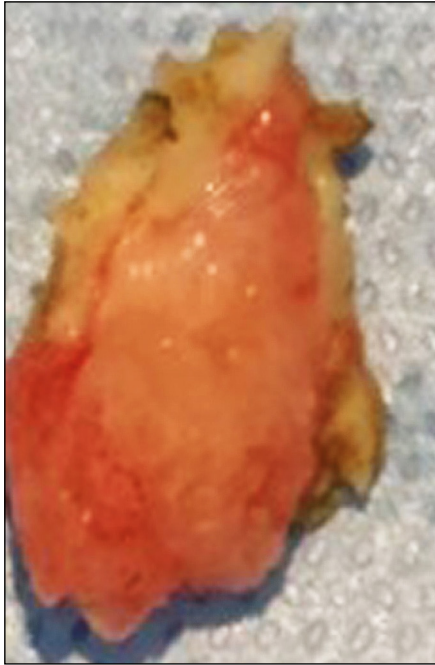

Figure 2. *En bloc potassium-titanyl-phosphate laser enucleated specimen.*

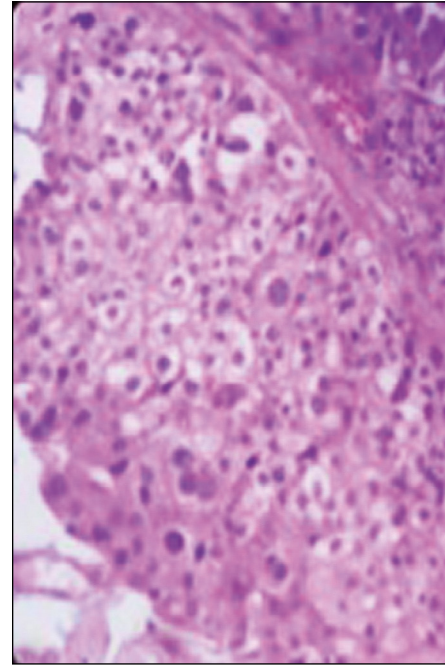


Figure 3. *Histopathology showing tumor with deep muscle.*

lesions and provide viable tissues for accurate pathological diagnosis [15]. Staging on TURBT specimens is often inaccurate due to their poor quality [16] resulting from piecemeal resection of tumors and charring of the resected tissues [17]. En bloc resection of bladder tumor was introduced so as to reduce recurrence rates due to complete tumor removal and reduction of tumor dispersal [18, 19]. En bloc resection technique provides better pathological evaluation for Ta and T1 tumors [20] as the detrusor muscle has been described to be absent in 30–50% of TURBT specimens at an initial resection [10, 21]. For this reason, en bloc enucleation was recently identified as a promising TURBT technique which can be done using an innovative resectoscope, snare resection technique and various lasers.

Among various lasers, Nd:YAG, KTP and Holmium:YAG have been used for en bloc resection of small bladder tumors. Use of laser en bloc enucleation of small bladder tumor has allowed various advantages over conventional piecemeal resection, such as better tissue yield, and lower recurrence and progression rates [21]. Lasers also achieve better haemostasis and thereby a good vision hence eliminating diathermy artefacts [22].

With advances in technology (like resection in saline and advent of lasers), the treatment procedures for superficial bladder cancer have become more safe owing to better haemostasis, less pain, shorter hospitalisation and catheterisation time. These properties

are also the prerequisites to perform the procedure in an outpatient setting, thus resulting in greater time efficiency and greater work output per day helping in reducing the waiting list [23]. Qubbaj et al. [24] reported similar results with outpatient procedures with the use of sedoanalgesia and concluded its safety in endourology procedures. Malik et al. [23] suggested that proper selection of the patient is needed for success of outpatient urological procedures and many patients with small, low-grade recurrences can be managed safely in the office setting with use of diathermy or laser ablation.

In this study we evaluated the efficacy, safety profile and outcomes of side-firing KTP laser enucleation with bipolar transurethral resection (TURBT) in carefully selected patients with small bladder tumours in an outpatient setting. In our study, the mean tumor diameter was 1.71 ± 0.64 cm in the KTP group and 1.74 ± 0.62 cm in the TURBT group and majority (>70%) of the tumors were located on lateral/posterolateral bladder wall. These findings correlated with the findings of similar other studies [25, 26, 27], where the mean size and location of the tumor were comparable to our cohort. None of our patient in the KTP group developed obturator reflex as compared to the TURBT group (18%). Also, there was significantly less use of irrigation fluid in the KTP group. These findings were also consistent with the findings of other studies [9, 25, 26, 27] where also, none of the patients in the KTP laser group developed obturator reflex.

The difference in the mean operative time (23 ± 5.24 min) in the KTP laser group in our study was statistically not significant compared with the bipolar TURBT group (21 ± 4.7 min) ($p = .207$) similar to Xu et al. [27]. However, this difference was statistically significant in studies by Chen and Cheng et al. [25, 26]. Overall, among the histopathology of all our 83 patients, papillary urothelial neoplasm of low malignant potential (PUNLMP) was present in 13.25% of the patients and low-grade and high-grade tumors in other 73.5% and 13.25% patients respectively. This was similar to the study by Chen et al. [26] where the respective figures were 12.6%, 73.4% and 13.9%. Only two of our patients were diagnosed as muscle-invasive bladder cancer. The probable reason of such a small number might be our inclusion criteria where we only included patients with small (<3 cm) and superficial bladder tumors. Muscle miss rate in our cohort was 45% in both the groups and the difference was not statistically significant ($p = 0.884$). This is in accordance with the TURBT literature where TURBT is associated with absence of detrusor in histopathology in 30–50% of specimen [22, 23] but not in accordance with KTP laser literature where Cheng et al. [26] noted a significantly lower muscle miss rate in the KTP group (2.94%). This discrepancy may be due to

the side-firing fibre used by us or may be due to our learning curve. However, further external validation in larger cohorts with a longer follow-up period is warranted.

CONCLUSIONS

The present study shows that, in patients with small bladder tumors (<3 cm), KTP laser enucleation is an effective and feasible alternative to bipolar TURBT and can be carried out safely as an outpatient procedure. Furthermore, the en bloc specimen can provide accurate assessment of tumor stage and is safe, associated with lower risk of obturator reflex and with smaller use of irrigation fluid. Tissue yield and treatment outcomes are comparable to bipolar TURBT. However, more studies with larger cohorts are required to further substantiate KTP laser enucleation and include it in the treatment protocol.

CONFLICTS OF INTEREST

The authors declare no conflicts of interest.

ACKNOWLEDGEMENT

We would like to thank Mr. Pankaj Chauhan who has helped us immensely in preparing the manuscript.

References

- Torre LA, Bray F, Siegel RL, Ferlay J, Lortet-Tieulent J, Jemal A. Global cancer statistics, 2012. *CA Cancer J Clin.* 2015; 65: 87-108.
- Anderson B. Understanding the role of smoking in the aetiology of bladder cancer. *Br J Community Nurs.* 2009; 14: 385-392.
- Kamat AM, Bağcıoğlu M, Huri E. What is new in non-muscle-invasive bladder cancer in 2016? *Turk J Urol.* 2017; 43: 9-13.
- Ramírez-Backhaus M, Domínguez-Escrig J, Collado A, Rubio-Briones J, Solsona E. Restaging transurethral resection of bladder tumor for high-risk stage Ta and T1 bladder cancer. *Curr Urol Rep.* 2012; 13: 109-114.
- Maruniak NA, Takezawa K, Murphy WM. Accurate pathological staging of urothelial neoplasms requires better cystoscopic sampling. *J Uol.* 2002; 167: 2404-2407.
- Pastuszek A, Zdrojowy R, Poletajew S, Adamowicz J, Krajewski W. Technical developments in transurethral resection of bladder tumours. *Contem Oncol.* 2019; 23: 195-201.
- Yang H, Lin J, Gao P, et al. Is the En Bloc Transurethral Resection More Effective than Conventional Transurethral Resection for Non-Muscle-Invasive Bladder Cancer? A Systematic Review and Meta-Analysis. *Urol Int.* 2020: 104; 402-409.
- Goonewardene SS, Persad R, Motiwala H, Albala D. Systematic Review- Results from En-Bloc Resection of Bladder Cancer. In: *Management of Non-Muscle Invasive Bladder Cancer.* Springer, Cham 2020; pp. 129-139.
- He D, Fan J, Wu K, al. Novel green-light KTP laser en bloc enucleation for non-muscle-invasive bladder cancer: technique and initial clinical experience. *J Endourol.* 2014; 28: 975-979.
- Mariappan P, Zachou A, Grigor KM. Detrusor muscle in the first, apparently complete transurethral resection of bladder tumour specimen is a surrogate marker of resection quality, predicts risk of early recurrence, and is dependent on operator experience. *Eur Urol.* 2010; 57: 843-849.
- Encina JO, Valdenebro AM, Gabarró JP, Sanz CR. Beyond the photodynamic diagnosis: Searching for excellence in the diagnosis of non-muscle-invasive bladder cancer. *Actas Urol Esp.* 2010; 34: 657-668.
- Bai Y, Liu L, Yuan H, et al. Safety and efficacy of transurethral laser therapy for bladder cancer: a systematic review and meta-analysis. *World J Surg Oncol.* 2014; 12: 301.
- Donat SM, North A, Dalbagni G, Herr HW. Efficacy of office fulguration for recurrent low-grade papillary bladder tumors less than 0.5 cm. *J Urol.* 2004; 171: 636-639.
- Moningi S, Durga P, Ramachandran G, Murthy PV, Chilumala RR. Comparison of inguinal versus classic approach for obturator nerve block in patients undergoing transurethral resection of bladder tumors under spinal anesthesia. *J Anaesthesiol Clin Pharmacol.* 2014; 30: 41-45.

15. Babjuk M, Burger M, Zigeuner R, et al. European Association of Urology. EAU guidelines on non-muscle-invasive urothelial carcinoma of the bladder: update 2013. *Eur Urol.* 2013; 64: 639-653.
16. Liang H, Yang T, Wu K, He D, Fan J. En bloc resection improves the identification of muscularis mucosae in non-muscle invasive bladder cancer. *W J Urol.* 2019; 37: 2677-2682
17. Sureka SK, Agarwal V, Agnihotri S, Kapoor R, Srivastava A, Mandhani A. Is en-bloc transurethral resection of bladder tumor for non-muscle invasive bladder carcinoma better than conventional technique in terms of recurrence and progression? A prospective study. *Indian J Urol.* 2014; 30: 144-149.
18. Maurice MJ, Vricella GJ, MacLennan G, Buehner P, Ponsky LE. Endoscopic snare resection of bladder tumors: evaluation of an alternative technique for bladder tumor resection. *J Endourol.* 2012; 26: 614-617.
19. Bach T, Muschter R, Herrmann TR, et al. Technical solutions to improve the management of non-muscle-invasive transitional cell carcinoma: summary of a European Association of Urology Section for Uro-Technology (ESUT) and Section for Uro-Oncology (ESOU) expert meeting and current and future perspectives. *BJU Int.* 2015; 115: 14-23.
20. Ayati M, Amini E, Damavand RS, et al. Second Transurethral Resection of Bladder Tumor: Is it Necessary in All T1 and/or High-Grade Tumors? *Urol J.* 2019; 16: 152-156.
21. Herr HW, Donat SM. Quality control in transurethral resection of bladder tumours. *BJU Int.* 2008; 102: 1242-1246.
22. Liang H, Yang T, Wu K, He D, Fan J. En bloc resection improves the identification of muscularis mucosae in non-muscle invasive bladder cancer. *World J Urol.* 2019; 37: 2677-2682.
23. Malik A, Ozair F, Ahsan A, Ahmad R. Sedoanalgesia for Day Case Urological Procedures-A view. *J Postgraduate Medical Institute (Peshawar-Pakistan).* 1997; 2: 130-132.
24. Qubbaj HS. Cystoscopy and TURBT using sedoanalgesia. Experience in 398 patients. *JRMS.* 2003; 10: 24-26.
25. Chen J, Zhao Y, Wang S, et al. Green-light laser en bloc resection for primary non-muscle-invasive bladder tumor versus transurethral electroresection: a prospective, nonrandomized two-center trial with 36-month follow-up. *Lasers Surg Med.* 2016; 48: 859-865.
26. Cheng B, Qiu X, Li H, Yang G. The safety and efficacy of front-firing green-light laser endoscopic en bloc photoselective vapo-enucleation of non-muscle-invasive bladder cancer. *Ther Clin Risk Manag.* 2017; 13: 983.
27. Xu Y, Guan W, Chen W, et al. Comparing the treatment outcomes of potassium-titanyl-phosphate laser vaporization and transurethral electroresection for primary nonmuscle-invasive bladder cancer: A prospective, randomized study. *Lasers Surg Med.* 2015; 47: 306-311. ■