



The Overall Number of Actinic Keratosis Lesions Is Not Predictable by the Number of Visible Lesions: Consequences for Field-Directed Therapies



Eggert Stockfleth, MD PhD¹, Nathalie Bégeault, MSc^{2,*}, Alain Delarue, MD²

¹Department of Dermatology, Ruhr-University Bochum, Bochum, Germany

²Pierre Fabre, Les Cauquillous, Lavaur, France

ARTICLE INFO

Article history:

Received 14 October 2021

Accepted 13 December 2021

Key words:

actinic keratosis
field cancerization
field-directed therapy
lesions

ABSTRACT

Actinic keratoses are keratotic lesions occurring on skin areas extensively damaged by sunlight. Using data from a previously published Phase III randomized, controlled clinical trial in patients with at least 5 actinic keratoses, we explored the potential link between the number of visible actinic keratosis lesions before any treatment and the total number of lesions of the field cancerization as revealed by 5-fluorouracil cream. Our analysis suggests that the baseline number of visible actinic keratoses is a poor indicator of the real number of lesions in the field of cancerization, reinforcing the need to explain the field cancerization concept to patients. (*Curr Ther Res Clin Exp.* 2022; 82:XXX–XXX) © 2022 Elsevier HS Journals, Inc.

© 2021 The Author(s). Published by Elsevier Inc.
This is an open access article under the CC BY-NC-ND license
(<http://creativecommons.org/licenses/by-nc-nd/4.0/>)

This communication provides details of an analysis to explore the potential link between the number of visible or palpable actinic keratosis (AK) lesions before any treatment and the total number of lesions of the field cancerization as revealed by a topical treatment.

AKs are keratotic lesions occurring on skin areas extensively damaged by sunlight.¹ They should be classified as in situ carcinomas that may lead to the development of invasive squamous cell carcinomas, with a likelihood of progression varying from 0.025 to 20%.^{2,3} The progression risk increases in patients with multiple (> 5) AKs.⁴

Although AK can occur as a single lesion, the more common clinical picture is multiple visible/nonvisible AKs within a chronically photodamaged area or field such as the front or scalp.⁵ The area is also influenced by subclinical (eg, nonvisible and nonpalpable) lesions, giving rise to the field cancerization concept; that is, a whole area affected by premalignant cells surrounding the visible lesions, and providing the rationale for field-directed therapies.^{5,6} So, it would be relevant to obtain a better estimate of the

total number of lesions in the field cancerization, not only those that are visible but also the subclinical lesions that are revealed by field-directed topical treatments.

We used data from a previously published Phase III randomized, controlled clinical trial in 841 patients with at least 5 AKs who received field treatment (4% 5-fluorouracil [FU] cream once daily vs 5% 5-FU cream twice daily, or corresponding vehicle, over 4 weeks) of the whole area of the face and/or ears and/or scalp.⁷ Full details of the Phase III trial have been published previously⁷; in brief, the evaluation of the number of lesions was the count of all visible and/or palpable AK lesions in the treatment area(s). At least 5 of the lesions counted at baseline had to measure ≥ 4 mm in longest diameter. AK lesions to be counted were those that were clinically typical nonhypertrophic and/or nonhyperkeratotic. None of the AK lesions could exceed 1 cm in size. Patients with any AK lesions within treatment areas that were hyperkeratotic or that were clinically suspected to be squamous cell carcinomas were excluded. The baseline location of each AK lesion was recorded on a diagram in the appropriate page of the case report form and the diagram served as a reference for all follow-up evaluations at all study visits.⁷ The **Table 1** shows the demographic and baseline characteristics of patients in each treatment group, with relevant data for the 4% 5-FU group discussed briefly: in the 4% 5-FU cream arm (n = 353), patients were predominantly men (81%), with phototype I through III (95%), and with a mean (SD) age of

* Address correspondence to: Nathalie Bégeault, Pierre Fabre, Les Cauquillous, F 81500 Lavaur, France.

E-mail address: nathalie.rouziq@pierre-fabre.com (N. Bégeault).

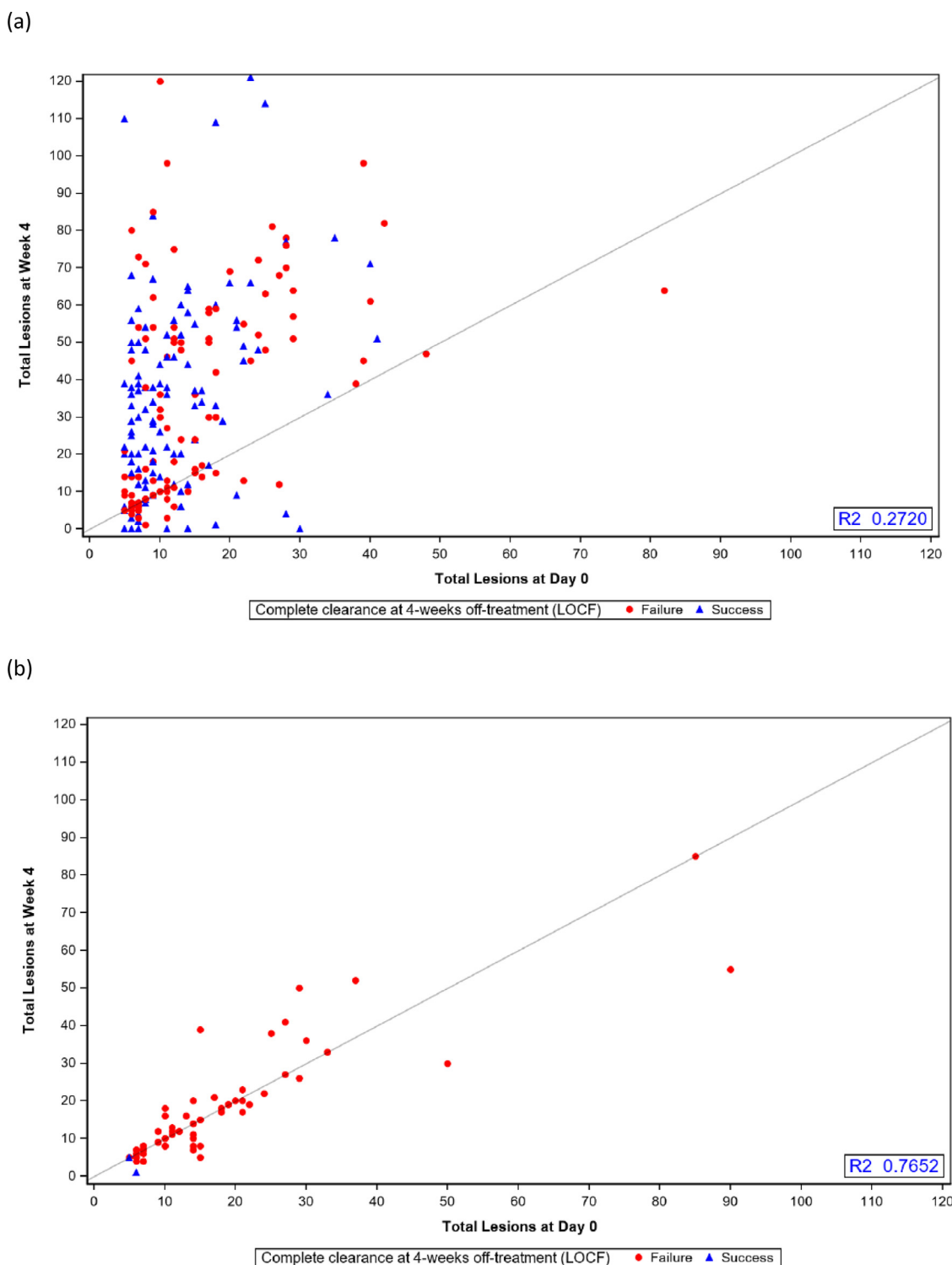


Figure 1. Scatterplot of success or failure for complete clearance at 4 weeks off-treatment, showing lesion numbers at baseline and at Week 4 (end of treatment) with (A) 4% 5-fluorouracil cream and (B) 4% 5-fluorouracil cream vehicle. LOCF=last observation carried forward.

67.7 (9.8) years (Table 1). Four percent 5-FU was applied on average for 26.5 days (range=2.0–35.0 days). For the 236 patients evaluated both at baseline and Week 4, the mean (SD) number of lesions at baseline was 13.8 (10.6), peaking at 34.8 (29.4) lesions at the end of treatment (EOT) (Week 4). Similar data were reported for the 5% 5-FU treatment group (Table 1).⁷

Overall, for the 4% 5-FU group, a higher number of lesions at baseline corresponded with a higher number of visible lesions at EOT, but with no specific trend ($r^2=0.2720$) when, in contrast, the correlation was good for the vehicle ($r^2=0.7652$) showing that the number of lesions counted at Week 4 is roughly the same as the number of lesions at baseline (see the Figure 1). In particular, with

Table 1
Demographic and baseline characteristics of the intention-to-treat population.^{7,*}

Characteristic	5-FU 4% cream	5-FU 5% cream	5-FU 4% vehicle cream	5-FU 5% vehicle cream
No. of patients	353	349	70	69
Age, y				
Mean (SD)	67.7 (9.8)	67.4 (10.0)	68.0 (10.1)	69.1 (12.1)
Range	36.7–88.9	37.6–94.1	47.7–84.8	37.6–88.4
Sex				
Male	287 (81)	282 (81)	58 (83)	55 (80)
Female	66 (19)	67 (19)	12 (17)	14 (20)
Race				
White	348 (99)	347 (99)	70 (100)	69 (100)
Other	5 (1)	2 (1)	0 (0)	0 (0)
Skin type				
I	84 (24)	91 (26)	13 (19)	18 (26)
II	178 (50)	155 (44)	35 (50)	33 (48)
III	75 (21)	80 (23)	19 (27)	15 (22)
IV	13 (4)	21 (6)	3 (4)	3 (4)
V	3 (1)	2 (1)	0 (0)	0 (0)
VI	0 (0)	0 (0)	0 (0)	0 (0)
No. of lesions at baseline				
Mean (SD)	14.4 (10.8)	14.8 (10.6)	16.2 (15.1)	14.7 (9.7)
Range	5.0–82.0	5.0–76.0	5.0–90.0	5.0–49.0
Baseline severity				
Mild (5–10 lesions)	171 (48)	154 (44)	31 (44)	30 (43)
Moderate (11–25 lesions)	138 (39)	162 (46)	29 (41)	31 (45)
Severe (>25 lesions)	44 (12)	33 (9)	10 (14)	8 (12)

5-FU = 5-fluorouracil.

* Values are presented as n (%) unless otherwise noted.

the active product, patients with fewer than 20 lesions at baseline could present a much higher number of lesions (up to 10 times more) at EOT. However, as shown in the [Figure 1](#), these data did not seem to influence the final results of the treatment assessed by the complete clearance rate at 4 weeks off of treatment. A similar trend was observed for the 5% 5-FU group and its vehicle ($r^2 = 0.1162$ and 0.3776 , respectively).

These results, based on data from a prospective randomized clinical trial, suggest that the number of visible AKs at baseline is a poor indicator of the actual number of lesions present in the field cancerization. Indeed, our analysis shows that, in field cancerization, there are nonvisible lesions that are revealed by 5-FU treatment (but not placebo), highlighting the fact that multiple sub-clinical lesions not visible at a simple clinical examination can be revealed by field-directed treatments for AK. This underlines the importance of treating the field cancerization using field-directed treatments for multiple AKs.⁸

Conclusions

These results are of clinical interest for further explaining to patients the field cancerization concept; that is, that the number of AKs to be treated in a field is usually much higher than only the visible lesions. If necessary, diagnostic imaging tools, such as line-field confocal optical coherence tomography or reflectance confocal microscopy, could be useful for convincing patients of the need to treat the whole field cancerization area. Furthermore, while undergoing treatment with 5-FU, patients could be reassured when seeing an increasing number of lesions and encouraged to remain compliant.

Declaration of Competing Interest

ES has received consulting fees, honoraria, payment for expert testimony, and support for attending meetings and/or travel from Avéne and Pierre Fabre; and has a leadership or fiduciary role in the Association of Dermatologic Oncology (ADO), European Association of Dermato Oncology (EADO), European Academy of Dermatology and Venereology (EADV), European Dermatology Forum

(EDF), and European Skin Cancer Foundation (ESCF). NB and AD are employees of Pierre Fabre.

Acknowledgments

The authors thank Clélia Cahuzac and Mélanie Groc, biostatisticians, Pierre Fabre, for their statistical assistance, and David P. Figgitt, PhD, ISMPP CMPP™, Content Ed Net, for providing editorial assistance, with funding from Pierre Fabre.

E. Stockfleth participated by providing his advice, assistance, and recommendations for this project of complementary analysis, by discussing the full results of this study, and reviewing the full article. A. Delarue participated by initiating this project of complementary analysis, by analyzing the results and figures, and in the preparation and the review of the article. N. Bégeault participated by initiating this project of complementary analysis, by analyzing the results and figures, and in the preparation and the review of the article. All authors approved the final manuscript for submission.

References

- Fleming P, Zhou S, Bobotsis R, Lynde C. Comparison of the Treatment Guidelines for Actinic Keratosis: A Critical Appraisal and Review. *J Cutan Med Surg*. 2017;21:408–417.
- Werner R, Sammain A, Erdmann R, Hartmann V, Stockfleth E, Nast A. The natural history of actinic keratosis: a systematic review. *Br J Dermatol*. 2013;169:502–518.
- Quaedvlieg PJ, Tirsi E, Thissen MR, Krekels GA. Actinic keratosis: how to differentiate the good from the bad ones? *Eur J Dermatol*. 2006;16:335–339.
- Marks R, Rennie G, Selwood TS. Malignant transformation of solar keratoses to squamous cell carcinoma. *Lancet*. 1988;1:795–797.
- Actinic Keratosis and Field Cancerization: New Insights [Internet]. Medscape. Available from: <https://www.medscape.org/viewarticle/774743> [cited 11 August 2021].
- Berman B, Cohen DE, Amini S. What is the role of field-directed therapy in the treatment of actinic keratosis? Part 1: overview and investigational topical agents. *Cutis*. 2012;89:241–250.
- Dohil MA. Efficacy, Safety, and Tolerability of 4% 5-Fluorouracil Cream in a Novel Patented Aqueous Cream Containing Peanut Oil Once Daily Compared With 5% 5-Fluorouracil Cream Twice Daily: Meeting the Challenge in the Treatment of Actinic Keratosis. *J Drugs Dermatol*. 2016;15:1218–1224.
- Stockfleth E. The importance of treating the field in actinic keratosis. *J Eur Acad Dermatol Venereol*. 2017;31(Suppl. 2):8–11.