



Contents lists available at ScienceDirect

## International Journal of Surgery Case Reports

journal homepage: [www.casereports.com](http://www.casereports.com)

# Right ectopic paraesophageal parathyroid adenoma with refractory hypercalcemia in pregnancy: A case report and review of the literature

Abdelrahman Abusabeib<sup>a</sup>, Harun Bhat<sup>b</sup>, Walid El Ansari<sup>c,d,e,\*</sup>, Mohamed S. Al Hassan<sup>a</sup>, Abdelrahman Abdelaal<sup>a</sup>

<sup>a</sup> Department of General Surgery, Hamad General Hospital, Hamad Medical Corporation, Doha, Qatar

<sup>b</sup> Weill Cornell Medicine in Qatar, Doha, Qatar

<sup>c</sup> Department of Surgery, Hamad General Hospital, Hamad Medical Corporation, Doha, Qatar

<sup>d</sup> College of Medicine, Qatar University, Doha, Qatar

<sup>e</sup> School of Health and Education, University of Skovde, Skovde, Sweden

## ARTICLE INFO

### Article history:

Received 2 October 2020

Accepted 20 October 2020

Available online 28 October 2020

### Keywords:

Ectopic parathyroid adenoma

Paraesophageal

Pregnancy

Primary hyperparathyroidism in pregnancy

## ABSTRACT

**INTRODUCTION:** Ectopic parathyroid adenoma is rare during pregnancy but poses multiple challenges in treatment. It presents as primary hyperparathyroidism which leads to symptoms and complications of hypercalcemia in both the mother and fetus.

**PRESENTATION OF CASE:** A 38-year-old Sudanese female presented with diffuse bone pain and polyuria. Laboratory investigations revealed elevated serum calcium and parathyroid hormone. Ultrasound of the neck did not show any abnormal lesion, however 99mTc-sestamibi scan showed a right sided parathyroid adenoma, and an earlier CT scan showed the adenoma to be in an ectopic paraesophageal position. Focused surgical neck exploration was done, and the ectopic parathyroid adenoma was excised.

**DISCUSSION:** Preoperative localization of the ectopic parathyroid adenoma allows for a focused surgical procedure. Ultrasound is the safest during pregnancy, but 99mTc-sestamibi and CT scan may be necessary if ultrasound or initial bilateral neck exploration do not detect any adenoma. Mild elevations in maternal serum calcium can have detrimental effects on the fetus which suggests that a surgical approach may be necessary in the majority of cases.

**CONCLUSIONS:** Ectopic parathyroid adenoma is rare during pregnancy and is detrimental to both the mother and fetus. Preoperative localization allows for a focused surgery which is a definitive treatment and can safely be performed during the 2nd trimester of pregnancy.

© 2020 The Author(s). Published by Elsevier Ltd on behalf of IJS Publishing Group Ltd. This is an open access article under the CC BY-NC-ND license (<http://creativecommons.org/licenses/by-nc-nd/4.0/>).

## 1. Background

The parathyroid glands (PG) are four small glands on the posterior aspect of the lateral lobes of the thyroid gland. The superior and inferior glands are usually symmetrical; however, their anatomical positions varies due to their lines of embryological descent from the 4th and 3rd branchial pouches respectively [1]. PG which deviate from normal positions are ectopic, and their location is related to the same origins of the parathyroid, thyroid, and thymic tissue [2]. The prevalence of ectopic parathyroid gland (EPG) ranges from 28–42.8% (autopsy series) to 6.3–16% (smaller series studies) [1]. For instance, others reported a 7% incidence of paraesophageal EPG [3,4].

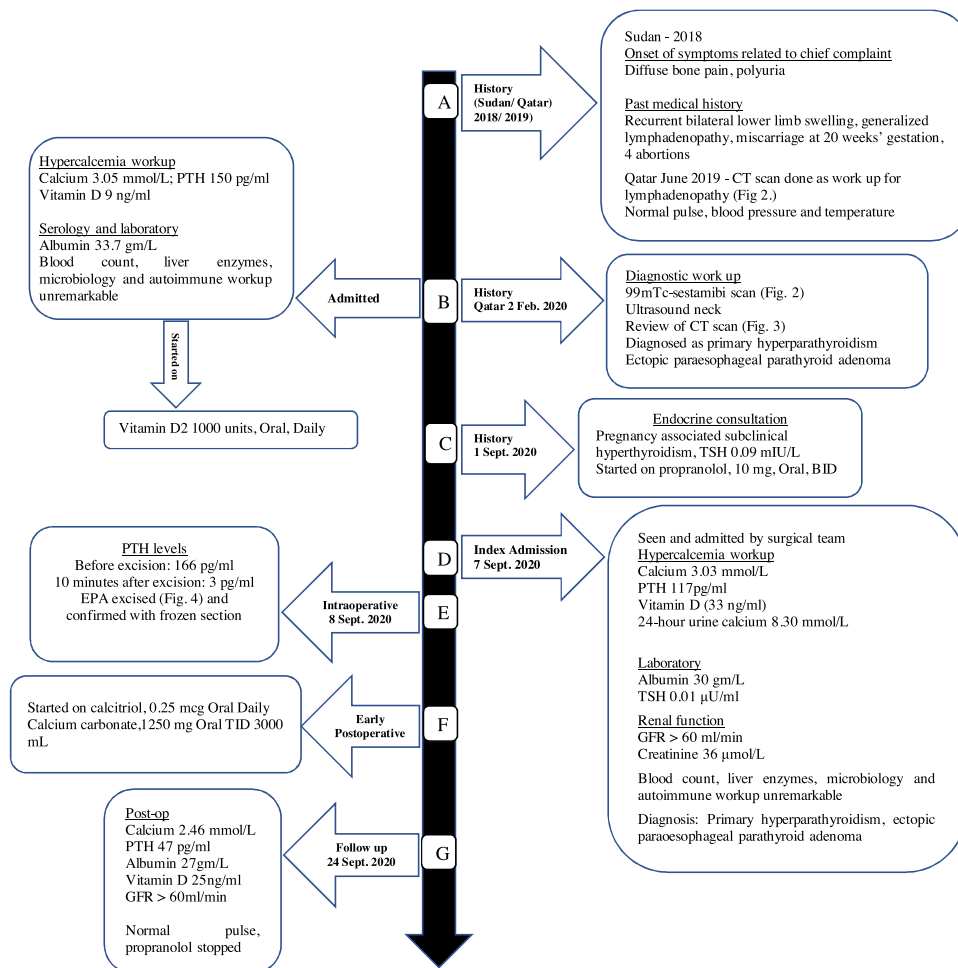
A primary pathology of the PG is a parathyroid adenoma (PA) resulting in primary hyperparathyroidism with refractory hyper-

calcemia. This is the third most common endocrine disorder worldwide [5], and females are affected as twice as males. Primary hyperparathyroidism in pregnancy, however, is rare, with 0.15–1.4% prevalence [6]. The initial presentation of primary hyperparathyroidism includes generalized fatigue, proximal weakness and increased frequency of urination, all of which can be mistaken to be part of the normal effects of pregnancy, therefore leading to a delayed diagnosis. In addition, maternal serum calcium may not be significantly elevated due to the physiologic effects of pregnancy that include decreased serum albumin levels and increased glomerular filtration rate [7].

During pregnancy, primary hyperparathyroidism needs to be diagnosed as early as possible in order to avoid the highly deleterious effects of hypercalcemia on the mother and developing fetus [8]. From the maternal side, very high serum calcium levels may present as hyperemesis, nephrolithiasis, recurrent urinary tract infection, and pancreatitis; as for the baby, there could be preterm delivery, low birth weight and fetal demise, as well as hypocalcemia

\* Corresponding author at: Department of Surgery, Hamad General Hospital, Hamad Medical Corporation, Doha, Qatar.

E-mail address: [welansari9@gmail.com](mailto:welansari9@gmail.com) (W. El Ansari).



**Fig. 1.** Timeline and sequence of events over 3 years. Normal values: Calcium (2.15–2.50 mmol/L), PTH (10–65 pg/mL), Albumin (35–50 g/L), Vitamin D (35–80 ng/mL), GFR (> 60 mL/min), Creatinine (44–97 µmol/L), 24-h urine calcium (2.50–7.50 mmol/L per 24 h), TSH (0.4–4.0 mIU/L).

and tetany (secondary to fetal parathyroid hormone suppression) in the immediate neonatal period [9,10].

To the best of our knowledge, this could be the seventh case globally and the second reported case from the MENA region (Middle East and North Africa) of primary hyperparathyroidism in pregnancy due to ectopic parathyroid adenoma (EPA). We report this case in line with the updated consensus-based surgical case report (SCARE) guidelines [11]. In addition, we undertook a literature review of EPA presenting during pregnancy.

**2. Case presentation**

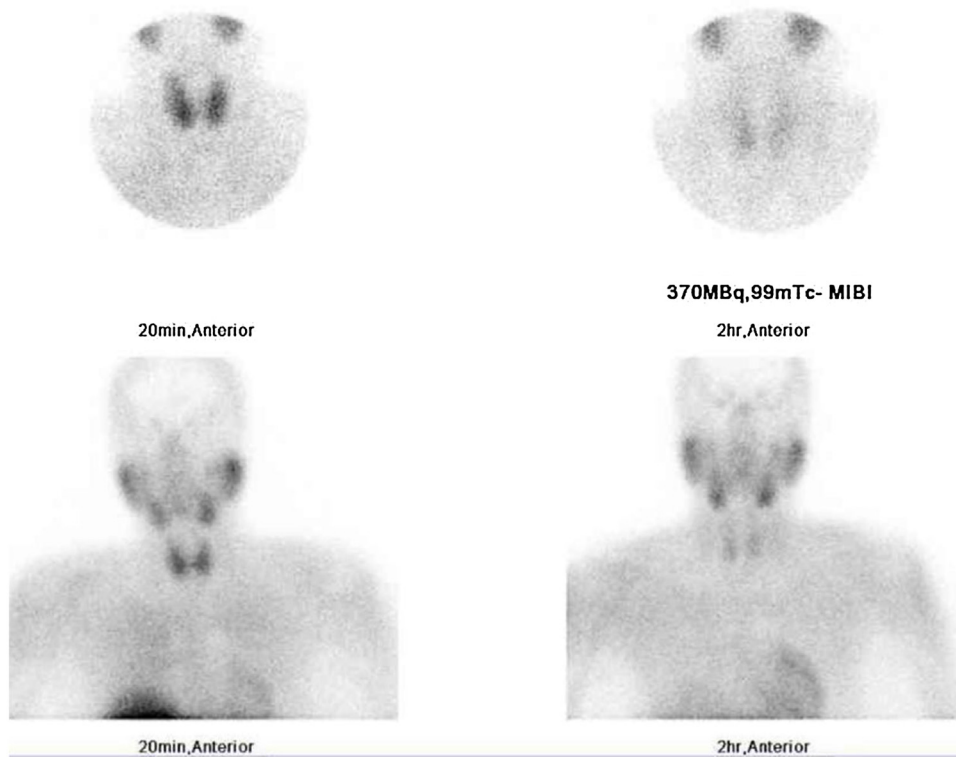
A 38 year old Sudanese female of 15 weeks gestation (gravida 9 para 4) came to our Thyroid Surgery outpatient clinic at Hamad General Hospital in Doha (largest tertiary care facility in Qatar), referred from obstetrics, with a 2 year history of generalized bone pain most prominent in the hands, palpitation, and increased frequency of urination. These symptoms gradually progressed in severity and were affecting her quality of life. She denied any nausea, vomiting, constipation or flank pain.

Past medical history (Fig. 1A) was significant for chronic generalized lymphadenopathy and recurrent lower bilateral lower limb swelling (possible lymphedema). Her last 5 pregnancies before the current pregnancy resulted in 4 abortions and a miscarriage at 20-week gestation, with no clear diagnosis. Family history, social history and review of systems were unremarkable. She did not

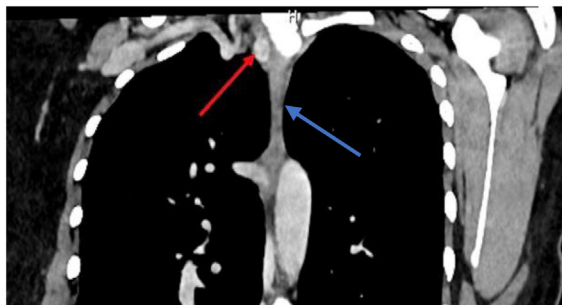
smoke tobacco and never consumed alcohol. Physical examination showed bilateral lower limb edema. The remainder of the physical exam was unremarkable. On admission, her pulse, blood pressure and temperature were within normal.

On initial admission to the medical team, a hypercalcemia workup was done (Fig. 1B). Serology and laboratory tests showed elevated corrected calcium and intact parathyroid hormone (PTH), and low vitamin D. Her complete blood count and liver enzymes findings were within normal limits and urinalysis, microbiology and autoimmune workups were unremarkable. A diagnosis of primary hyperparathyroidism was made which warranted imaging of the PG (Fig. 1B). Ultrasound (US) of the neck did not identify parathyroid lesions; an earlier 99mTc-sestamibi scan (sestamibi scan) undertaken before her current pregnancy (Fig. 2) revealed activity at the lower pole of the right thyroid lobe suggesting a right inferior PA; and, her CT scan taken a year earlier (Fig. 3) as work up for generalized lymphadenopathy showed an ectopic right inferior paraesophageal parathyroid lesion (7 mm diameter) impressive of right inferior PA.

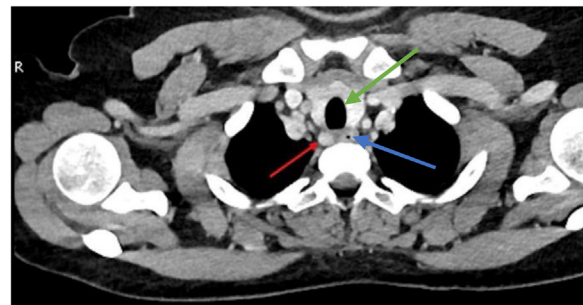
She was referred urgently to our thyroid surgery clinic, and was 18 weeks pregnant with hypercalcemia due to primary hyperparathyroidism associated with subclinical hyperthyroidism which was managed with beta blocker only (Fig. 1C). The patient was then seen and admitted to our surgical team (index admission, Fig. 1D). Apart from her high serum calcium and PTH, laboratory tests and renal function were within normal, and based on the previous ses-



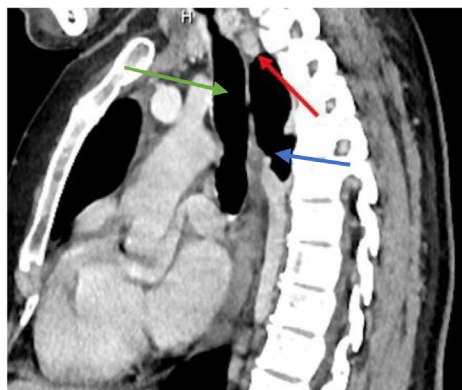**Fig. 2.** Early and late 99mTc-sestamibi scintigraphy parathyroid scan images of neck and mediastinum anteriorly at 20 min and 2 h showing increased focal uptake suggestive of right inferior parathyroid adenoma.



**A**



**B**



**C**

**Fig. 3.** **A** Coronal, **B** axial and **C** sagittal views CT scan of the neck showing the ectopic parathyroid adenoma (red arrow) located in a paroesophageal position, trachea (green arrow) and esophagus (blue arrow).

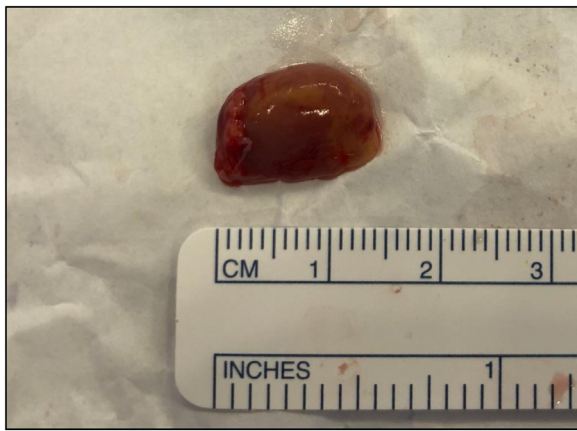

Fig. 4. Excised paraesophageal PA.

tambi scan and CT (Fig. 1B, and Figs. 2 and 3), the diagnosis of primary hyperparathyroidism due to EPA (paraesophageal) was confirmed.

The patient was admitted for urgent parathyroidectomy. Focused neck exploration by an experienced senior surgeon confirmed that the PG was not at its normal anatomical position, and that the PA was ectopic (paraesophageal), posterior to the recurrent laryngeal nerve. Frozen sections histologically confirmed PA, and intraoperative rapid PTH monitoring before excision and 10 min after excision of the PA, showed a serum PTH decrease by 98% (Fig. 1E) confirming the removal of the hypersecreting gland (Fig. 4). On the first postoperative day, the patient developed mild symptoms and signs of hypocalcemia, the laboratory findings revealed low intact PTH (1 pg/mL) and serum calcium (1.9 mmol/L), and she was given treatment (Fig. 1F). A week later, follow up at our thyroid surgery clinic revealed that the patient did not complain of any of the symptoms of hypercalcemia experienced prior to surgery, or symptoms of hypocalcemia that developed in the early postoperative period, and she had normal laboratory findings (Fig. 1G), and histopathology showed findings consistent with hypercellular parathyroid tissue, compatible with PA (1.5 × 0.7 × 0.4 cm) weighting 0.1 g.

### 3. Discussion

Calcium homeostasis during pregnancy avoids hypercalcemia and its complications in the mother and fetus. We report a rare case of a pregnant female with ectopic right paraesophageal PA leading to hyperparathyroidism and hypercalcemia. Such hypercalcemia might have been possibly responsible for her previous four successive abortions and one miscarriage in the period prior to her current pregnancy. Fetal PG develop after the first trimester, hence maternal serum calcium levels dictate calcium homeostasis in the fetus during this time [12]. Elevated maternal serum calcium results in fetal hypercalcemia [13], and as fetal PG develop, fetal hypercalcemia suppresses the fetal PG that predisposes the fetus to postpartum hypocalcemia once calcium delivery from the mother ceases after birth and the fetus is unable to mobilize calcium from the bones [14]. Our case demonstrates dysregulated calcium homeostasis evidenced by the mother's symptomatic presentation and previous abortions and miscarriage, possibly as a result of hypercalcemia.

Table 1 shows that our patient's presentation with polyuria agrees with cases identified in the literature review we undertook [15], but she had no renal complications e.g., nephrolithiasis and pyelonephritis, contrary to other reports [6,15,16]. Her complaint of bone pain was also not commonly reported by other

Table 1 Comparison of current case with other similar cases of ectopic parathyroid adenomas presenting in pregnancy identified in the literature review.

Current Case	Qatar	Triantafylidou 2018 Switzerland	Horton 2017 USA	Saad 2014 USA	McMullen 2010 Canada	Dinçer 2008 Turkey	Rooney 1998 Northern Ireland
Age	36	40	21	18	—	29	31
Symptoms, M <sup>a</sup>	Diffuse bone pain, polyuria	Nausea, hyperemesis	Headache, intractable vomiting, polydipsia	Polyuria, weakness, vomiting, nephrolithiasis, pyelonephritis	Renal calculi	Renal calculi	Abd pain, nausea, vomiting
Effects, F <sup>b</sup>	—	Nil	Nil	Nil	Nil	Convulsive attacks	Nil
S Ca	3.03	3.04	3.37	3.1	3.5	3.24	2.93
S PTH	117	120	191	204	236	2490	38
MisC <sup>c</sup>	1	0	0	0	0	0	0
Pre-op <sup>d</sup>	Y	N	N	N	N	N	N
Imaging	US, CT Sestamibi	18F-F PET/CT	4DCT Sestamibi	US Half-dose Sestamibi	Sestamibi	Sestamibi, SPECT, Spiral CT, MRI	MRI, CT
Location <sup>e</sup>	R paraesophageal	R middle Med	L Med	S P Med	Med level of AA	Thymus	AA within thymus
Surgical Procedure	Focused NE	TE after failed NE	VATP after failed NE	VATP	THc	TE	MS after failed CE
Trimester	2	2	2	2	2	**	2
Excision <sup>f</sup>	Y	N	Y	Y	Y	Y	Y

Due to space considerations, only first author is cited; <sup>a</sup> Symptoms in mother; <sup>b</sup> Effect on fetus; <sup>c</sup> Number of past miscarriages; <sup>d</sup> Pre-op: Preoperative localization; <sup>e</sup> Location of ectopic parathyroid gland; <sup>f</sup> Excision done during pregnancy. \*\*Not applicable because surgery performed after delivery; AA: Aortic arch; Abd: abdominal; CE: cervical exploration; L: left; Med: mediastinum; MRI: magnetic resonance imaging; MS: median sternotomy; N: No; NE: Neck exploration; P: Posterior; PET/CT: Positron Emission Tomography R: Right; S Ca: Serum calcium (mmol/L); S PTH: Serum parathyroid hormone (pg/mL); S: superior; SPECT: Sestamibi; 99mTc-sestamibi scan; Single-photon emission computed tomography; TE: thoracoscopic exploration; THc: Thoracotomy; Trimester: Trimester of pregnancy when surgery was performed; US: ultrasound; VATP: video assisted thoracoscopic parathyroidectomy; Y: Yes; — Computed Tomography, 18F-F: 18F-fluorocholine; — not reported.

authors (Table 1). About 67% of women with primary hyperparathyroidism have symptoms of hypercalcemia, e.g. nausea, vomiting and constipation, which are normal complaints during pregnancy [14,17]. In primary hyperparathyroidism during pregnancy, the early mild hypercalcemia can be difficult to diagnose due to two reasons: symptoms can be overlooked; and, normal physiologic responses (increased intravascular volume and glomerular filtration that lead to hemodilution and gestational hypoalbuminemia, hypercalciuria, and decreased total body calcium) can mask the hypercalcemia [14,18,19]. Despite such physiologic responses, our patient had high level of serum calcium (3.03 mmol/L). As for the investigations, our case demonstrates the importance of identifying EPA prior to surgery in order to prevent unsuccessful neck exploration and prolonged time of surgery. Preoperative localization of EPA avoids reoperation in > 95% of cases [20]. CT and sestamibi are harmful to the fetus, but our patient had the CT as a workup for her lymphadenopathy and had the sestamibi during her initial hypercalcemia workup, both before pregnancy. US is safe during pregnancy but is operator dependent (possible false negative findings), with 27–89% sensitivity for EPA detection [1]. We encountered such a false negative finding (US did not detect the EPA), in agreement with others [12] (Table 1). Localization of EPA in pregnancy is difficult, US is the imaging of choice, but further imaging may be required to localize the EPA. Sestamibi scan is useful for preoperative identification of EPA (80–99% sensitivity) [21], and it successfully identified our patient's PA but did not localize its ectopic position. In pregnancy, low dose sestamibi scan is unlikely to be detrimental [22]; and CT is contraindicated in pregnancy but may be used with appropriate abdominal shielding [6,23] (Table 1).

Combined imaging (sestamibi and CT) enhance the diagnosis, detecting the most abnormal glands [6]. Such combination after failed neck exploration can ensure success of the second surgery [6]. 18F-fluorocholine PET/CT may localize EPA in pregnancy after negative/equivocal US and/or scintigraphy/single-photon emission computed tomography (SPECT) [24]. A multidisciplinary team can select the appropriate imaging with the least harm to both the mother and fetus [25].

The 'true' EPA prevalence remains unconfirmed. In small studies of patients undergoing neck re-exploration, prevalence was 29–45% [1]. EPA can locate within the mediastinum as observed in Table 1 [6,12,15,16,24] or thymus [23].

Nephrolithiasis, bone disease, and pancreatitis complicate hypercalcemia due to primary hyperparathyroidism [17]. Post-delivery, the mother no longer provides the fetus, which exposes her to very high calcium levels (life threatening hypercalcemic crisis) [9,26]. Postpartum fetal hypocalcemia (convulsive attacks) with maternal bilateral nephrolithiasis have been reported [16] (Table 1). Fetal complications include fetal demise, low birth weight, preterm delivery, and depressed fetal parathyroid leading to postpartum neonatal hypocalcemia/tetany [9,14,27]. Our case had no complications: diagnosis was done at the index admission, and within two weeks, urgent surgery (EPA excision) was undertaken in the second trimester and follow up by obstetrician confirmed uneventful post-operative period for mother and fetus. This is in support of the importance of early suspicion and diagnosis prior to severe presentations, increased morbidity and mortality [8].

As for miscarriage, hyperparathyroidism is associated with 3.5 times increase in miscarriage [8]. Roughly > 50% of primary hyperparathyroidism in pregnancy is undiagnosed; 72% of pregnant women had hypercalcemia at miscarriage, suggesting delayed diagnosis; and serum calcium as low as 10.7 mg/dL led to miscarriage [8]. This warrants thorough investigations in order to exclude PHA-primary hyperparathyroidism. Due to our patient's history of overlap of previous abortions/miscarriage and symptoms of hypercalcemia, it is possible that the patient's primary

hyperparathyroidism (undiagnosed at that time) could have been responsible for her miscarriage in Sudan before we encountered her in Qatar. We are unable to confirm such speculation as the data is not available.

As for management, surgical procedures depend on the EPA's location (Table 1). We localized the EPA before surgery, and undertook right sided focused parathyroidectomy, which is as effective as bilateral neck dissection, but associated with better scars and patient satisfaction, and shorter operative time and hospital stay [28]. Other techniques include median sternotomy for mediastinal EPA [23], and less invasive video assisted thoracoscopic surgery [16].

A pregnant patient raises concerns about the safety of general anesthesia and surgery. The argument against parathyroidectomy due to teratogenic effects of general anesthesia may be overexaggerated [6] as modern-day anesthesia can be used safely in pregnancy [29,30]. In addition, surgery (parathyroidectomy) has much lower neonatal complications compared to conservative therapy [17,31]. Parathyroidectomy is safe when carried out by experienced surgeons [8], and surgery provides a curative treatment which removes the risks of maternal and fetal hypercalcemia as well as post-partum fetal hypocalcemia [31]. Conservative management (oral hydration and bisphosphonates) is sometimes recommended, although even mild hypercalcemia can lead to significant maternal complications and neonatal tetany [8,31]. The lack of a tightly defined relationship between serum calcium level and the ability to predict maternal or fetal complications suggests that mild hypercalcemia may still require definitive surgical management [6].

The current case demonstrated a successful focused neck exploration undertaken during the 2nd trimester which is an agreed optimal time for surgery [32]. For women diagnosed with PA and are planning to get pregnant, information should be provided regarding the difficulty and risks associated with the management of primary hyperparathyroidism during pregnancy [33].

#### 4. Conclusion

EPA in pregnancy is rare, with challenges in diagnosis and management. A high index of suspicion is useful, and as even mild elevations of maternal serum calcium can exert potential negative effects on the fetus, a surgical approach should be considered over conservative therapy. A multidisciplinary approach is required in order to select the safest imaging modalities for pre-operative localization of the EPA in pregnancy which will allow for a focused, shorter and less invasive surgical procedure. The procedure should be performed by an experienced surgeon taking into consideration the ectopic location of the PA and the potential intraoperative technical difficulties and morbidities related to both the mother and fetus.

#### Declaration of Competing Interest

The authors report no declarations of interest.

#### Funding

Nothing to declare.

#### Ethical approval

Approved by Medical Research Center, Hamad Medical Corporation reference number (MRC-04-20-859).

## Consent

Written informed consent was obtained from the patient for publication of this case report and accompanying images. A copy of the written consent is available for review by the Editor-in-Chief of this journal on request.

## Registration of research studies

Not first in Man.

## Guarantor

Prof Dr Walid El Ansari.

## Provenance and peer review

Not commissioned, externally peer-reviewed.

## CRediT authorship contribution statement

**Abdelrahman Abusabeib:** Investigation, Writing - review & editing. **Harun Bhat:** Investigation, Writing - original draft, Writing - review & editing. **Walid El Ansari:** Investigation, Supervision, Project administration, Writing - original draft, Writing - review & editing. **Mohamed S. Al Hassan:** Investigation, Project administration, Writing - review & editing. **Abdelrahman Abdelaal:** Investigation, Project administration, Writing - review & editing.

## References

- [1] G. Nossios, Ectopic parathyroid glands and their anatomical, clinical and surgical implications, *Exp. Clin. Endocrinol. Diabetes* 120 (2012) 604–610.
- [2] R. Bliss, P. Gauger, L. Delbridge, Surgeon's approach to the thyroid gland: surgical anatomy and the importance of technique, *World J. Surg.* 24 (2000) 891–897.
- [3] R. Phitayakorn, C.R. McHenry, Incidence and location of ectopic abnormal parathyroid glands, *Am. J. Surg.* 191 (2006) 418–423.
- [4] V. Mendoza, C. Ramirez, A. Espinoza, G. González, J. Peña, M. Ramirez, I. Hernández, M. Mercado, Characteristics of ectopic parathyroid glands in 145 cases of primary hyperparathyroidism, *Endocr. Pract.* (2010) 977–981.
- [5] T. Madkhali, A. Alhefthi, H. Chen, D. Elfenbein, Primary hyperparathyroidism, *Ulus. Travma Acil Cerrahi Derg.* 32 (2016) 58–66.
- [6] T.P.W. McMullen, D.L. Learoyd, D.C. Williams, Hyperparathyroidism in pregnancy: options for localization and surgical therapy, *World J. Surg.* 34 (2010) 1811–1816.
- [7] C. Marcocci, F. Cetani, Clinical practice. Primary hyperparathyroidism, *N. Engl. J. Med.* 365 (2011) 2389–2397.
- [8] J. Norman, D. Politz, L. Politz, Hyperparathyroidism during pregnancy and the effect of rising calcium on pregnancy loss: a call for earlier intervention, *Clin. Endocrinol.* 71 (2009) 104–109.
- [9] K.C. Kort, H.J. Schiller, P.J. Numann, Hyperparathyroidism and pregnancy, *Am. J. Surg.* 177 (1999) 66–68.
- [10] M.T. Truong, M.L. Lalakea, P. Robbins, M. Friduss, Primary hyperparathyroidism in pregnancy: a case series and review, *Laryngoscope* 118 (2008) 1966–1969.
- [11] R.A. Agha, M.R. Borrelli, R. Farwana, K. Koshy, A. Fowler, D.P. Orgill, For the SCARE Group, The SCARE 2018 statement: updating consensus Surgical CAseREport (SCARE) guidelines, *Int. J. Surg.* 60 (2018) 132–136.
- [12] W.B. Horton, M.M. Stumpf, J.D. Coppock, Gestational primary hyperparathyroidism due to ectopic parathyroid adenoma: case report and literature review, *J. Endocr. Soc.* 1 (2017) 1150–1155.
- [13] D.J. Hosking, Calcium homeostasis in pregnancy, *Clin. Endocrinol.* 45 (1996) 1–6.
- [14] N.G. Mokrysheva, A.K. Eremkina, S.S. Mirnaya, A case of pregnancy complicated by primary hyperparathyroidism due to a parathyroid adenoma, *Am. J. Case Rep.* 20 (2019) 53–59.
- [15] A.F. Saad, L.D. Pacheco, M.M. Costantine, Management of ectopic parathyroid adenoma in pregnancy, *Obstet. Gynecol.* 124 (2014) 478–480.
- [16] S.I. Dinçer, A. Demir, H.V. Kara, M.Z. Günlüoğlu, Thoracoscopic removal of a maternal mediastinal ectopic parathyroid adenoma causing neonatal hypocalcemia: a case report, *Ann. Thorac. Cardiovasc. Surg.* 14 (2008) 325–328.
- [17] P.F. Schnatz, S.L. Curry, Primary hyperparathyroidism in pregnancy: evidence-based management, *Obstet. Gynecol. Surv.* 57 (2002) 365–376.
- [18] S. Malekar-Raikar, B.P. Sinnott, Primary hyperparathyroidism in pregnancy—a rare cause of life-threatening hypercalcemia: case report and literature review, *Case Rep. Endocrinol.* 2011 (2011) 516–520.
- [19] T. Dahlman, H.E. Sjöberg, E. Bucht, Calcium homeostasis in normal pregnancy and puerperium. A longitudinal 6 Case Reports in Endocrinology study, *Acta Obstet. Gynecol. Scand.* 73 (1994) 393–398.
- [20] W. Shen, M. Düren, E. Morita, Reoperation for persistent or recurrent primary hyperparathyroidism, *Arch. Surg.* 131 (1996) 861–869.
- [21] K.S. Norton, L.W. Johnson, F.D. Griffen, J. Burke, S. Kennedy, D. Aultman, Li. BD, G. Zibari, The sestamibi scan as a preoperative screening tool, *Am. Surg.* 68 (2002) 812–815.
- [22] S.R. Moosvi, S. Smith, J. Hathorn, T. Groot-Wassink, Evaluation of the radiation dose exposure and associated cancer risks in patients having preoperative parathyroid localization, *Ann. R. Coll. Surg. Engl.* 99 (2017) 363–368.
- [23] D.P. Rooney, A.I. Traub, C.F. Russell, Cure of hyperparathyroidism in pregnancy by sternotomy and removal of a mediastinal parathyroid adenoma, *Postgrad. Med. J.* 74 (1998) 233–234.
- [24] Maria Triantafyllidou, et al., Localisation of ectopic mediastinal parathyroid adenoma by 18F-fluorocholine PET/CT, *BMJ Case Rep.* 2018 (2018), bcr2017222089.
- [25] E. Malheiro, N. Chabbert-Buffet, J.N. Talbot, S. Périé, Hyperparathyroidism in pregnancy and <sup>99m</sup>Tc-MIBI scintigraphy, *Eur. Ann. Otorhinolaryngol. Head Neck Dis.* 136 (2019) 501–503.
- [26] M.J. Carella, V.V. Gossain, Hyperparathyroidism and pregnancy: case report and review, *J. Gen. Intern. Med.* 4 (1992) 448–453.
- [27] D. Hirsch, V. Kopel, V. Nadler, S. Levy, Y. Toledano, G. Tsvetov, Pregnancy outcomes in women with primary hyperparathyroidism, *J. Clin. Endocrinol. Metab.* 100 (2015) 2115–2122.
- [28] J. Westerdahl, A. Bergenfelz, Unilateral versus bilateral neck exploration for primary hyperparathyroidism: five-year follow-up of a randomized controlled trial, *Ann. Surg.* 246 (2007) 976–980.
- [29] P.G. Duncan, Fetal risk of anesthesia and surgery during pregnancy, *Anesthesiology* 64 (1986) 790–794.
- [30] B.C. Visser, R.E. Glasgow, K.K. Mulvihill, S.J. Mulvihill, Safety and timing of nonobstetric abdominal surgery in pregnancy, *Dig. Surg.* 18 (2001) 409–417.
- [31] T.R. Kelly, Primary hyperparathyroidism during pregnancy, *Surgery* 110 (1991) 1028–1033.
- [32] P. Pothiwala, S. Levine, Parathyroid surgery in pregnancy: review of the literature and localization by aspiration for parathyroid hormone levels, *J. Perinatol.* 29 (2009) 779–784.
- [33] A.N. DiMarco, K. Meeran, I. Christakis, V. Sodhi, C.N. Piercy, N.S. Tolley, F.F. Palazzo, Seventeen cases of primary hyperparathyroidism in pregnancy: a call for management guidelines, *J. Clin. Endocrinol. Metab.* 3 (2019) 1009–1021.

## Open Access

This article is published Open Access at [sciencedirect.com](https://www.sciencedirect.com). It is distributed under the [IJSCR Supplemental terms and conditions](#), which permits unrestricted non commercial use, distribution, and reproduction in any medium, provided the original authors and source are credited.