

Submitted: 05/04/2021

Accepted: 21/06/2021

Published: 05/08/2021

## Effects of timolol maleate eye drops on experimentally dilated cardiomyopathy and healthy rabbits

Mitsuhiro Isaka\*, Reimi Hayashida, Yuumi Tamashima and Ryuji Araki

Department of Small Animal Clinical Sciences, School of Veterinary Medicine, Rakuno Gakuen University, Ebetsu, Japan

### Abstract

**Background:** Dilated cardiomyopathy (DCM) is the most frequently diagnosed cardiomyopathy in rabbits. Timolol maleate (nonselective beta-blockers), which reduces the heart rate (HR) and blood pressure, has been used for glaucoma. However, this effect has not been assessed in a rabbit DCM model.

**Aim:** This study aimed to evaluate the circulatory effects of 0.5% timolol maleate eye drops on rabbit DCM models.

**Methods:** Rabbits were randomly divided into healthy ( $n = 8$ ) and DCM rabbits ( $n = 8$ ). Rabbit DCM models were established through intravenous administration of daunorubicin (4 mg/kg/week), an anthracycline anticancer drug, for 6 weeks. We measured the HR, mean arterial pressure (MAP), and echocardiography before (pre) and at 10, 30, 60, and 120 minutes after timolol maleate administration.

**Results:** Timolol maleate 0.5% eye drops significantly reduced the HR at 10, 30, and 60 minutes in DCM models and 10 minutes in healthy rabbits; however, there were no alterations in MAP. There was a significant fraction shortening elevation at 10 and 120 minutes in DCM models; moreover, there were marked ejection fraction elevations at all measurement points in only DCM models.

**Conclusion:** Timolol maleate eye drops exert several effects on the circulatory system in rabbit DCM models and healthy rabbits.

**Keywords:** Dilated cardiomyopathy, Eye drops, Rabbit, Timolol.

### Introduction

Numerous myocardial diseases have been reported in rabbits; furthermore, cardiomyopathy is a common postmortem finding in older rabbits (Redrobe, 2001). Primary cardiomyopathies can be classified as hypertrophic, restrictive, or dilated, with all these different forms being reported (Varga, 2014) and dilated cardiomyopathy (DCM) being the most common in rabbits (Mitchell *et al.*, 2008; Orcutt, 2014). Anthracyclines are cytotoxic anticancer antibiotics derived from the Gram-positive bacterium *Streptomyces*. They have been used for hematopoietic tumors and numerous cancer types (Merlet *et al.*, 2013). Electrocardiography has revealed arrhythmias and myocardial damage in the acute and chronic phases, respectively. Irreversible myocardial damage results in myofibril alignment abnormalities, vacuolar myocardium degeneration, prolapse, and necrosis. Consequently, the myocardium thins and the cardiac cavity expands due to reduced cardiac contractility, which induces DCM (Watanabe *et al.*, 2000; Merlet *et al.*, 2013; Hallman *et al.*, 2019); moreover, clinical symptoms, including arrhythmia as well as loss of appetite and energy, are observed (Hallman *et al.*, 2019). Previous treatments of choice for DCM were angiotensin-converting enzyme inhibitors and other drugs. Moreover, beta-blockers

were contraindicated as treatments, given their altered negative potency. However, beta-blockers slow down the progression of heart failure and improve cardiac function in human medicine (Abi-Samra and Gutterman, 2016). Other studies have reported that the administration of metoprolol, which is a beta-blocker, reduces the heart rate (HR) (Wu *et al.*, 2019). Moreover, low-dose carvedilol, a nonselective beta-blocker, has been reported to inhibit the progression of myocarditis to chronic DCM in rats (Watanabe *et al.*, 2000). Specifically, beta-blocker usage has become more established as a treatment given their better prognosis compared with that of angiotensin-converting enzyme inhibitors and their ability to inhibit heart failure progression (Merlet *et al.*, 2013). Timolol, which is a nonselective beta-blocker, has been used to treat glaucoma and reduce intraocular pressure (IOP) through inhibition of the production of ocular aqueous humor. However, this drug affects IOP and HR, and blood pressure (Bartels *et al.*, 1980; Merlet *et al.*, 2013). This study aimed to evaluate the circulatory effect of timolol eye drops in rabbit DCM models compared to healthy rabbits.

### Materials and Methods

Eight New Zealand white rabbits were placed in a cylindrical retainer; subsequently, 24 G indwelling

\*Corresponding Author: Mitsuhiro Isaka. Department of Small Animal Clinical Sciences, School of Veterinary Medicine, Rakuno Gakuen University, Ebetsu, Japan. Email: [m-isaka@rakuno.ac.jp](mailto:m-isaka@rakuno.ac.jp)

needles were placed in either the left or right auricular vein. Next, intravenous administration of daunorubicin (4 mg/kg) over 8 minutes was carried out by two predetermined individuals to avoid extensively stressing the animals, once per week for 6 weeks as previously described (Talavera *et al.*, 2015; Isaka *et al.*, 2021). After a 2-week observation period, we confirmed the establishment of DCM models. Auscultation, blood pressure measurement, and echocardiography were carried out in the provided order before the eye drops were administered (pre). Next, timolol maleate 0.5% eye drop was applied to the right eye, and the aforementioned tests were repeated 10, 30, 60, and 120 minutes after administration. During the waiting period, the rabbits were kept in a carrying case to minimize stress and prevent excitement from affecting the measurements. Three minutes before the measurement, one researcher placed the rabbits in the prone position. Blood pressure measurements were obtained through the oscillometric method using the pet map graphic II veterinary blood pressure monitor (AVS Corporation). Another research wrapped a 2.5 cm cuff around the right hand and measured the blood pressure six times, with the average of the six readings being obtained. An ACUSON SC2,000 PRIME (Siemens Healthineers, Shinagawa, Tokyo) was used for echocardiographic measurement of fraction shortening (FS) and ejection fraction (EF). We compared the pre-treatment values with those at 10, 30, 60, and 120 minutes after eye drop administration. Statistical analysis software *R* was used. Based on the Shapiro–Wilk test results, the variances were determined using a Wilcoxon signed-ranked test, compared to pre-administration, and Mann–Whitney *U* test to compare both groups.  $p < 0.05$  was considered statistically significant.

#### Ethical approval

This study was approved by the Rakuno Gakuen University, School of Veterinary Medicine Institutional Animal Care and Use Committee (approval no. VH19A10).

## Results and Discussion

There was a significant reduction in HR at 10, 30, and 60 minutes after the administration of timolol maleate eye drops in DCM models and 10 minutes in healthy rabbits; however, there were no alterations in the MAP of both groups (Fig. 1). Upon timolol maleate treatment, FS significantly increased at 10 and 120 minutes, while EF showed marked elevations at all measurement points in the DCM models (Fig. 2).

0.5% timolol maleate eye drops did not induce alterations in MAP; however, they had several circulatory effects, especially FS and EF improvements, in the daunorubicin-induced DCM models. B-receptors are catecholamine receptors and are of two types:  $\beta_1$  and  $\beta_2$ .  $\beta_1$  receptors are found in the sinoatrial node, which regulates the heart rhythm and the myocardium and atrial muscle, regulating heart contractility. The sinoatrial node is excited by mouth opening and influx of calcium ions into the cells, which excites the cells and fastens the HR. Additionally,  $\beta$ -receptors are involved in vascular smooth muscle contraction, which increases blood pressure. Timolol is a nonselective  $\beta$ -blocker that suppresses  $\beta_1$  receptors and blocks their effects on cardiac myocytes and the sinusoidal nodule, reducing HR and cardiac contractility. Similarly, it inhibits  $\beta_2$  receptors, which suppresses vascular smooth muscle excitation and increases blood pressure. These two effects have been similarly observed in numerous studies on glaucoma using timolol as a therapeutic agent (Januleviciene *et al.*, 2012; Mishra *et al.*, 2014; Oddone *et al.*, 2015; Gunther-Harrington *et al.*, 2016; McCauley *et al.*, 2020; Slenter *et al.*, 2020). In this study, timolol maleate administration decreased the HR but did not alter the MAP. A doxorubicin-induced cardiomyopathy rat model showed a decrease in  $\beta_1$  and an increase in  $\beta_2$  receptor expressions, which caused an increase in the alternative action of  $\beta_2$  receptors (Merlet *et al.*, 2013). Thus, the circulatory effects in our study might be related to the altered functions and

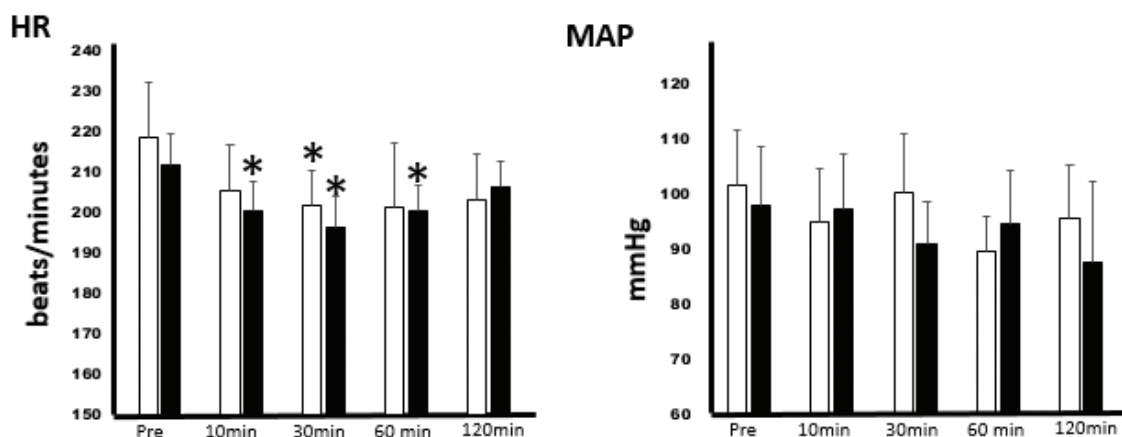


Fig. 1. Effects of timolol eye drops on HR and mean blood pressure.

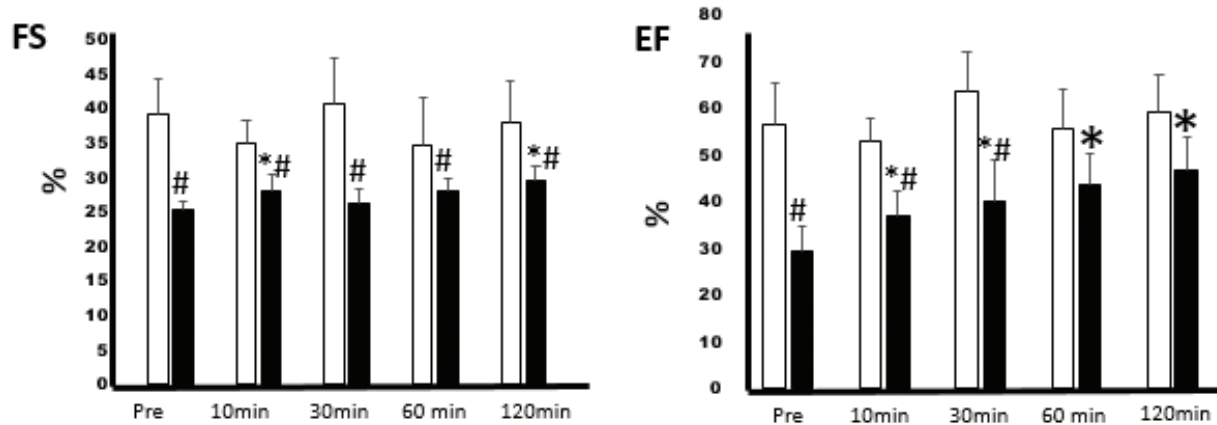


Fig. 2. Effects of timolol eye drops on echocardiographic parameters.

numbers of receptor subtypes. Blood flow velocity is determined based on the pressure difference between the left atrium and left ventricle; this difference is specifically determined by the preload. In general, cardiac output, which is calculated as (stroke volume)  $\times$  (HR), is defined by preload, afterload, and cardiac contractility. Taken together, these findings suggest that timolol maleate eye drops might improve FS and EF, which results in a decrease in HR and an unchanged MAP. A previous study on the rabbit maleate eye reported that 0.5% timolol eye drops at approximately 40% inhibited isoproterenol-stimulated cyclic adenosine monophosphate production by the cornea *in vitro* at 3 hours, but HR showed a peak decrease at 1.5 hours (Bartels *et al.*, 1980). Although our study evaluated the circulatory effects for 2 hours, the peak decrease of HR in the DCM models was observed at 30 minutes after timolol maleate administration, which suggests that the circulatory reaction might be different from that of the healthy rabbits, consistent with a previous study (Bartels *et al.*, 1980). Although there was a difference between systemic and ocular effects, timolol eye drops might present circulatory effects for  $> 2$  hours. Therefore, there is a need to evaluate the circulatory effects over a longer duration. The present study showed a trend toward increased EF and FS with timolol maleate eye drops administration in the DCM models, compared to healthy rabbits; this effect might be clinically meaningful. However, further studies are needed to evaluate clinical DCM and healthy cases.

#### Acknowledgment

The authors would like to thank Editage (www.editage.com) for English language editing.

#### Conflict of interest

The authors declare that there is no conflict of interest.

#### Funding

This research did not receive any specific grant from funding agencies in the public, commercial, or not-for-profit sectors.

#### Authors' contribution

Mitsuhiro Isaka: principal investigator, study idea, study design, data analysis, and manuscript preparation; Tamashima Yumi, Reimi Hayashida, and Ryuji Araki: data collection and data analysis.

#### References

- Abi-Samra, F. and Gutterman, D. 2016. Cardiac contractility modulation: a novel approach for the treatment of heart failure. *Heart. Fail. Rev.* 21, 645–660.
- Bartels, S.P., Roth, H.O., Jumblatt, M.M. and Neufeld, A.H. 1980. Pharmacological effects of topical timolol in the rabbit eye. *Invest. Ophthalmol. Vis. Sci.* 19, 1189–1197.
- Gunther-Harrington, C.T., Ontiveros, E.S., Hodge, T.E., Visser, L.C. and Stern, J.A. 2016. Effects of 0.5% timolol maleate ophthalmic solution on heart rate and selected echocardiographic indices in apparently healthy cats. *J. Vet. Intern. Med.* 30, 733–740.
- Hallman, B.E., Hauck, M.L., Williams, L.E., Hess, P.R. and Suter, S.E. 2019. Incidence and risk factors associated with development of clinical cardiotoxicity in dogs receiving doxorubicin. *J. Vet. Intern. Med.* 33, 783–791.
- Isaka, M., Hayashida, R., Tamashima, Y. and Araki, R. 2021. Surgical ventricular restoration for rabbit dilated cardiomyopathy model: preliminary study. *Res. Vet. Sci.* 136, 373–376.
- Januleviciene, I., Siaudvytyte, L., Diliene, V., Barsauskaite, R., Paulaviciute-Baikstiene, D., Siesky, B. and Harris, A. 2012. Comparison of intraocular pressure, blood pressure, ocular perfusion pressure and blood flow fluctuations during dorzolamide versus timolol add-on therapy in prostaglandin analogue treated glaucoma subjects. *Pharmaceuticals (Basel)*. 5, 325–338.
- McCauley, S.R., Clark, S.D., Quest, B.W., Streeter, R.M. and Oxford, E.M. 2020. Review of canine

- dilated cardiomyopathy in the wake of diet-associated concerns. *J. Anim. Sci.* 98, 1–20.
- Merlet, N., Piriou, N., Rozec, B., Grabherr, A., Lauzier, B., Trochu, J.N. and Gauthier, C. 2013. Increased beta2-adrenoceptors in doxorubicin-induced cardiomyopathy in rats. *PLoS. One.* 8, 1–15.
- Mishra, D., Sinha, B.P. and Kumar, M.S. 2014. Comparing the efficacy of latanoprost (0.005%), bimatoprost (0.03%), travoprost (0.004%), and timolol (0.5%) in the treatment of primary open angle glaucoma. *Korean J. Ophthalmol.* 28, 399–407.
- Mitchell, E.B., Zehnder, A.M., Hsu, A. and Hawkins, M.G. 2008. Pimobendan: treatment of heart failure in small mammals. *Proceed 29th Annu AAV Conf & Expo with AEMV*, pp: 71–79.
- Oddone, F., Rossetti, L., Tanga, L., Berardo, F., Ferrazza, M., Michelessi, M., Roberti, G., Manni, G. and Centofanti, M. 2015. Effects of topical bimatoprost 0.01% and timolol 0.5% on circadian IOP, blood pressure and perfusion pressure in patients with glaucoma or ocular hypertension: a randomized, double masked, placebo-controlled clinical trial. *PLoS. One.* 10, 1–15.
- Orcutt, C. 2014. Cardiovascular disorders. In *BSAVA Manual of Rabbit Medicine*. Eds., Meredith, A., Lord, B., Quedgeley, UK: BASAVA, pp: 205–213.
- Redrobe, S. 2001. Imaging techniques in small mammals. *Sem. Avian Exot. Pet. Med.* 10, 187–197.
- Slenter, I.J.M., Djajadiningrat-Laanen, S.C., Elders, D.J., de Gee, R., Koele, L.E., Vermeer, L.W. and Boeve, M.H. 2020. The effects of topical dorzolamide 2% and brinzolamide 1%, either alone or combined with timolol 0.5%, on intraocular pressure, pupil diameter, and heart rate in healthy cats. *Vet. Ophthalmol.* 23, 16–24.
- Talavera, J., Giraldo, A., Fernández-Del-Palacio, M.J., Garcia-Nicolas, O., Seva, J., Brooks, G. and Moraleda, J.M. 2015. An upgrade on the rabbit model of anthracycline-induced cardiomyopathy: shorter protocol, reduced mortality, and higher incidence of overt dilated cardiomyopathy. *Biomed. Res. Int.* 8, 1–13.
- Varga, M. 2014. Cardiorespiratory disease. in: *Textbook of Rabbit Medicine*, 2nd ed. Edinburgh, UK: Butterworth-Heinemann, pp: 390–404.
- Watanabe, K., Ohta, Y., Nakazawa, M., Higuchi, H., Hasegawa, G., Naito, M., Fuse, K., Ito, M., Hirono, S., Tanabe, N., Hanawa, H., Kato, K., Kodama, M. and Aizawa, Y. 2000. Low-dose carvedilol inhibits progression of heart failure in rats with dilated cardiomyopathy. *Br. J. Pharmacol.* 130, 1489–1995.
- Wu, L., Zhang, Q., Shu, Q., Zhang, R. and Meng, Y. 2019. Sex-dependent changes in physical, mental, and quality of life outcomes in metoprolol-treated Chinese chronic heart failure patients. *Medicine.* 98, 1–8.